

Pathogenesis and Management of Thrombosis with Thrombocytopenia Syndrome (TTS)

Michael B. Streiff, MD
Medical Director

The Johns Hopkins Anticoagulation Management Service and Hemostatic Disorder
Stewardship Program

The Johns Hopkins Special Coagulation Laboratory
Professor of Medicine & Professor of Pathology
Johns Hopkins University School of Medicine

Disclosures: Michael B. Streiff, MD

- Consulting

- Bristol-Myers Squibb
- Coagulo Medical Technologies
- Dispersol
- Janssen
- Pfizer

- Research support

- AHRQ
- Janssen
- NIH/NHLBI
- PCORI

What is Cerebral Venous Sinus Thrombosis?

Clinical characteristics: Thrombosis in the deep or superficial veins of the brain

Incidence: 10-15 cases per million

Mean Age: 35 years

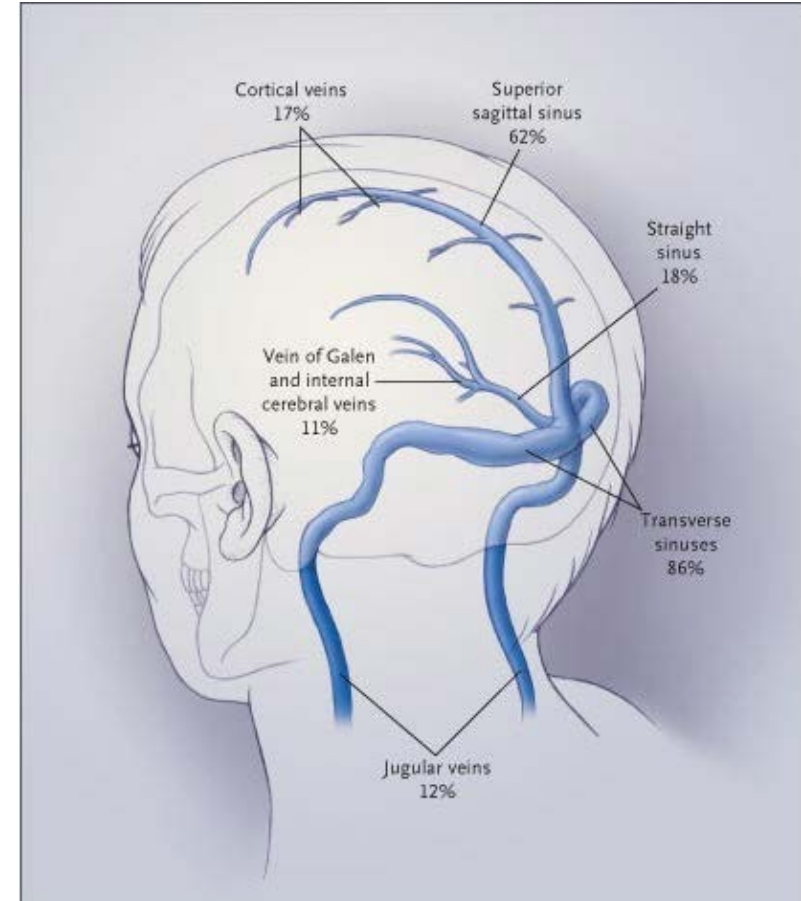
Gender distribution F:M 2.2 : 1

Clinical presentation: Headache, seizures, limb weakness, reduced consciousness/coma

Risk factors: Oral contraceptives, clotting disorders, pregnancy, cancer, infections, surgery

Diagnosis: Contrast CT or MR venogram

Treatment: Anticoagulation, thrombolysis



What are the clinical characteristics of TTS?

Associated with replication-defective adenoviral vector SARS-CoV-2 vaccines

Incidence: Estimated 1 case per 100,000-250,000/vaccine recipients

Age range: 21- 77 years (90% less than 60)

Gender distribution F:M 2.5 : 1

Median onset: 10 days (range 5-24 days)

Thrombotic events: Cerebral venous sinus thrombosis (N=27), DVT/PE (10), Abdominal vein clots (7), Arterial clots (6)

Heparin induced thrombocytopenia testing: Platelet factor 4 antibody immunoassay positive, Platelet activation assays (variable)

Platelet nadir: 27,000/ μ L (range 7-113,000) , Fibrinogen nadir: 125 mg/dL (range 40-568), D dimer $\uparrow\uparrow\uparrow$

Progression of thrombosis on heparin, platelet recovery with IVIG

Comparison of thrombotic events after Oxford-AZ and Johnson + Johnson SARS-CoV-2 vaccines

Oxford-AZ SARS-CoV-2 Vaccine Cases

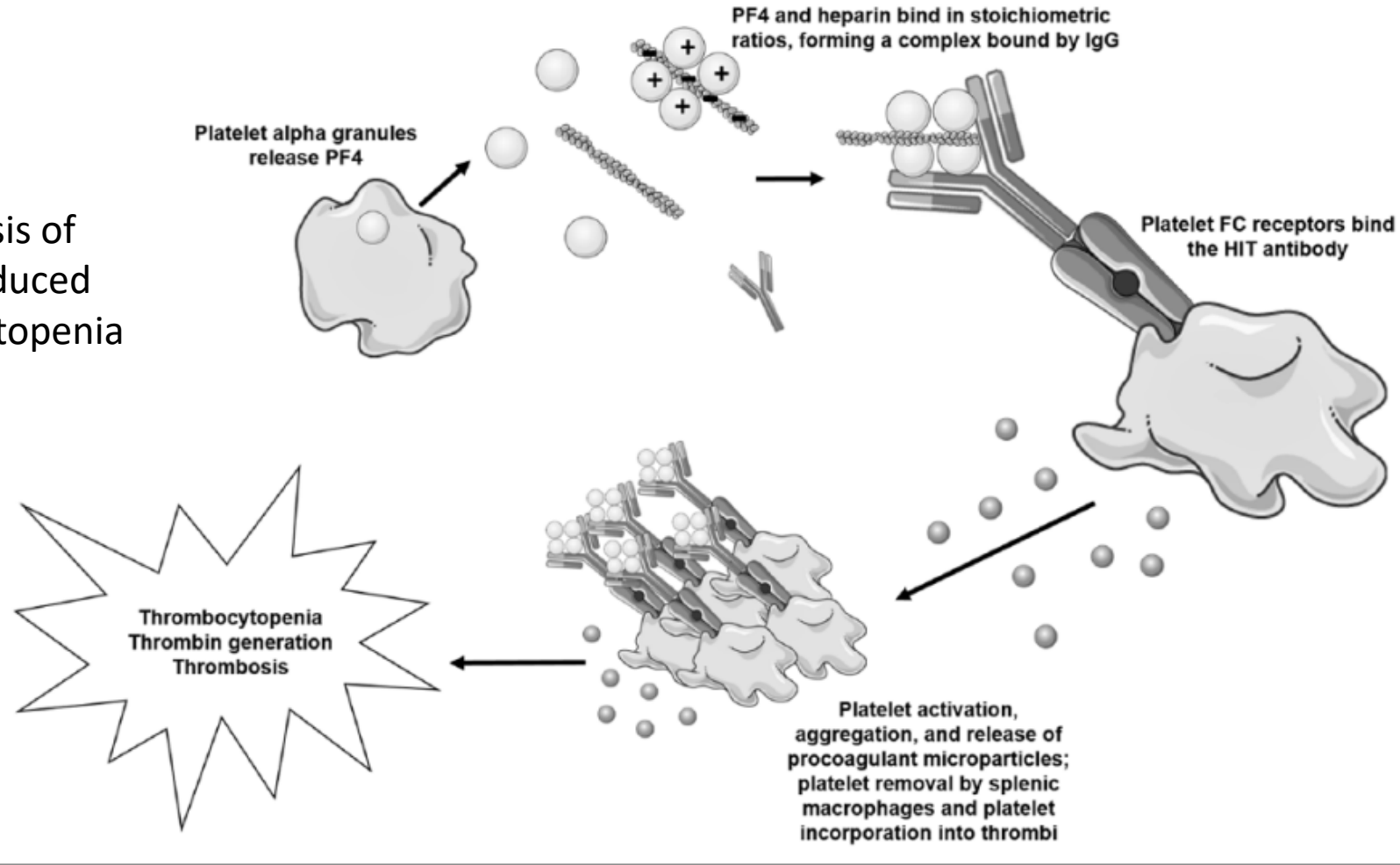
- Median age 40 (range 21-77)
- Gender: F:M 2.5:1
- Onset: 5-24 days after vaccine
- Symptoms: Headache, backache, abdominal pain, visual disturbance, leg/arm weakness
- Thrombosis: Cerebral , Abdominal veins, DVT/PE, arterial thrombosis
- Platelet nadir: 7-113,000
- Heparin-Platelet factor 4 immunoassay-positive
- Platelet activation assay- positive

Johnson + Johnson SARS-CoV-2 Vaccine cases

- Age range teens to 50s
- Gender F:M 8:0
- Onset: 6-13 days
- Symptoms: Headache, lethargy, back pain, abdominal pain, neurologic symptoms
- Thrombosis: Cerebral veins, abdominal veins
- Platelet nadir: 10-127,000
- Heparin-Platelet factor 4 immunoassay-positive
- Platelet activation assay-negative 4 of 5

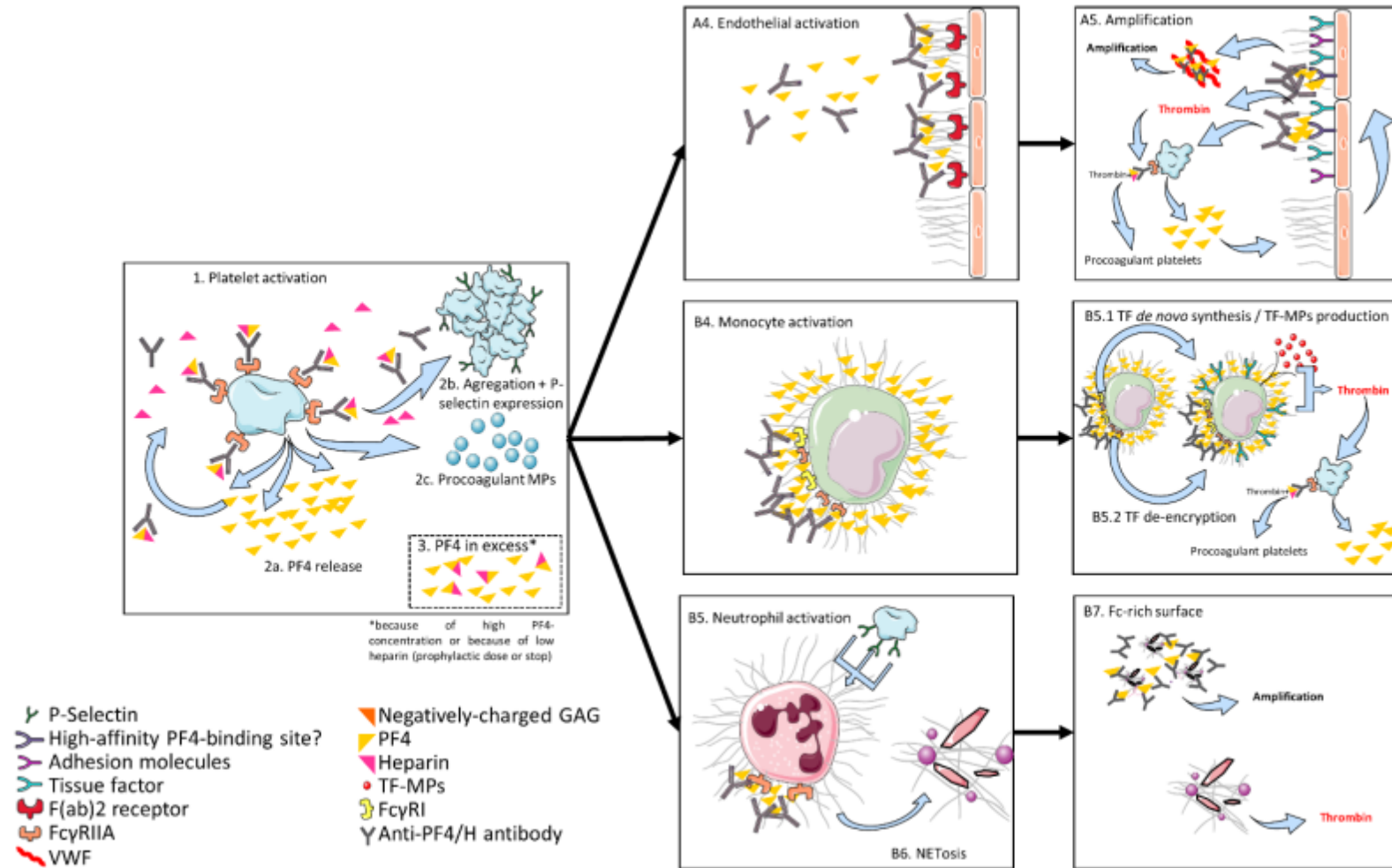
Pathogenesis of TTS Appears to be Similar to Autoimmune Heparin Induced Thrombocytopenia

Pathogenesis of Heparin-induced thrombocytopenia



Hogan M, Berger JS. Vasc Med. 2020 Apr;25(2):160-173.

Heparin Induced Thrombocytopenia Antibodies Lead to Multicellular Activation of Coagulation



Marchetti M, Zermatten MG, Bertaggia Calderara D, Aliotta A, Alberio L. J Clin Med. 2021 Feb 10;10(4):683.

TTS is similar to Autoimmune Heparin Induced Thrombocytopenia

- Laboratory testing consistent with autoimmune heparin induced thrombocytopenia
 - Positive platelet factor 4 immunoassay and platelet activation assays
 - Platelet activation enhanced by addition of platelet factor 4
 - Platelet activation inhibited by high concentrations of heparin
 - Platelet activation blocked by intravenous immunoglobulin
- Clinical course consistent with heparin induced thrombocytopenia
 - Onset mirrors onset of autoimmune thrombocytopenia
 - Thrombosis and thrombocytopenia worsens with heparin treatment
 - Clinical manifestations improve with non-heparin anticoagulation and IVIG
- Etiology of Thrombotic Thrombocytopenia Syndrome is Unclear
 - Does not appear to molecular mimicry between platelet factor 4 and SARS-CoV2 spike protein
 - 0 of 222 patients with SARS-CoV-2 infection have platelet activating antibodies

Management of Thrombosis Thrombocytopenia Syndrome

- Maintain a high index of suspicion for any patient that presents with symptoms of a clot in association with thrombocytopenia after recent (within 3 weeks) administration of the J+J SARS CoV2 vaccine
- Confirm the thrombotic event
- Send testing for heparin-induced thrombocytopenia with platelet factor 4 immunoassay and platelet activation assay
- Consult a hematologist to confirm the diagnosis and rule out other diagnostic possibilities
- Treat clots with a non-heparin anticoagulant
- Treat the thrombocytopenia with intravenous immunoglobulin
 - Avoid platelet transfusions

Questions

