DYSBARISM-RELATED OSTEONECROSIS

A SYMPOSIUM

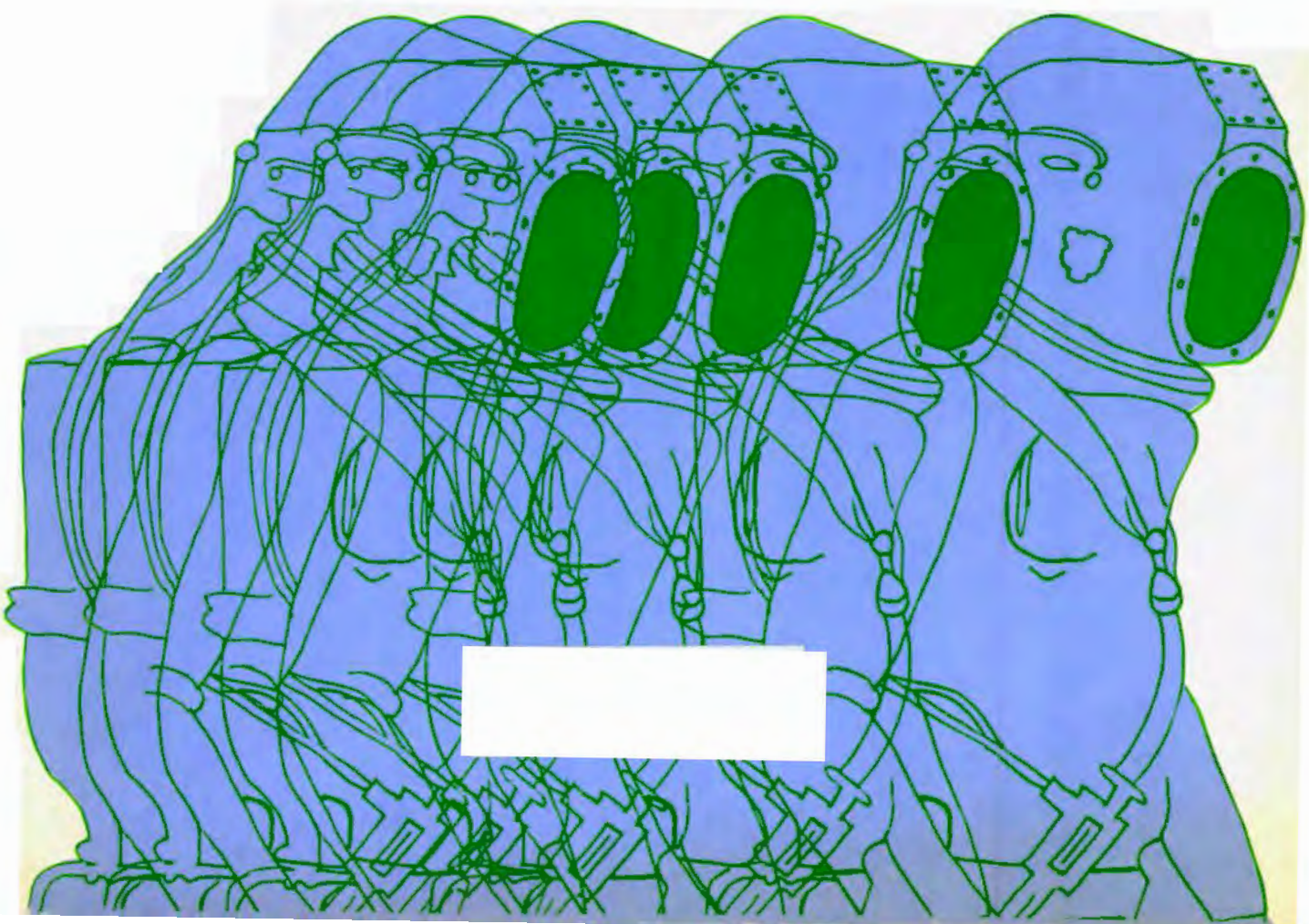

DYSBARISM-RELATED OSTEONECROSIS

Proceedings of a Symposium on Dysbaric Osteonecrosis

Presented by the

Marine Biomedical Institute
The University of Texas Medical Branch
Galveston, Texas
February 1972

Sponsored by the

National Institute for Occupational Safety and Health

Scientific Editors

EDWARD L. BECKMAN
DAVID H. ELLIOTT

Volume Editor

ELIZABETH MIREMONT SMITH

U.S. DEPARTMENT OF HEALTH, EDUCATION, AND WELFARE

Public Health Service
Center for Disease Control
National Institute for Occupational Safety and Health

1974

FOREWORD

It is the responsibility of the National Institute for Occupational Safety and Health (NIOSH) to help assure that every person in the nation has safe and healthful working conditions. To accomplish this end, the Institute engages in research on occupational safety and health problems including evaluation of hazards and toxicity determinations.

One of the many hazards considered for investigation by the Institute is barotrauma, a stress induced in workers subject to large changes in atmospheric pressure, such as those encountered in deep-sea diving. Thus we were pleased to sponsor the Symposium on Dysbaric Osteonecrosis which brought together individuals interested in this bone disease, including its medical, legal, and economic aspects.

This volume contains the edited proceedings of the Symposium. This is the only known source book on the subject of osteonecrosis. We hope that it will provide the basis for further research.

Edward J. Baier
Acting Director, NIOSH

PREFACE

The Industrial Revolution not only increased man's creature comforts, but also his liability to industrial diseases. One such disease is osteonecrosis related to decompression sickness, or dysbarism.

Osteonecrosis has long been recognized as secondary to other disease processes — *e.g.*, sickle-cell anemia or fracture of the neck of the femur. But it was only when man began exposing himself to large changes in ambient pressure, such as in flying, diving, and working in a caisson, that he learned about decompression sickness. Even more recently he learned that osteonecrosis is one aspect of this perplexing disease of dysbarism. Osteonecrosis thus caused may be considered a chronic form of the disease; it may be debilitating and invaliding as well. This disease is therefore of vital concern whenever man must breathe compressed air in the course of building bridges or tunnels, or when he dives deep into the sea to harvest its resources.

The term *osteonecrosis* is, in the opinion of the Chairmen of this Symposium, currently the most widely accepted and the least ambiguous term available to describe the disease. It has also been known by a wide variety of other names — *e.g.*, aseptic, avascular, and ischemic necrosis of bone. The term *dysbaric osteonecrosis* identifies the particular disease process found in otherwise healthy laborers who work in compressed air. It is found as well in aviators and in divers who breathe air, oxygen-helium, or other gases under water. *Dysbaric* distinguishes the condition from the radiologically and histologically similar one found in persons known to be suffering from various chronic illnesses and from the relatively rare so-called idiopathic form of osteonecrosis. Further, the term is chosen carefully so that both hypobaric and hyperbaric workers may be included. This usage precludes scientific prejudgment regarding whether the etiological factors are associated with compression, exposure, decompression, or any other features unique to these occupations.

This Symposium sets out to define for the National Institute for Occupational Safety and Health the epidemiology of the type of osteonecrosis that develops under conditions of hyperbaric exposure. The disease is commonly described in terms of abnormalities revealed radiologically, either an increase or decrease in bone density. But a roentgenogram does not describe the disease process in pathologic terminology. A further purpose of this Symposium, then, is to detail the relationship between dysbarism and osteonecrosis, the disease process, and its etiology (at least the theories concerning the cause of osteonecrosis).

The prevention of osteonecrosis is, quite naturally, the most important subject of the Symposium. One can hardly recommend that there be no more diving, although those who are never exposed to hyperbaric or reduced pressure do not develop dysbarism-related osteonecrosis. Since no consensus exists on the subjects of etiology, prevention, exacerbating conditions, or management of the disease, once it occurs, it becomes obvious that additional research must be conducted to answer these crucial questions.

It is the belief of the Chairmen that this, the proceedings of the first symposium on the subject, will prove to be of value for several years to come for both the participants and those who were unable to attend.

Edward L. Beckman
David H. Elliott
Symposium Chairmen

Preceding page blank

ACKNOWLEDGMENTS

The editors wish specifically to acknowledge the support given them by Dr. Edward J. Fairchild and Dr. Alan H. Purdy of the National Institute for Occupational Safety and Health. They offered not only encouragement but also their personal assistance in all phases of the project, especially in structuring the Symposium and in publishing these Proceedings.

We wish also to thank the Marine Biomedical Institute and the University of Texas Medical Branch — in particular, Robert W. Martindale and his staff — for their help in a multitude of ways in launching both the Symposium and the Proceedings.

The senior editor expresses his personal appreciation to the Moody College of Marine Sciences and Maritime Resources of Texas A&M University, and the Baylor College of Medicine to which he transferred shortly after the Symposium was held. Although the project was not their own, the colleges lent their support willingly and in many valuable ways.

Most of the literature reported in the Annotated Bibliography included in this volume was collected and abstracted (Contract No. N-00014-67-A-0214-0009) to fulfill the requirements of an Office of Naval Research program designed to alert interested individuals to the latest information in the field of underwater activity.

The editors are deeply grateful to Emily Preslar for her patience, helpfulness, and unflagging good humor in coping with such tedious details as verifying the most obscure of references.

Mary Elizabeth Sieber was also of great help to us as editorial consultant, as was Ronald Kelly in the preparation of the illustrations.

Lastly, we have been most gratified with the response of the various Symposium participants. We are deeply grateful for their cooperation and patience in reviewing the manuscripts and in submitting the illustrative materials.

Preceding page blank

AUTHORS AND PANELISTS

Symposium Co-Chairmen:

EDWARD L. BECKMAN, M.D.
Moody College of Marine Sciences and Maritime Resources
Texas A&M University
Galveston, Texas 77550

also:
Professor of Physiology
Baylor College of Medicine
Houston, Texas 77025

DAVID H. ELLIOTT
Surgeon Commander, Royal Navy
Royal Naval Physiological Laboratory
Alverstoke, Hants PO12 2DU, England

ALLEN, Thomas H., Ph.D.
Scientific Advisor
USAF School of Aerospace Medicine (AFSC)
Brooks Air Force Base, Texas 78235

ANDERSON, Carl E., M.D.
Clinical Professor
Department of Orthopedic Surgery
University of California School of Medicine
San Francisco, California 94122

BEHNKE, Albert R., Jr., M.D.
Clinical Professor of Epidemiology and International Health (Retired)
University of California (San Francisco)
Present address:
2241 Sacramento St.
San Francisco, California 94115

BOETTCHER, William G., M.D.
Department of Bone and Joint Surgery
The Mason Clinic
1118 9th Ave.
Seattle, Washington 98101

BOND, Ted P., M.A.
Department of Physiology
The University of Texas Medical Branch
Galveston, Texas 77550

BÜHLMANN, Albert A., M.D.
Department für Innere Medizin der Universität
Kantonsspital Zürich
Rämistrasse 100
8006 Zürich, Switzerland

COOLEY, Robert N., M.D.
Chairman, Department of Radiology
The University of Texas Medical Branch
Galveston, Texas 77550

DAVIS, Jefferson C.
Colonel, USAF, MC
Brooks Air Force Base, Texas 78235

DEISS, William P., Jr., M.D.
Chairman, Department of Internal Medicine
The University of Texas Medical Branch
Galveston, Texas 77550

EVANS, Anthony, Ph.D.
Senior Research Associate
Department of Surgery
Royal Victoria Infirmary
The University of Newcastle upon Tyne
Newcastle upon Tyne NE1 4LP, England

FAGAN, Charles J., M.D.
Assistant Professor, Department of Radiology
The University of Texas Medical Branch
Galveston, Texas 77550

FAIRCHILD, Edward J., Ph.D.
Associate Director
National Institute for Occupational Safety and Health
1014 Broadway
Cincinnati, Ohio 45202

FARAH, Joseph
National Association of Professional Divers, Inc.
P. O. Box 2025
Morgan City, Louisiana 70380

GALERNE, André
President, International Underwater Contractors, Inc.
264 Fordham Place
City Island, New York 10461

GALLETTI, John B., Jr.
President, J & J Marine Diving Company
P. O. Box 4117
Pasadena, Texas 77502

GILLEN, H. William, M.D.
President, Diving Safety Bureau
7205 Wrightsville Ave.
Wilmington, North Carolina 28401

GORTEN, Ralph J., M.D.
Department of Nuclear Medicine
The University of Texas Medical Branch
Galveston, Texas 77550

GUEST, M. Mason, Ph.D.
Professor Emeritus, Department of Physiology
The University of Texas Medical Branch
Galveston, Texas 77550

Preceding page blank

HANDELMAN, Lad R.
President, Oceaneering International
9219 Katy Freeway
Houston, Texas 77024

HARRISON, John A. B.
Surgeon Captain, Royal Navy
Royal Naval Hospital
Haslar, Gosport
Hants, PO12 2AA, England

HARVEY, Claude A., M.D.
Commander, USN, MC
Naval Submarine Medical Research Laboratory
Naval Submarine Base
Groton, Connecticut 06340

HILLS, Brian A., Ph.D.
Reader in Physiology, Queen Elizabeth College
University of London
Campden Hill Road
London W8 7AH, England

HODGSON, Corrin J.
Lieutenant Colonel, USAF, MC
2522 Viking Dr., NW
Rochester, Minnesota 55901

JOHNSON, Ward
Compensation Claim Manager
Employers Insurance of Wausau
6620 West Capitol Dr.
Milwaukee, Wisconsin 53216

JONES, John Paul, Jr., M.D.
Medical and Research Director
Diagnostic Osteonecrosis Center
and Research Foundation
P. O. Box 590
Clearlake Oaks, California 95423

KINDWALL, Eric P., M.D.
Director, Department of Hyperbaric Medicine
St. Luke's Hospital
2900 W. Oklahoma Ave.
Milwaukee, Wisconsin 53215

McCALLUM, R. Ian, M.D.
Nuffield Department of Industrial Health
The University of Newcastle upon Tyne
Newcastle upon Tyne NE2 4AA, England

MILES, James S., M.D.
Chairman, Department of Orthopedics
University of Colorado Medical Center
4200 East 9th Ave.
Denver, Colorado 80220

PAULEY, Stephen M., M.D.
124 Riviera Way
Laguna Beach, California 92651

PECK, Alexander S., Jr.
Lieutenant Commander, USNR, MC
Naval Submarine Medical Research Laboratory
Naval Submarine Base
Groton, Connecticut 06340

PURDY, Alan H., Ph.D.
Acting Deputy Associate Director
Washington Operations, NIOSH
Department of Health, Education, and Welfare
Public Health Service
Rockville, Maryland 20852

SAKOVICH, Leo
Chief Medical Technologist
Orthopedic Surgical Laboratory
Department of Orthopedic Surgery
University of California School of Medicine
San Francisco, California 94122

SEALEY, J. Leon, M.D.
Northwest Industrial Medical Clinic
1500 First Avenue South
Seattle, Washington 98134

SMITH, Kent H., D.V.M., Ph.D.
Chairman, Department of Hyperbaric
Physiology
Virginia Mason Research Center
1000 Seneca St.
Seattle, Washington 98101

SPENCER, Merrill P., M.D.
Director, Institute of Environmental Medicine
and Physiology
556 18th Ave.
Seattle, Washington 98122

STEGALL, Phyllis
Aseptic Bone Necrosis Project
Virginia Mason Research Center
1000 Seneca St.
Seattle, Washington 98101

TEED, John
Messrs. Brown & Teed, Attorneys at Law
2323 Caroline
Houston, Texas 77004

WALDER, Dennis N., M.D.
Professor of Surgical Science
Royal Victoria Infirmary
The University of Newcastle upon Tyne
Newcastle upon Tyne NE1 4LP, England

WELLS, Charles H., II, Ph.D.
Department of Physiology
The University of Texas Medical Branch
Galveston, Texas 77550

WORKMAN, Robert D., M.D.
Director of Research
Taylor Diving & Salvage Company
795 Engineers Road
Belle Chasse, Louisiana 70037

WRIGHT, W. Brandon
Lieutenant Commander, USN, MC
Experimental Diving Unit
Deep Sea Diving School
U.S. Navy Yard
Washington, D.C. 20390

CONTENTS

Page

Foreword iii

Preface v

Acknowledgments vii

Authors and Panelists ix

PART I. OSTEONECROSIS IN COMPRESSED-AIR WORKERS, DIVERS, AND AVIATORS

Osteonecrosis in Tunnel and Caisson Workers 3
R. I. McCallum

Incidence of Osteonecrosis in Royal Naval Divers 7
D. H. Elliott

Discussion 1 8

Sample Survey of Osteonecrosis in Gulf of Mexico Commercial Divers 9
C. J. Fagan and E. L. Beckman, with J. B. Galletti, Jr.

U.S. Air Force Experience in Hypobaric Osteonecrosis 17
T. H. Allen, J. C. Davis, and C. J. Hodgson

Discussion 2 19

PART II. U.S. EXPERIENCE IN COMPRESSED-AIR WORK

Seattle Tunnel Follow-up Report 23
J. L. Sealey

Preliminary BART Tunnel Results 25
A. R. Behnke, Jr., and J. P. Jones, Jr.

Milwaukee Sewerage Tunnel Project 41
E. P. Kindwall

Decompression Tables in Relation to Dysbaric Osteonecrosis 47
C. A. Harvey

Discussion 3 55

PART III. PATHOPHYSIOLOGY OF OSTEONECROSIS

The Metabolism of Bone 61
W. P. Deiss, Jr.

The Pathogenesis of Osteonecrosis 67
J. S. Miles

Fatal Fat Embolism Following Decompression Sickness in an Experimental Dive 83
A. A. Bühlmann

PART IV. OSTEONECROSIS ASSOCIATED WITH OTHER DISEASES

Epidemiological and Etiological Considerations in Osteonecrosis 87
W. G. Boettcher

Osteonecrosis Associated with Metabolic Disease and Corticosteroid Therapy 91
J. P. Jones, Jr.

Discussion 4 102

PART V. EXPERIMENTAL STUDIES

Experimentally Induced Osteonecrosis in Miniature Swine 105
K. H. Smith and P. Stegall

Experimentally Induced Osteonecrosis in Animals 113
D. N. Walder

Experimentally Produced Osteonecrosis as a Result of Fat Embolism 117
J. P. Jones, Jr., L. Sakovich, and C. E. Anderson

Changes in Rheology of Animals Following Various Pressure Exposures 133
M. M. Guest, C. H. Wells II, and T. P. Bond

Some Physiological Aspects of Dysbarism-induced Osteonecrosis 137
B. A. Hills

Discussion 5 143

PART VI. DIAGNOSIS OF OSTEONECROSIS

Radiological Criteria in Diagnosing Dysbaric Osteonecrosis 151
J. A. B. Harrison

Discussion 6 160

Bone Scans with Fluorine-18 in Diagnosing Osteonecrosis in Divers 171
R. J. Gorten and R. N. Cooley

Xeroradiography as a Technique for Diagnosing Osteonecrosis 177
C. J. Fagan and E. L. Beckman

Additional Diagnostic Techniques 183
J. P. Jones, Jr.

Discussion 7 190

Discussion 8 191

PART VII. CASE MANAGEMENT AND TREATMENT

Management and Treatment of Osteonecrosis in Divers and Caisson Workers 195
D. N. Walder

Orthopedic Management and Treatment of Osteonecrosis 201
J. P. Jones, Jr.

Discussion 9 209

PART VIII. VALUE AND FUNCTION OF A MEDICAL REGISTRY

Medical Registry for Bone Necrosis in England 215
R. I. McCallum and A. Evans

Proposal for an Osteonecrosis Registry in the United States 221
H. W. Gillen

Discussion 10 223

PART IX. ADDITIONAL IMPLICATIONS IN OSTEONECROSIS

Medico-legal Aspects of Osteonecrosis 229
J. Teed

Osteonecrosis As It Concerns the Diving Contractor 231
L. R. Handelman

Osteonecrosis As It Concerns the Insurance Underwriter 233
W. Johnson

Discussion 11 235

PART X. RECOMMENDATIONS FOR FUTURE RESEARCH

Role of the National Institute for Occupational Safety and Health 239
E. J. Fairchild

Discussion 12 241

Summary and Recommendations for Future Research 243
E. L. Beckman

Discussion 13 247

APPENDIX

An Annotated Bibliography 251
M. F. Werts and C. W. Shilling

INDEX

..... 269

PART I

OSTEONECROSIS IN COMPRESSED-AIR WORKERS, DIVERS, AND AVIATORS

OSTEONECROSIS IN TUNNEL AND CAISSON WORKERS

R. Ian McCallum

The occurrence of bone necrosis in compressed-air workers in the United Kingdom became generally known in the construction industry and to the general public about 1967. However, the Decompression Sickness Panel (DSP) of the Medical Research Council (MRC) in England has been actively concerned with the problem since about 1959. Sporadic cases of painful and disabling bone necrosis in tunnelers and caisson workers have been described for over 60 years. But only comparatively recently has it been recognized that the disease is a fairly widespread condition in compressed-air workers and that the majority of lesions occur without clinical symptoms or signs other than radiological changes.

Data on aseptic necrosis of bone resulting from compressed-air work in the U.K. have been sought mainly through the study of tunnel-construction operations, in several of which large numbers of miners have been employed. For example, during the contracts at the Dartford (1957–1959), Clyde (1958–1963), and Blackpool (1960–1964) tunnels, over 1000 men worked for some time in compressed air (McCallum, 1968).

The first British radiographic survey of the joints of men during the course of their employment in compressed air, at the Dartford Tunnel, was a rather limited one (Golding *et al.*, 1960). At this contract the primary interest of the DSP was to evaluate what was at that time a new decompression table (Work in Compressed Air Special Regulations, 1958), a table that is in fact still the official one in Great Britain. Symptomless bone necrosis was found in 10 out of 83 men with a long history of exposure to compressed air, all of whom had suffered from bends at one time or another; and in 3 out of 20 men who had never sought treatment for decompression sickness. It was thus established that a history of bends severe enough to demand treatment is not necessarily associated with bone necrosis.

It became clear that for practical purposes radiography of the bones of compressed-air workers should be concentrated on the areas around the shoulder, hip, and knee joints. These sites, particularly the hips and shoulders, are the clinically important ones. Radiation exposure in routine examinations had to be limited; and the time involved in these examinations, which were and are still voluntary in the U.K., further restricted the number of radiographs taken.

It also seemed desirable in a study of men employed at a particular contract to distinguish between those who had previously worked in compressed air and those who had not, so that the circumstances in which bone lesions had occurred might possibly be defined more clearly. These considerations were applied in a study of men employed in compressed air during the construction of two tunnels under the River Clyde in Glasgow (Decompression Sickness Panel, 1966). Work on these tunnels was spread over five years, during which time 1362 men were so employed. In this survey 47 (19%) of the 241 men radiographed were found to have one or more bone lesions. Subsequently 11 other men not included in the original survey were found to have bone lesions. Out of 58 men known to have developed bone necrosis during this contract, 12 have become seriously disabled by lesions in the femoral or humeral heads.

Some of the serious problems associated with the epidemiological study of bone necrosis were revealed by this investigation. The survey was conducted toward the end of the compressed-air work, so that it was not possible to examine radiographically more than 18% of all those at risk. Furthermore, there were two or three major tunnel projects in the U.K. that overlapped one another in time. Marginal differences in pay rates among these contracts led to rapid movement of men from one contract to another. At times an entire shift of men might disappear from one site, shortly to reappear at another.

On the basis of our experience with the River Clyde and Dartford tunnel workers, a classification of the radiological abnormalities of bone necrosis was drawn up (Decompression Sickness Panel, 1966) that has since proved useful in practice.

Preceding page blank

Further observations were made on men employed in constructing a large road tunnel under the River Tyne near Newcastle between 1963 and 1966 (Decompression Sickness Panel, 1971). Although 641 men worked in compressed air, it was possible to take radiographs of the joints of only 171 (27%). Of the 171 men, 124 were new to compressed-air work. Bone necrosis was found in 44 men altogether; and of the 15 (12%) new to work in compressed air who had developed bone necrosis, 4 are now disabled.

One of the difficulties in making accurate estimates of the prevalence of bone necrosis is that it may not be detected in men who have worked at a particular contract until months or even years after the contract has ended. Unless the initial examination and follow-up rates are very good, the true prevalence of bone lesions is likely to be underestimated.

The most recent contract studied by the Decompression Sickness Panel is one concerned with cooling-water tunnels for a nuclear power station on the seacoast at Dungeness in southeast England. This is the first major contract in which newly calculated decompression tables (Blackpool Trial Decompression Tables, 1966), prepared for and sponsored by the DSP, have been used. At present we of the DSP are examining data from the Dungeness contract for comparison with the Tyne tunnel data. So far, we have found four or five cases of bone necrosis in men whose exposure to compressed air has been only at the Dungeness contract, but none of them has a disabling or potentially disabling lesion.

Bone lesions found in a group of compressed-air workers were distributed rather unevenly in different anatomical sites. In a series of 629 lesions in 281 men (Table I), about 40% were in the lower end of the femur (Walder, 1969), where they are typically symptomless and nondisabling; and 16% were in the femoral head, where they are potentially the most disabling. The longer men continue in compressed-air work the more likely they are to have bone lesions (Table II).

Table I. Distribution of Bone Lesions in 281 Compressed-Air Workers*

	Number of lesions	% total lesions
Humeral head	182	29
Femoral head	101	16
Lower end of femur	252	40
Upper end of tibia	94	15
Totals	629	100

*Walder, 1969

Table II. Percentage of Compressed-Air Workers with Bone Lesions When Radiographed 1 to 5 Years (or more) after First Exposure to Pressure*

Years after first exposure	% with bone lesions
1	6
2	20
3	39
4	44
5	40
>5	66

*Walder, 1969

Our general experience in tunnel contracts is that about half the seasoned compressed-air workers of some years' experience have radiographic evidence of symptomless bone lesions.

In attempting to determine the cause of bone necrosis, one must try to take into account a number of variables — *e.g.*, maximum pressure experienced, shift length, overall period of exposure, acclimatization factors arising from experience, a rise in working pressure, or breaks in pressure due to holidays, strikes, etc. The overall exposure period (total number of shifts worked) and maximum pressure experienced are difficult to separate. We have tried to compare men with bone lesions and those without, according to maximum pressure experienced and number of shifts worked (number of compressions–decompressions) (Fig. 1). Unfortunately, most men have worked at pressures greater than 18 or 25 psig, so that the picture is at present incomplete. As more data are collected, it is hoped to add the missing information.

One striking feature of compressed-air work is the gross difference between decompression procedures in different parts of the world or even within the same country (Table III). These

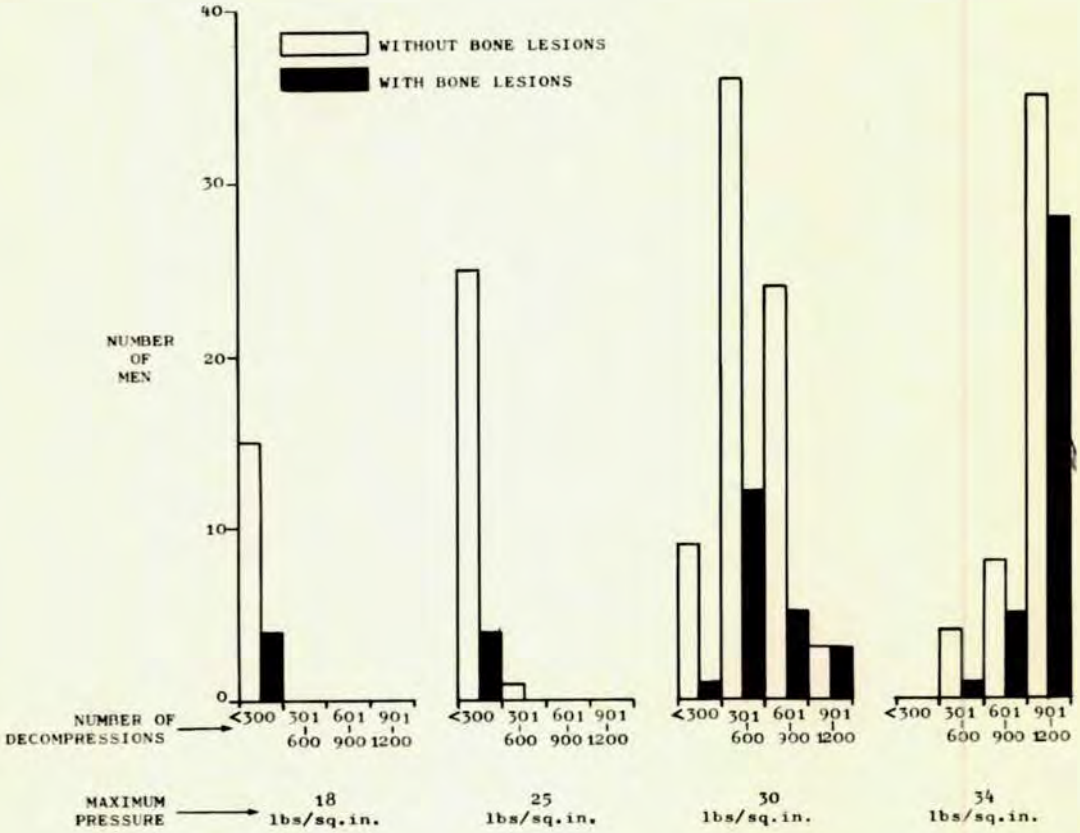

FIG. 1. Comparison of men with and without bone lesions according to maximum pressure experienced at a tunnel contract and number of shifts worked.

Table III. COMPARISON OF U.S. AND U.K. DECOMPRESSION PROCEDURES USED IN CIVIL ENGINEERING

	Pressure (psig)	Shift length (hr)	Total decompression time (min)
Great Britain			
1958 Regulations	24	5	37
Blackpool Trial Tables	24	5	94
United States of America			
Washington, D.C., Tables, 1966	24	5	117
Seattle, Washington, Tables	25	6	125

differences underline the need for reliable indices by which the success or inadequacies of decompression tables can be judged. As part of our response to this situation we have established, with Medical Research Council help, a Registry in Newcastle upon Tyne. This Registry contains information on the health and compressed-air experience of almost 10,000 workers, including some 1700 bone radiographs. The Registry will be described in more detail later. More information is still required on the very large number of men who have at some time or other worked in compressed air and on whom we have no data. It appears that the more one looks for bone lesions the more one finds. We hope to go on looking.

REFERENCES

Decompression Sickness Panel, Medical Research Council. (1966). Bone lesions in compressed-air workers, with special reference to men who worked on the Clyde Tunnels, 1958-1963. J. Bone Joint Surg. 48-B, 207-235.

Decompression Sickness Panel, Medical Research Council. (1971). Decompression sickness and aseptic necrosis of bone. Brit. J. Ind. Med. 28, 1-21.

Golding, F. C., Griffiths, P., Hempleman, H. V., Paton, W. D. M., and Walder, D. N. (1960). Decompression sickness during the construction of the Dartford Tunnel. Brit. J. Ind. Med. 17, 167-180.

McCallum, R. I. (1968). Decompression sickness: A review. Brit. J. Ind. Med. 25, 4-21.

Walder, D. N. (1969). Work in compressed air, including diving. Institution of Civil Engineers' Safety on Construction Sites Conference, 1969. Paper 6. pp. 49-55.

INCIDENCE OF OSTEONECROSIS IN ROYAL NAVAL DIVERS

DAVID H. ELLIOTT

Bone necrosis in a diver was first reported by Grutzmacher in 1941. That report was similar to the first reports of bone necrosis in the compressed-air industry because it was concerned primarily with a complaint of pain in a joint. It was not until 1952 that surveys were conducted to determine the extent of the problem in the diving population.

Table I (Elliott and Harrison, 1970) summarizes the incidence of osteonecrosis according to the literature available in 1969. Although differences in diagnostic standards and sampling methods invalidate true comparisons of the several investigations, the ratio of shoulder to femoral-head lesions of about 3:1 is consistent, and is an inversion of the ratio found in alcoholics.

The osteonecrosis survey of divers in the Royal Navy has been reported elsewhere (Elliott and Harrison, 1970; Elliott, 1971; Harrison, 1971). Within a total sample of 383 men, there was an 8% incidence in the 149 men aged 30 or over. No positive cases were diagnosed in men under the age of 30.

In the study by Ohta (personal communication; Ohta and Shigeto, 1969) a 15% incidence was found in the group aged 16 to 19 years, and a 76% incidence among those over 40 years of age. These findings do not necessarily mean that bone necrosis is age-related, for it may be a function of decompression or diving experience.

In the group of British naval divers aged 30 or over for whom there was an adequate diving history, it was possible to find some interesting associations. Of the 97 men in this age group who had never had any therapeutic recompression, there were 4 cases of osteonecrosis. But among the 44 men who had at some time been recompressed, there were 9 cases — a statistically significant difference.

Etiological factors cannot be subdivided because the men who had dived on oxygen–helium were also the ones who had suffered decompres-

Table I. EARLIER OSTEONECROSIS SURVEYS OF DIVERS*

	Divers examined	Divers with lesions	% incidence	Number of divers with lesions		
				Humeral head	Femoral head	Elsewhere, *e.g.*, tibia
Herget (1948*a*, *b*)	47	13	36	13	1	—
(1952)	90 (including 1948 results)	29	32	—	—	—
Slørdahl (1953)	13	3	23	3	1	—
Alnor (1963)	65 (for 10 years)	43	—	39	12	>1
	131 (total)	72	55	—	—	—
Kiryakov (1964)	29	19	65	12	7	—
Ohta (1969)	301	152	50	92	58	81
Totals	564	275	49	—	—	—

*From Elliott and Harrison, 1970

sion sickness. Among the 57 divers over the age of 30 who had adhered to the Royal Navy decompression tables, there was only one case of osteonecrosis. In contrast, there were 12 cases among the 84 men who had undertaken experimental diving. In other subcategories, the highest incidence, 28%, was among those who had suffered decompression sickness from oxygen–helium diving. Further figures are given elsewhere (Elliott, 1971).

A control group of subjects was also examined (Harrison, 1971). Among nearly 100 men with a similar naval background but with no exposure to hyperbaric or hypobaric environments, there was a zero incidence of osteonecrosis.

REFERENCES

Alnor, P. C. (1963). Chronic changes in the bone structure of divers. Bruns' Beitr. Klin. Chir. 207, 475-485.

Elliott, D. H. (1971). Decompression inadequacy in aseptic bone necrosis of divers. Proc. Roy. Soc. Med. 64, 1278-1280.

Elliott, D. H., and Harrison, J. A. B. (1970). Bone necrosis — An occupational hazard of diving. J. Roy. Naval Med. Serv. 56, 140-161.

Grutzmacher, K. T. (1941). Changes of the shoulder as a result of compressed-air sickness. Roentgenpraxis 13, 216-218.

Harrison, J. A. B. (1971). Aseptic bone necrosis in naval clearance divers: Radiographic findings. Proc. Roy. Soc. Med. 64, 1276-1278.

Herget, R. (1948*a*). Changes in the joints of divers. Klin. Wochenschr. 26, 288.

Herget, R. (1948*b*). Recent observations of barotraumatic chronic joint complaints in divers. Arch. Klin. Chir. 261, 330-360.

Herget, R. (1952). Primary infarcts of the long hollow bones, through local disturbances to the circulation. Zentr. Chir. 77 (32), 1372-1375.

Kiryakov, K. (1964). Chronic occupational diseases in divers. Higiena 7 (1), 75-79.

Ohta, Y., and Shigeto, O. [1969]. Working conditions of professional divers at the Arjake Bay. Unpublished data.

Slørdahl, J. (1953). Aseptic necrosis of bone in caisson disease. Tidsskr. Norske Laegeforen. 73, 300-304.

DISCUSSION 1

Dr. PECK: The experience that we have had in the U.S. Navy is not nearly as well laced with history as is the Royal Navy's. A series of random X-rays was gathered, covering a period of about three years. They were not taken specifically to uncover osteonecrosis. They encompassed most of the SeaLab divers, the Tektite divers, and other Navy air and helium divers. Among approximately 218 cases reviewed by the Armed Forces Institute of Pathology, only four are definitely positive for aseptic necrosis.

SAMPLE SURVEY OF OSTEONECROSIS IN GULF OF MEXICO COMMERCIAL DIVERS

CHARLES J. FAGAN
EDWARD L. BECKMAN
with JOHN B. GALLETTI, JR.

This report concerns the results of a roentgenographic bone survey for osteonecrosis recently conducted among a small group of commercial hard-hat Gulf Coast (of Mexico) divers.

METHOD

All divers in the survey were referred to the Department of Radiology, University of Texas Medical Branch, Galveston. Thirty commercial divers, ranging in age between 24 and 53 years, were surveyed during a six-month period. The following roentgenograms were made of all the subjects: *1*) anteroposterior (A-P) projections of each shoulder on 10 x 12 films with the patient rotated 45° to the table, permitting the shoulder to be in contact with the table top; 2) A-P 10x12 projections of each hip; and *3*) A-P and lateral projections of each knee, including the distal two-thirds of the thigh and the proximal one-third of the legs on separate 7 x 17 films. A Bucky grid was used in the exposure of all films (Elliott and Harrison, 1970).

ROENTGENOGRAPHIC FINDINGS

The classification and terminology formulated by the British Medical Research Council's Decompression Sickness Panel (1970) were used as diagnostic parameters:

Juxta-articular Lesions

A1 Dense areas, with intact articular cortex
A2 Spherical segmental opacities
A3 Linear opacity
A4 Structural failure
  a. Translucent subcortical band
  b. Collapse of articular cortex
  c. Sequestration of cortex
A5 Secondary degenerative arthritis

Medullary Lesions of the Head, Neck, and Shaft

B1 Dense areas (*not* bone islands)
B2 Irregular calcified areas
B3 Translucent areas and cysts
B4 Cortical thickening

In an attempt to be completely objective about the reading of the films, the surveys were interpreted without the benefit of any medical history — specifically, the individual diver's work experience and whether there were current or previous symptoms of bone necrosis were not known. It was anticipated that osteonecrosis in divers would present the same clinical findings seen in a non-diving patient population afflicted with osteonecrosis incident to other systemic illnesses (Edeiken *et al.*, 1967; Jaffe, 1969). It soon became obvious that this assumption was not always justified, that the lesions of osteonecrosis in divers are often quite subtle and not readily apparent. For when the survey material was reviewed again, lesions of osteonecrosis overlooked in the initial reading were discovered. Of the 30 divers surveyed, 8 had objective evidence of osteonecrosis. There was a total of 31 lesions — 22 (71%) in the shoulders, 6 (19%) in the knees, and only 3 (10%) in the hips. Twelve (40%) of the 31 areas of osteonecrosis were located in the significant juxta-articular regions of the involved bone. See Fig. 1 for a summary of these findings, in which the numbers in parentheses refer to medullary lesions.

The results of this survey are compared in Table I with those of other osteonecrosis surveys. Of note is the percentage yield in the present study: It is roughly the same as that in the majority of similar studies conducted in the past.

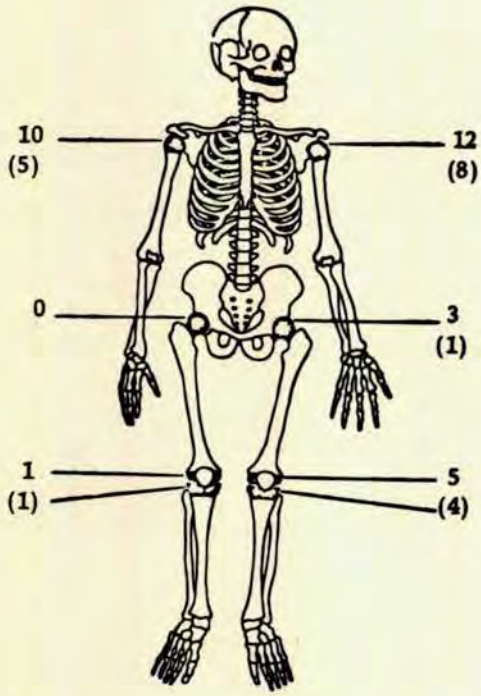

FIG. 1. Distribution of 31 bone lesions in sample survey of Gulf of Mexico divers. Of 30 divers surveyed, 8 had positive diagnoses of osteonecrosis. Numbers in parentheses refer to medullary lesions.

Table I. INCIDENCE OF BONE LESIONS IN SEVERAL SURVEYS OF DIVERS*

Surveys	Divers	Divers with lesions	% incidence
Herget	47	13	34
Herget	90	29	32
Slørdahl	13	3	23
Alnor	131	72	55
Ohta	301	152	50
Royal Navy	250	13	6
Gulf Divers	30	8	27

*After Elliott and Harrison, 1970 and 1971

In the interest of conserving space, only certain of the lesions disclosed in the present survey are illustrated (see Fig. 2 and 3). They have been selected as examples of subtle, moderate, and gross osteonecrotic involvement.

A CASE HISTORY FROM THE MBI SURVEY

The progression of osteonecrosis over a period of 14 years in one diver evaluated in this study is shown in Fig. 4 through 6, in the following section.

Personal Account of a Diver with Osteonecrosis

The following account of the diving and medical history of John B. Galletti illustrates the progression of dysbarism-related osteonecrosis. Written in the first person, the account refers to Case #3 (Fig. 4–6).

I have been diving approximately 30 years and have been active in the commercial field for about 22 years. I first became interested in diving in about 1941 and did some shallow-water diving, down to 10 or 12 ft, before entering the Seabees, a branch of the U.S. Navy. In the Seabees I dove on a volunteer basis, using conventional or converted gas masks and whatever other diving gear was available. I worked at depths ranging usually from 20 to 50 ft. We were always under the supervision of a U.S. Navy diver, First Class, and used air decompression tables.

After my discharge in 1946, I did various types of construction work until 1949, when I decided to go to diving school and make a career for myself as a commercial diver. After completing a course in California, I worked in diving for two years on the West Coast. The jobs were usually at depths of 225 to 250 ft, on air. My deepest dive at that time was to 285 ft, also on air.

In 1951 I returned to Galveston and started my own business, serving the Gulf Coast and any other area where diving was needed. Most of my work was salvage and repair in shallow water, down to approximately 40 ft. During this time I assisted in setting up one of the first offshore drilling platforms in the Gulf, in 60 ft of water. During the next seven years, the diving industry began to expand and my business continued to grow. We were diving occasionally to depths as great as 150 ft, always on air. As more offshore drilling rigs were installed and the work became more complex, the need for divers grew. By 1958, when J & J Marine Diving Company was formed, we were diving to depths of 170 to 225 ft.

In 1959, I had a bends "hit" in the shoulder. Decompression chambers were relatively unknown at that time. We worked constantly at great depths without chambers; all our decompression was done in the water. I had to sweat that one out. In 1960 we acquired our first chamber, which was available when I had an attack of bends in my left knee. It was treated according to Table No. 1 of the U.S. Navy diving tables — apparently successfully. The pain was relieved at less than 60 ft.

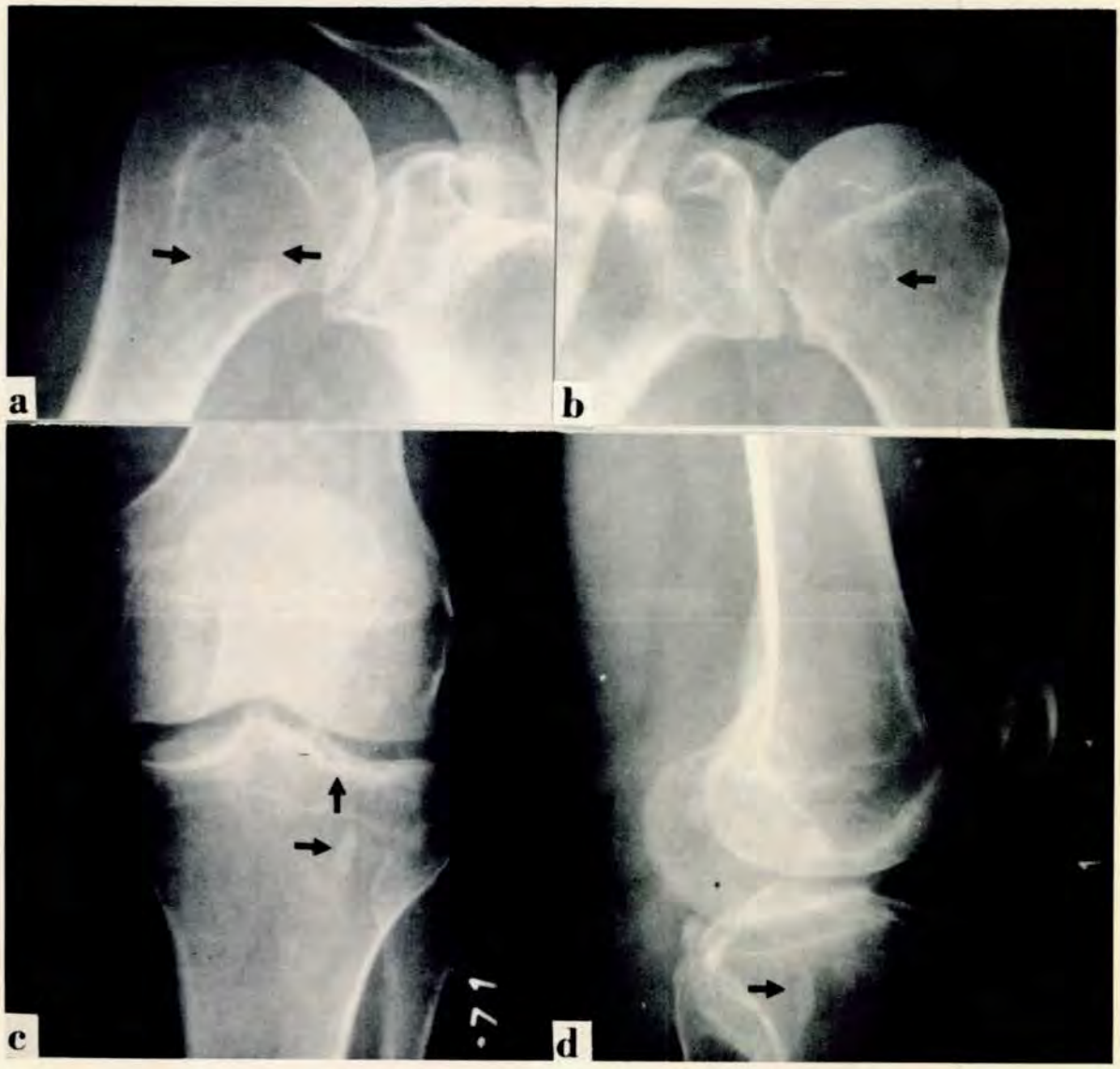

FIG. 2. Case #1, R.N., aged 50; 20 years' diving experience. (*a*) and (*b*) Very subtle rarefactions with surrounding sclerosis in the humeri (arrows), examples of B3 medullary-shaft lesions of osteonecrosis. (*c*) and (*d*) Dense spherical area (horizontal arrows) in proximal shaft of L tibia. Because of findings in shoulders, this lesion is believed to be area of osteonecrosis rather than bone island. It represents B1 medullary-shaft lesion (Kim and Barry, 1964). Old traumatic changes are marked by vertical arrow.

In March of 1961, when I was driving from Corpus Christi to Pasadena, Texas, I suddenly became aware of a problem in my left hip. When I tried to apply my left foot to the clutch pedal, I realized that I could not raise my leg. In fact, I had to raise my leg with my hand, place it on the pedal, and then bear down with my hand on my knee. There was no pain in my hip joint, only in my ankle and knee. The pain gradually subsided, but returned later and continued to bother me occasionally. It had become severe enough by May that I decided to consult a doctor.

I saw four bone specialists, all of whom agreed that there was damage to the socket in the hip

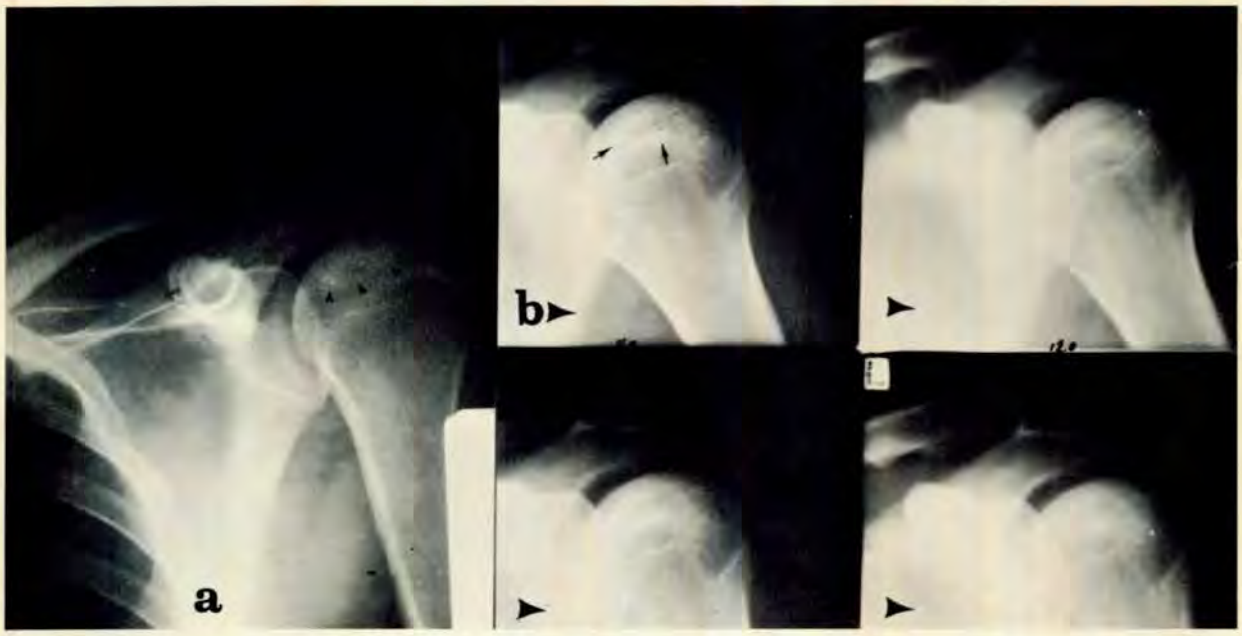

FIG. 3. Case #2, R.L., aged 32; 8 years' diving experience. (*a*) Subtle to moderate areas of osteonecrosis manifested by sclerosis of humeral head with intact cortex. (*b*) Serial tomograms clearly define juxta-articular snowcap lesions, or A1 area of osteonecrosis. This case illustrates value of tomograms in defining extent and magnitude of osteonecrotic involvement.

joint. But each had a different solution to the problem. The first doctor suggested replacing the ball-and-socket joint with a steel ball in the socket. The second doctor suggested that I stay off my leg for a year and walk with crutches in hopes of healing it. The third doctor suggested that the joint be fused.

The fourth doctor told me that the damage was due to a cyst on the socket and suggested removal of the cyst and a bone graft. This last diagnosis and solution seemed the most logical, and I was operated on in August 1961 by an orthopedic surgeon, Dr. Ainsworth, at John Sealy Hospital in Galveston. After a period of six months I returned to diving, starting at depths of 25 to 30 ft. I continued diving on a full-time basis to depths as great as 230 ft until about five years ago, when company responsibilities made it imperative for me to discontinue diving.

The pain that I experienced before my operation was always in the ankle and knee, and still is. Cold damp weather makes them hurt a bit worse, causing me to limp from time to time.

I can only guess at the total number of dives that I have made. They were all made on air, and U.S. Navy decompression procedures were always followed. Yet I developed bone necrosis. I was unaware of the problem of bone necrosis until August 1971, when a doctor from the Marine Biomedical Institute suggested that I have X-rays made of the hip. The X-rays were taken at the University of Texas Medical Branch and were compared with those taken before surgery in 1961. It was confirmed by the doctor that I do have bone necrosis. I did not know that before; as far as I had known previously, I just had cysts.

We at J & J are now aware of the problem of bone necrosis and realize how little is known about the disease. We are cooperating with the MBI and the University of Texas Medical Branch by having all of our divers X-rayed and their diving histories studied so that they might be compared with other divers' experiences. We hope that in this way we can be of some help to the diving industry in preventing future development of bone necrosis.

SUMMARY

Dysbaric osteonecrosis of bone is not an uncommon disease among Gulf Coast divers. A sam-

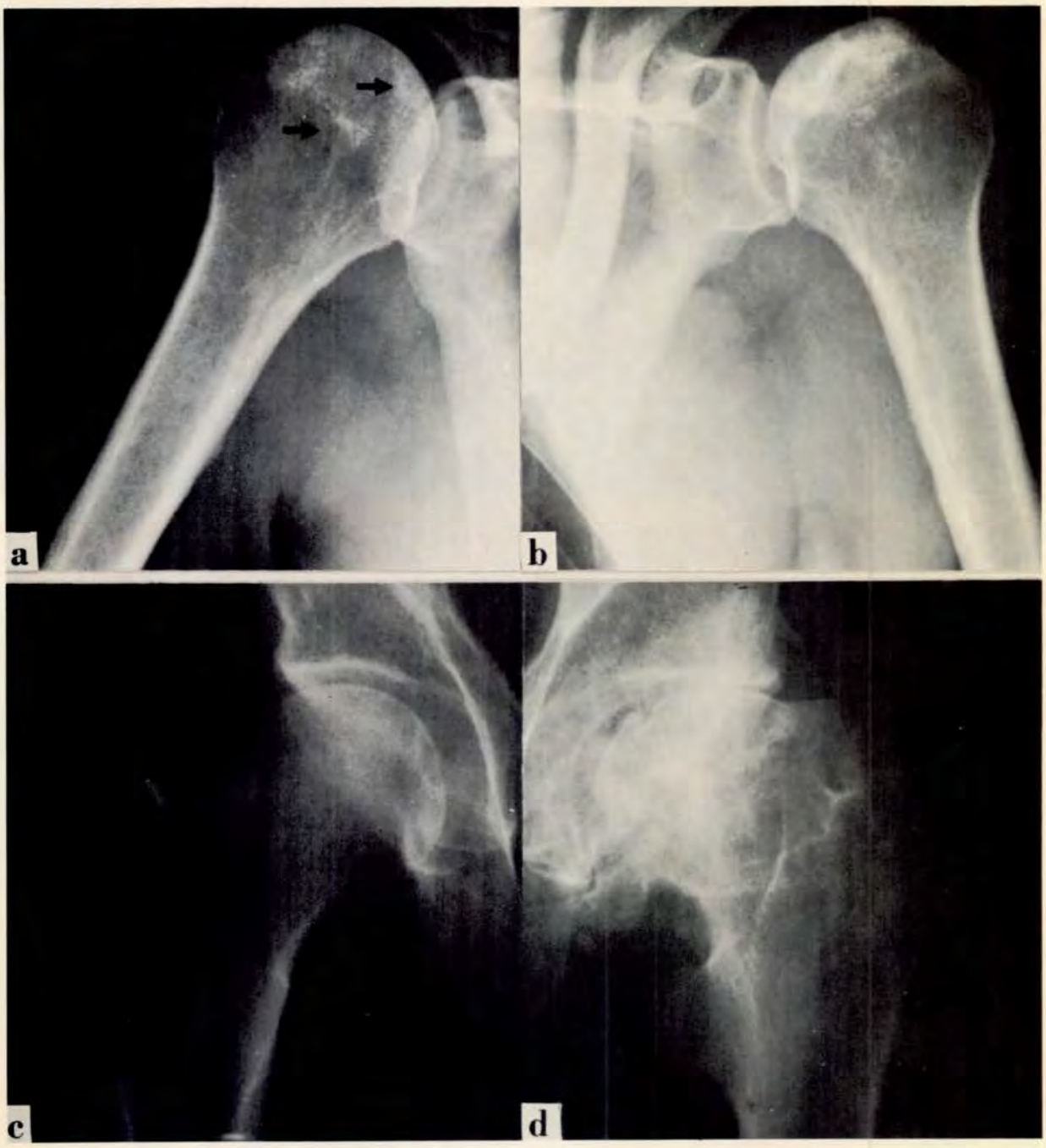

FIG. 4. Case #3, J.B.G., aged 47; 22 years' commercial diving experience. (*a*) Juxta-articular lesions manifested by dense areas as well as spherical segmental opacities (arrows). There is, in addition, dense area in humeral shaft. (*b*) Marked juxta-articular changes (A4 lesion) in contralateral shoulder, including collapse of articular cortex. (*c*) Normal R hip. (*d*) By contrast, extensive involvement in L hip, with extensive structural failure (A4 lesion) and complicating osteoarthritis (A5 lesion).

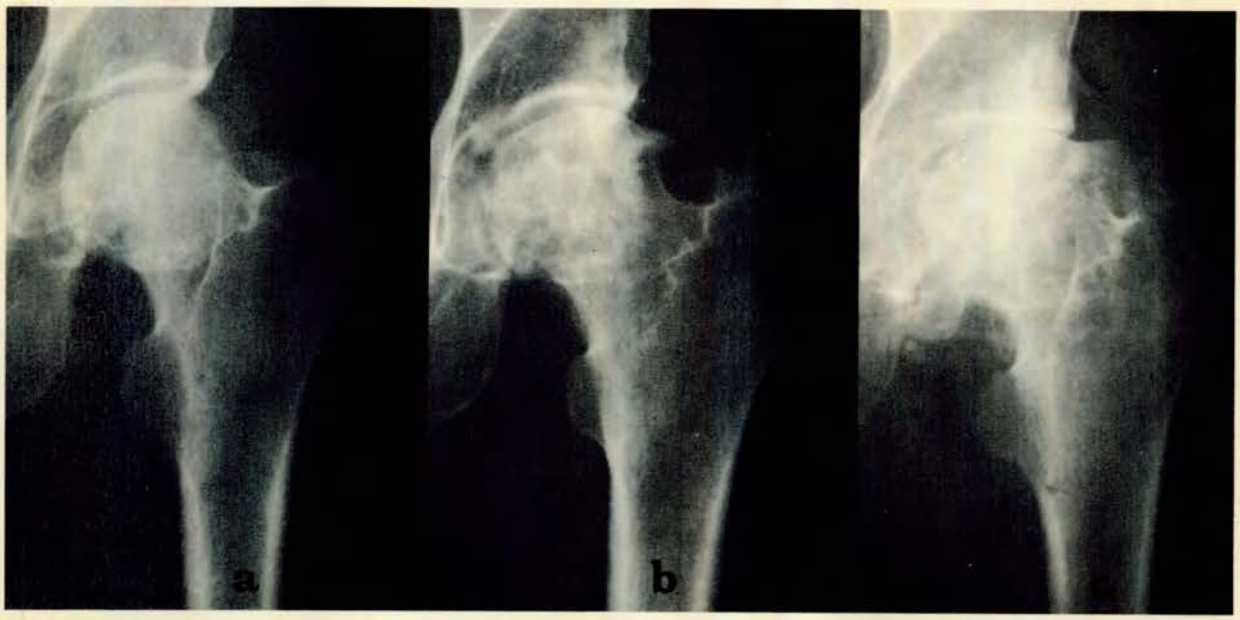

FIG. 5. Sequence of films demonstrates progression of changes in L hip of Case #3. (*a*) 1961; (*b*) 1963; and (*c*) 1972.

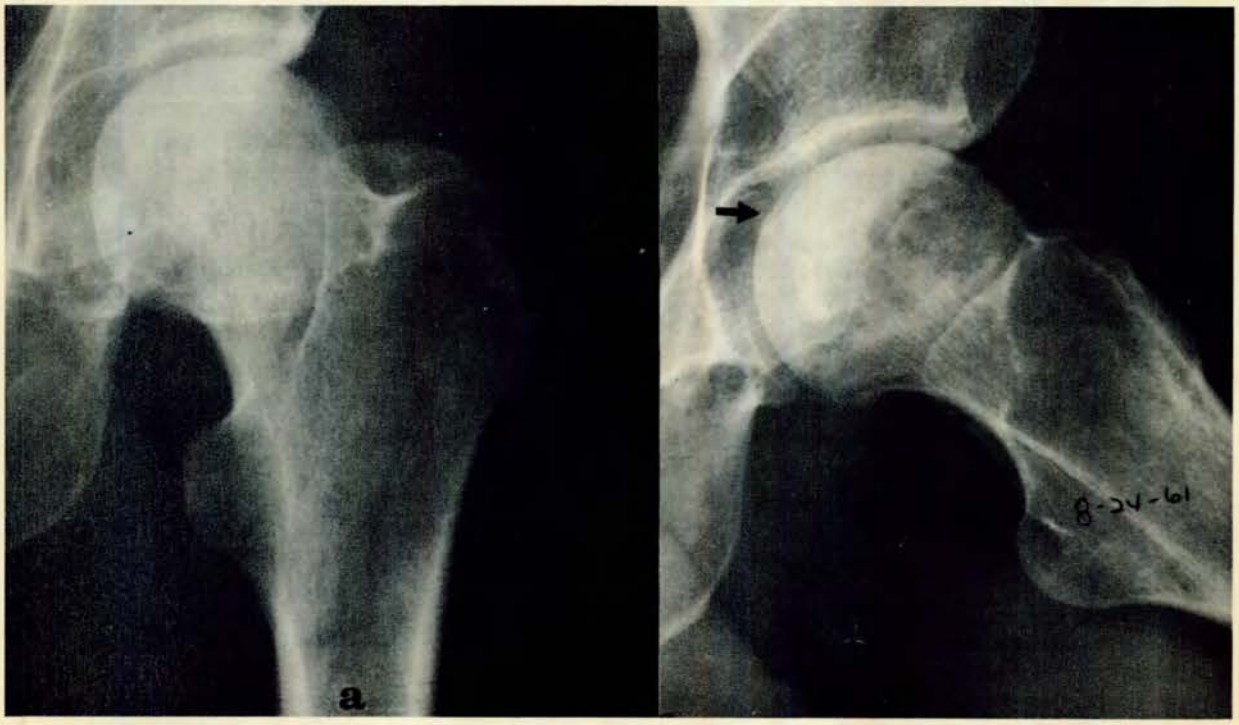

FIG. 6. (*a*) A-P (frontal) film compared with (*b*) frogleg projection in Case #3. Fracture, manifested by subcortical translucent band, is evident only on frogleg projection, demonstrating the latter's value in revealing changes in articular surface (Martel and Sitterley, 1969).

ple survey of a small number of commercial divers yielded a high incidence (27%) of this disorder. A number of the lesions were significant in that they were located in the juxta-articular regions of the involved bones. The shoulders were the most common site of involvement. In many cases the lesions were very subtle. Tomography is a useful modality to better define the actual area of involvement.

REFERENCES

Edeiken, J., Hodes, P. J., Libshitz, H. I., and Weller, M. H. (1967). Bone ischemia. Radiol. Clin. N. Amer. 5 (3), 515-529.

Elliott, D. H., and Harrison, J. A. B. (1970). Bone necrosis — An occupational hazard of diving. J. Roy. Naval Med. Serv. 56, 140-161.

Elliott, D. H., and Harrison, J. A. B. (1971). Aseptic bone necrosis in Royal Navy divers. In Underwater Physiology. pp. 251-262. New York: Academic Press.

Jaffe, H. L. (1969). Ischemic necrosis of bone. Med. Radiogr. Phot. 45 (3), 58-86.

Kim, S. K., and Barry, W. F., Jr. (1964). Bone island. Amer. J. Roentgenol., Radium Therapy Nucl. Med. 92, 1301-1306.

Martel, W., and Sitterley, B. H. (1969). Roentgenologic manifestations of osteonecrosis. Amer. J. Roentgenol., Radium Therapy Nucl. Med. 106 (3), 509-522.

Medical Research Council Decompression Sickness Panel. (1971). Decompression sickness and aseptic necrosis of bone. Brit. J. Ind. Med. 28, 1-21.

U.S. AIR FORCE EXPERIENCE IN HYPOBARIC OSTEONECROSIS

THOMAS H. ALLEN
JEFFERSON C. DAVIS
CORRIN J. HODGSON

Hypobaric osteonecrosis has indeed occurred following military flight. Hodgson *et al.* (1968) presented this history from the files of Wilford Hall USAF Hospital:

> A 45-year-old B-29 crew member in combat was subjected to two episodes of rapid decompression to 35,000 and 45,000 foot altitudes within one week in 1953. On both occasions the aircraft was required to remain at altitude for an hour or more. He experienced pain . . . in several joints . . . and his symptoms required several days to resolve each time. After the second episode, he never was fully free of discomfort in the left hip joint. . . . In 1962, he was medically retired with a diagnosis of "aseptic necrosis of the left hip due to caisson [*sic*] disease. . . ."

By 1965, this man's hip required surgical repair, and the femoral head was replaced with a prosthesis. See Hodgson *et al.* (1968), Fig. 4.

From RAF experience the following case history was recorded by D. I. Fryer (1969): In about 1955, after 20 years of unpressurized aircraft flying, a 43-year-old photo-survey pilot suddenly suffered joint pains at 27,000 feet for a period of 6 hours. After he landed, he was confined to bed for 4 days suffering from severe pain in all his extremities. Between 1963 and 1967 he experienced 2 similar episodes, and on 6 other flights he had moderately severe shoulder and elbow bends. In May 1967 he experienced a sharp pain in his left shoulder associated with a "thunk" sound. Radiographs showed an impending "separation of a fragment from the head of the humerus." Six weeks later a jarring within this joint was distinctly heard and felt. The fragment had indeed separated.

Aside from J. H. Allan's (1945) claim of "calcific deposits and aseptic necrosis as predisposing factors in bends pain," these two cases apparently are the only specific accounts of disabling hypobaric osteonecrosis in the literature. They can be compared with 18 subatmospheric decompression sickness (DCS) fatalities (Fryer, 1969) in the USAF, RAF, RCAF, and USN from 1943 to 1958 (none since) and with 46 severe DCS cases successfully treated by compression, chiefly to 2.8 atm, between 1941 and the present time (as compiled by author J.C.D.). In both above-referenced cases, note that joint pain had persisted after landing, that there had been several such episodes, and that bone damage was found several years later.

Three reports (Ratnoff, 1943; Berry and Hekhuis, 1960; Hodgson *et al.*, 1968) exist dealing with roentgenography of bones and joints in men who in their regular duties were often exposed to simulated altitudes. The earliest (Ratnoff, 1943) concerned 21 military men who had undergone repeated exposures of 4 to 2 hours, or less, to altitudes of 35,000 and 40,000 feet. X-ray films of both hip joints were examined. "In none of the subjects were the roentgenographic changes described in caisson workers noted. Lesions of doubtful significance were present in two subjects, neither of whom had a history of bends."

In 1958, 623 USAF altitude-chamber men were X-rayed; the results on 579 of them were described by Berry and Hekhuis in 1960. Of this number, anterior-posterior views of the humeri, radii, ulnae, femorae, tibiae, and fibulae revealed not a single lesion that might be attributable to pressure changes. In the interim between 1958 and a follow-up study conducted in 1966 (Hodgson *et al.*, 1968), the X-rays of the additional 44 men were examined. An immature lesion was found in the midshaft of one right femur (see Fig. 2 of that study).

In their 1966 follow-up study, Hodgson *et al.* (1968) were unable to obtain X-rays on 459 of the entire sample. Although 291 of the original 623 men were still enlisted in the Air Force in December 1965 and 279 were in locations at which they could be reached, only 164 responded to the request for X-rays. In this second survey, it was found that the immature lesion mentioned

Preceding page blank

above had become "a mature intramedullary infarct" (see Fig. 1 of that study). It was 4 cm long and filled the entire thickness of the medulla. This man had a history of 6 attacks of bends.

In the 1966 study, as well, an additional case of aseptic bone necrosis was found in a man who had a history of 5 episodes of bends (see Hodgson *et al.*, Fig. 3). The lesion, 1 cm in diameter, was a round radiolucent area in the neck of the left humerus, just distal to the epiphysis. The lesion was "surrounded by a rim of increased bone density, and contained a few flecks of calcification. The 1958 X-rays are cut off just below the area of this lesion, so its onset cannot be documented."

Only 44 of the 164 respondents in the 1966 study had no history of DCS. Hence the *apparent* incidence of bony lesions may have been 2/120 among the altitude-chamber men who had suffered various mild forms of DCS, chiefly bends. To recapitulate, from 1958 to 1966 a lesion in one man had progressed to a mature medullary infarct of the femur. A lesion in a second man may or may not have been present earlier, but it was distinctly affecting the neck of the left humerus in 1966.

Even given the obvious deficiencies of the cited studies, it is possible to guess at the overall incidence of hypobaric osteonecrosis among men abruptly exposed to simulated high altitudes. From 1943 to 1966 the number was perhaps $(2+2)/(21+164)$, or 2.2% at the most. More likely the number could be as low as $(0+2)/(21+623)$, or 0.31%. Only the 2 fliers whose histories were given above have been disabled by hypobaric osteonecrosis; both of them had often suffered persistent postflight pain. They were fortunately not among the 18 known fatalities of subatmospheric DCS. On the other hand, they were unfortunately not among the 46 who were successfully treated from 1941 to date for severe reaction to hypobaric exposure.

In sum, disabling hypobaric osteonecrosis had indeed occurred — twice, surely. Initial X-ray films of 623 altitude-chamber men showed low incidences of bony lesions; it is difficult for obvious reasons to check an entire sample of that size 8 years later. Beginning in 1966 many USAF altitude-chamber operators have also been exposed regularly to 3 and 6 atm and are decompressed in exact accordance with U.S. Navy tables used in treatment of DCS. The 1966 USAF study was therefore biased toward a "last chance" attempt to find osteonecrosis in these operators before they began working in diving chambers as well. Because of this bias, only 2 cases of comparatively evident lesions were uncovered. Three cases of bone islands were excluded, plus one of endosteal scalloping, which could have yielded 6 cases, all told, out of 164 respondents in the 1966 study, had we chosen to use more liberal interpretative criteria at the time.

Of more importance, none of the original 623 men apparently suffered from or reported "postflight" symptoms of severe DCS. It is therefore felt that only those who have been afflicted with severe postflight reactions should be studied now and in the future. In other words, after treatment of such reactions by means of oxygen breathing at 2.8 atm, those individuals should be clinically observed in subsequent years.

The sequelae of severe DCS affecting the bones could thus be contrasted to the total of 46 incidences following subatmospheric exposure, recorded between 1941 and January 1972, that were successfully treated. Finally, it should be clear that the currently accepted treatment of altitude DCS persisting at ground level may prevent development of hypobaric osteonecrosis.

REFERENCES

Allan, J. H. (1945). Traumatic calcifications: A precipitating factor in "bends" pain. J. Aviation Med. 16, 235-241.

Berry, C. A., and Hekhuis, G. L. (1960). X-ray survey for bone changes in low-pressure chamber operators. Aerospace Med. 31, 760-766.

Fryer, D. I. (1969). Subatmospheric decompression sickness in man. p. 278. Slough, England: Technivision Services.

Hodgson, C. J., Davis, J. C., Randolph, C. L., Jr., and Chambers, G. H. (1968). Seven-year follow-up X-ray survey for bone changes in low pressure chamber operators. Aerospace Med. 39, 417-421.

Ratnoff, O. D. (1943). The absence of roentgenographically demonstrable bony changes at the hip joint in subjects exposed to simulated high altitudes. Project 201, Report 1, USAAF School Aviation Medicine, Randolph Field, Texas.

DISCUSSION 2

Dr. ELLIOTT: Osteonecrosis is not just a question of X-ray changes. Some real problems are generated for the afflicted individual. I should like to cite a quotation from Alnor (1963), which may be of interest to Dr. Fairchild and his associates: "Of the 65 men kept under observation for more than 10 years in the German study, only 22 of them remained free of radiological evidence of lesions. Of the 43 with lesions, 17 had symptoms, and 7 were totally unable to work." So, for the men concerned, it is indeed a very real problem.

Dr. KINDWALL: I should like to ask Dr. Beckman what method of selection was used in picking the 27 divers of the Gulf of Mexico survey. Was it slanted toward men who indeed had symptoms? Was there anything other than pure random choice involved?

Dr. BECKMAN: There was no selection whatsoever.

Dr. HARRISON: I should like to congratulate Dr. Fagan on his survey and to reinforce one or two points that he made. He commented on how very subtle some of these early lesions are, and how very difficult it is to recognize them. He also stressed that the lesions are frequently multiple. His point is well taken, I think, that the frogleg position is rather an improvement over the British straight A-P X-ray of the hips.

Dr. Fagan also demonstrated something that has concerned many of us — *i.e.*, the association of these vague densities with what we now recognize as lesions. By "vague densities" I mean an area that one cannot with certainty identify as a bone island or accept as evidence of aseptic bone necrosis. Experience seems to indicate that these densities are certainly much more common in divers than in a comparable nondiving population.

Dr. Fagan also made the very relevant point that when one begins a roentgenographic survey and makes the initial readings, one does not want to know anything at all about the divers. The survey must begin as a blind reading. In later evaluations of the lesions, of course, some knowledge is helpful.

Dr. JONES: In our opinion there is a very definite association between metaphyseal lesions and irregular osteosclerotic lesions in epiphyseal regions. I think serial evaluation of the multiple features previously conceived of as "bone islands" may actually show that they are focal areas of necrosis.

Dr. WORKMAN: We have done 152 bone surveys on our own divers and on applicants seeking employment as divers; we have also done 10 planograms (tomograms) of these men. We made the routine films suggested by England's Medical Research Council.

Ten planograms were done of suspicious areas that we could not otherwise define. Ten of the 152 men studied had lesions of the head of the humerus. One was bilateral, with compaction of subchondral bone and disruption of cartilage. Three of these happened to be company divers and seven were diver applicants. Planograms were repeated on two subjects one year later; there was no perceptible change in the lesions in the mid-head of the humerus. As Dr. Fagan has shown, the lesions were radiolucent, sclerotic areas, with disruption or irregularity of the trabeculae. We found that planograms are extremely helpful in defining these things — much more so, I think, than the best cone spots we could get.

We refused 35 applicants for employment because of multiple bone lesions in which early stages of aseptic necrosis could not be excluded, or because of other hypertrophic joint changes that we felt were risky in active divers. Several of our older divers have been active for 10, 15, or perhaps 25 years; I am impressed that most have no lesions that we considered positive for osteonecrosis.

Dr. WALDER: We have done a survey of 230 professional civilian divers, men sent to us by an organization called the Construction Industry Research and Information Association. They were thus unselected by us. To date we have found 3 definite and 12 suspect positive lesions in the group.

Dr. ELLIOTT: That low incidence is very encouraging. I think we should remember that similar results have been reported in other surveys. One I would like to mention was reported by Graczyk (1970), who examined 67 Polish divers, all of whom had 10 or more years' diving experience. He found lesions in only 5 men, a 7% incidence. So there appear to be groups of divers in whom the incidence is less than that found in the majority of surveys. But the criteria of diagnosis in the Polish survey may not have been the same as those used by the Medical Research Council or the same as those used by the German authors.

REFERENCES

Alnor, P. C. (1963). Chronic changes in the bone structure of divers. Bruns' Beitr. Klin. Chir. 207, 475-485.

Graczyk, M. (1970). Radiological aspect of osteoarthropathy in Polish divers with long employment period. Bull. Institute Marine Med., Gdansk. 21, 7-13.

PART II

U.S. EXPERIENCE IN COMPRESSED-AIR WORK

SEATTLE TUNNEL FOLLOW-UP REPORT

J. LEON SEALEY

The Washington State Standards for Work in Compressed Air were developed in 1962-1963 with the help of the U.S. Navy, especially that of Albert R. Behnke, Jr., and Gerald J. Duffner. These standards are based upon a 120-minute half-saturation time for the slowest tissue compartment. The tables were first used in Seattle, in late 1964, in the construction of a major sewer tunnel known as the Lake City Sewer Tunnel.

The tunnel is 19,000 feet long and took approximately 150 weeks to construct at pressures ranging from 13 to 34 psig. The workers' exposures were as follows:

42 weeks at pressures between 13 and 18 psig;
92 weeks at 18 to 23 psig; and
15 weeks (10% of their work time) at pressures above 23 psig.

These groupings resulted in part from the simple fact that at pressures lower than 24 psig, the decompression protocol still permits 6 hours' working time. At higher pressures, union contractual agreements stipulated a shorter work shift or, alternatively, overtime pay. A group of 33 men worked 100 to 190 days at pressures of 18 psig, or greater, averaging:

10 days on an 8-hr shift;
85 days on a 6- to 7.75-hr shift; and
27 days on a 3.5- to 5.75-hr shift.

A group of 40 men worked 200 to 375 days at 18 psig, or greater, averaging:

14 days on an 8-hr shift;
214 days on shifts lasting 6 to 7.75 hr; and
54 days on shifts of 3.5 to 5.75 hr.

A group of 33 men worked 475 to 625 days at 18 psig, or greater, averaging:

9 days on an 8-hr shift;
487 days on a 6- to 7.75-hr shift; and
69 days on shifts lasting 3.5 to 5.75 hr.

Although a few men spent a full 8-hour shift at pressures of 24 to 32 psig, 90% of the shifts involving 23-psig exposures, or greater, lasted approximately 4 hours. At pressures of 13 to 23 psig, 95% of the shifts were 6 to 8 hours in length.

These data are summarized in Table I.

Recompression treatment for simple bends was used 212 times during the course of construction, about one-third on standard U.S. Navy air tables and two-thirds on low-pressure oxygen tables. There was no instance of dysbarism involving the central nervous system. To date there have been no claims of disability arising from these experiences.

Table I. LAKE CITY SEWER TUNNEL OF SEATTLE, WASHINGTON
Daily Work Shifts, Pressure Exposures, and Number of Days Worked
October 1964–May 1967*

Pressure (psig)	Total number days worked	Work profiles			Average totals	
		3.5- to 5.75-hr shifts	6- to 7.75-hr shifts	8-hr shift and longer	Days	Men
18 to 23	100 to 190	13.8 days	83 days	9.75 days	100	33
	200 to 375	27.4	210	13.00	250	40
	475 to 625	12.3	483	8.50	504	33
24 to 32	100 to 190	13.4 days	2.2 days	0.25 days	16	33
	200 to 375	26.3	3.9	0.50	31	40
	475 to 625	56.4	2.4	0.85	60	33

*Total construction time: 150 weeks

Preceding page blank

PRELIMINARY BART TUNNEL RESULTS

ALBERT R. BEHNKE, JR.
JOHN PAUL JONES, JR.

The Bay Area Rapid Transit System, known as BART, was the first significant compressed-air tunneling operation in California and the largest civil engineering project ever performed on the West Coast of the United States. The 75-mile network includes duo-rail surface tracks, elevated lines, and subways linking San Francisco to the East Bay counties across San Francisco Bay and beneath the Oakland–San Francisco Bay Bridge. Of 64,576 ft of soft-ground tunneling performed during this project, 22,600 ft were machine-shield-driven by men using compressed air under hazardous soil and obstacle conditions.

Preliminary follow-up studies indicate that dysbaric osteonecrosis can possibly be prevented by instituting sophisticated engineering principles designed to avoid use of compressed air altogether, or to minimize exposure to pressure. Also important in the prevention of this disease in projects such as BART are comprehensive medical supervision, including thorough preemployment examinations; the use of the Washington State decompression tables, as incorporated in the California code (Behnke, 1968); and oxygen decompression in a closed system (Behnke, 1967).

FIG. 1. Cable system used to lower tube sections from barge onto bottom of San Francisco Bay in course of Bay Area Rapid Transit construction. (Photograph courtesy of CIVIL ENGINEERING—ASCE, monthly publication of the American Society of Civil Engineers; September 1967.)

ENGINEERING PRACTICES IN THE BART PROJECT

The BART project was engineered to avoid completely the use of compressed-air workers during construction of the Trans-Bay Tube. Prefabricated 320-ft-long sealed binocularlike tube sections, weighing 10,000 tons each, were floated into position. After gravel ballast was added to overcome buoyancy, each tunnel section was lowered by four cable falls, suspended from a twin-hulled placing barge, into a previously dredged 3.6-mile-long trench extending across the bottom of San Francisco Bay (Fig. 1). Deep-sea divers, using conventional diving suits and hard helmets, worked at approximately 100- to 120-ft depth, where they directed placement and mechanical linkage of the tube sections. No instance of decompression sickness was reported in these divers.

Of 64,576 ft of soft-ground tunneling performed on the BART project, nearly half was hand mined. Of the entire 12 miles of subway tunneling, 9 miles were driven in free air and 3 miles (15,026 ft) under compressed air. However, only 135 ft were driven in compressed air in excess of 17 psig, over a period of 47 days.

Tunneling machines, a recent innovation, were used in the BART project for the other half of

Preceding page blank

the tunnel. A typical tunneling machine has a large cutting wheel (Fig. 2) that scrapes ground off the face and drops it onto a conveyor belt. Three radial doors on the face of the cutting wheel were opened by hydraulic rams. The cutting wheel was turned by planetary gears driven by hydraulic motors, which provided about 2 million ft-lb of torque (Fig. 3). Shove jacks, with the capacity of 115 tons each, were used to hold the cutter against the face during excavation. The forward progress, or shove, sufficient to install a liner ring in the tail of the shield, was 2.5 ft. Although manpower requirements were about equal for both machine-tunneling and hand-tunneling methods, those contractors using tunneling machines averaged advances of 40 ft per day as compared with 25 ft in the hand-mining projects.

About 5100 ft of twin subway tunnels north of the 16th Street Mission Station and an additional 3500 ft of twin tunnels south of the station were driven under compressed air. In both instances the original water level was above the crown of the tunnels.

To reduce the pressure of compressed air, dewatering procedures were introduced by drilling wells, 40 to 140 ft deep, into which submersible pumps were installed. Pumping began prior to tunnel excavation and the water table was lowered approximately 50 ft. It was often impossible to draw water down below the level of the tunnel invert, and air pressure was needed to counterbalance water pressure at the heading. These tunnels were constructed about 50 ft below the surface of the ground and air pressure varied from 9 psig to a maximum of 17 psig.

That portion of the project requiring work in compressed air at pressure great enough to cause dysbaric osteonecrosis involved construction of twin tunnels from the ventilation shaft to the

FIG. 2. Cutting wheel of soft-ground tunneling machine used in BART project.

FIG. 3. Rear view of tunneling machine's cutting wheel, used in BART project.

ventilation caisson through land reclaimed from beyond the shoreline as it existed in 1888. The tunnel is completely founded within new bay mud, which is very unstable material.

It was suspected that an old timber pier might be buried under the street surface, since it had been built as an extension of Market Street from First Street to the present location of the Ferry Building. In addition, the tunnel passes within a few feet of an old rubble seawall and through a forest of piling supporting the foundations of the Ferry Building. The final obstacle confronting this part of the project, and that which required use of progressively higher levels of compressed air, was the unstable backfill and clay blanket surrounding the caisson. Unfortunately, the lower end of Market Street was also the site of major destruction to buildings, which were constructed on unstable ground, during the 1906 San Francisco earthquake.

Timber-pile obstructions were handled by compressed-air workers with extreme caution since each pile was a potential "blow hole" whereby compressed-air pressure could suddenly be lost, with serious potential consequences for the workers. A total of 896 piles had to be disposed of, including one concrete and one steel pile. Locating the piling before each shield advance involved considerable delay. Of the 93 man-hours expended per foot of tunnel construction, 68 were required for excavation, ring erection, and grouting, and 5.2 for pile removal.

When horizontal tunnel excavation had progressed about 200 ft, a muck-lock and man-lock (Fig. 4) were installed adjacent to the working area. Compressed air supplied to the heading was cooled and filtered to prevent excessive fogging; burning and smoking inside the tunnels were prohibited.

The working day in compressed air was divided into four 6-hr shifts for each tunnel. An average heading crew consisted of 23 men with a support crew of 15. Those activities performed

FIG. 4. Photograph of man-lock of 7½-ft diameter. Lock systems were automatically controlled by computer, which the lock tender set for the required decompression time. Highest pressure at which tunnel was operated, 36 psig, required decompression of 3 hr and 28 min. Door through bulkhead into compressed-air tunnel remained open at all times to allow miners to enter lock rapidly in case of emergency.

during a typical soft-ground tunnel-driving cycle included shield advance, ring erection, grouting, and installation of hog rods. Pneumatic impact wrenches were ordinarily used to tighten the bolts between ring segments, pneumatic reciprocating pumps to inject grouting cement, and pneumatic chipping hammers to introduce lead strips into caulking grooves. Unfortunately, much of this work had to be performed overhead, resulting in significant stress to the workers' shoulder joints. Behind the shield was a platform where the soft-ground miners used a pneumatic hoist to lift the ring segments into position. The compressed-air workers were responsible for erecting the steel tunnel liners and for bolting the rings together. Through use of tunneling machines and other hydraulic equipment, however, the heavy overhead lifting usually required of these workers was minimized.

It was during the final phase of tunneling, when the pressure had to be increased, that the majority of severe cases of decompression sickness (Type II) developed. Maximum pressure in the left tunnel was 36 psig for 5 days and, in the right tunnel, 35 psig for 24 hours.

MEDICAL PRACTICES IN THE BART PROJECT

A Transit Compressed Air Medical Center in San Francisco serviced all BART operations conducted under compressed air. The Center performed all medical services required by the "Compressed Air Safety Orders" issued by the Division of Industrial Safety of the State of California. Every prospective workman in the compressed-air projects was required to be qualified by medical examination. After continuous hyperbaric work for one year, he was reexamined to reconfirm his qualification.

Each applicant completed a preemployment health-history form and underwent a comprehensive physical examination, including 11 roentgenograms. He was then subjected to a pressure test in the medical lock before being approved (Behnke, 1969). From June 1967 to November 1969, 1633 initial examinations and 256 annual examinations were performed. Of those examined, 81.1% were qualified for compressed-air work and 18.9% were disqualified, principally because of excessive weight and pulmonary abnormalities. Any applicant whose body weight exceeded 20% of normal was excluded. Pulmonary-function tests were routinely performed; if vital capacity was less than 80% of normal, timed VC measurement of maximal expiratory force was performed (Behnke, 1970) (see Table I).

To date, over 17,000 skeletal roentgenograms have been made on more than 2000 workers. Thirty-three osteonecrosis lesions of varying maturity were discovered in 12 preemployment examinations; 8 additional applicants had sus-

Table I. BART PROJECT: RESULTS OF PHYSICAL EXAMINATIONS OF APPLICANTS FOR WORK IN COMPRESSED AIR

	Number	%
Preemployment examinations		
Applicants qualified	1324	81.1
Applicants disqualified	309	18.9
Totals	1633	100.0
Reasons for disqualifications		
Overweight	96	31.1
Pulmonary dysfunction	66	21.4
Hernia	28	9.0
Ear block	28	9.0
Ear infection	21	6.8
Metabolic disorder	13	4.2
Osteonecrosis	12	3.9
Sickle-cell hemoglobinopathy	8	2.6
Other conditions	37	12.0
Totals	309	100.0

picious lesions and were rejected. Of the 12 subjects, 11 had potentially disabling juxta-articular lesions affecting one or both humeral heads; only 2 had involvement of the femoral heads.

It is significant that all these applicants, with one exception, were allegedly asymptomatic of joint involvement. It would therefore not have been possible to establish a diagnosis of chronic dysbaric osteonecrosis in these men without routine roentgenograms. Two of these rejected workers had previously been exposed to maximum pressures of 16 and 18 psig, respectively, without decompression sickness, but both had a history of alcoholism. All other rejected examinees had previously worked in compressed air for at least one year, and had been exposed to pressures in excess of 30 psig. Only 3 of these applicants admitted having experienced an attack of dysbarism; 7 had previously been exposed to maximum pressures in excess of 45 psig. Eight other applicants (2.6%) were disqualified because of sickle-cell hemoglobinopathy.

DECOMPRESSION PRACTICES IN THE BART PROJECT

The Medical Center had three compression chambers for testing workmen and for treating decompression sickness (DCS). Each had two compartments. The inner one, used for treatment, was equipped with oxygen; the small outer one allowed an attendant to enter without altering the inner compartment's pressure (Fig. 5). Because using compressed oxygen for treatment created a substantial fire hazard, each chamber was equipped with a sprinkler system capable of spraying the interior.

A pressure chamber was carried in an ambulance (Fig. 6) so that a severely injured workman

FIG. 5. Front and rear compartments of medical compression chamber at BART Transit Medical Center. Technician is standing inside inner treatment compartment.



FIG. 6. Portable recompression chamber in rear of ambulance used in BART project, which allowed severely injured workmen to be removed from compressed-air tunnels without undergoing a decompression cycle.

might be extricated from the tunnels without undergoing decompression. Still under compression in the portable chamber, the workman was transported to the Center's medical chamber where his injuries could be treated during decompression.

From November 1967 to May 1969, 80,360 man-decompressions were performed at pressures between 9 and 36 psig. There were 135 instances of DCS involving 85 men among approximately 400 compressed-air workers — 128 of Type I (minor) and 7 of Type II (serious). In constructing the tunnels from the ventilation shaft to the ventilation caisson 473,000 man-hours were worked, followed by 22,359 decompressions. There were 116 episodes of DCS (110 Type I and 6 Type II); 46 men suffered repeat attacks.

In two instances a relatively low pressure was associated with postdecompression symptoms following 6-hr work shifts — 13 psig in one case and 11.5 psig in the other. At relatively high pressures a rather high incidence of DCS was experienced, despite curtailed hours of work. As mentioned, work at higher pressures lasted only one week; hence the time was too short to evaluate the role of acclimatization. However, there appeared to be selective susceptibility in that, of the 85 workers involved, 52 had one attack and 33 suffered repeated ones. One man was treated 6 times for DCS, and 10 of the 33 susceptible individuals had a second attack within 48 hours of the earlier one. No criteria were delineated from these examinations to separate the susceptible workers from those who were apparently resistant, or at least did not report for treatment (approximately 75%). The interval between decompression and the onset of symptoms was prolonged — 5 or 6 hours — which may

possibly reflect the individual's reluctance to undergo recompression therapy or, possibly, to driving the 10- to 50-mile distance to the Medical Center.

Only 133 of the 832 miners originally employed for compressed-air work remained on the job and were available for their first annual examination. Results of a radiological bone survey were negative in all these men. Subsequent roentgenographic evaluations have likewise been negative. But since tunnelers are often an itinerant, migratory labor group, follow-up clinical and roentgenographic examinations are virtually impossible.

Four years have passed since the last compressed-air exposure of the BART project. No worker with clinical or roentgenographic evidence of dysbaric osteonecrosis has been reported, and no workmen's compensation claims have been filed in California as a result of the project. However, this is admittedly a preliminary report based on insufficient follow-up examinations.

DISCUSSION

The Decompression Sickness Panel of the Medical Research Council (U.K.) has found that bone lesions are related directly to the number of times that a man has been decompressed, the pressure at which he has worked, and the number of episodes of decompression sickness for which he has required recompression. The basic problem, however, transcends the prevention of DCS and focuses on decompression schedules that do not allow for the separation of inert gas from solution. Thus, nascent bubbles in the circulation, whether "silent" or clinically active, are clearly identified with such secondary phenomena as platelet aggregation, cell clumping, lipid release from lipoproteins, hemoconcentration, and fat embolism (Jones, 1971).

In the BART compressed-air operations, decompression (dc) was in accord with the recently formulated Washington State tables, which provide for single daily work shifts, rather than split shifts, and extended stage dc. The experience with these tables—which have also been adopted by other states, including New York and California — is that no crippling bone disability has been reported to date (November 1972) following trials in the Lake City Tunnel, Seattle (1964–1967), and in the BART project (1967–1969). The incidence of DCS in those two projects was, however, about the same as that in earlier compressed-air operations, which were followed by much shorter dc times.

Before specific regimens in support of these concepts are presented, it is appropriate to examine earlier dc experience resulting in the serious complication of avascular necrosis of bone.

New York Tables

East River Tunnel Decompression Practices (to 1909). Keays (1909) reported 3692 cases of DCS resulting from 557,000 decompressions in the construction of the East River Tunnels for the Pennsylvania Railroad. There were 20 deaths. At pressures of 32 psig, men worked 8 hours out of 24, taking 30 minutes for lunch at working pressure or one slightly lower. At higher pressures the work shifts consisted of two 3-hr exposures with a 3-hr rest interval at normal pressure. Working pressure never exceeded 42 psig. Keays preferred a 6-hr continuous shift to two 3-hr shifts "as it exposes the man to the risks of only one decompression instead of two."

In 23,000 decompressions from pressures between 40 and 42 psig, there were no serious or fatal cases among the 330 men employed for 36 days. The total dc time for each shift was 48 min, as follows:

1. Pressure was lowered from 40 to 29 psig in 5 min; the men then spent 10 min walking 1000 ft to a second lock.
2. Pressure was lowered from 29 to 12.5 psig in 8 min; the men spent another 10 min walking to a third lock.
3. Pressure was lowered from 12.5 to 0 psig in 15 min.

Considerable time, then, was spent at relatively high pressure levels during dc, and the workers engaged in light exercise (walking). Reporting on 8510 of these decompressions, Keays recorded 1.6% minor cases of DCS (Type I). Noteworthy is his statement that "only seasoned men were employed," conveying Keays' recognition of the remarkable acclimatization or acquired resistance to DCS that has subsequently been confirmed by British medical authorities (Paton and Walder, 1954; McCallum, 1968).

One of the paradoxes of dc practice observed over the years is that decreased incidence of Type I DCS does not correlate with increased dc time beyond minimal requirements. Keays' 3-hr work shift at 40 psig was followed by 48-min dc. This same exposure would require 98-min dc in England (Work in Compressed Air Special Regulations, U.K.); 162-min dc for USN divers (U.S. Navy Standard Air Decompression Tables for exceptional exposures); and 183 min for Seattle tunnelers (Washington State tables). Of possible

significance in the occurrence of bends is the probability of extensive bubble evolution during the first-stage drop of 50% in the absolute or gauge pressure in these later tables. In this event the pressure head facilitating gas transport is greatly reduced, and little benefit would accrue from the moderately increased dc time. It is possible that a 48-min dc (Keays, 1909) at higher pressure is as effective as a two- or threefold increase in dc time at lower levels following initially large, abrupt increments of dc.

N. Y. Tables of 1912 and Subsequent Revisions. Progressively, hours of caisson work were decreased and the interval between shifts was lengthened. In contrast to the earlier compressed-air schedules, the 1912 tables (Table II) were seemingly liberal. In 1947 Captain O. E. Van Der Aue, MC, USN (personal communication), conducted dry-chamber tests at 26 psig with 12 divers in good physical condition and at rest. The exposures were the same as those allowed by the 1912 tables (3 hr) but included a rest interval, at normal pressure, of 3 hr (2 hr longer than that stipulated by the 1912 tables). The outcome of these nonwork exposures is shown in Table III.

Table II. 1912 N.Y. STATE DECOMPRESSION TABLES AND SUBSEQUENT REVISIONS

Pressure (psig)	Shift 1 (hr)	Interval at surface	Shift 2 (hr)	Decompression per shift (min)	
1912					
to 22	4.0	0.5	4.0	7 at 17.8 psig	
22 to 30	3.0	1.0	3.0	12 at 26.7 "	
30 to 35	2.0	2.0	2.0	19 at 31.2 "	
35 to 40	1.5	3.0	1.5	24 at 40 "	
40 to 45	1.0	4.0	1.0	— —	
45 to 50	0.75	5.0	0.75	28 at 49 "	
1922*					
to 18	4.0	0.5	4.0	5**	
18 to 26	3.0	1.0	3.0	12**	
26 to 33	2.0	2.0	2.0	21**	
33 to 38	1.5	3.0	3.0	23**	
38 to 43	1.0	4.0	4.0	27**	
43 to 48	0.75	5.0	0.75	29**	
1955–1957***				1st	2nd
to 22	3.0	2.5	3.0	16**	27**
22 to 30	2.0	3.5	2.0	22**	37**
30 to 35	1.5	4.0	1.5	25**	42**
35 to 40	1.0	4.5	1.0	29**	49**
40 to 45	0.75	4.75	0.75	32**	57**
45 to 50	0.5	5.0	0.5	37**	62**

*Decompression time for maximum pressure in each category

**Stage 1 dc — Reduce gauge pressure by 50% at rate of 5 psi/min

Stage 2 dc — Reduce pressure at uniform rate according to maximum pressure:

Working pressure 0 to <15 psi, rate: 3 psi/min
Working pressure 15 to <20 psi, rate: 2 psi/min
Working pressure 20 to <30 psi, rate: 3 psi/2 min
Working pressure 30 psi and over, rate: 1 psi/min

***Lincoln Tunnel (Third Tube)

Table III. RESULTS OF DRY-CHAMBER PRESSURE EXPOSURES, WITH SUBJECTS AT REST*

Diver	Condition between 1st and 2nd shifts	Following 2nd shift
1	No symptoms	Bends, recompression
2	" "	No symptoms
3	" "	Pain, hand
4	" "	Pain, arm
5	" "	Back pain, fatigue
6	" "	No symptoms
7	" "	Stiffness, knee
8	" "	Bends
9	Skin itch	Skin itch
10	Fleeting pain, shoulders	Bends
11	Pain, shoulder (at 175 min)	Bends, recompression
12	Pain, knees (at 120 min)	Bends

*Van Der Aue, personal communication

It is likely that acclimatization may have modified these unexpected results. However, it is difficult to reconcile the striking difference between dc practice relative to divers (stage dc with progressively longer time at successive stops) and to tunnel workers (the split shift and shortened dc time at a uniform rate following the initial 50% drop in gauge pressure).

The 1912 tables proved to be inadequate and were revised in 1922 (Table II). But despite shortened hours of work and somewhat longer intervals in open air, serious morbidity still occurred. Of the 300 instances of DCS reported by Thorne (1941), there were 25 Type II cases involving the CNS, 15 Type II cases with cardiopulmonary symptoms ("chokes"), and 30 Type II cases with vertigo ("staggers").

Bone Necrosis Relative to the 1922 N. Y. Tables. In 1942, Bell *et al.* reported on a radiologic survey of 32 compressed-air workers in New York, none of whom had symptoms or gross signs indicative of bone lesions. The men had worked intermittently for 3 to 33 years in compressed air. The shortest continuous employment was 10 months, the longest, 36 months. Fourteen men gave a history of DCS but 18 stated that they had never had an attack of bends. Yet only 8 of the 32 workers were free of radiologic evidence of bone lesions.

Certain aspects of avascular bone necrosis — specifically, individual variations in response to similar conditions of decompression — were as puzzling then as now. Taylor (1944) reported that the same type of lesions was observed in 38 individuals who had never worked in compressed air: "Individuals with an inadequate circulatory tree who work under increased pressures may develop bone and joint lesions with the ordinary so-called adequate decompression, even in the absence of an acute attack of caisson disease. Agglutination of red cells may play a part."

Based on radiologic evidence of bone lesions, 63 claims for disability were made by tunnel workers in New York in October 1963. Paradoxically, these claims related to the Lincoln Tunnel (Third Tube) operations of 1955–1957 (Table II), which were conducted according to "enlightened" schedules stipulating minimal hours of work and maximal decompression, in accord with principles underlying U.S. Navy practice. This experience merits recounting, since it points up the prohibitive cost of manned, pressurized tunnel operations.

Following World War II, the New York State Department of Health and the Port Authority, in consultation with O. E. Van Der Aue, G. J. Duffner, and A. R. Behnke, Jr., sought to revise the 1922 tables. In addition to curtailing work hours further, about 66% more stage-decompression time was allotted for the second shift of the split-shift regimen. Although Kooperstein and Schuman (1957) reported only 44 cases of DCS out of 138,034 decompressions (3.18 cases/10,000), it is not possible to state with complete assurance that no bone lesions complicated this specific operation. It seems probable that some of the 63 processed claims for disability due to osteonecrosis in the Lincoln Tunnel workers may

have occurred as a result of injury received prior to 1955, since preemployment radiological bone surveys were not performed.

Washington State Tables, 1963

Rationale. In 1961 J. Leon Sealey, Medical Consultant to the Municipality of Seattle and Metropolitan Engineers, organized a committee to revise dc tables for compressed-air workers. Their objective was to formulate tables based on the following concepts:

1. A single daily work shift with stage dc limited to a ΔP of 16 psi relative to tissue half-times of 30, 60, and 120 min.
2. A potential 8-hr exposure in compressed air apportioned between work at tunnel pressure and stipulated dc time.

For example, a 6-hr shift at 22 psig requires 103-min dc; total time under pressure, 7 hr and 43 min. A 5-hr shift at 32 psig is accorded 178-min dc; total time under pressure, 7 hr and 58 min. The extended time stipulated for dc in the usual range of tunnel pressures (0 to 35 psig) is more than twice the time allotted for the same work shifts in England, and even exceeds dc time for exceptional air exposures in the U.S. Navy diving tables.

Incidence of DCS Relative to Extended Decompression Time. The innovations outlined above were enforced throughout the Seattle project (1964–1967), the BART project (1967–1969), and recently in Milwaukee (1971–1972). An unexpected finding was that the incidence of DCS did not diminish as a result of the greatly extended dc time (Table IV). The exceptionally high incidence in the BART operation at 29.5 and 35.5 psig, relative to the modest length of the work shifts, may be partially due to a lack of acclimation in the workers. Highly favorable, however, was the response to low-pressure oxygen therapy, as stipulated by U.S. Navy treatment tables 5 and 6, in the 345 cases of DCS (Seattle and BART projects). There were no residual complications in these cases.

Absence of Disabling Bone Lesions. The major benefit now apparent from this protocol is the absence of disabling juxta-articular necrosis. Limited opportunity for radiologic follow-up precludes a conclusive statement regarding ultimate benefits, but restricting the number of work shifts above 26 psig also appears to militate against osseous complications.

Inherent and Extraneous Impediments to Decompression. In the Washington State tables, a 16-psig drop in pressure takes place in 3 min to the first stop. Following a 6-hr work shift at 30 psig, the P_{N_2} resulting from the rapid pressure drop to 15 psig is substantially below that calculated as safe (18 psig) in a 120-min tissue half-time ($T_{1/2}$). The pressure is then reduced from 14 to 4 psig in 35 min, and from 4 to 0 psig in 130 min. The substantial part of dc is therefore spent under conditions of diminishing N_2 transport (*i.e.*, a decreasing size of the "oxygen window"). On the assumption (now experimentally verified) that bubbles form during initial stages of dc, the schedule is, in effect, a treatment regimen. It is beyond the scope of this section to discuss obvious modifications of the Washington State tables, which must be validated by systematic test procedures.

Two undesirable physical effects of a rapid pressure drop in chamber-lock air are fog formation and cooling. When hot and sweating workers become chilled, a peripheral vasoconstriction may occur. These conditions impair blood flow and favor bubble evolution in subcutaneous vessels, which may give rise to pruritus and mottling.

Various physiologic factors impair gas trans-

Table IV. DECOMPRESSION TIME (MIN) ACCORDING TO 1971 MRC (U.K.) TABLES AND TO WASHINGTON STATE TABLES*

Pressure (psig)	Shift, 1 to 2 hr	Shift, 2 to 3 hr	Shift, 3 to 4 hr	Shift, over 4 hr
18 to 20	8 (8)	10 (11)	12 (17)	17½ (63)
24 to 26	17 (27)	27 (52)	37 (92)	51 (122)
28 to 30	39 (41)	51 (98)	58 (127)	70 (153)
34 to 36	52 (98)	72 (151)	82 (178)	98½ (218)
38 to 40	62 (128)	86 (178)	98 (203)	117½ (238)

*The decompression times (min) shown in parentheses are calculated from Washington State tables for the lowest pressure in the range quoted from the MRC (U.K.) tables and for shifts of 2, 3, 4, and 6 hr, respectively.

port — *e.g.*, dehydration in the hot atmosphere surrounding the automated shield at the face of the tunnel, disruption of circadian rhythms because of periodic work-shift rotations, and deficient blood perfusion of tissues as a result of alcoholism, intravascular bubble formation, bubble-related clumping of cells, and decreased blood-clotting time. In the course of long decompressions, the relative immobility of the lower extremities of workers as they play cards (the typical pastime) obviously serves to restrict regional N_2 transport.

British Decompression Experience

In the construction of the road tunnel under the River Tyne (England), 641 men worked in compressed air over a period of 31 months (1962–1965). The maximum pressure was 42 psig and the overall dysbarism rate for work at pressures of 18 psig and higher was 2%. Data extracted from the report of the Decompression Sickness Panel (1971) affirm the high percentage of DCS with increased exposures over 4 hr and with higher pressures (Table V). Inexplicably, the modified U.K. statutory decompression table does not provide increased dc time for work shifts over 4 hr. In an earlier study, Paton and Walder (1954) reported that increase in stipulated dc time did not diminish the incidence of DCS. A possible explanation of this circumstance was commented on earlier.

During construction of the River Tyne road tunnel, radiologic examinations were made of 171 men; avascular osteonecrosis was found in one or more bones of 44 men (26%). Although most of these workers were symptomless three years after the termination of compressed-air exposure, four were partially disabled despite surgery.

The results shown in Table V reveal that work shifts of less than 4 hr produced minimal complications. When the shifts were 8 hr or longer, the incidence of Type I DCS increased fivefold, and there were 16 cases of Type II DCS.

In Table IV the total dc times of the 1971 MRC (U.K.) tables for the usual range of tunnel pressures relative to shift duration are compared with the much greater dc times of the Washington State tables. Note again that absolute pressure is reduced 50% during the rapid pressure decrease to the first stop. With the Doppler ultrasonic detector, it is possible to substantiate the theory that gas bubbles form in the circulation during this initial stage of decompression. The Decompression Sickness Panel concludes that the dc procedures and treatment of bends currently accepted in civil-engineering practice do not prevent aseptic bone necrosis in compressed-air workers.

Table V. INCIDENCE OF DECOMPRESSION SICKNESS RELATIVE TO MAN-DECOMPRESSIONS, TYNE ROAD TUNNEL, ENGLAND*

Pressure (psig)	Number of man-decompressions			
	Shift, under 4 hr	Shift, 4 to 6 hr	Shift, 6 to 8 hr	Shift, 8 hr and over
14 to 19	7625 [0.53]**	1504 —	2332 [5.58]	8698 [5.98]
20 to 29	5262 [4.6]	1073 [27.0]	1617 [33.4]	9367 [20.8]
30 to 36	1547 [8.5]	359 [61.3]	404 [40.4]	2977 [53.4]
37 to 41	495 [18.2]	105 —	38 —	564 [67.4]
Totals	14,929 [3.35]	3041 [23.4]	4391 [19.1]	25,606 [17.1]
Number of Type II (Serious) DCS	1	3	3	16

*Abstracted from Medical Research Council, 1971

**Incidence of Type I (minor) DCS per 1000 man-decompressions shown in brackets

Physiologic Principles Pertaining to Gas Transport during Decompression

Body Composition and Gas Transport. An estimate, supported in part by quantitative data, can be made of blood flow to various bodily tissues of a hypothetical lean (70-kg) man relative to N_2 content (Table VI). About 50% of the N_2 content of this man (10% fat in adipose tissue) is in aqueous tissues with a large blood supply. The other 50% is in fatty tissues with a meager blood supply. The $T_{1/2}$ for N_2 transport in aqueous tissues varies from less than 2 min to not more than about 16 min. In this man's fatty tissues, $T_{1/2}$ for N_2 transport ranges between 85 and 120 min.

Definite end-points for N_2 elimination have not been determined. But Lundin's data (1960) clearly show the association between body fat and prolongation of desaturation time. Calculations indicate that about 54 ml of N_2 will be added to the body's N_2 store for every kg of fat gain. Moreover, the "heavy" men in Gray's analysis (1951) manifested progressive susceptibility to altitude decompression sickness in relation to weight.

Haldane's Ratio Concept and Stage Method. It is apparent from dc data that exposures to 15 psig and even somewhat higher pressures are well tolerated in acclimatized workers without need for more than a few minutes' dc (minimal). Haldane postulated (Boycott *et al.*, 1908) that, since the body could be decompressed rapidly from 2 to 1 atm abs, it would be safe to reduce the absolute pressure at higher levels by 50% as the first stage in dc. For the diving depths and exposure times with which Haldane was concerned, it appeared that the 2:1 supersaturation ratio was satisfactory. But subsequent deeper dives and longer exposures have demonstrated unequivocally that no single ratio applies in decompression and that, probably, no degree of inert-gas supersaturation is maintained in circulating blood for any appreciable time. *What appears to be a ratio indicative of inert-gas supersaturation in blood may, in reality, be an index of the degree of air embolism that the body can tolerate.*

The ΔP Principle. Another concept applied to decompression-schedule calculation is based upon the assumption that tissue pressure can be safely decreased from 2 to 1 atm abs, creating a pressure head of air (*i.e.*, about 12 psi N_2) that can be safely sustained during decompression at all pressure levels above ambient pressure. The ΔP principle has been widely applied, notably in the computation of the Washington State tables. However, the physiologic and physical bases underlying gas transport do not explain decompres-

Table VI. ESTIMATED WEIGHT, FLUID, AND LIPID CONTENT OF 5 TISSUE CATEGORIES FOR 70-KG MAN, PLUS CALCULATED N_2 CONTENT RELATIVE TO BLOOD PERFUSION AND $T_{1/2}$ FOR N_2 TRANSPORT

Parameter	Tissue-organ group				
	Blood, organs, red marrow, GI tract	Muscles, skin, spinal cord, nerves	Bone matrix* (fat, mineral-free)	Bone marrow (fat-rich)	Adipose tissue (lean man)**
Weight (g)	15,000	37,000	4,000	1,500	9,500
Fluid (g)	12,000	28,000	2,500	200	2,000
Lipid (g)	400	400	—	1,200	7,000
N_2 content (ml)***					
Fluid	108	252	23	2	18
Lipid	22	22	—	65	378
Blood perfusion (ml/min)	4,000	1,200	80?	50?	400
N_2 transport ($T_{1/2}$/min)	2 to 16		85? to 120?		

*Weight of mineral in bone: 3000 g

**Lean man: 10% of body weight is lipid in adipose tissue

***N_2 solubility per kg fluid, 9 ml; per kg lipid, 54 ml (P_{N_2}=570 mm Hg; temp., 37°C)

sion at a fixed oversaturation pressure of 12 psig any better than they do decompression at a fixed 2:1 ratio.

The Isobaric ("Oxygen Window") Concept. During the course of blood flow through capillaries, oxygen is unloaded in different quantities to various tissues. During the late 1930s Capt. Charles B. Momsen, USN, and his medical officers (U.S. Navy Experimental Diving Unit) postulated that O_2 diffusion from capillary blood into tissues creates a "partial pressure vacancy" to permit isobaric transport of an equivalent amount of inert gas from tissues to capillaries to lungs. This concept holds that, essentially, an "oxygen window" exists in the capillary blood through which inert gas diffuses from tissues. This window is proportional in size to the alveolar Po_2.

At normal pressure during air inhalation, arterial Po_2 (100 mm Hg) falls to about 40 mm Hg in the capillaries. The size of the potential window (60 mm Hg) is reduced to about 53 mm Hg by an increase in capillary CO_2 tension. If arterial Po_2 is elevated to 287 mm Hg through inhalation of a mixture richer in O_2 than air, mean capillary Po_2 rises to about 50 mm Hg. With the addition of 7 mm Hg of CO_2, the O_2 window $[287-(50+7)]$ equals 230 mm Hg, the equivalent of 10 FSW.

How does this concept apply to diving decompression? It is postulated currently that, during the course of decompression following a helium saturation dive, there is permissible oversaturation of inert gas, ΔP, equal to $\pi - P$, where π is inert-gas tension in the slowest desaturation tissue ($T_{1/2}$, 240 min) and where P is total ambient pressure. The total driving force implementing inert-gas transport is ΔP + alveolar Po_2. Ascent rate for desaturating 1 ft of He from a 240-min tissue is represented by:

$$\frac{d\pi}{dt} = -\frac{0.693}{240\text{ min}}(20+10) = 11.6 \text{ min per ft.}$$

π is equal to inert-gas tissue tension, $0.693 = \ln 2$, $\Delta P = 20$ FSW, and $Po_2 = 0.3$ atm abs $= 10$ FSW (Workman, 1969). However, if permissible oversaturation — *i.e.*, ΔP of 20 FSW — is incompatible with transport of inert gas *in solution*, an ascent rate of 11.6 min/ft would still hold if the $T_{1/2}$ of the slowest tissue is 80 min rather than 240 min, as indicated by earlier (admittedly incomplete) measurement of He transport. The following comparative data demonstrate isobaric gas transport from tissues to lungs.

	Gas tensions (mm Hg)	
	Lungs	*Tissue-capillary blood*
Helium	2000	2230
Oxygen	287	50
Carbon dioxide	40	47
Water vapor	47	47
Totals	2374	2374

The O_2 window for He transport is 230 mm Hg (≈ 10 FSW). Isobaric decompression can progress uniformly at a rate of about 11.5 min/ft, a rate concurrent with a 230-mm-Hg fall per min of He in the 80-min tissue.

The isobaric principle of decompression is mandatory in deep saturation diving, but it requires too long a time to be practical in subsaturation diving. Hence an unfortunate compromise between the ideal and the practical has been made with the consequence of an appreciable incidence of decompression sickness (Behnke, 1967; Behnke, 1969).

Oxygen in Decompression and Recompression Practice

Oxygen is not routinely employed in the dc of tunnel workers, chiefly because a regimen has not been developed to control the fire hazard involved. However, effective fire control has been maintained in hyperbaric chambers in the dc of divers, treatment of DCS, and administration of hyperbaric oxygen to patients. During salvage operations of the Submarine *Squalus* in 1939, oxygen was first used in surface decompression. Divers were brought rapidly to the surface, then were recompressed in a deck decompression chamber on O_2 to pressures between 26.7 psig (60 FSW) and 17.8-psig (40 FSW). At the end of the scheduled 17.8 psig period, pressure was decreased to 1 atm abs in 5 min. There were no decompression stages at less than 40 FSW (17.8 psig).

Oxygen decompression of divers and O_2 treatment of DCS have become routine in the U.S. Navy, but there is either stage or uniform decompression at pressures lower than 15 psig. These procedures are questionable for two reasons: *1*) the possibility of bubble growth increases, and *2*) the inert-gas transport capacity of blood diminishes as the pressure gradient falls below 15 psig.

Sealey (1970) found that hyperbaric O_2 treat-

ment in accord with U.S. Navy treatment tables 5 and 6 was singularly effective in the management of 210 cases of DCS. This therapy, modified to eliminate uniform decompression from 15 psig, was also highly effective in promoting the prompt recovery of 135 BART workers stricken with DCS, despite an average 5- to 6-hr delay before they reported for treatment. With few exceptions the patients, who had received 90 and 120 min of O_2 therapy, resumed their next regular work shift (Behnke, 1970).

Oxygen Decompression of Tunnel Workers. Oxygen rather than air inhalation during the dc of tunnel workers would reduce the decompression time of the Washington State tables by at least a factor of 2. This regimen also holds great promise in preventing both DCS and dysbaric bone necrosis, since excess N_2 can be eliminated from tissues under isobaric conditions. In addition, work shifts could be lengthened safely.

Table VII incorporates data for various isobaric decompressions utilizing O_2 inhalation following work shifts of 6 hr at 20, 30, and 36 psig, and of 4 hr at 40 psig.

Calculation Based on a 120-min Half-time Tissue. At the end of a 6-hr shift, $P_{N_2} = 11 + 0.875$ (80% psig) and at the end of a 4-hr shift, $P_{N_2} = 11 + 0.75$ (80% psig). The values 0.875 and 0.75 represent % saturation of 120-min tissue following 3 and 2 half-saturation time units (T.U.), respectively; 11 psia is tissue N_2 partial pressure in equilibrium with alveolar N_2 at 1 atm abs.

Excess N_2 (ΔP_{N_2}) is the difference between the P_{N_2} of the 120-min tissue and the permissible level, which is set at the conservative figure of 19 psia (11 psia + 8 psia). The 8-psia P_{N_2} value for the 120-min tissue is highly conservative, a level requiring no decompression after saturation exposure.

The length of time for O_2 decompression is calculated as follows:

$$\frac{\Delta P}{P_{N_2}\ (120\text{-min tissue})}.$$

For example, after a 6-hr shift at 36 psig, P_{N_2} in the 120-min tissue is 36.2 psia and ΔP_{N_2} is 17.2 psi (36.2 − 19). Oxygen decompression time is computed from 17.2/36.2, or 47.5% of the total. This percentage of N_2 is eliminated in 112 min from the 120-min tissue. In the last column of Table VII are shown rounded values for O_2 dc per hr of work. These values relate conservatively to the estimate that 80% to 85% is the "effective" O_2 concentration in the lungs.

The size of the O_2 window (*i.e.*, the approximate pressure level for O_2 inhalation) is at all times not less than the P_{N_2} in the 120-min tissue (Table VII). Inhalation of O_2 at these pressures has been well tolerated in practice. In preliminary tests of isobaric decompression, the following schedule of moderate exercise, performed under the voluntarily imposed adverse chamber conditions of high humidity and no ventilation, was well tolerated by a 65-yr-old subject:

Pressure (psig)	Duration (hr)	O_2 decompression (min) per hr of work
20	1 to 6	10
30	1 to 6	20
40	1 to 4	30

After the 40-psig exposures, the subject inhaled O_2 continuously at pressures no higher than 30 psig (for short periods) and no lower

Table VII. PROTOTYPE OXYGEN DECOMPRESSION TABLE FOR TUNNEL WORKERS

Tunnel pressure (psig)	Work shift (hr)	P_{N_2}* (psia)	ΔP_{N_2}** (psi)	Calculated decompression time (min)***	
				Total	*Per hr work*
20	6	25.0	6.0	48	10
30	6	33.0	14.0	96	20
36	6	36.2	17.2	112	23
40	4	35.0	16.0	102	30

*In 120-min tissue at end of shift

**Excess N_2 to be eliminated from 120-min tissue + P_{N_2} − 19

***Rounded estimates based on 80% to 85% alveolar O_2

than 15 psig. The closed-circuit O_2 inhalation apparatus was periodically rinsed by means of a "demand" regulator. Continuous O_2 inhalation against some expiratory resistance, interspersed with periodic deep breaths, was well tolerated for 2-hr periods. At the termination of O_2 breathing, the subject was decompressed on air in 5 min to normal pressure.

Few data exist regarding daily inhalation of O_2 for the purpose of decompression. Tests by Jacobs *et al.* (1970) demonstrated that elderly persons with senile impairment could tolerate inhalation of 100% O_2 for 90-min periods twice daily at 2.5 atm abs without ill effects. These exposures were repeated for 150 to 435 days with only an occasional break. What is now needed is the systematic daily exposure of healthy men to an O_2 dc regimen following the work shifts described in this paper.

Periodic Residence in Compressed Air

It has been shown repeatedly that habitation in dry chambers and undersea habitats is feasible for at least two weeks in air atmospheres at depths equivalent to 50 FSW (22.2 psig). Larsen and Mazzone (1967) conducted tests showing that a 4-hr no-decompression excursion can be made to a simulated depth of 100 FSW (44.5 psig) from a saturation pressure of 15.6 psig (35 FSW). The following tabulation indicates the scope of no-decompression excursions that are considered theoretically safe:

Saturation pressure (psig)	Working pressure (psig)	Work time (hr)
15	25	6
15	30	4
15	35	3
15	40	2

The feasibility of two work shifts daily per man remains to be tested with and without O_2 inhalation following saturation exposures at 15 psig.

If the pressure in an undersea habitat can be safely raised to an upper level of 22.2 psig (50 FSW), it should be possible to conduct work at tunnel pressures up to 32 psig for indefinite periods followed by isobaric decompression back to habitat pressure. At higher working pressures O_2 could be inhaled for short periods at habitat pressure.

A detailed schedule applicable to tunnel workers remains to be developed and validated by repeated tests.

SUMMARY

Osteonecrosis is a major hazard when compressed air is used in civil-engineering projects (tunnel or caisson work). Preliminary analysis of the BART project's history suggests that dysbaric osteonecrosis may possibly be prevented by following certain engineering and medical practices.

The risk of decompression sickness is minimal if working pressure can be maintained below 11 psig; maintaining pressure below 17 psig minimizes the risk of dysbaric osteonecrosis. Engineering consideration should therefore be given to avoiding the use of compressed air altogether, or minimizing the pressure necessary in tunnel, caisson, or diving work. Engineering principles should also include *1*) use of prefabricated tunnels deployed with minimum direct supervision by divers breathing compressed air; *2*) dewatering, probing, and elimination of obstacles in the heading; *3*) use of machine-tunneling apparatus and mechanically operated erector arms, which reduce the requirement for pneumatic hand-operated equipment and heavy overhead lifting; and *4*) maintaining a man-lock and emergency lock adjacent to the working area.

To disqualify from work those applicants with antecedent dysbaric osteonecrosis or coexistent illnesses associated with avascular osteonecrosis, comprehensive preemployment examinations are essential — including special laboratory studies and roentgenograms. Bone lesions have been associated with the primary effects of nascent bubbles liberated during rapid decompression and with such secondary complications incident to bubble release as platelet aggregation, cellular clumping, release of lipids with embolic potential, and circulatory stasis. Predisposing factors are repeated decompressions, the pressure under which the individual has worked, and the number of attacks of dysbarism that he has experienced.

During the past 50 years steps have been taken in New York State to reduce the incidence of dysbarism and the complication of bone necrosis by shortening hours of work. In both U.S. and U.K. experience, it has not been possible to limit the hazard of decompression sickness.

Tables have recently been computed by the State of Washington that greatly extend decompression time following prolonged pressure exposure. But use of these tables in the Seattle tunnel project (1964–1967) and in San Francisco's BART project (1967–1969) did not appear to reduce the incidence of dysbarism. Nevertheless, no case of disabling bone necrosis has been

reported as of this writing (1972).

To circumvent future dysbarism-related injury in compressed-air work, two positive procedures are suggested: *1*) O_2 decompression under conditions favoring isobaric N_2 elimination from tissues; and *2*) residence in compressed-air habitats with pressure adjusted to that of the tunnel. The feasibility of these procedures has been demonstrated in diving practice, but they remain to be implemented in compressed-air tunnel operations.

ACKNOWLEDGMENTS

The authors are deeply indebted to Mr. Edward Peterson, Manager of Construction, and Mr. Peter Frobenius, Senior Engineer, of Parsons, Brinckerhoff-Tudor-Bechtel Corp., San Francisco, who permitted the authors to abstract from their comprehensive reports on the various phases of BART operations. The authors are also most grateful to Mr. Leland J. Hoagland, Insurance Director of the BART Transit Insurance Administrators, for his cooperation; and to Mr. Marlin E. Young, the Administrators' Field Service Coordinator, without whose invaluable assistance much of this work would not have been possible.

REFERENCES

Behnke, A. R. (1967). The isobaric (oxygen window) principle of decompression. In The New Thrust Seaward. pp. 213-228. Washington, D.C.: Marine Tech. Soc.

Behnke, A. R. (1968). Medical aspects of work in pressurized tunnel operations. Transit Insurance Administrators Publ.

Behnke, A. R. (1969). New approaches to medical aspects of work in compressed air. J. Occupational Med. 11, 259-272.

Behnke, A. R. (1970). Medical aspects of pressurized tunnel operations. J. Occupational Med. 12, 101-112.

Bell, A. L., Edson, G. N., and Hornick, N. (1942). Characteristic bone and joint changes in compressed-air workers: A survey of symptomless cases. Radiology 38, 698-707.

Boycott, A. E., Damant, G. C. C., and Haldane, J. S. (1908). The prevention of compressed-air illness. J. Hyg., Camb. 8, 342-443.

Decompression Sickness Panel, Medical Research Council. (1971). Decompression sickness and aseptic necrosis of bone. Brit. J. Med. 28, 1-21.

Gray, J. S. (1951). Constitutional factors affecting susceptibility in decompression sickness. In Decompression Sickness. p. 182. Ed. Fulton, J. F. Philadelphia: Saunders.

Jacobs, E. A., Winter, P. M., Alvis, H. J., and Small, S. M. (1970). Hyperoxygenation effect on cognitive functions. In Proceedings of the Fourth International Congress on Hyperbaric Medicine. pp. 448-452. Tokyo: Shoin.

Jones, J. P., Jr. (1971). Alcoholism, hypercortisonism, fat embolism and avascular necrosis. In Idiopathic Ischemic Necrosis of the Femoral Head in Adults. p. 130. Ed. Zinn, W. M. Stuttgart, Germany: Thieme.

Keays, F. L. (1909). Compressed air illness with a report of 3,692 cases. Publ. Cornell Univ. Med. Coll. 2, 1-55.

Kooperstein, S. J., and Schuman, B. J. (1957). Acute decompression illness: A report of 44 cases. Ind. Med. Surg. 26, 492-496.

Larsen, R. T., and Mazzone, W. F. (1967). Excursion diving from saturation exposures at depth. In Proceedings of the Third Symposium on Underwater Physiology. pp. 241-254. Ed. Lambertsen, C. J. Baltimore: Williams & Wilkins.

Lundin, G. (1960). Nitrogen elimination from the tissues during oxygen breathing and its relationship to fat:muscle ratio and the localization of bends. J. Physiol. 152, 167-175.

McCallum, R. I. (1968). Decompression sickness: A review. Brit. J. Ind. Med. 25, 4-21.

Paton, W. D. M., and Walder, D. N. (1954). Compressed air illness: An investigation during the construction of the Tyne Tunnel, 1948-50. p. 18. Special Rep. Series, Medical Research Council (Lond.), No. 281. London: Her Majesty's Stationery Office.

Sealey, J. L. (1969). Safe exit from the hyperbaric environment: Medical experience with pressurized tunnel operations. J. Occupational Med. 11, 273-275.

Sealey, J. L. (1970). Minimal recompression, hyperbaric oxygen treatment of decompression sickness in tunnel workers. In Proceedings of the Fourth International Congress on Hyperbaric Medicine. pp. 100-104. Tokyo: Shoin.

Taylor, H. K. (1944). Aseptic necrosis in adults: Caisson workers and others. Radiology 42, 550-569.

Thorne, I. J. (1941). Caisson disease: A study based on three hundred cases observed at the Queens-Midtown Tunnel project. J. Amer. Med. Assoc. 117, 585-588.

Workman, R. D. (1969). American decompression theory and practice. In The Physiology and Medicine of Diving and Compressed Air Work. Ed. Bennett, P. B., and Elliott, D. H. Baltimore: Williams & Wilkins.

MILWAUKEE SEWERAGE TUNNEL PROJECT

ERIC P. KINDWALL

The City of Milwaukee Sewerage Commission is at the present time engaged in constructing 70 miles of sewer tunnel under Milwaukee County, which ranges from 8 to 12 feet in finished diameter. Since much of the work is performed in wet porous soil, the pressures under which the men work have averaged from 20 to 38 psig.

When the author first arrived in Milwaukee, in 1969, to supervise the operation of two hyperbaric chambers at St. Luke's Hospital, he was familiar only with U.S. Navy decompression practices. It came as a surprise, therefore, to discover that the tunnel workers were using a split shift, with an hour's surface interval between shifts. The fact of repetitive exposure was not taken into account in the decompression following the second shift. Furthermore, these decompression schedules — a modification of the 1922 New York code incorporated into the Wisconsin statutes — provided only about a third of the decompression required following similar exposures in U.S. Navy practice.

Because of these discoveries, St. Luke's Hospital began routinely to X-ray the joints of any patient who presented himself for treatment of bends to see if he had contracted aseptic necrosis. It soon became evident that many men were afflicted with the disease, some of them already symptomatic. As a result of these preliminary investigations, a new state code committee was formed, of which the author became chairman. In August 1970 the Washington State decompression tables were adopted in Wisconsin by emergency order of its Department of Industry, Labor, and Human Relations; by September 1971 a completely new code had been devised. However, the decompression procedures followed until 1970 have produced an alarming incidence of bone disease.

Under the new code it is mandatory that each man be X-rayed before he enters compressed air. The author has therefore had the opportunity to examine all those men still working in tunnels who had had previous exposure to compressed air, in addition to some who have retired.

At this writing 188 men have been examined, of whom 169 had previous exposure to compressed air at pressures greater than 16 psig. Of the latter group, 59 (or 35%) were found to have lesions of aseptic necrosis. Forty-two (71%) of the men with the disease had potentially disabling juxta-articular lesions; of that number, 16 were already symptomatic. It is also of interest that an additional 26 of the 188 men examined were found to have classic "bone islands"; of those 26, only 3 had never worked in compressed air.

This extremely high incidence of aseptic necrosis is actually not surprising. Almost all compressed-air tunnel and caisson work done in the United States prior to 1963 was carried out with split-shift tables, usually modifications of the 1922 New York code — which provided inadequate decompression, as we are now well aware. Thus anyone who worked in compressed-air tunneling or caisson construction at pressures greater than 16 psig prior to 1963 is a likely candidate for aseptic necrosis.

Subsequent to their introduction in 1963, the Washington State decompression tables were adopted by California, Wisconsin, and Michigan. The Occupational Safety and Health Act of April 1971 has since designated them as the national standard for all compressed-air work done in the United States. To date not a single well-documented case of aseptic necrosis has evolved from use of the Washington State tables.

Washington and Wisconsin also have the first state codes requiring preemployment X-rays of tunnel workers. The new federal code unfortunately does not require such X-rays, despite strong recommendation from medical experts. For this reason, the true incidence of aseptic necrosis in areas where much pressurized tunnel construction has taken place is still unknown. For example, as far as is known the compressed-air workers of Illinois have not been X-rayed. Yet prior to the new federal code, Illinois had

even worse decompression schedules than Wisconsin did.

In establishing our own program, we were initially quite ignorant of the proper X-ray views to take to detect early necrosis. But, thanks to help from Albert Behnke of the San Francisco Transit Compressed Air Medical Center, and from John P. Jones, Jr. — and drawing, as well, from British experience — we have devised an X-ray protocol that we find quite suitable.

Regarding the shoulder, it is important to use the Grashey position so that overlap of the humeral head, glenoid, and acromion is eliminated or greatly reduced. Two views — one in internal and the other in external rotation — are obtained in the Grashey position, with the patient's shoulder tilted at a 45° angle to the table and with a 15° angle on the X-ray tube. To detect aseptic necrosis of the femur, it is not necessary to X-ray areas other than the hips and knees. The hips should be filmed in the A-P and frogleg lateral positions. For maximum trabecular detail, each side should be X-rayed separately.

In summary, a complete caisson worker's X-ray survey consists of two views of the shoulders, two views of the hips, and A-P and lateral views of each knee — a total of 12 films.

The U.S. Public Health Service is quite concerned about radiation from diagnostic X-ray, especially in large survey projects. In addition to gonadal shielding, therefore, pelvic shielding is also necessary, because of the bone-forming marrow present in the pelvis. Our present protocol has been approved by the U.S.P.H.S.

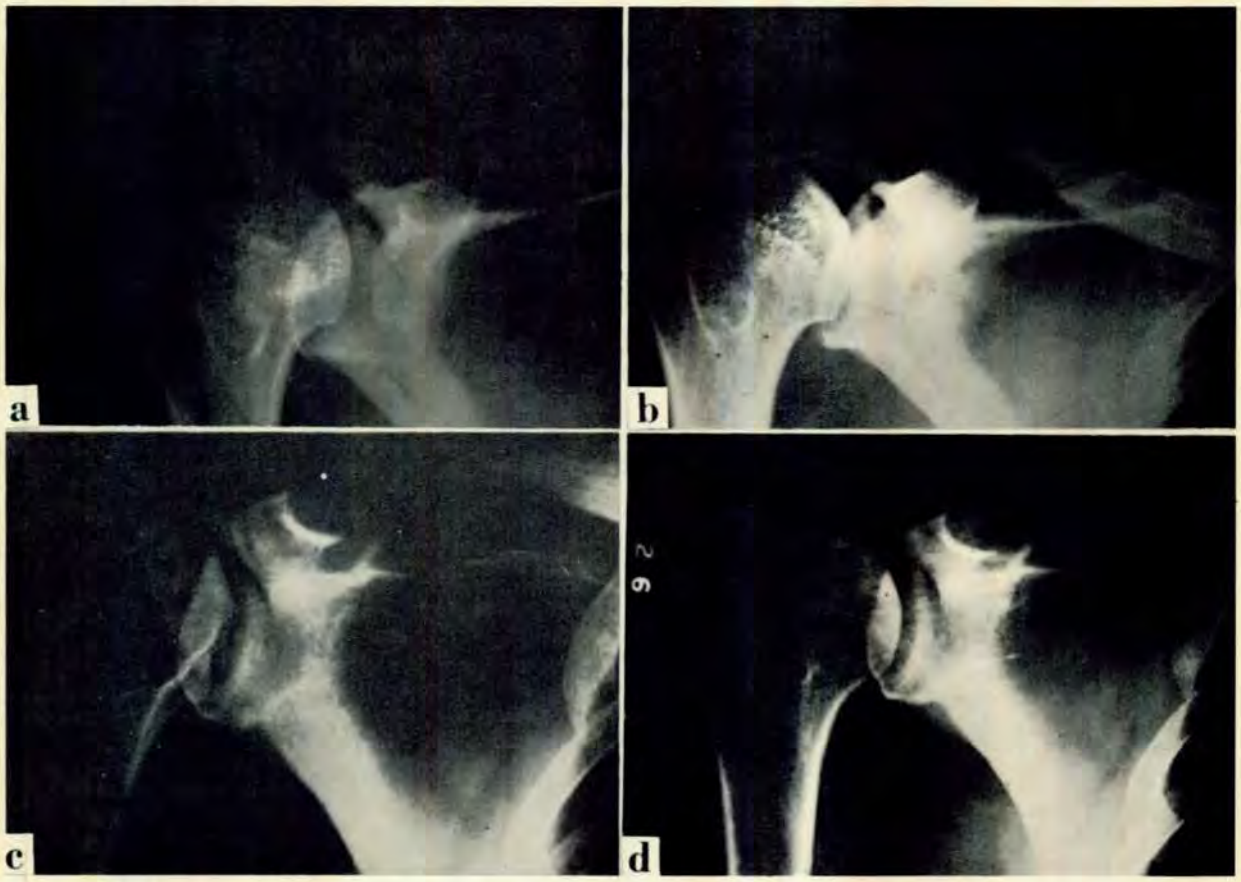

FIG. 1. (*a*) Shoulder of man who had suffered an attack of bends; (*b*) same shoulder one year later, during which time patient had worked in pressures up to 30 psig; (*c*), (*d*) X-rays of same shoulder with different rotation.

Figure 1 shows the shoulder of a man whom we first saw when he suffered an attack of bends. The film in 1*a* is poor, but after studying additional views we concluded that the shoulder was not diseased. The patient continued working a split shift at pressures up to 30 psig; a year later he was X-rayed again. Note the margin of sclerosis in 1*b*, which appeared in the juxta-articular view of the right shoulder after a period of one year. As stated, two views are now taken of the shoulder; the reason is well demonstrated in 1*c* and 1*d* — X-rays of the same shoulder, but with a different rotation. A large defect is visible in 1*d* on the superior aspect of the humeral head.

In Fig. 2*a* is a rather typical snowcap lesion, perhaps an early one. These snowcaps are quite common in aseptic osteonecrosis. In Fig. 2*b* is something we call a pseudosnowcap lesion. The superior medial aspect of the bone looks more dense than the area below it, but fades off with no line of demarcation. The trabeculae are visible on close examination; in our opinion, however, these changes may appear in normal people. The findings from this X-ray were not considered grounds for disqualifying the subject from further hyperbaric exposure.

A sizable sequestrum is seen in Fig. 3. This patient was symptomatic when he presented himself for examination. In Fig. 4 is a rather unusual phenomenon: a large sequestrum is visible in the hip. This man was absolutely asymptomatic when he came in for a routine X-ray before returning to work in compressed air. The articular space is normal and the articular cartilage is apparently intact, which probably accounts for his presently being pain-free. In all probability he will eventually have to have a prosthetic replacement.

Figure 5 shows the shoulders and hips of a patient who had maintained mining machinery under hyperbaric pressure. Figure 6 shows the same four joints of a man who actually had very little experience in compressed air, but did work at pressures greater than 16 psig. His hip joints have since collapsed completely. Figure 7 shows the shoulder of a man who worked as a miner with an air spade in his left hand. When he

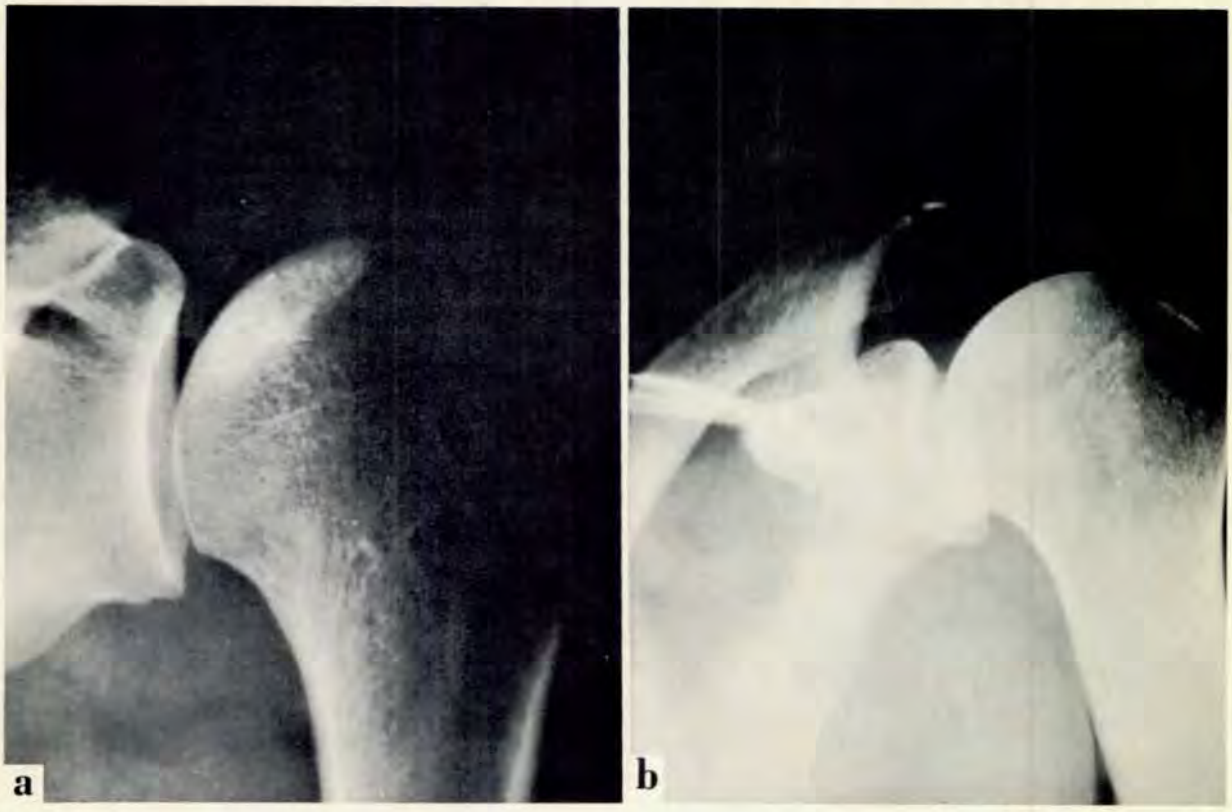

FIG. 2. (*a*) A typical snowcap lesion, common in aseptic osteonecrosis; (*b*) a pseudosnowcap lesion, which was not considered sufficient grounds to disqualify subject from further hyperbaric exposure.

FIG. 3. Sequestrum in cortex of humeral head.

could no longer lift the implement because of pain, he shifted it to his right hand and triggered it with his left. This offered a temporary solution to his problem and he kept working, despite his diseased left shoulder, for another three years. He felt that he merely had a severe case of arthritis.

FIG. 4. Sequestrum in hip of patient who was completely asymptomatic when he underwent routine X-ray.

Figure 8 is a very rare X-ray. Other than the series reported by El Ghawabi *et al.* (1971), only two or three lesions of the articular margin of the knee are cited in the world literature. Sclerosis in the distal shaft of the femur is commonplace. But sclerosis extending down all the way to the knee-joint margin, as seen here, is extremely rare. This man had symptoms of pain; in fact, the knee is that of the same man whose shoulder is shown in Fig. 7.

It is important to point out additional factors that possibly play a role in decompression sickness and aseptic necrosis. Comparisons of decompression tables are commonly made in terms of the length of *total decompression time*, which, although indeed important, is not the sole consideration. The entire *decompression profile* of any given table is of equal importance. The profiles of the Washington State tables are clearly inadequate in that they do not provide sufficient decompression time at intermediate pressures. The bends rate remains high. Those profiles call for the greatest decompression time (up to two hours) to be spent at pressures less than 4 psig, where bubble formation is quite likely to occur. In Milwaukee, we start decompressing directly from higher pressures by straight-line decompression from, say, 16 psig. Our men therefore spend significant decompression periods at the intermediate pressures. Once this protocol was introduced, the incidence of bends seemed to drop rather dramatically. Yet we have not shortened the tables in any way, for we wish to avoid further threat of aseptic bone necrosis.

Another possible contributory factor in bends or aseptic necrosis is the quality of the breathing atmosphere. The muck found in the Milwaukee tunnels produces large amounts of carbon dioxide when it comes into contact with compressed air. We find a definite correlation between a high CO_2 level in the tunnel and the incidence of bends among the workers. Thus it may be that decompression schedules alone cannot be depended upon to prevent the problems of bends and aseptic necrosis. Men using the new federal code, but working in contaminated air, could conceivably develop lesions of aseptic necrosis despite close adherence to adequate decompression schedules.

Regarding our management of these cases, we have borrowed freely from the experience of

FIG. 5. Shoulders and hips of a mining machinist, who had been exposed to hyperbaric pressure, showing extensive osteonecrosis of all four joints.

others and claim no innovations. We might differ somewhat with the British MRC recommendations (see D. H. Walder's "Management and Treatment" chapter, this volume) regarding a juxta-articular lesion. We always consider it potentially disabling until it has proven to be otherwise. Our opinion is that we are probably not seeing the entire lesion. As opposed to British practice, therefore, we give the man no choice; he is simply disqualified. If a man has a juxta-articular lesion in the shoulder, for example, he is no longer permitted to work in compressed air. Nor is he permitted to lift more than 25 lb. from the floor, or raise more than 10 lb. above his head, until it is demonstrated that there has been no disease progression. These are Dr. Jones's recommendations.

The author consulted with Prof. Roland

FIG. 6. Shoulders and hips of man with little history of hyperbaric work, but with exposure to pressures greater than 16 psig.

Barnes of Glasgow about treatment of these men; he is becoming more permissive, as are we. In the past when we came across a patient with four joints involved, we thought of prescribing bed rest. However, this is impractical, as one cannot keep a man bedridden for two or three years if he is otherwise in excellent health. Since the majority of these men are young, we are hesitant about implanting prostheses immediately, even in severely damaged joints. But when a lesion becomes too painful and the disability can no longer be tolerated, operative intervention is offered.

Finally, we have found that rehabilitation or retraining is largely a failure, despite the efforts of Wisconsin's very active State Employment and Rehabilitation Service. These men find it difficult to cooperate, as they often lack the adaptive ability to learn a different trade.

FIG. 7. Collapse of L humeral head of miner who operated air spade with his L hand.

FIG. 8. Lesion of femoral condyles of knee, with sclerosis extending down to knee-joint margin. Patient is the same one whose shoulder is shown in Fig. 7.

REFERENCE

El Ghawabi, S. H., Mansour, M.B., Youssef, F. L., El Ghawabi, M. H., and Abd El Latif, M. M. (1971). Decompression sickness in caisson workers. Brit. J. Ind. Med. 28, 323-329.

DECOMPRESSION TABLES IN RELATION TO DYSBARIC OSTEONECROSIS

CLAUDE A. HARVEY

INTRODUCTION

The possibility that individuals exposed to hyperbaric conditions may develop radiographic evidence of bone lesions after a latent period of several weeks or months is well recognized (McCallum *et al.*, 1966). The exact pathophysiology of dysbarism-induced osteonecrosis is not clear. Hills (this volume) has suggested the possibility that osmotic stresses generated during compression might be a contributing factor. The implications of this and other compression and isobaric phenomena of gas exchange cannot be discounted. But the present paper will be confined to the stresses of decompression and the possibility that dysbaric osteonecrosis is a form of decompression sickness, with delayed manifestations initiated by decompression procedures which were, in some way, inadequate.

The possibility that fatty bone marrow might exchange gas very slowly and thus gradually become dangerously supersaturated after several successive dives will be examined through use of a simple exponential gas-exchange model. Some limitations in this approach and certain implications of the findings will be discussed. So also will be certain theoretical and practical approaches to avoiding supersaturation and consequent gas formation in amounts potentially damaging to bone during decompression.

BACKGROUND

Many theoretical models have been proposed to describe the transport of inert gases within the body, the number of critical tissues that should be considered, and the constraints necessary to prevent decompression sickness. Several of these models have been used to develop decompression tables for animals and man, a few of which have proven reasonably safe for sport, commercial, military, and scientific diving purposes. Several investigators have compared decompression tables and their inherent assumptions, implications, and limitations (Hempleman, 1960; Schreiner and Kelley, 1966; Schreiner, 1967; Hills, 1970; Feld, 1971; Kidd *et al.*, 1971).

Many decompression tables in current use have evolved from concepts developed by Haldane and associates (Boycott *et al.*, 1908). Haldane treated the body as a group of discrete parallel mathematical compartments or half-time tissues that exchange inert gas in solution with the blood, which was assumed to be at equilibrium with the inspired gases. He also assumed that rates of inert-gas exchange in tissue compartments are functions of inert-gas solubility in various bodily tissues and of the blood perfusion rates in those tissues. He further assumed that diffusion of a gas in bodily tissues is very rapid, so that blood-perfusion rates limit tissue gas exchange. Haldane also predicted that when the partial pressure of gas in an individual tissue compartment, divided by the ambient pressure, exceeds a critical ratio (2:1), symptoms of decompression sickness might result. Many of these assumptions have since been challenged.

With the accumulation of experimental data in the intervening years, several modifications of Haldane's concepts have evolved. Tissues with longer half-times than Haldane considered were added and different critical ratios applied to them (Workman, 1965; Bühlmann, 1971; Schreiner and Kelley, 1971). Harvey (1951 *a* and *b*) and Behnke (1951) suggested that safe ratios for various tissues are also a function of depth.

Workman (1965) developed a more flexible approach, postulating for each tissue compartment a maximum allowable inert-gas tissue tension (called *M-value*) that would permit safe incremental changes to a lower ambient pressure. A matrix of M-values was developed and refined as experiments suggested that assumed gas tensions in particular tissues were, in fact, excessive and liable to cause symptoms of decompression sickness. Unfortunately, present-day knowledge of gas-exchange rates in bone and insufficient data on the incidence of osteonecrosis do not clearly identify those exposure profiles and gas tensions productive of that disease. Meaningful modification of Workman's (or any other) mathematical model, and the decompression tables based upon it, are therefore difficult.

However, certain clues are available. McCal-

lum *et al.* (1966) found that bone lesions in caisson workers are related directly to the number of times a man has been decompressed, to the pressure at which he has worked, and to symptoms of dysbarism for which treatment was given. Nellen and Kindwall (1972) reported that men decompressed twice daily during split-shift work have a higher incidence of osteonecrosis than workers decompressed once daily from a single, longer shift. These findings suggest inadequate decompression as the cause of bone lesions.

Lesions are typically found in the proximal humerus and in the proximal and distal ends of the femur (McCallum *et al.*, 1966), which have "yellow" marrow containing large amounts of fat. Because fatty marrow is assumed to be a "slow" tissue (Jones, 1951), decompression would cause a great supersaturation of dissolved nitrogen, which may persist for long periods of time. Further work is needed to reexamine and extend the work of Campbell and Hill (1933 *a* and *b*), who attempted to measure the rates of gas exchange in fatty marrow and other tissues. If fatty marrow is in fact a slow tissue, then one must establish the *slowest* tissues to be considered in calculating decompression tables.

Workman (1965) used a tissue half-time ($T_{1/2}$) of 240 minutes for the slowest tissue in computing the U.S. Navy Standard Air Decompression Tables. Schreiner and Kelley (1971) summarized several pieces of evidence justifying 400 to 500 minutes as the longest half-time compartment for N_2 exchange in the body. Bühlmann (1971) suggested 480 minutes for N_2 exchange. He used 640 minutes in calculating long decompressions after deep dives to compensate for sleeping and other variables that affect human physiology.

Thus if fatty marrow is considered a slow body tissue, and if damage can occur in marrow without the appearance of symptoms elsewhere, it seems necessary to consider gas accumulations in tissues with longer half-saturation times in recalculating standard air decompression profiles. A $T_{1/2}$ of 720 minutes was accordingly chosen by the Institute for Environmental Medicine, University of Pennsylvania — a figure exceeding the longest half-times suggested by earlier workers. Although arbitrarily chosen, the decompression tables were representative of those employed in diving and caisson work in recent years.

Accordingly, several representative tables were subjected to analysis by use of the PADUA* computer program. The program is based on a simple exponential gas-exchange formula (such as those frequently used in a perfusion-limited model of gas exchange).

For gas exchange during periods not involving a change in ambient pressure:

$$\pi_f = \pi_o + (PP_I - \pi_o) \cdot (1 - 2^{-\Delta t/H})$$

For gas exchange during periods involving a linear change in ambient pressure:

$$\pi_f = \pi_o + [(PP_I - mV\Delta t) - \pi_o] \cdot (1 - 2^{-\Delta t/H})$$

Symbols:

π_f = final tissue tension of inert gas
π_o = initial tissue tension of inert gas
PP_I = implied partial pressure
Δt = change in time
H = tissue half-time
m = mole fraction of inspired inert gas
V = velocity of ascent or descent

*Pennsylvania Analysis of Decompression for Undersea and Aerospace

PROCEDURE AND RESULTS

Two sets of M-values, those of Workman and PADUA, were used to calculate tissue tensions at the start of a "dive" and at "surfacing" (see Table I). M-values refer to maximum allowable tissue tensions of inert gas in units of feet of seawater absolute (FSWA). The slightly more conservative PADUA M-values are those employed recently at the Institute in calculating air decompression tables. PADUA M-values represent allowable tissue tensions for a subject's ascent from a final 10-feet-of-seawater (FSW) stop to surface in 10 seconds. Any calculated tissue tension higher than the corresponding M-value indicates that tissue supersaturation would be such that the subject could not surface without significant risk of developing dysbarism.

Table I. COMPARISON OF WORKMAN AND PADUA* M-VALUES ON SURFACING (IN FSWA)

Tissue half-times (min)	5	10	20	40	80	120	160	240	320	480	560	720
Workman	104	88	72	56	54	52	51	50				
PADUA	100	84	68	53	52	51	50	49	49	48	48	48

*PADUA — Pennsylvania Analysis of Decompression for Undersea and Aerospace computer program

The depths and times chosen permitted evaluation of the deeper and longer dives allowed by several commonly used tables (see Table II). (*N.B.*: Regarding Tables II and IV, the "surfacing" nitrogen tensions that exceed the allowable PADUA M-values for several tissues with different half-times — the unsafe supersaturation values — are enclosed in rectangles.) The Blackpool tables (1968) permit a 4-hr working time at 66 FSW, whereas the New York tables (1960) allow two 2-hr exposures to achieve the same 4-hr working time. With the Blackpool tables, 4-hr exposures produced maximum tissue tensions in the 120- and 160-min compartments. There were no M-value violations in tissue tensions upon surfacing in any compartment, even after 7 consecutive days of exposure. The New York table exposures (two 2-hr shifts) produced maximum tissue tensions in the 40- and 80-min tissues. They did not exceed the Workman M-values, although they did slightly exceed the PADUA M-values in the 40-, 80-, and 120-min tissues. The longer theoretical compartments again did not accumulate enough gas to exceed the surfacing M-values even after 7 consecutive days of exposure.

Exposures of 8 hr at 100 FSW were evaluated according to the British tables (1951) and Blackpool tables (1968). On the 1951 tables, maximum tissue tensions were reached on Day 1 in the 160-, 240-, and 320-min tissues, which exceeded M-values in all tissues having a $T_{1/2}$ of 80 min (or longer). Tissues with a $T_{1/2}$ longer than 320 min showed significantly higher gas tensions after Day 7 in comparison with Day 1. On the Blackpool tables the same series of daily 8-hr exposures produced maximum tensions in tissues with a $T_{1/2}$ of 320 min or longer, which slightly exceeded allowable M-values.

On the U.S. Navy tables (1963), 30-min exposures to 180 FSW twice daily for 7 days, with a surface interval of 277 min, produced maximum tissue tensions in the 40- to 120-min tissues. There were no M-value violations.

Under the U.S. Navy Standard Air Decompression Tables (1963) a second dive, following

Table II. COMPARISON OF N_2 TISSUE TENSIONS IN 12 THEORETICAL COMPARTMENTS RESULTING FROM SEVEN-DAY REPETITIVE PRESSURE EXPOSURES FOLLOWED BY DECOMPRESSION ACCORDING TO FIVE DIFFERENT TABLES

Tissue half-times (min)			5	10	20	40	80	120	160	240	320	480	560	720
			Tissue tensions of inert gas (FSWA)											
New York Tables	Day 1	Start	26	26	26	26	26	26	26	26	26	26	26	26
(1960)		Surfacing	30	35	46	54	54	52	50	46	43	39	38	36
66 ft, 2 hr	Day 7	Start	26	26	26	26	26	26	26	27	28	30	31	31
twice daily		Surfacing	30	35	46	54	54	52	50	46	40	41	40	39
British Tables	Day 1	Start	26	26	26	26	26	26	26	26	26	26	26	26
(1951)		Surfacing	28	29	33	43	59	68	71	71	68	61	58	53
100 ft, 8 hr	Day 7	Start	26	26	26	26	26	26	27	30	33	38	40	42
		Surfacing	28	29	33	43	59	68	71	72	70	66	65	63
Blackpool Tables	Day 1	Start	26	26	26	26	26	26	26	26	26	26	26	26
(1968)		Surfacing	26	26	26	27	31	37	42	49	51	52	51	49
100 ft, 8 hr	Day 7	Start	26	26	26	26	26	27	28	31	34	39	41	44
		Surfacing	26	26	26	27	31	37	42	49	53	55	56	56
Blackpool Tables	Day 1	Start	26	26	26	26	26	26	26	26	26	26	26	26
(1968)		Surfacing	27	29	31	38	47	50	50	47	44	40	39	37
66 ft, 4 hr	Day 7	Start	26	26	26	26	26	26	26	27	28	29	30	31
		Surfacing	27	29	31	38	47	50	50	47	45	42	41	40
U.S. Navy	Day 1	Start	26	26	26	26	26	26	26	26	26	26	26	26
Tables (1963)		Surfacing	34	34	39	47	49	47	45	42	40	37	36	34
180 ft, 30 min	Day 7	Start	26	26	26	26	26	26	26	27	28	29	30	30
twice daily		Surfacing	34	34	39	47	49	47	45	43	41	39	38	37

Table III. NITROGEN TISSUE TENSIONS (FSWA) AT START OF AND SURFACING FROM FOUR CONSECUTIVE 30-MIN SIMULATED DIVES TO 180 FSW, ACCORDING TO U.S. NAVY TABLES (1963)*

Tissue half-times (min)	5	10	20	40	80	120	160	240	320	480	560	720
	Tissue tensions of inert gas (FSWA)											
Dive 1, Start	26	26	26	26	26	26	26	26	26	26	26	26
Dive 1, Surface	34	34	35	40	49	50	50	46	44	39	38	36
Dive 2, Start	26	26	26	26	26	26	27	29	30	31	31	31
Dive 2, Surface	34	34	35	40	49	51	50	48	46	43	41	40
Dive 3, Start	26	26	26	26	26	26	27	29	30	32	32	33
Dive 3, Surface	34	34	35	40	49	51	50	48	46	43	43	41
Dive 4, Start	26	26	26	26	26	26	27	29	30	32	33	34
Dive 4, Surface	34	34	35	40	49	51	50	48	46	44	43	42
Dive 5, Start	26	26	26	26	26	26	27	29	30	32	33	34

*All "dives" separated by 12-hr "surface" interval

a surface interval longer than 12 hr, is not subject to the rules of repetitive diving. Table III sets out the tissue tensions at the start and finish of each of 4 consecutive 30-min dives to 180 FSW separated by 12-hr surface intervals.

The same series of dives was made to 190 FSW for 60 min, the longest and deepest dive permitted by the U.S. Navy decompression tables (see Table IV). Maximum tensions developed in the 40-min tissues on the 190-FSW exposures and exceeded the PADUA M-value for 40-min tissues on each dive while approximately equaling the Workman M-value. Maximum tension developed in the 120-min tissue on the 190-FSW dives, but no M-values were exceeded after 4 dives.

Tables II, III, and IV indicate that theoretical gas tensions accumulated in longer half-time tissue compartments may approach or exceed the supersaturation considered permissible with the M-values adopted. In general, however, analysis suggests that these tables — with the exception of the now discarded 1951 British tables, which were included merely for com-

Table IV. NITROGEN TISSUE TENSIONS (FSWA) AT START OF AND SURFACING FROM FOUR CONSECUTIVE 60-MIN SIMULATED DIVES TO 190 FSW, ACCORDING TO U.S. NAVY TABLES (1963)*

Tissue half-times (min)	5	10	20	40	80	120	160	240	320	480	560	720
	Tissue tensions of inert gas (FSWA)											
Dive 1, Start	26	26	26	26	26	26	26	26	26	26	26	26
Dive 1, Surface	34	38	50	57	52	47	43	38	36	33	32	31
Dive 2, Start	26	26	26	26	26	26	27	28	28	28	28	28
Dive 2, Surface	34	38	50	57	52	47	43	40	37	35	34	33
Dive 3, Start	26	26	26	26	26	26	27	28	28	29	29	29
Dive 3, Surface	34	38	50	57	52	47	43	40	38	36	35	34
Dive 4, Start	26	26	26	26	26	26	27	28	29	29	30	30
Dive 4, Surface	34	38	50	57	52	47	43	40	38	36	35	34
Dive 5, Start	26	26	26	26	26	26	27	28	29	30	30	30

*All "dives" separated by 12-hr "surface" interval

parison — are reasonably safe, even when used on a daily basis. The qualification is that there must be a minimum surface interval of 12 hr between dives; otherwise they are considered repetitive.

DISCUSSION

The implication of the foregoing calculations may be misleading. Supersaturation in bone marrow may produce damage at gas-tension levels below those causing symptoms of dysbarism elsewhere in the body. Thus M-values for the longer half-time tissues, in particular, may need revision downward.

Hempleman (1960) demonstrated that the rates of N_2 uptake and elimination are unequal. He suggested that "silent" bubbles might form in tissues during decompression, altering the kinetics of gas exchange. The modified Haldane approach is based on the assumption that the rate of gas uptake varies exponentially with time and that several different tissues are involved. Hempleman theorized that the uptake curve is a complex equation represented by a sum of exponentials, and that only one type of tissue is involved. (This model assumes that gas diffusion, rather than tissue perfusion, is the rate-limiting factor for gas exchange in the body.)

Neither the diffusion nor perfusion theory allows for Hempleman's observation that a "discontinuity in the body physics takes place when large and rapid drops in pressure occur." He therefore suggests that separate theories are necessary for inert-gas uptake and elimination. Bornmann (1970) and Summitt *et al.* (1970) approached the problem of repetitive excursion dives from saturated depths on He–O_2 mixtures by calculating uptake according to a 200-min $T_{1/2}$ during excursions and gas elimination according to a 240-min $T_{1/2}$ during the surface interval. Bühlmann (1969) used a 480-min $T_{1/2}$ for N_2 uptake and elimination, but altered the figure to 640 min during sleep.

This inequality of uptake and elimination raises a serious doubt about the validity of calculations based on a conventional exponential equation, as was used to produce the values shown in Tables II, III, and IV. This error could be compounded by repetitive dives.

Kidd and Stubbs (1969) have pointed out that the pneumatic analogue computer offers efficient decompression protocol from random profile dives and repetitive exposures. They have commented, as well, that the computer seems to have an inherent asymmetry similar to that operating in man during gas uptake and elimination.

There is a body of evidence suggesting that "silent" bubbles and gas separation occur in routine asymptomatic decompression (Behnke, 1967). Mackay and Rubissow (1971), employing pulsed ultrasonic energy and the Doppler shift principles, have discussed techniques for studying the occurrence of bubbles and masses of gas within the body. Kidd and Stubbs (1969) noted a small but significant (0.5 dB) ultrasonic signal change during ascent when inert-gas tension, computed by their MkVS pneumatic analogue computer, approximated ambient pressure. A strong signal change (7 dB) was always observed prior to the occurrence of obvious bends symptoms. However, they also noted many instances of 3- to 5-dB signal changes when no symptoms were experienced.

The significance of these silent bubbles is not clear, but repeated showers of bubbles or emboli may be more important in the development of osteonecrosis than a single insult. Stegall and Smith (1972) used repeated exposures to develop lesions in miniature swine. Repetitive dive schedules may therefore need more conservative criteria in their calculations than schedules designed for less frequent use. Further refinement of ultrasonic techniques may make it possible to tailor each decompression protocol to the individual diver by monitoring him constantly.

Behnke (1967) has discussed the principles of isobaric ("oxygen window") decompression, a technique that theoretically avoids bubble formation but "calls for too long a decompression for dives up to one-hour duration, unless it is feasible to breathe pure oxygen for a prolonged period at the +15 psi pressure level." He points out that lengthy half-times, such as those analyzed in Tables II, III, and IV herein, seem much too long to be consistent with the limited physiological data available on N_2 elimination in man. They have been employed, he suggests, only because models used to calculate tables may have questionable physiologic bases. Behnke adds: "It is likely that decompression practice in the past has served to initiate bubble evolution which subsequently has been controlled by prolonged stage decompression at relatively shallow depths."

If these silent bubbles do, in fact, precipitate dysbaric osteonecrosis, tables must be calculated that rely less on ratio principles and, instead, adhere more closely to the O_2-window principle of decompression — even at the cost of longer

stops at the early, deep stages of decompression. No valid data exist on the circulatory changes induced in bone by high-pressure O_2 or on the sensitivity of fatty bone marrow to O_2 toxicity. Such factors might influence the use of high Po_2 to speed inert-gas elimination during decompression.

Hills (1966; 1968; 1970) has suggested that a small amount of gas separation can occur in many tissues without causing symptoms, and that the process is random. His analysis (1970) summarizes several empirical approaches used in the perfusion and diffusion models of inert-gas exchange to allow for the inequality in gas exchange.

Hills also defines an important basic issue in formulating decompression tables. Gas in physical solution is lost from a supersaturated tissue by a conventional exponential format, whereas a very different driving force eliminates gas separated from solution. Conventional supersaturation models keep divers at as shallow a depth as is consistent with their permissible supersaturation; by contrast, Hills's "phase equilibration" model suggests that much deeper staging is needed. The successful use of surface decompression is also explained by the concept of phase equilibration, whereas the concept of acceptable supersaturation makes it hard to explain why there is not more difficulty with bubble formation during the surface interval. Gas formation in the rigid confines of a bone has a more devastating effect than in many other tissues. Unfortunately, the degree to which gas separates from solution in bone marrow during commonly used decompression procedures is unknown.

Harvey *et al.* (1944) and Aggazzotti and Ligabue (1942) suggested the importance of preexisting gas nuclei in gas-bubble formation. Walder (1969) has suggested that reducing the number of these nuclei by repeated decompressions might explain the observation that divers are more resistant to dysbarism when they have been diving regularly (*e.g.*, daily). Hills (1970) has offered an alternative explanation — namely, that successive formation and elimination of a stable-gas phase could cause a fall in the "elastic modulus" of a critical tissue and, hence, in the pressure differential between gas and tissue, tending to distort a nerve ending beyond its pain-provoking threshold.

Walder's theory would permit less conservative decompression procedures during the later dives of a series than in earlier ones. Hills's theory, on the other hand, suggests following the same protocol in every dive, since rigid bone structures might be less capable of change in elastic modulus than many other tissues would. Repeated insults might therefore produce permanent damage to bone.

Use of a gas (or a combination of gases) other than N_2 for hyperbaric work would modify the concepts discussed in this paper. Modification would depend on many physical characteristics — *e.g.*, partition coefficient, fat solubility, oil–water solubility ratios, molecular weight, and molecular size of the specific gas. The exact risk of developing dysbaric osteonecrosis in helium, neon, or hydrogen exposures on existing tables following dives deeper than 200 FSW is not known. Until further data are accumulated, the risk cannot be predicted accurately.

The effect of mixing or switching inert gases for the purpose of shortening total decompression time (Bühlmann *et al.*, 1967) as a causative mechanism in the production of osteonecrosis is also open to question. (Cutaneous, vascular, and vestibular manifestations have recently been observed by Idicula *et al.* [1972] in studying isobaric skin–gas exchanges involving different inert gases.)

Yet to be explored is the possibility that bone marrow saturated with a slowly exchanged gas (such as N_2) might become temporarily supersaturated should the subject begin breathing a "fast" gas (such as He). This possibility might have a limiting effect on the development of tables for diving with multiple inert gases, although Keller and Bühlmann (1965) have demonstrated that decompression time might be shortened by breathing mixed gases.

Alteration in blood components relative to diving and silent bubbles has been reported (Philp *et al.*, 1972). Stegall and Smith (1972) reported alterations in blood constituents in mini-pigs that developed dysbaric osteonecrosis. Further studies of blood–bubble interactions may give additional insight into the pathophysiology of osteonecrosis and the stresses that must be limited or avoided altogether during decompression.

SUMMARY

In areas of developing dysbaric osteonecrosis, bone marrow probably exchanges inert gas slowly. Lesions have developed even with tables of apparent safety — as evaluated in terms of incidence of dysbarism or by a simple exponential gas-exchange model (as used in the modified Haldane perfusion-limited model). Inequality in

gas uptake and elimination, as well as the low tolerance of bone for inert-gas supersaturation, may precipitate development of lesions when present-day decompression tables are followed. Showers of silent embolic bubbles during repeated decompressions may also be contributory factors, possibly because of secondary changes in blood constituents. Reflex circulatory and toxic changes in bone from an elevated Po_2 need further evaluation. Inert-gas exchange rates and the consequences of mixing or switching inert gases should also be studied in many tissues.

A reasonable approach to the modification of current decompression practices might reasonably include *1*) more positive consideration of tissues with longer half-times; *2*) reduction of supersaturation in those tissues; and *3*) greater emphasis on the inequality of inert-gas uptake and elimination. Of possible importance, as well, would be efforts to decrease the separation of gas from solution into a gas phase (silent bubbles) by using deeper decompression stages, by closer adherence to the O_2 window principle of decompression, and by monitoring with ultrasonic techniques — particularly in repetitive diving.

However, expenditure of the large amounts of time, money, and energy required to arbitrarily modify and retest existing tables seems inefficient until a better understanding of the pathophysiology of dysbaric osteonecrosis helps reduce the choice of modifications. Meanwhile, a central registry to collect data on cases in the United States would allow a better evaluation of existing decompression tables. Statistical relationships could be established that might suggest certain changes that would make existing tables safer.

REFERENCES

Aggazzotti, A., and Ligabue, L. (1942). Azione dell'aria compressa sugli animali. XX. L'elasticita di volume del sangue e dei tessuti. Ball. Soc. Ital. Biol. Sper. 17, 479.

Behnke, A. R. (1951). Decompression sickness following exposures to high pressures. In Decompression Sickness. Ed. Fulton, J. F. London and Philadelphia: Saunders.

Behnke, A. R. (1967). The isobaric (oxygen window) principle of decompression. Transactions of the Third Annual MTS Conference and Exhibit, San Diego, California.

Blackpool tables. (1968). "Blackpool" Trial Decompression Tables, Royal Naval Physiological Laboratory, Alverstoke, Hants.

Bornmann, R. C. (1970). Decompression schedule development for repetitive saturation-excursion helium-oxygen diving. Res. Rep. 1-70, Dept. of the Navy, D.S.S.P. Office, Bethesda, Md.

Boycott, A. E., Damant, G. C. C., and Haldane, J. S. (1908). The prevention of compressed-air illness. J. Hyg., Camb. 8, 342-443.

British tables. (1951). Revised Preliminary Draft of Regulations as to Safety, Health and Welfare in Work of Engineering Construction, Ministry of Labour and National Service.

Bühlmann, A. A. (1969). The use of multiple inert gas mixtures in decompression. In The Physiology and Medicine of Diving and Compressed-air Work. Ed. Bennett, P. B., and Elliott, D. H. Baltimore: Williams and Wilkins.

Bühlmann, A. A. (1971). Decompression in saturation diving. In Underwater Physiology. Ed. Lambertsen, C. J. New York and London: Academic Press.

Bühlmann, A. A., Frei, P., and Keller, H. (1967). Saturation and desaturation with N_2 and He at 4 atm. J. Appl. Physiol. 23, 458-462.

Campbell, J. A., and Hill, L. (1933*a*). Studies in saturation of the tissues with gaseous nitrogen. I. Rate of saturation of goat's bone marrow *in vivo* with nitrogen during exposure to increased atmospheric pressure. Quart. J. Exptl. Physiol. 23, 197-210.

Campbell, J. A., and Hill, L. (1933*b*). Studies in saturation of the tissues with gaseous nitrogen. III. Rate of saturation of goat's brain, liver, and bone marrow *in vivo* with excess nitrogen during exposure to +3, +4, and +5 atmosphere pressure. Quart. J. Exptl. Physiol. 23, 219-227.

Feld, J. N. (1971). A dissertation in biomedical electronic engineering. Ph.D. dissertation, Grad. School A and S of the Univ. of Penn.

Harvey, E. N. (1951*a*). Physical factors in bubble formation. In Decompression Sickness. Ed. Fulton, J. F. London and Philadelphia: Saunders.

Harvey, E. N. (1951*b*). Animal experiments on bubble formation. I. Bubble formation in rats. In Decompression Sickness. Ed. Fulton, J. F. London and Philadelphia: Saunders.

Harvey, E. N., Barnes, D. K., McElroy, W. D., Whiteley, A. H., Pease, D. C., and Cooper, K. W. (1944). Bubble formation in animals. I. Physical factors. J. Cellular Comp. Physiol. 24, 1-22.

Hempleman, H. V. (1960). The unequal rates of uptake and elimination of tissue nitrogen gas in diving. Procedures U.P.S. 195, R.N.P. 62/1019.

Hills, B. A. (1966). A thermodynamic and kinetic approach to decompression sickness. Libr. Board of S. Australia, Adelaide.

Hills, B. A. (1968). Relevant phase conditions for predicting occurrence of decompression sickness. J. Appl. Physiol. 25, 310-315.

Hills, B. A. (1970). Vital issues in computing decompression schedules from fundamentals. Intern. J. Biometeor. 14, 111-131.

Idicula, J., Graves, D. J., Quinn, J. A., and Lambertsen, C. J. (1972). Bubble formation resulting from steady counterdiffusion of two inert gases. In Proceedings of the Fifth Symposium on Underwater Physiology. (In Press).

Jones, H. B. (1951). Preoxygenation and nitrogen elimination: Pt. II. Gas exchange and blood-tissue perfusion factors in various body tissues. In Decompression Sickness. Ed. Fulton, J. F. London and Philadelphia: Saunders.

Keller, H., and Bühlmann, A. A. (1965). Deep diving and short decompression by breathing mixed gases. J. Appl. Physiol. 20, 1267-1270.

Kidd, D. J., and Stubbs, R. A. (1969). The use of the pneumatic analogue computer for divers. In The Physiology and Medicine of Diving and Compressed-air Work. Ed. Bennett, P. B., and Elliott, D. H. Baltimore: Williams and Wilkins.

Kidd, D. J., Stubbs, R. A., and Weaver, R. S. (1971). Comparative approaches to prophylactic decompression. In Underwater Physiology. Ed. Lambertsen, C. J. New York and London: Academic Press.

McCallum, R. I., Walder, D. N., Barnes, R., Catto, M. E., Davidson, J. K., Fryer, D. I., Golding, F. C., and Paton, W. D. M. (1966). Bone lesions in compressed air workers. J. Bone Joint Surg. 48-B, 207-235.

Mackay, S., and Rubissow, G. (1971). Detection of bubbles in tissue and blood. In Underwater Physiology. Ed. Lambertsen, C. J. New York and London: Academic Press.

Nellen, J. R., and Kindwall, E. P. (1972). Aseptic necrosis of bone secondary to occupational exposure to compressed air: Roentgenologic findings in 59 cases. Amer. J. Roentgenol., Radium Therapy Nucl. Med. 115, 512-524.

New York tables. (1960). Work in compressed air. The Industrial Code Rule No. 22 as Amended Effective Oct. 15, 1960, State of New York, Dept. of Labor, Board of Standards and Appeals.

Philp, R. B., Inwood, M. J., and Warren, B. A. (1972). Interactions between gas bubbles and components of the blood: Implications in decompression sickness. Aerospace Med. 43, 946-953.

Schreiner, H. R. (1967). Mathematical approaches to decompression. Intern. J. Biometeor. 11, 301-310.

Schreiner, H. R., and Kelley, P. L. (1966). Computation methods for decompression from deep dives. In Proceedings of the Third Symposium on Underwater Physiology. Ed. Lambertsen, C. J. Baltimore: Williams and Wilkins.

Schreiner, H. R., and Kelley, P. L. (1971). A pragmatic view of decompression. In Underwater Physiology. Ed. Lambertsen, C. J. New York and London: Academic Press.

Stegall, P. J., and Smith, K. H. (1972). The etiology and pathogenesis of decompression sickness: Radiographic, hematologic and histologic studies in swine. In Proceedings of the Fifth Symposium on Underwater Physiology. Ed. Lambertsen, C. J. (In Press).

Summitt, J. K., Alexander, J. M., Flynn, E. T., and Kulig, J. W. (1970). Repetitive excursion dives from saturated depths on helium-oxygen mixtures. Phase IV: Saturation depth 500 feet and saturation depth 600 feet. Res. Rep. 8-70, U.S. Navy Experimental Diving Unit, Washington, D.C.

U.S. Navy tables. (1963). In U.S. Navy Diving Manual (1970). NAVSHIPS 0994-001-9010, Navy Department, U.S. Govt. Printing Office, Washington, D.C.

Walder, D. N. (1969). The prevention of decompression sickness in compressed-air workers. In The Physiology and Medicine of Diving and Compressed-air Work. Ed. Bennett, P. B., and Elliott, D. H. Baltimore: Williams and Wilkins.

Workman, R. D. (1965). Calculation of decompression schedules for nitrogen-oxygen and helium-oxygen dives. Res. Rep. 6-65, U.S. Navy Experimental Diving Unit, Washington, D.C.

DISCUSSION 3

Dr. HILLS: What rates of compression were used in the Washington tables, and what was the rate of decompression to the first stop?

Dr. SEALEY: The first stop was always a 13-psi drop in 3 min. The compression rate was not more than 5 psi per min, generally straight-line. It would take about 6 min to go in at 30 to 32 psi.

Dr. KINDWALL: It is clear that there is a great difference between compressed-air workers and divers when it comes to air quality. It is impossible in a tunnel to provide air of good quality when cutting, welding, and burning are going on. Diesel fumes from the surface are also a problem with regard to contamination of not only the tunnel's fresh-air supply but also the pneumatic-tool air, which is often overlooked. Nitrogen oxides produced by diesel engines can throw off any decompression-table calculations. These fumes reaching tunnel workers can cause pulmonary edema, which tends to block N_2 elimination. High CO_2 levels cause high bends rates.

It is not adequate to specify in a contract, as is presently done, a certain number of cubic feet of air per man in a tunnel. Serious consideration must also be given to contaminant levels and air quality. And the levels specified in the new federal regulations have not taken into account the fact that men working at 30 psi are exposed, in effect, to three times the contaminants that would exist in the same atmosphere at sea-level pressure. This fact, incidentally, was brought out before the regulations were promulgated, but was ignored.

Dr. SEALEY: Washington State standards have very strict air-quality standards limiting CO_2 and nitrogen oxides. In fact, we do not allow diesel equipment underground; electric or compressed-air power is used. The only time that significant CO_2 or oxides of N_2 levels developed was during a tunnel fire caused by an electric arc.

Dr. McCALLUM: I understood Dr. Kindwall to say that when CO_2 in a working area rises to high levels, the incidence of bends is much higher. I feel that he cannot just leave the matter there, because he must convince us that he has dealt with all the other variables controlling the incidence of bends after decompression. We have no figures on CO_2 in working areas, but in a decompression lock we consider it safe to 2% at 1 atm.

Dr. KINDWALL: The tunnel contract on which we have had the highest incidence of bends involves a company that is grossly underfunded and therefore does not have adequate compressor capacity to keep the CO_2 levels down. I visited their tunnel and found the working conditions just about identical to those of other companies, except that one could literally feel the heaviness of air contaminants. We and the state inspectors have checked for CO, N_2 oxides, oil mist, CO_2, and so on, and have usually found them to be within normal limits — although CO_2 levels do sometimes rise.

After having no cases of decompression sickness for about a week and a half, in one night we had three men with bends. I had a gas sample taken from the tunnel immediately and found a CO_2 content of 5600 ppm, although we insist that the maximum not exceed 2500 ppm, or 0.25%, at pressures greater than 2 atm abs. When CO_2 was reduced, the bends rate fell. We had a similar case in which four men got bends after working in a poorly ventilated area about 40 ft ahead of the air supply.

Dr. WALDER: We compared the bends rate of a group of welders with that of all other compressed-air workers and found it significantly higher. They were using a welding process that generates nitrogen dioxide.

Mr. GALERNE: I should like to revert to the CO_2 problem as it applies to divers. A few years ago we found that, if you oblige a diver to stay at rest for the last minute on bottom before coming up, the bends rate is tremendously suppressed.

We think that this is connected with CO_2, which is very unstable. If a man exhausts himself on the bottom, he gets a bubble of CO_2 on ascent, which stops the perfusion at some place and provokes poor local decompression. But resting on the bottom one minute removes 80% of the CO_2 from his blood and avoids a lot of trouble.

Dr. ELLIOTT: It is worth adding that André Galerne speaks from the extensive experience of his team of divers, whom he employs continuously and not seasonally.

Dr. WORKMAN: I have known for some time of statements by Dr. Jones and Dr. Sealey that they had no clinical or X-ray evidence of osteonecrosis in their men, implying that the decompression procedures used effectively prevented it, particularly after initial screening. How good is their evidence for this? Did they in fact conduct bone surveys over a sufficient period of time to make such a statement without qualification?

Dr. JONES: The concept promulgated in the literature is that the vast majority of those lesions destined to develop the classical roentgenographic manifestations of osteonecrosis will do so within six years of the known causative insult. The BART studies are only preliminary, since compressed-air exposure terminated in May 1969. Dr. Behnke and I are continuing these studies, but we must wait two to three more years for the final results. A program of incentives, or possibly some form of legislation, is necessary to obtain follow-up examinations of compressed-air workers in the United States. This is a highly paid, migratory labor group, certain members of which present fraudulent histories.

Dr. SPENCER: I should like to discuss the use of the Doppler blood-bubble detector in the prevention of decompression illness, including dysbaric osteonecrosis, which so far has not been dissociated from gas embolism at this meeting. The Doppler ultrasonic detection system can individualize a decompression schedule and inform the physician or attendant before serious trouble occurs. It has four main advantages: it is the only objective system that works, it is inexpensive, it operates simply, and it is safe. I should like to elaborate a bit.

The system works by detecting a Doppler shift frequency from a moving acoustical interface, such as a gas–plasma interface, which is a perfect reflector. It does have a limitation in that the interface must be in motion; that is, at the present state of its development it will not detect a static bubble (Spencer and Campbell, 1968; Spencer *et al.*, 1969; Spencer and Clarke, 1972).

It is exquisitely sensitive to very small bubbles. How small, exactly, we do not know, but at least down to 20 μ. A peripheral sensor on the extremities detects presymptomatic bubbles moving in the venous blood before they occur in arterial blood in air embolism. We have very recently developed a precordial detector that will spot all gas bubbles returning to the heart and passing through the right ventricular outflow tract.

We have found no symptoms of decompression illness without venous gas embolism. In all our experimental dives, in chambers and in the water, decompression sickness is always preceded by venous bubbles, which appear before symptoms.

We have frequently been asked about the safety of the detector. We supply 10 milliwatts of power to the crystal placed over the heart, which we have calculated can produce no more than 5 microwatts of sound power by the time it reaches 2 cm depth. Converted to sound pressure, this energy is several orders of magnitude less than the heart itself generates at each beat. In a recent experiment, one of two people exposed at 30 ft for 12 hr had definite bubbles, which lasted 2 to 3 hr.

Dr. WALDER: In a saturation dive to 200 meters, we used a Doppler scanning device placed over the right ventricle of the diver's heart. We heard a shower of bubbles following each change of pressure during decompression. Toward the end of the dive, bubbles were quite profuse. This dive was designed to be safe and, in fact, did not result in any decompression sickness.

Dr. ELLIOTT: I think that ultrasound in decompression has a very high research priority, although it will probably not be easy to correlate showers of bubbles with short-term — to say nothing of long-term — decompression inadequacy.

REFERENCES

Spencer, M. P., and Campbell, S. D. (1968). Development of bubbles in venous and arterial blood during hyperbaric decompression. Bull. Mason Clinic 22, 26-32.

Spencer, M. P., Campbell, S. D., Sealey, J. L., Henry, F. C., and Lindbergh, J. (1969). Experiments on decompression bubbles in the circulation using ultrasonic and electromagnetic flowmeters. J. Occupational Med. 11, 238.

Spencer, M. P., and Clarke, H. F. (1972). Precordial monitoring of pulmonary gas embolism and decompression bubbles. Aerospace Med. 43, 762-767.

PART III

PATHOPHYSIOLOGY OF OSTEONECROSIS

Preceding page blank

THE METABOLISM OF BONE

WILLIAM P. DEISS, JR.

There is no body of information on the metabolic events underlying dysbarism-related osteonecrosis. This paper will focus on the metabolism of normal bone in the hope that it will assist toward an eventual understanding of this interesting disorder. Figure 1 is a greatly simplified

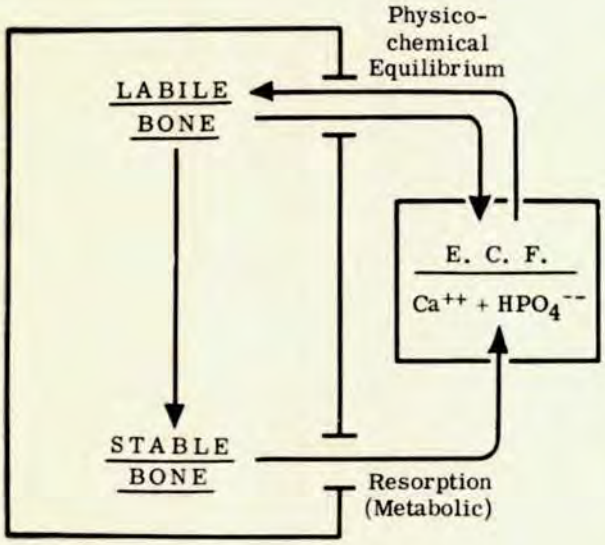

FIG. 1. Simplified diagram showing relationship between bone minerals and extracellular fluid.

diagram showing the relation between the mineral phase of bone and extracellular fluid. A physicochemical equilibrium governs the exchange between mineral ions (*e.g.*, Ca^{++} and HPO_4^{--}) in solution and in bone salts, an exchange that is independent of active metabolic processes. This phenomenon is readily demonstrable by dead bone, which extracts calcium from the bathing medium or liberates calcium into it, until an equilibrium point is reached, although that point is below the one maintained by living bone. In actively metabolizing bone, cellular activity is directed toward synthesizing the organic phase and properly mineralizing it with the crystals associated with mature bone. Simultaneously, other cells are actively engaged in resorbing this bone, so that in a steady state there is a balance between synthesis and resorption. These are the events that reflect the metabolism of living bone.

Figure 2 presents diagrammatically some of the major metabolic activities involved in the biosynthesis of the organic matrix of bone. One can say that, generally speaking, the osteoblast seems primarily responsible for synthesizing the polypeptide chains that eventually join to form triple-helical collagen fibrils, which are extruded into the extracellular spaces. Characteristically gellike, these spaces are filled with a matrix or ground substance composed of mucoproteins, or proteoglycans.

These events can be measured most accurately in various *in vitro* systems, including tissue cultures. The results of one such experiment are shown in Fig. 3 (Deiss *et al.*, 1962; Johnston *et al.*, 1962), in which rat bones were incubated in a simple buffer with labeled glucose. Labeled glucose is incorporated by bone cells into insoluble matrix components. In the presence of 95% oxygen, the synthesis is approximately a rectilinear function. When bones are preboiled, of course, there is no synthesis. Under a nitrogen atmosphere, the biosynthesis of these ground-substance constituents is greatly inhibited. It

Table I. CALVARIUM CARBOHYDRATE METABOLISM

Glucose consumption	=	0.33μ moles/100 mg/hr
Lactate production	=	0.50μ moles/100 mg/hr
Matrix hexosamine synthesized	=	0.0023μ moles/100 mg/hr (or 1% of the glucose utilized)
Since matrix hexosamine pool	=	0.40μ moles
then turnover	=	0.5%/hr, or
half-turnover time	=	4 days

Preceding page blank

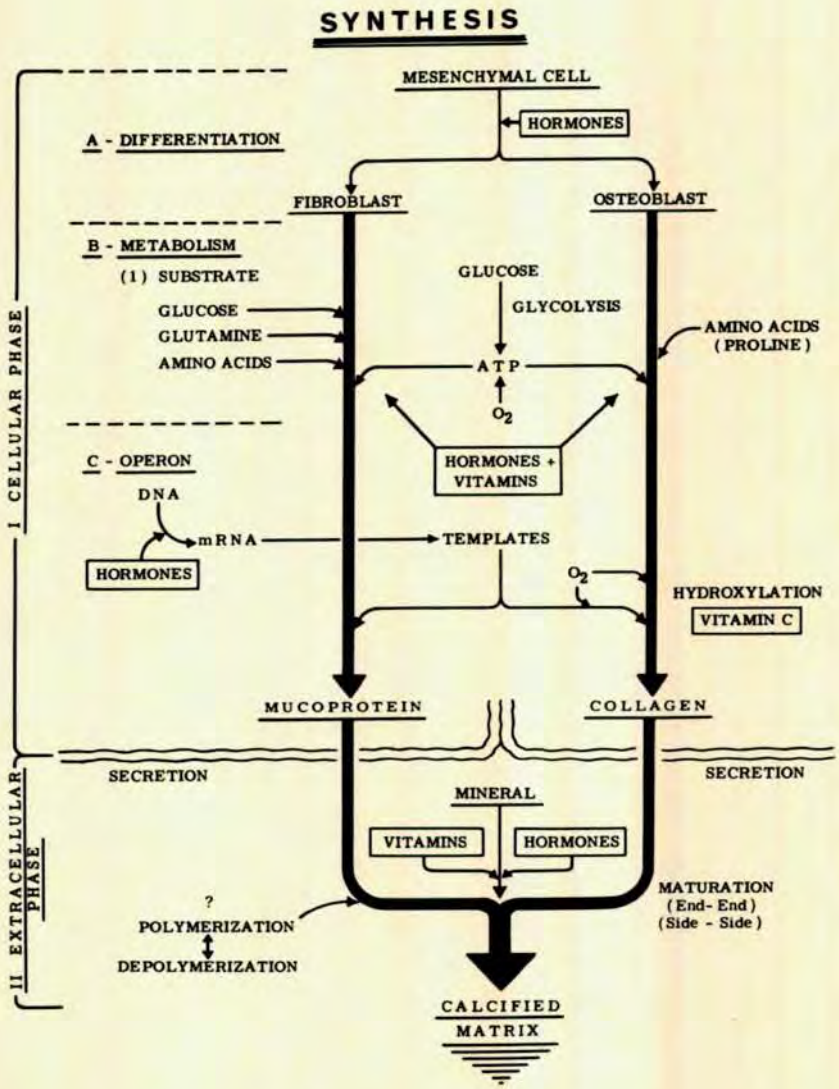

FIG. 2. Schematic diagram of biosynthetic events involved in producing mature calcified matrix of bone.

has additionally been shown (unpublished data) that, in a similar *in vitro* system, both labeled glucose and labeled glucosamine are incorporated by bones into the large molecular-weight glycoproteins and sialoproteins, as well as into hyaluronic acid and chondroitin sulfates.

Table I sets out a semiquantitative estimate of glucose consumption and lactate production in similarly incubated bones.

The table demonstrates something interesting about bone-cell metabolism, something that differs somewhat from other tissue metabolism. If the total glucose consumed by bone is calculated and expressed as a function of the number of cells involved, it becomes obvious that bone cells are avid consumers of glucose. A second rather interesting feature is that bones have a very active glycolytic pathway, as is evident from the large accumulation of lactate produced from the glucose. Flanagan and Nichols (1965*a* and *b*) made the same observation in their study of human bone. Table I also demonstrates that, by using calculations of *in vitro* matrix-hexosamine pool biosynthesis, one can show that the pool has a biological half-turnover time of about four days.

Similar studies (Deiss *et al.*, 1962) of bone *in vitro* have demonstrated the biosynthesis of the major constituent of bone matrix, collagen, from the labeled precursor proline. Bone cells transport this amino acid and incorporate it into the polypeptide chains of protocollagen. There it is hydroxylated to hydroxyproline and eventually matures into the insoluble collagen of the matrix (see Fig. 4). The amount of collagen formed is in part a function of the availability of an energy substrate. An optimum rate of synthesis is reached at about the equivalent of the physiologic blood glucose of man. When the glycolytic pathway is interrupted by the addition of iodoacetate or a nitrogen atmosphere, collagen synthesis is markedly reduced. By contrast, when the Krebs cycle is interrupted by the addition of fluoroacetate, there is little inhibition of collagen biosynthesis. Using the same *in vitro* system, one can make some crude calculations about the pool size of bone collagen. It can be similarly calculated that the collagen pool turns over at a very slow rate, its biological half-time being about 100 days (see Table II).

Turning from general bone biosynthesis, one might look briefly at some elements of bone resorption that are modulated by cellular and metabolic events. Figure 5 shows the cellular and extracellular compartments in the degradation scheme of the calcified matrix. How do cells modify these events? We can say specifically that, for effective bone resorption, there must be an active glycolytic pathway with lactate production.

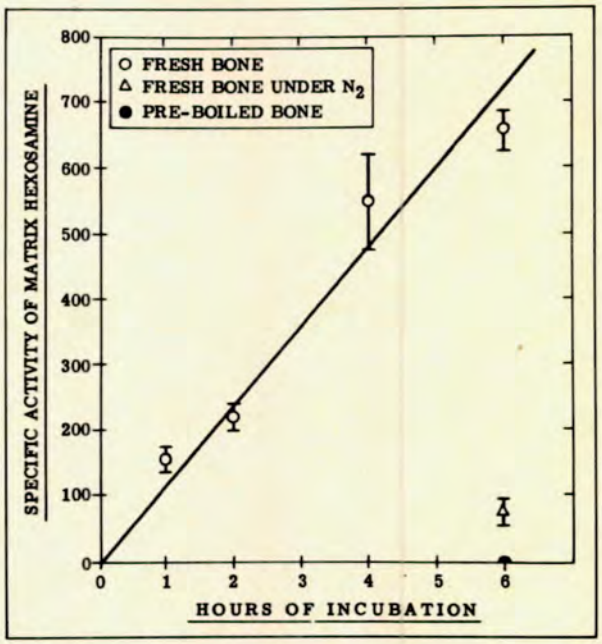

FIG. 3. Biosynthesis of matrix glycosaminoglycans of bones *in vitro* from ^{14}C-glucose. Specific activity is expressed as c.p.m./μ mole.

Table II. CALVARIUM COLLAGEN SYNTHESIS

Collagen hydroxyproline pool	=	16μ moles
Collagen hydroxyproline synthesized	=	0.00032μ moles/100 mg/hr (or 0.002% of the pool per hour)
Half-turnover time	=	100 days

It was once postulated — and a large body of circumstantial and factual evidence supported the contention — that, under bone-resorbing circumstances, excessive amounts of citric acid are formed by the cells and then deposited in and around the crystals in the calcified matrix. This process was thought, as well, to drop the pH and chelate some of the mineral, causing the matrix to demineralize *in vivo*, just as a piece of bone does when dropped in acid *in vitro*. The pH does fall, as indirect measurements (and a few preliminary direct ones) of resorbing bone have shown (Neuman and Neuman, 1957).

Bone cells are now known to play a role in bone resorption because they participate in the generation of lactate and citrate ions, which cause the pH to drop. Bone cells also produce lytic enzymes, which attack both the ground substance and collagen, so that degradation products are formed. Both are either completely degraded or partially carried away. Raisz (1970) has reviewed the multiple physiologic and pharmacologic factors that influence bone resorption.

With respect only to the net changes in bone collagen (Fig. 6), proline is incorporated (as already described) into the hydroxyproline of collagen polypeptides, which are then extruded from the cell as soluble collagen. Soluble collagen eventually matures by cross-linkage into insoluble collagen. It is known that both soluble-collagen precursors and insoluble collagen are

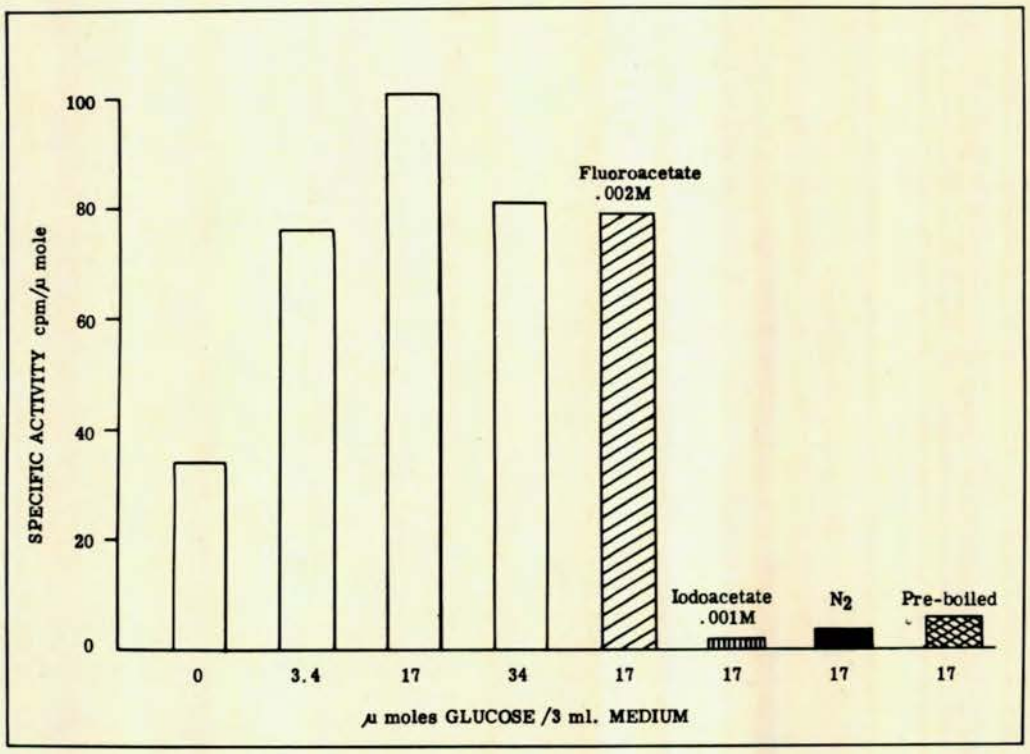

FIG. 4. Biosynthesis in bone of collagen hydroxyproline from labeled proline as a function of glucose supplementation.

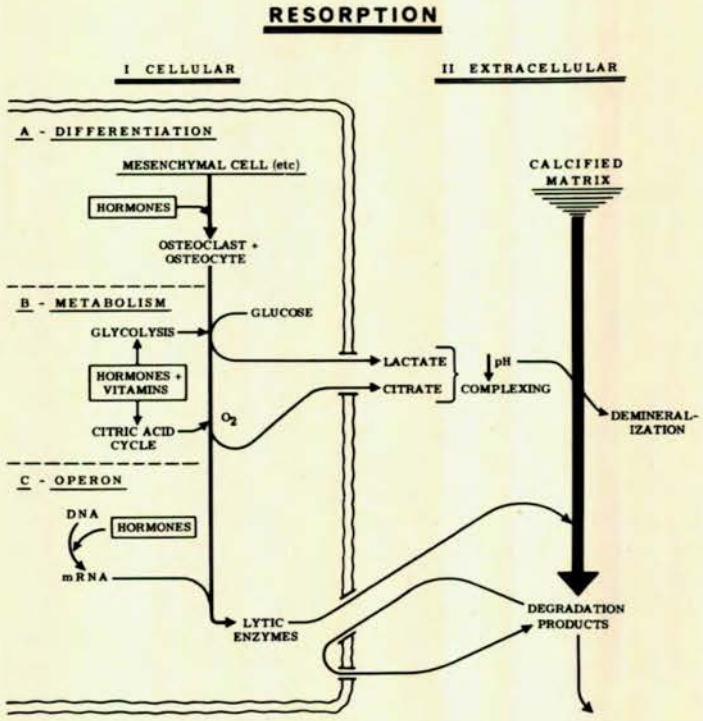

FIG. 5. Schematic diagram of major events in resorption of bone matrix.

degraded to form certain urinary hydroxyproline containing peptides. Using this general scheme, one can examine certain conditions under which bone resorption in the whole animal is accelerated (see Fig. 7). Johnston and Deiss (1965) demonstrated that parathyroid extract, which is known to hasten bone resorption, will elicit a brisk increase in products of bone-collagen resorption in the form of incremental excretion of these urinary hydroxyproline peptides.

The possible relevance of this phenomenon to dysbarism-related osteonecrosis is that one might expect necrotic bone to be resorbed and that, if the urine of an individual suspected of having osteonecrosis is carefully and periodically examined, the products of this resorption might well be detected in it.

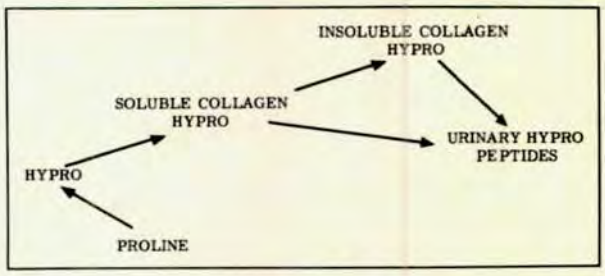

FIG. 6. Origin of urinary hydroxyproline containing peptides from bone metabolism.

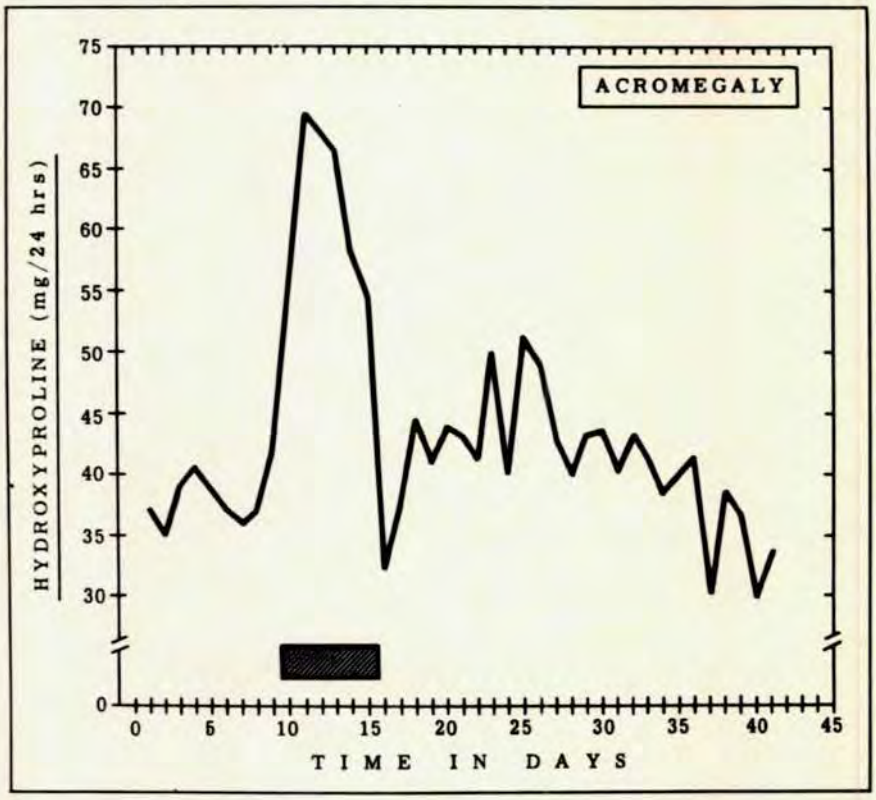

FIG. 7. Influence of a bone resorption stimulus — parathyroid extract — on urinary hydroxyproline. Shaded box represents 200 units of parathyroid extract administered 3 times daily.

REFERENCES

Deiss, W. P., Jr., Holmes, L. B., and Johnston, C. C., Jr. (1962). Bone matrix biosynthesis *in vitro*. I. Labeling of hexosamine and collagen of normal bone. J. Biol. Chem. 237, 3555-3559.

Flanagan, B., and Nichols, G., Jr. (1965*a*). Metabolic studies of human bone *in vitro*. I. Normal bone. J. Clin. Invest. 44, 1788-1794.

Flanagan, B., and Nichols, G., Jr. (1965*b*). Metabolic studies of human bone *in vitro*. II. Changes in hyperparathyroidism. J. Clin. Invest. 44, 1795-1804.

Johnston, C. C., Jr., and Deiss, W. P., Jr. (1965). Parathyroid hormone and urinary hydroxyproline. Metabolism 14, 523-529.

Johnston, C. C., Jr., Deiss, W. P., Jr., and Miner, E. G. (1962). Bone matrix biosynthesis *in vitro*. II. Effects of parathyroid hormone. J. Biol. Chem. 237, 3560-3565.

Neuman, W. F., and Neuman, M. W. (1957). Emerging concepts of the structure and metabolic functions of bone. Amer. J. Med. 22, 123-131.

Raisz, L. G. (1970). Physiologic and pharmacologic regulation of bone resorption. New Engl. J. Med. 282, 909-916.

THE PATHOGENESIS OF OSTEONECROSIS

JAMES S. MILES

The word *bone* has many meanings, and the distinction must be made whether one is speaking of bone as a tissue or an organ. In this Symposium, the physiology of bone is of primary interest, and bone must therefore be considered in the context of its cellular metabolism and function as a tissue. And as tissue, bone may be considered from many different approaches — that of the crystallographer, the physiologist, or the biochemist.

As tissue, bone is affected by all known hormones and vitamins as well as by the general metabolic state of the body. The participants of this Symposium are primarily concerned with bone necrosis associated with dysbarism and the fate of the necrotic bone. Whether bone, in whole or part, is killed by metabolic defect, trauma, vascular loss, or some other condition, appears to make no difference: the body's reaction to it is the same.

The bone necrosis most commonly observed clinically, and one of great academic interest, involves the femoral head following interruption of its vascular supply caused by fracture or dislocation. In Fig. 1 are shown the major vessels of the proximal end of the femur. Medial and lateral circumflex femoral arteries form a ring about the base of the femoral neck. Retinacular vessels branch from this arterial ring and pass proximally up the femoral neck, remaining extra-

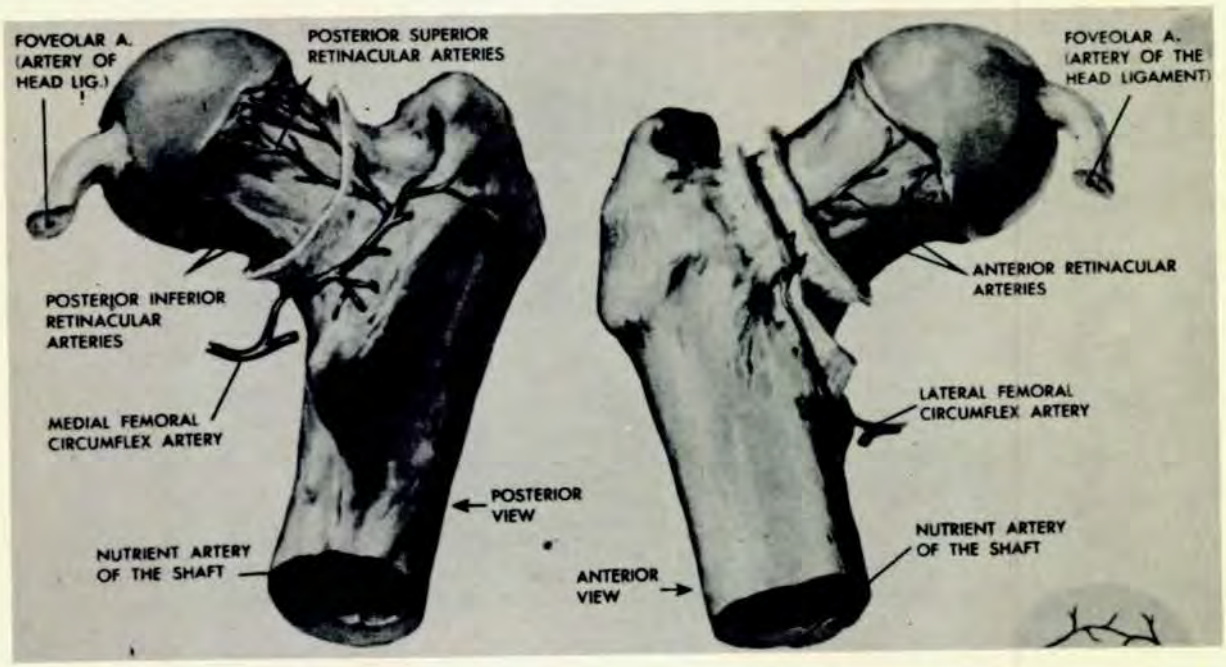

FIG. 1. Extraosseous vascular supply of proximal femur. (© Copyright 1953 CIBA Pharmaceutical Company, Division of CIBA-GEIGY Corporation. Reproduced, with permission, from the CLINICAL SYMPOSIA illustrated by Frank H. Netter, M.D. All rights reserved.)

osseous in position but subcapsular or subsynovial within the hip joint. Branches from these arteries enter the bone through numerous vascular foramina in the femoral neck, metaphysis, and epiphysis. The head itself is composed of an epiphyseal ossification center, which is proximal to an epiphyseal cartilage. Since no vessels from the metaphysis traverse this cartilage, they must enter the bone of the ossification center by first coursing around the periphery of the cartilage still in their subsynovial position.

The extraosseous and intraosseous positions of these vessels are more clearly demonstrated in Fig. 2, an injection study by Trueta and Harrison (1953). The retinacular or capsule vessels are shown in relationship to the epiphyseal "scar," the remnant of the two cortices that were once on the sides of the epiphyseal cartilage. By their position these vessels are designated as *1*) medial and lateral metaphyseal arteries and *2*) medial and lateral epiphyseal arteries. Clearly, no vessels cross the scar from the metaphysis into the epiphysis.

The lateral epiphyseal vessels cross approximately in the subperiosteal and subsynovial position around the epiphyseal scar and have a previous ossification center laterally. The medial epiphyseal vessels are the terminal branches of the vessels of the ligamentum teres, entering the center medially through the fovea centralis of the femoral head. The medial and lateral metaphyseal vessels are simply those entering the

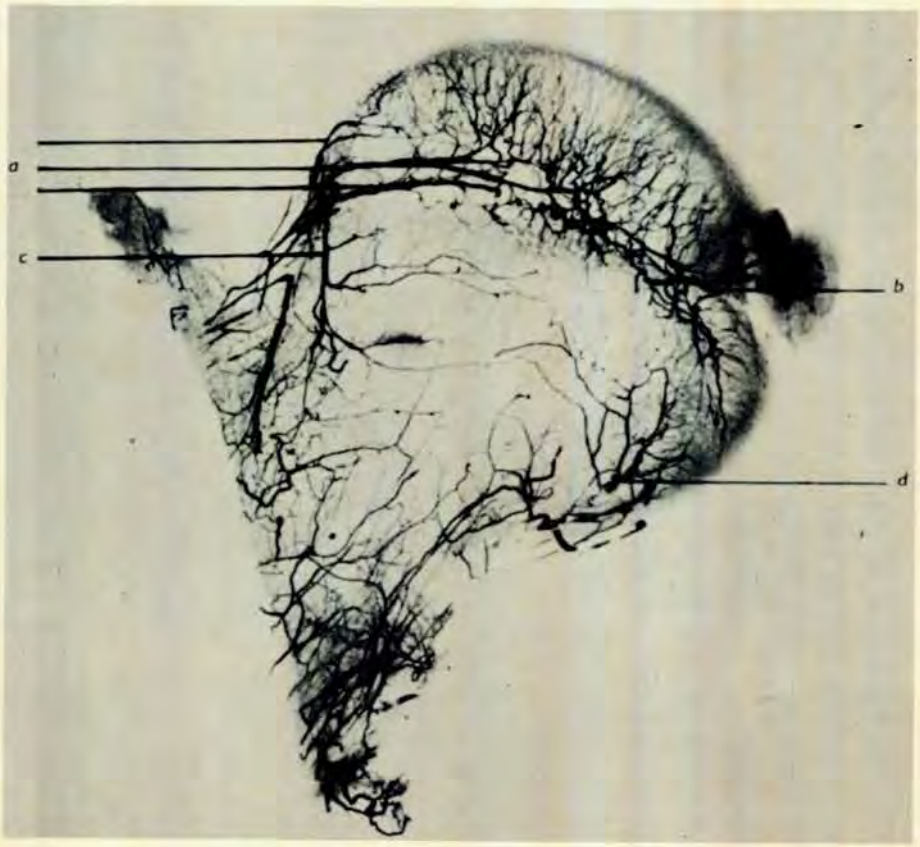

FIG. 2. Intraosseous vascular supply of proximal femur demonstrated by injection. (*a*) Lateral epiphyseal vessels; (*b*) medial epiphyseal vessels; (*c*) lateral metaphyseal vessels; (*d*) medial metaphyseal vessels. There are anastomoses between medial and lateral metaphyseal vessels and a few between medial and lateral epiphyseal vessels, but none between metaphyseal and epiphyseal vessels. (Trueta and Harrison, 1953. Illustration courtesy of publisher.)

bone distal to the old epiphyseal scar. All these vessels are in a very precarious position and can easily be damaged by trauma to the femoral neck or capsule.

The following illustrations demonstrate the result of such damage to retinacular vessels. The roentgenogram of Fig. 3 was made in September 1958. It shows the pelvis of a 69-year-old female who had fallen some three months earlier. She had not sought medical care, feeling that she had merely "sprained" her hip. The film demonstrates a fracture of the left femoral neck, with the calcar femorale of the distal fragment gouging into the medullary canal of the femoral head. There is shortening of the proximal femur and a secondary external-rotation deformity of the left lower extremity. The orthopedist decided that the fracture was probably stable and therefore could be treated simply by protection and bed rest.

In December 1958 the roentgenogram of Fig. 4 was made. Remarkable changes are apparent, especially when the September and December films are compared. There now is marked contrast in the density of the two femoral heads. In those three months the right femoral head has atrophied, but the left has not. Both acetabular cortices have also atrophied. The femoral necks, proximal femoral shafts, and intertrochanteric areas have atrophied as well. That the left femoral head has maintained its original density in a situation destined to produce bone atrophy (namely, bed rest) is *ipso facto* evidence of its necrosis. Necrotic tissues do not atrophy.

The patient's left femoral head was removed and a prosthesis inserted, providing a very interesting specimen, cut in a coronal plane, for microscopic study (Fig. 5). There is a very thick articular cartilage over the superior and supermedial surface. The fovea capitis femoris is evi-

FIG. 3. Pelvis of female with 3-month-old injury to L hip, showing shortening of L femoral neck. Fracture line is not visible because fragments have telescoped.

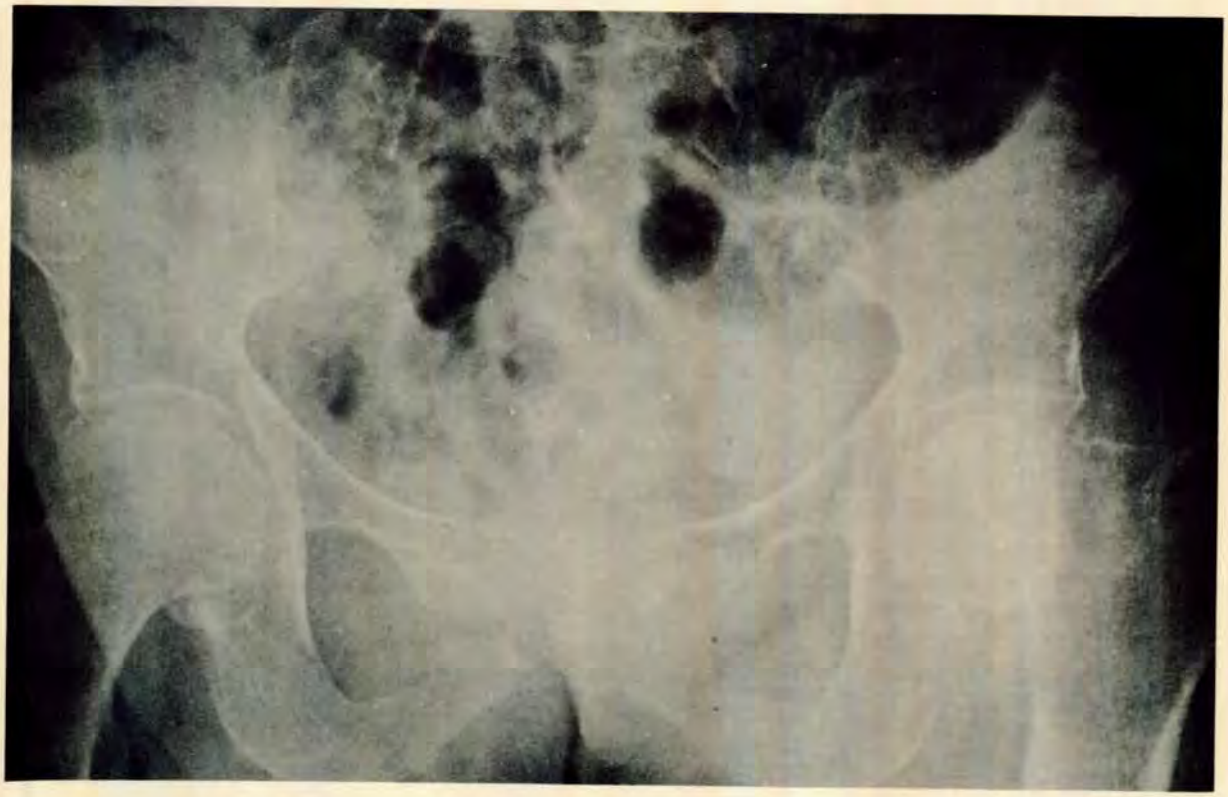

FIG. 4. Pelvis of patient in Fig. 3, who has been on strict bed rest, about 3 months later. Fracture deformity, with shortening of femoral neck, has progressed. There is relative increase in density of L femoral head — relative because it has retained density, while all around it the bone has atrophied. R femoral head is also atrophic. Absence of change in density of L femoral head is indicative of necrosis.

dent and is devoid of cartilage. The thin articular cartilage over the inferior portion of the femoral head is also evident. On the fracture surface, to the right, is a large gouged-out area where the calcar femorale of the distal fragment protruded into the head. Surrounding this gouged-out area is a thin reddish-brown band of tissue. The spaces from this area to the articular cortex of the femoral head medially are filled with reddish-brown marrow. This marrow stands in sharp contrast to the yellowish marrow of the superior weight-bearing quadrant and the fatty marrow of the inferior femoral head.

Figures 6 through 12, photomicrographs of various parts of the femoral head at much higher magnification, show what has happened in the six months between fracture and surgical removal. The first (Fig. 6), from the superior weight-bearing quadrant, presents a picture of total tissue necrosis. The trabeculae are unchanged, but the lacunae contain no osteocytes; the fat cells are indistinct and have been broken up by autolysis. No capillaries are seen.

Figure 7 is a photomicrograph taken from the middle portion of the femoral head extending proximally from the gouged-out area toward the medial articular cortex. The medullary fat cells have been replaced with living loose areolar fibrovascular tissue. Numerous viable capillaries with erythrocytes are seen. The trabeculae show remarkable osteoclastic activity on numerous surfaces of the bone. There are Howship's lacunae of resorption on numerous trabecular surfaces; and, strangely enough, on the opposite side of the dead trabeculae, numerous osteoblasts are laying down new bone in an appositional layer on the preexisting necrotic trabecula. The central core of the trabecula remains necrotic, its lacuna devoid of osteocytes. This process of laying down new bone and resorption of dead bone,

FIG. 5. Gross macroscopic section of L femoral head of patient in Fig. 3 and 4. Fracture line is on L. (*a*) through (*f*): Sites of high-magnification photomicrographs shown in Fig. 6 through 12.

FIG. 6. Bone and medullary contents of superior weight-bearing portion of L femoral head, fractured 6 months earlier, shown in Fig. 5 (site *a*). No living cells are visible.

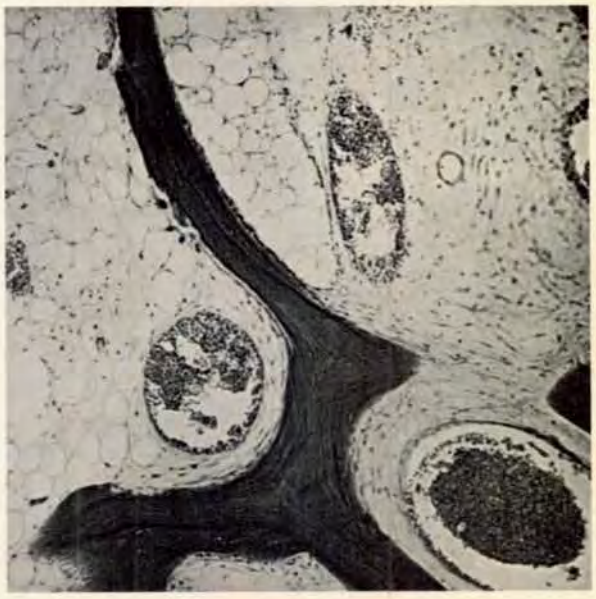

FIG. 7. Area of femoral head shown in Fig. 5 (site *b*), proximal to gouged-out area of the medulla, in which replacement process called *creeping substitution* is taking place.

FIG. 8. Area of femoral head shown in Fig. 5 (site *c*), proximal to gouged-out area of medullary space, showing a single trabecula and process of creeping substitution. Active line of osteoblasts on inferior surface of necrotic trabecula has deposited thin band of appositional new living bone. Marrow contents are beginning to differentiate from loose fibrovascular tissue, visible in Fig. 7, into fatty and hematopoietic marrow.

marrow contents, and necrotic tissue has been termed *creeping substitution.*

The next photomicrograph (Fig. 8) concerns a single trabecula. Again the loose fibrous tissue has invaded and replaced all of the marrow contents; creeping substitution is taking place. Extremely active osteoblastic activity is seen on one side, whereas there is very little on the other. Creeping substitution may be so perfect that the new living tissue and organ may be indistinguishable from the original. However, under certain circumstances, which are as yet unknown, something may go wrong with the replacement process. In some areas the very loose areolar or fibrous tissue with its rich vascular supply may became highly collagenized, forming a dense fibrous connective tissue, and the substitution seems to come to a halt.

The photomicrograph in Fig. 9, again from the central portion proximal to the gouged-out area,

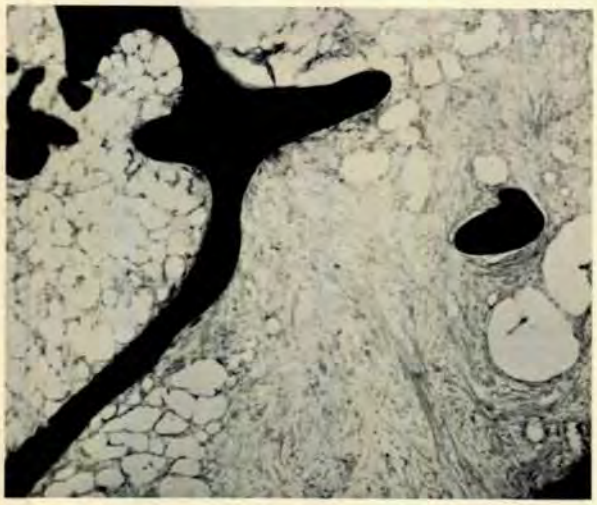

FIG. 9. Area of femoral head shown in Fig. 5 (site *d*), immediately proximal to gouged-out area of medulla. Creeping substitution of marrow has occurred on R; marrow on L is as yet unreplaced. Fibrovascular tissue has apparently matured and lost its potential for creeping substitution of bone.

shows fibrous marrow tissue densely collagenized with minimal osteoclastic and osteoblastic activity about the trabeculae. The smaller trabecula is completely surrounded by this tissue, which has limited potential for removal and replacement of necrotic bone. Fibrous tissue is approaching the larger necrotic trabecula to the left, but is not replacing it. It would appear that the trabecula has acted as a barrier to the invasion of living tissue, and that the necrotic fatty marrow, to the left, has not yet been replaced. Reasons for this variation in the replacement process are entirely unknown, but they must be local.

Figure 10 is a higher magnification of a trabecula of dead bone with appositional new bone

FIG. 10. Area of femoral head shown in Fig. 5 (site *e*), revealing creeping substitution. On inferior trabecular surface is single Howship's lacuna of osteoclastic resorption. Applied to both trabecular surfaces is layer of new appositional bone, its lacunae filled with living osteocytes with layer of osteoblasts on its exterior surface.

formation. The necrotic preexisting trabecula is seen centrally, its lacuna devoid of cells. On the trabecula's two surfaces are thick bands of viable immature reactive bone; very active osteoblastic activity is seen. The appositional new bone has more than doubled the size of the preexisting trabecula.

With highly refined roentgenographic techniques it would be possible to show a true and absolute increase in density of this portion of the femoral head as a consequence of this creeping substitution with its appositional bone formation. Thus if microscopic radiographs were possible we could see a mixture of areas of decreased density, where bony trabeculae had been

resorbed, together with areas of increased density caused by appositional new bone formation. Such microradiographic techniques are available for laboratory specimens but are not possible in clinical studies.

Clinical roentgenograms are influenced by another factor — the application of Wolff's law, which, simply stated, is that the architecture and structure of bone are dependent upon the forces acting upon it. The more that force and stress are applied to bone, the more will bone formation occur; the less force and stress applied, the more will bone atrophy. Disuse atrophy is a part of most clinical situations. Living bone surrounding an area of necrotic bone will undergo atrophy quite similar to that occurring in soft tissues. Because of disuse and, hence, reduced stress, living bone replacing dead bone will be quite porotic.

If the patient is quite inactive until all the necrotic bone has been replaced, the entire area will appear to be less dense — *i.e.*, atrophic — in the gross or macro roentgenogram. In the micro roentgenogram (if such were possible in the clinical situation), small areas might appear to be of normal or increased density, as the trabeculae in Fig. 10 would indicate. If the patient were later permitted to resume normal activity, hypertrophy of the bone would occur (Wolff's law), with a real increase in bone density visible in both micro and macro roentgenograms.

FIG. 11. Area of femoral head shown in Fig. 5 (site *f*), immediately adjacent to gouged-out area of medulla (upper border). Medullary contents have been replaced by loose fibrovascular tissue, which is differentiating into bone (callus) in an obvious attempt to unite the two fragments.

Figure 11 shows the calcar femorale of the distal fragment penetrating the bone. The traumatized trabeculae (upper portion of the photomicrograph) are surrounded by marrow spaces filled with loose fibrous tissue; active creeping substitution is apparent. There is osseous metaplasia in the fibrous tissue, which has the appearance of fracture callus. The large trabecula to the right demonstrates creeping substitution, where bone removal seems to be more advanced than appositional bone formation. Figure 12, at higher magnification than Fig. 11, shows the previously mentioned necrotic trabecula where osteoclastic activity exceeds osteoblastic activity. Numerous multinucleated osteoclasts are seen absorbing the trabecula. All previous necrotic marrow contents have been replaced by a mixture of loose areolar or vascular fibrous tissue and, in some areas, by very dense, highly collagenized fibrous tissue.



FIG. 12. High magnification of necrotic trabecula in R of Fig. 11 (Fig. 5, site *f*). Lacunae are devoid of cells. Very early creeping substitution is occurring. Single Howship's lacuna of osteoclastic resorption is seen on L side of trabecula; osteoclasts have single nucleus only. Loose fibrovascular tissue has replaced marrow content on R. On L, invading tissue is more mature and has differentiated into callus.

These photomicrographs, taken of a single specimen, demonstrate that the process of creeping substitution varies in different portions of the femoral head. The variations are probably due

in part to the accessibility of necrotic bone to invading fibrovascular tissue. In some femoral heads proximal to the femoral neck, the medial and lateral metaphyseal vessels and the lateral epiphyseal vessels may be torn as a direct result of a fracture. The medial epiphyseal vessels from the ligamentum teres may remain intact; in other instances they may be torn. If all the vessels are torn, the entire femoral head will become necrotic.

In some femoral heads proximal to a femoral-neck fracture, some of these retinacular vessels may remain intact, leaving the areas that they supply viable. These femoral heads may then reveal roentgenographic evidence of segmental or partial necrosis. Decreased density in one portion may indicate atrophy of living bone where retinacular vessels have remained intact. Or it might indicate replacement of necrotic trabeculae by living atrophic bone in the process of creeping substitution. Increased density in that area might simply be relative in comparison with the atrophy of the surrounding area. Or it might be a true increase resulting from appositional creeping substitution, hypertrophy of the newly substituted bone, or the addition of callus.

Proper roentgenographic interpretation of femoral-head damage depends upon knowing *1*) the time interval between injury and X-ray, *2*) the accessibility of the injured area to vascular invasion, and *3*) the status of the surrounding area. Precise interpretation of the pathologic process is not possible from a single clinical roentgenogram. Accurate assessment depends upon making serial roentgenograms in sufficient numbers of the highest possible quality, at sufficiently frequent intervals, and with the most standardized technique. Obviously, critical evaluation is also dependent upon specialized knowledge of bone physiology and pathology. The correlation of roentgenograms and microscopic sections is of greatest importance. Unfortunately, in most clinical situations neither adequate microscopic sections nor comparable roentgenograms are available. Serious errors in interpretation are therefore quite frequent.

The invasion and replacement of a necrotic femoral head proximal to a femoral-neck fracture depend upon many factors. Some are well known, other not at all. One such factor is age. The younger the individual is, the more rapidly the fibrous tissue will grow into the head. In younger individuals this tissue appears to be of the highly vascular, loose areolar type, and replacement may be quite rapid and perfect. Another factor is stability. Even though the femoral head is entirely necrotic, if it can be stabilized on the neck by internal fixation devices or by external plaster, union of the fracture will probably take place. If union occurs, then the fibrous tissue may invade the head rapidly. If, on the other hand, union does not take place, the



FIG. 13. Closed one-month-old fracture of tibia in 20-year-old male. Good overall alignment exists, but distal fragment (R) is slightly displaced, accounting for tangential cut of section and apparent convergence of the two cortices. (*a*) and (*b*): Sites of high-magnification photomicrographs shown in Fig. 14 and 15, respectively.

tissue cannot bridge the gap between the necrotic head and the living neck.

Similarly, if a pseudoarthrosis develops at the fracture site, the loose fibrous tissue cannot invade the femoral head because of a developing pseudojoint and its cartilage, which become part of the pseudoarthrosis. Infection will also seriously impair the replacement process, despite apparent increased vascularity in the area. Trauma may likewise disrupt the replacement process. Obviously the newly replaced atrophic area is weaker than the surrounding living atrophic bone or the necrotic bone that is as yet unreplaced. A pathologic fracture can occur in the zone of creeping substitution, further complicating the process, making more difficult the radiographic and microscopic interpretation.

Figure 13 shows a fracture of the tibia sustained by a 20-year-old college student when struck by an automobile. The fracture of this extremity was completely immobilized by paralysis and a long-leg plaster dressing prior to the patient's death one month later. The photograph shows the comminuted fracture of the tibial cortices, remnants of the fracture hematoma, and damage to the striated muscle.

In high magnification (Fig. 14) the loose fibrous tissue reaction is seen in the removal of the necrotic erythrocytes from the fracture hematoma. The necrotic erythrocytes and fat cells in the lower left are essentially unchanged since the date of fracture. In the upper right is an impressive ingrowth of loose fibrous tissue with a spectacular number of capillaries. The tissue and capillaries are advancing in an essentially oblique line from the upper left to the lower right. The tissue in the extreme upper right has undergone differentiation into osteoblasts, the product of which is very immature bone formation. The healing process is therefore quite clear: ingrowth of fibrovascular buds; replacement of necrotic hematoma, fat cells, and other tissue; and then differentiation of fibrous tissue into fibroblasts, after which collagen or bone is formed.

FIG. 14. Tibial fracture shown in Fig. 13 (site *a*). Taken from hematoma of central portion of medullary canal, section shows numerous fibrovascular buds (upper R) and quite immature bone callus (extreme upper R).

Not only must a necrotic hematoma be removed, but necrotic muscles and their tissues as well. In high magnification, Fig. 15 shows necrotic striated muscle (left), with fibrovascular tissue (right) invading the central fracture hematoma. Once again is the appearance of very active fibrovascular tissue advancing to replace necrotic hematoma and muscle.

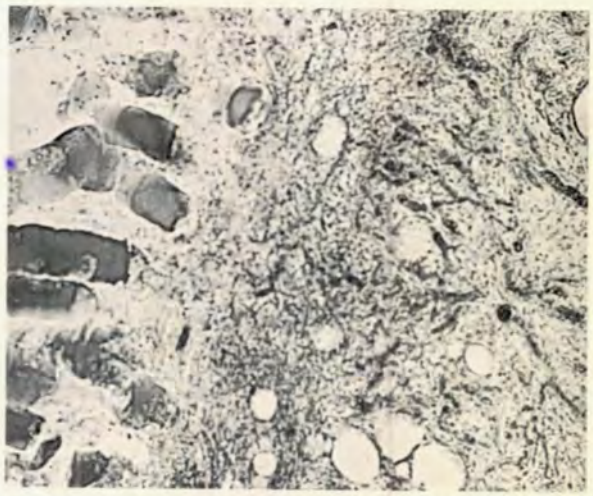

FIG. 15. Site *b* of Fig. 13, showing fracture callus with creeping substitution of necrotic tissue.

It is well known that this replacement process is the first stage of callus formation. Differentiation of loose fibrous tissue into cartilage and bone represents the healing process, the callus.

The roentgenogram in Fig. 16 illustrates another aspect of the problem of osteonecrosis. A 14-year-old boy was a passenger in an automobile

FIG. 16. Pelvis of 14-year-old male with injury to R hip. R capital femoral epiphysis is posterior to hip joint, partially obscured by iliac portion of acetabulum. Ossification center is not attached to metaphysis and is rotated 90°.

in which the headlights had failed. He volunteered to act as headlights, sitting on the right front fender and telling the driver which way to turn. Following a bit of misdirection, the car hit a bridge abutment, which the patient tried to fend off with his right foot.

The roentgenogram shows what happened. The metaphysis of the proximal right femur is lying within the acetabulum, and the ossification center of the femoral head is lying completely outside and posterior to it. The patient obviously sustained a dislocation of his right hip joint and then set his muscles very tightly, causing the femur to pull back toward the acetabulum. The ossification center was reduced surgically and fixed to the metaphysis with pins. It probably would have been wise to remove the epiphyseal cartilage; but to do so would have left the patient with a shortened right extremity, because growth potential would have been lost. After surgery the patient was placed on crutches, the right leg non-weight-bearing.

Figure 17 is a roentgenogram made some 6 months after injury, showing three pins fixing the ossification center to the femoral neck and trochanteric region. Particularly striking is the appearance of the right proximal femur, the ossification center of the head, and the acetabular weight-bearing cortex. There is marked atrophy

FIG. 17. Pelvis of patient in Fig. 16, 6 months after injury. R femoral atrophy is spectacular, yet there is no decrease in density in R femoral ossification center.

of the cortex, which is particularly apparent when it is compared with that of the left acetabulum.

In addition, there is atrophy of the wing of the right ilium and of the intertrochanteric and subtrochanteric areas of the right femoral neck. The atrophy of these areas is striking when the two sides of the pelvis and the two femora are compared. Obviously the ossification center of the right femoral head has not atrophied. The center retains precisely the same density as that of the left one. Disuse atrophy (Wolff's law) has affected all bones of the right pelvis and right lower extremity, *except* the ossification center of the femoral head — this last circumstance indicative of necrosis of that bone. The surgeon realized that the epiphyseal cartilage between the ossification center and the femoral metaphysis had acted as a barrier against ingrowth of any fibrovascular tissue. Accordingly, a second operation was performed; multiple holes were drilled through the epiphyseal cartilage and a bone graft placed across it, thus opening up the ossification center to invasion by fibrovascular buds.

Figure 18 is a roentgenogram of the patient's right hip joint some six years later, showing severe degenerative arthritis. There is marginal osteophyte formation laterally on both the femoral head and acetabulum. The cartilage space is narrowed. The femoral head is deformed with flattening of its superior weight-bearing surface. A large portion of the weight-bearing quadrant

FIG. 18. A-P view of R hip of patient in Fig. 16, taken some 6 years after original X-ray film.

of the femoral head is sclerotic, and the replaced areas of the metaphysis are mottled in appearance.

In the intervening six years, this patient's necrotic ossification center has undergone creeping substitution. Unfortunately the weakened replacement bone has also undergone pathologic fracture, and there is depression of the superior weight-bearing articular surface. This has caused loss of sphericity of the femoral head, producing deformity.

The additional aspect of osteonecrosis posed by this case is the fate of articular cartilage overlying necrotic bone. This cartilage derives nutrition from two sources: superficially by lubrication from synovial fluid, and by perfusion from capillary buds penetrating the articular cortex from beneath. Quite probably articular cartilage varies markedly in its dependence upon these two sources of nutrition in different patients and in different areas. At any rate, the fate of articular cartilage overlying any articular necrotic cortex cannot be determined for a long time.

Articular cartilage may be viable; in this event, after replacement of the subjacent necrotic bone, the patient's joint will be quite satisfactory. But if the subjacent bone has undergone pathologic fracture, as happened in the foregoing case (Fig. 18), then degenerative arthritis may result. If, on the other hand, the subjacent necrotic bone has been properly replaced, the joint may be restored to almost perfect congruity and function. In other instances, the articular cartilage may have undergone necrosis along with the subjacent bone. Then the cartilage space will remain intact for a long time. When the subjacent necrotic bone is replaced, the process will continue until the articular cartilage is replaced as well, and the joint will then become the seat of degenerative arthritis. It is apparent, therefore, that the roentgenograms of articular cartilage are even more difficult to interpret than those of bone.

The enigma of articular cartilage is more frequently encountered in the process known as *osteochondritis dissecans* than in osteonecrosis. In the first instance, a piece of bone containing articular cortex undergoes necrosis. The overlying cartilage may or may not undergo necrosis as well. In some cases the necrotic bone and cartilage separate from the surrounding viable host tissue and a loose body is formed.

Many variations on this theme are seen clinically in osteochondritis dissecans. The necrotic bone may separate while the cartilage remains intact, either viable or necrotic. The necrotic bone may separate, accompanied by partial separation of the articular cartilage. Or an entire viable fragment containing necrotic bone and cartilage may separate from the host bone.

Figure 19 is a roentgenogram of the knee joint of a young adult male with osteochondritis dissecans of the medial femoral condyle. The large necrotic area in the weight-bearing portion is quite evident; a necrotic bone fragment has separated from the surrounding host bone. Because the man was symptomatic, arthrotomy was performed. The fragment is shown in Fig. 20. Most of the cartilage was fractured, but bridges still remained, holding the osteochondral fragment *in situ*. It was felt that, since this fragment was loose in its bed, its replacement was quite unlikely.

The fragment was therefore removed. Figure 21 reveals marrow spaces filled with necrotic tissue and a small amount of fibrous tissue, which is attached to the deeper margin of bone and the fracture surface (to right of photomicrograph). The necrotic articular cortex and cartilage, showing a "tidewater mark," are seen in Fig. 22 at higher magnification. The cortical lacunae are devoid of cells and the chondrocytes poorly

FIG. 19. L knee of young adult with osteochondritis dissecans of medial femoral condyle, in which can be seen a large oval-shaped defect containing articular cortex in two irregularly rounded areas (arrows).

FIG. 20. L knee joint of patient in Fig. 19 at time of surgery. Osteocrondritis dissecans fragment (arrow), which was subsequently removed, is in center of weight-bearing portion of medial femoral condyle.

stained. The picture is one of necrosis of bone and cartilage without any evidence of replacement. A very small amount of loose fibrous tissue has invaded and replaced the necrotic medullary content (lower right corner).

What happens to the articular cartilage of the fragment is shown in Fig. 23. Again, the cortical lacunae are devoid of cells, and the chondrocytes of the cartilage appear necrotic. The medullary content (lower left) has been completely replaced by loose fibrous tissue, which has invaded the cartilage through the necrotic articular cortex. It seems that creeping substitution could have progressed into the articular cartilage with subsequent removal of its necrotic tissue.

From a clinical standpoint, it would therefore appear that the fate of articular cartilage controls the prognosis of patients with osteonecrosis. If necrotic bone is adjacent to the articular cortex, the cartilage may remain viable or it may become necrotic. If the cartilage remains viable,

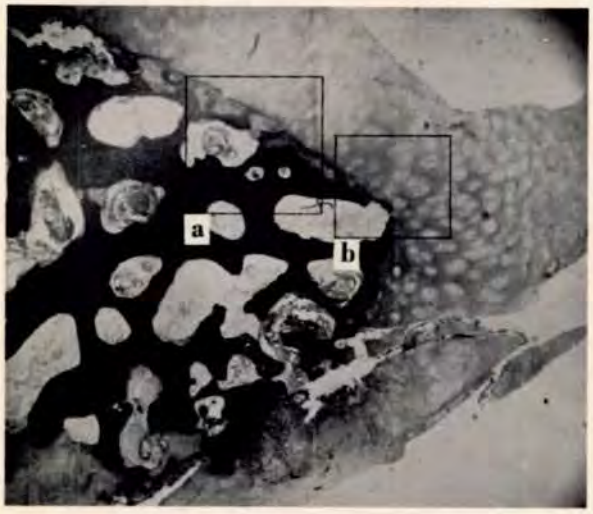

FIG. 21. Portion of removed osteochondritis dissecans fragment of L knee joint of Fig. 19. Invading loose fibrovascular tissue has differentiated into fibrocartilage, indicating movement of both bone fragment and invading tissue. (*a*) and (*b*): Sites of higher magnification shown in Fig. 22 and 23, respectively.

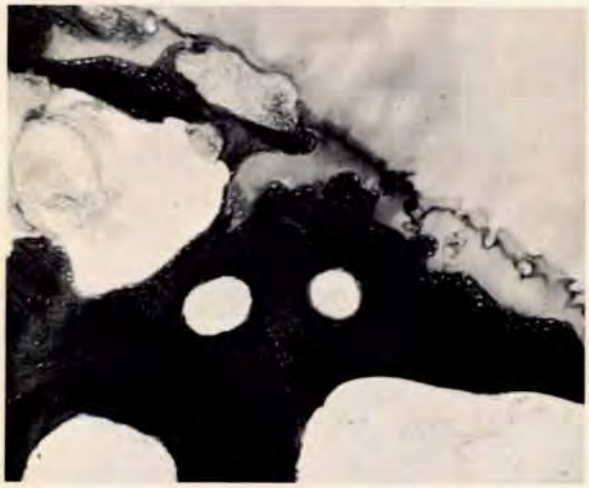

FIG. 22. Articular cortex and cartilage of osteochondritis dissecans fragment in Fig. 21 (site *a*) at higher magnification, showing "tidewater mark" of articular cartilage. All the bone is necrotic, with no replacement yet evident. Cartilage cells are indistinct, indicative of necrosis.



FIG. 23. Osteochondritis dissecans fragment of Fig. 21 (site *b*) at higher magnification than site *a* (Fig. 22), showing necrotic articular cartilage and cortex —both as yet unreplaced. Medullary contents of space at lower L have been replaced with loose fibrovascular tissue, which has left gap in the cortical continuity and has invaded cartilage to its "tidewater mark." The tissue has been primarily invasive and destructive, not having yet differentiated into fibrocartilage, appositional bone, or dense fibrous tissue.

the cartilage space will retain a normal width roentgenographically, and the patient's prospects are quite good. If the cartilage is necrotic, however, and if a subjacent necrotic bone is replaced, the replacement process extends to the dead articular cartilage as well. Hyaline articular cartilage is replaced with fibrocartilage, which will not tolerate weight-bearing. The net result in this instance is severe degenerative arthritis, although the cartilage space may remain normal for many years. The main clinical concern in these cases, then, is the fate of the articular cartilage, which cannot be predicted from roentgenograms or other clinical tests.

The next series of films demonstrates the influence of age on creeping substitution and the patient's prognosis. The patient is a 7-year-old male with Legg-Calvé-Perthes disease — idiopathic necrosis of the capital femoral epiphyseal ossification center — who had had symptoms for some 3 months.

In Fig. 24 are A-P and frogleg roentgenograms of the patient's pelvis. Necrosis in the ossifica-

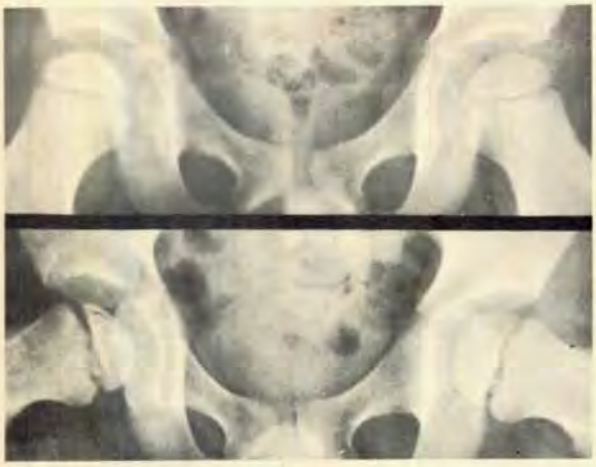

FIG. 24. Pelvis of 7-year-old boy with Legg-Calvé-Perthes disease, in A-P (above) and frogleg lateral (below) projections. Disuse has caused atrophy of R iliac acetabulum and proximal femur, but not of R capital femoral ossification center, the relative increase in density indicative of that center's necrosis.

tion center of the proximal right femur is apparent in the A-P film because of the relative increase in density. This increase is due to atrophy of the acetabular bone and of the femoral neck and trochanteric area, while the necrotic ossification center has retained its original density. The frogleg lateral view also demonstrates this relative increase of density. The dark irregular fracture line seen immediately beneath the articular cortex of the ossification center separates it and the cartilage from the subjacent trabecular bone of the center; it is a pathologic fracture.

Films made 3, 6, and 9 months later (Fig. 25) show replacement of the trabecular bone, which proceeds from the synovial membrane's point of attachment. The acetabulum and femoral metaphysis have undergone further atrophy. Decreased density is the result of a non-weight-bearing regimen in this period. The articular cartilage space is widening because of continued growth of cartilage and its nonreplacement by enchondral ossification from necrotic subjacent bone. Vertical bands of decreased bone density medially and laterally in the ossification center demonstrate very early creeping substitution.

The child was quite uncooperative in the crutch-walking, non-weight-bearing treatment program. He placed much weight on the ossification center, traumatizing the fragile atrophic replaced bone. A-P and frogleg views taken 2 years later (Fig. 26, upper films) and 3 years later (lower films) show the condition of the femoral head. Once more, flattening of the ossification center was caused by continued weight-bearing. Patchwork replacement of the trabecular bone of the anterior ossification center is quite evident, probably caused by the variable creeping substitution of necrotic bone. Importantly, the articular cartilage space has widened; the articular cartilage has obviously continued to grow, but enchondral ossification has not taken place. Ordinarily the ossification center enlarges and the articular cartilage grows. The articular cartilage space in this case is much larger than normal because of continued cartilaginous growth and its nonreplacement by normal enchondral ossification. Widening of the articular cartilage space (Fig. 26) is evidence of cartilage

FIG. 25. A-P projections of R hip of Fig. 24, taken 3, 6, and 9 months after original X-ray films, showing density changes.

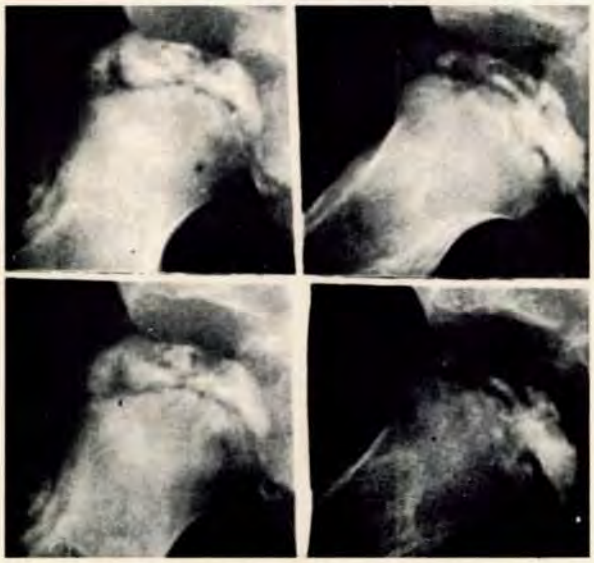

FIG. 26. A-P and frogleg lateral projection of R hip of patient in Fig. 24. Upper films were taken 2 years after those in Fig. 24; lower ones, 3 years after.

viability. Although replacement of the necrotic bone of the ossification center appears to be proceeding haphazardly, the prognosis is good.

Figure 27 is a roentgenogram taken 6 years after the diagnosis of Legg-Calvé-Perthes disease was established. The articular cartilage space has now returned to normal, the ossification center has been completely replaced, and normal enchondral ossification of the cartilage has occurred. There is little real deformity of the femoral head. Similar articular cartilage changes taking place in an adult would be most unusual.

In summary, necrosis of bone may generate a unique pathologic event — replacement through

FIG. 27. Hips of Fig. 24, taken 6 years later. Ossification center has been completely replaced, and overall configuration of R and L femoral heads is much alike.

a process called creeping substitution. The replacement may be quite perfect. However, when the necrotic process involves the articular cortex, the fate of the associated articular cartilage becomes crucial. If the cartilage is necrotic, it will be replaced rather imperfectly and degenerative arthritis will be the result. But whatever the etiology of the bone necrosis may be — whether idiopathic, traumatic, metabolic, or physiologic — the replacement process is identical, although it is influenced by many factors, including:

1. Site of involvement, whether articular or nonarticular
2. Age
3. Presence or absence of fracture
4. Presence or absence of union, if there is a fracture
5. Accessibility of the necrotic areas to fibrovascular invasion and the presence or absence of invasion
6. State of the articular cartilage.

REFERENCE

Trueta, J., and Harrison, M. H. M. (1953). The normal vascular anatomy of the femoral head in adult man. J. Bone Joint Surg. 35-B, 442.

FATAL FAT EMBOLISM FOLLOWING DECOMPRESSION SICKNESS IN AN EXPERIMENTAL DIVE

ALBERT A. BÜHLMANN

Professor Bühlmann was unable to attend the Symposium to present this paper. Its contents are nonetheless considered pertinent to a study of osteonecrosis related to dysbarism, and hence the paper is included.
—Eds.

A simulated dive, involving two subjects, was undertaken at the Kantonsspital, Zurich, Switzerland, in February 1968. The subjects were compressed in 20 minutes to 31 ATA*, at which pressure they remained 3 hours. They were then decompressed to 1.0 ATA in 63.5 hours. The first subject experienced decompression difficulties only at the beginning of decompression and was asymptomatic thereafter.

The second subject, of concern to this report, was R.B., aged 22; he was 185.2 lb. (84 kg) in weight and 69.3 in. (167 cm) in height. Prior to the experiment no abnormal clinical findings were uncovered, other than a blood volume value of 56 ml/kg (normal value in the laboratory, 67 ml/kg). Hematocrit was 47%; total lipids were 505 mg %.

This subject experienced no difficulty during compression or during the period at maximum pressure. But on decompression he suffered "vertigo bends" at 18.5 ATA, which was relieved by recompression to 23 ATA.

During the final period of decompression, in which the breathing mixture was 50% O_2 and 50% N_2 at 2.6 ATA, the subject experienced mild pain in both knees. The pain dissipated spontaneously during decompression at the scheduled slower rate.

*A distinction should be made between references to *atmospheres absolute* as used by certain European and by U.S. and U.K. researchers:

1 ATA (as used here) = 1 atmosphere absolute, technical (or 735 mm Hg, which is also the normal atmospheric pressure at Zurich); whereas

1 atm abs = 1 atmosphere absolute, international, or 760 mm Hg

R. B. slept for five hours after decompression was completed, and then was mobilized for medical examination. His blood pressure at that time was 120/70; his pulse rate, 116; and his total lipids, 560 mg %. His blood volume had decreased to 46 ml/kg, his hematocrit had increased to 51%, and he showed evidence of dyspnea and cyanosis. Chest X-ray revealed a faint shadow on the left side. Because of R.B.'s increasing dyspnea and cyanosis, he was placed under intensive care. Such measures as intubation and artificial respiration with positive end-expiratory pressure (PEEP B) were undertaken, and plasma infusions were given. Arterial blood-gas levels, blood pressure, and diuresis were maintained satisfactorily.

On the third day of therapy the triglyceride level in the patient's blood was elevated to 328 mg % (normal, 30 to 190 mg %); chylomicron level was 111 mg % (normal, 1 to 3 mg %); and very low density lipoprotein was 217 mg % (normal, 30 to 190).

The patient suffered a cardiac arrest on both the second and third days of treatment, but was successfully resuscitated. Cardiac arrest occurred again on the sixth day; in this instance, unfortunately, efforts at resuscitation were unavailing.

Postmortem findings. Gross examination revealed a hemorrhage, 3 cm x 2 cm x 8 cm in size, in the bone marrow of the distal third of the left femur (Fig. 1). Microscopic study of the tissues revealed diffuse fat embolization of the lungs (Fig. 2), brain, heart, kidneys, and muscular system.

Diagnostic hypothesis. Hypovolemia, of unclear etiology, caused poor blood flow and tissue perfusion. The rate of gas elimination was inadequate and decompression sickness resulted. The decompression sickness then caused hemorrhage and fat-tissue destruction in the marrow of the left femur, which was followed by a diffuse, and fatal, fat embolization.

Preceding page blank

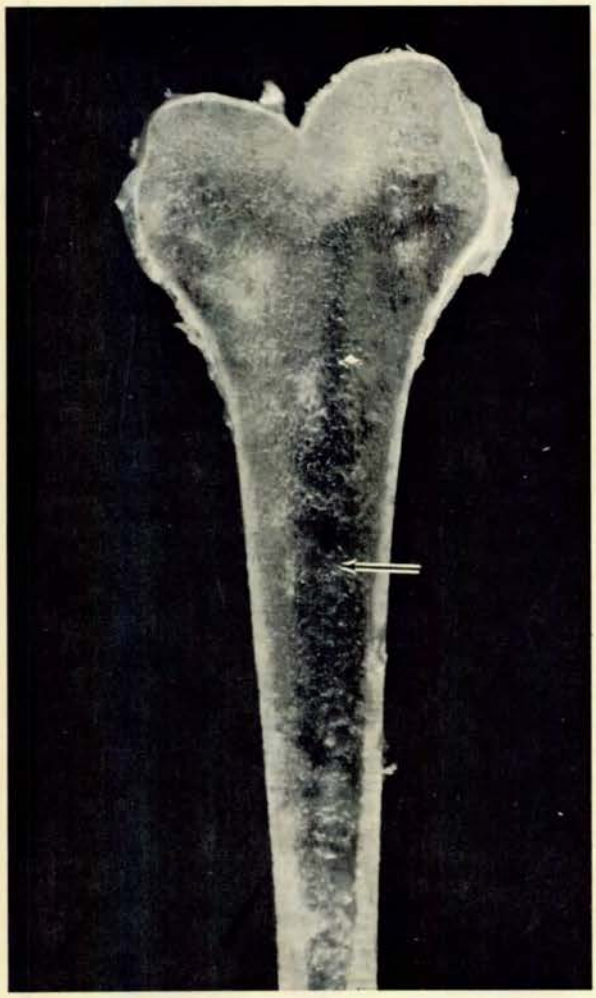

FIG. 1. Longitudinal section through distal third of left femur of patient R.B., showing intramedullary hemorrhage (arrow) in posterior segment.

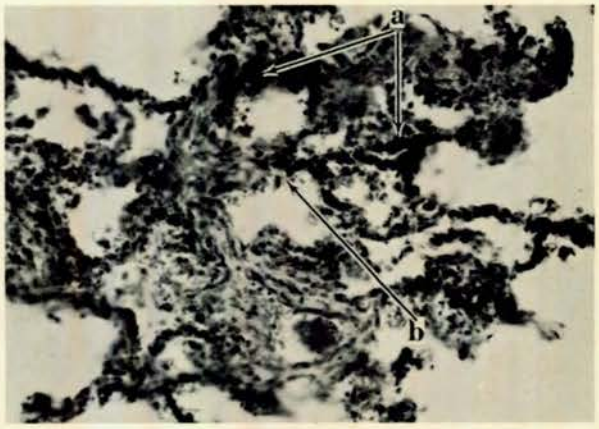

FIG. 2. Photomicrograph of lung tissue of patient R.B., showing vascular fat embolization; (*a*) droplets of fat in lung capillaries and (*b*) hemorrhagic extravasation.

PART IV

OSTEONECROSIS ASSOCIATED WITH OTHER DISEASES

EPIDEMIOLOGICAL AND ETIOLOGICAL CONSIDERATIONS IN OSTEONECROSIS

WILLIAM G. BOETTCHER

In this paper will be examined some of the clinical and epidemiological characteristics of aseptic bone necrosis as it affects the head of the femur in the general population. This population does not include those who are subjected to decompression. Also to be discussed is the occurrence of coagulation and hematologic abnormalities in these patients, with speculation on how they may be related to excessive alcohol consumption and other systemic disturbances. It should be emphasized that in most instances aseptic bone necrosis is a skeletal manifestation of a very serious and generalized metabolic disturbance.

To understand the problem more clearly, a group of 50 patients afflicted with femoral-head necrosis was studied at the University of Iowa between 1951 and 1968 (Boettcher *et al.*, Part I, 1970; Boettcher *et al.*, Part II, 1970). The results are shown in Table I.

The condition is clearly not a matter of degeneration due to age. There must be some underlying disturbance that leads to the development of these skeletal lesions in a group whose ages range from 24 to 65 years.

Prior to the time of diagnosis, most patients had had symptoms for an average of 18 months; in some, symptoms had persisted as long as 5 years. In many instances a variety of false diagnoses had been made before the correct one was arrived at. Seven hips were asymptomatic at the time of diagnosis, meaning that the lesion had not progressed to the point of femoral-head collapse. Most likely the patient who experiences acute pain has probably at that point suffered some collapse of the weight-bearing segment.

Of our patients, 36 were afflicted bilaterally. This very high incidence of bilaterality was revealed through regular follow-up examinations of the patients, at which time radiographs were taken of both hips. We can say that if a patient has aseptic bone necrosis involving the head of the femur, the chances are perhaps three in four that the other femoral head will be similarly affected. In all, 86 hips in 50 patients were diseased.

When these patients were recalled for follow-up examinations, 45 out of the 50 returned; the other 5 were dead. The average age of these patients at death was 52 years, attesting to the severe generalized metabolic disturbance involved in this patient population.

By analyzing the 50 patients' records, reevaluating their histories, and reexamining them and their laboratory data, we attempted to uncover a common link among the cases or a factor that might in some way have contributed to their aseptic bone necrosis. The following are other diseases and conditions that these patients shared in association with osteonecrosis, all of which

Table I. FEMORAL-HEAD NECROSIS IN 50 PATIENTS*

Average age	46 years (age span, 24 to 65 years)
Duration of symptoms	18 months (span, 1 to 60 months)
Asymptomatic	7 hips
Bilateral necrosis	36 patients
Unilateral necrosis	14 patients
Total number hips	86
Adequate follow-up (36 patients)	55 hips

*44 males, 6 females

Preceding page blank

have been reported in the literature:

Excessive alcohol consumption	37
Hepatic disease	21
Gout or hyperuricemia	16
Thrombocytopenia	15
Thrombocythemia	6
Steroid therapy	9
Hypercholesteremia	5
Hyperlipidemia	1
Discoid lupus erythematosus	1
Systemic lupus erythematosus	1
Fabry's disease	1
Reynaud's disease	1
Gaucher's disease	1

As noted, 37 patients had a history of excessive alcohol consumption. We were rather conservative in what we labeled excessive, defining it as being three or more drinks of hard liquor per day, regularly. However, the alcohol consumption of most of these patients was much higher. Many were binge drinkers, consuming as much as a fifth [one-fifth gallon] per day. Twenty-one patients had hepatic disease. Hepatomegaly was palpated in 13; abnormal BSP retentions were found in 12; liver biopsies on 2 patients revealed sclerosis.

We became aware of the fact that bleeding and coagulation disorders seemed to occur with unusual frequency among the 50 patients. On the basis of their histories and our clinical observations, 11 were thought to manifest such disorders, namely:

Clotting Defect	Occurrences
Epistaxis	2
Bruising	4
Abnormal bleeding	3
Petechiae or purpura	3
Thrombosis	1
Menorrhagia	1
Wound hematoma	3
Retinal hemorrhage	1

Of the two patients with epistaxis, one had drug-induced thrombocytopenia. At that time he had a platelet count of only 5000. The second patient also had thrombocytopenia as well as hyperlipidemia; his cholesterol level at that time was over 1000.

Of the four patients reporting repeated and easy bruisability, abnormal surgical bleeding in the form of diffuse, persistent capillary oozing occurred in three. One patient, suffering from persistent deep-vein phlebitis with thrombosis, had an interesting family history in that his father had died at a young age of mesenteric thrombosis. When the patient with menorrhagia had a hysterectomy, she required 10 units of blood for transfusion and was subsequently found to have idiopathic thrombocytopenia. Three patients with low platelet counts had wound hematomas. One man with hyperlipidemia and thrombocytopenia had retinal hemorrhages.

Because of these findings, we studied the platelet counts in our patients, most of them in retrospective investigations. The curve in Fig. 1 shows the normal distribution of platelet counts

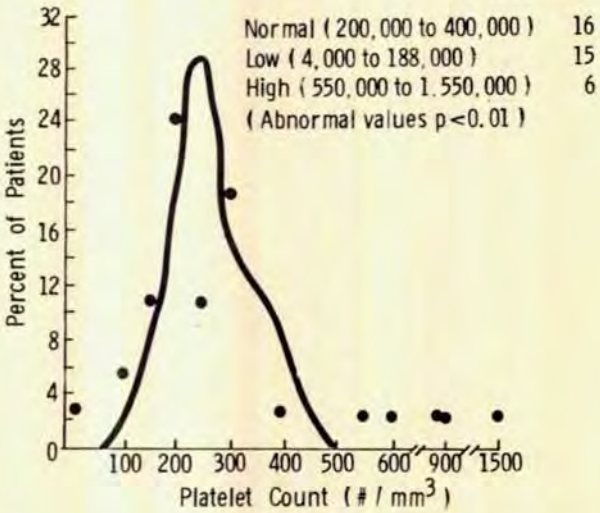

FIG. 1. Platelet counts in femoral-head necrosis in 37 patients, revealing abnormally high and low values in so-called idiopathic osteonecrosis. Normal range is within curve.

made in our laboratory on an unrelated group of patients as part of a different epidemiological study, the normal values being from 200,000 to 400,000. Of the 37 patients in our bone-necrosis investigation whose platelet counts were determined, 15 had low values and the platelets of 6 were elevated. The low values ranged down to 4000 — quite low. Some very elevated ones, as high as 1.5 million, were also recorded. The frequency of abnormal platelet counts, even in so small a subject population, is considered statistically significant.

We also studied the incidence of abnormal

serum uric acids in 33 patients; the normal value is 8 mg % or less. The graph in Fig. 2 shows a

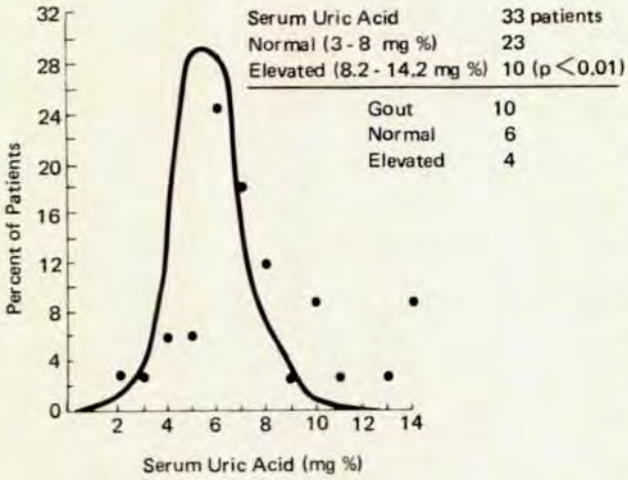

FIG. 2. Shift of abnormally high uric-acid values to right in 33 osteonecrosis patients in comparison with those of control group (under curve).

shift to the right. Serum uric-acid determinations of up to 14 mg % were recorded. Ten of these people were known to be under treatment for gout, which would have tended to reduce their uric acid to normal. So the value in an untreated population would probably have been even higher. The presence of abnormal levels of uric acid in this small a group of patients is also statistically significant.

After we became aware of the coagulation disorders in our patient population, we subjected 30 of them to the following rather extensive battery of coagulation tests:

Bleeding time

Clotting time

Silicone clotting time

Clot retraction

Prothrombin time (one stage)

Prothrombin time (two stage)

Thrombin time

Thromboplastin generation time

Prothrombin utilization (30 min)

Prothrombin utilization (60 min)

Plasma clotting time

Circulating anticoagulant

Fibrinogen

Factor VIII

Fibrinolysis plasma clot

The tests showed that at least one abnormal condition existed in every patient, which of itself is not significant. However, 9 patients revealed a combination of several coagulation abnormalities; the evidence suggested a hypercoagulable tendency in 5 of them and a hypocoagulable tendency in the other 4.

Coagulation and platelet-count abnormalities plus observations of bleeding and hemorrhages — together with an overlap among the disorders — appeared to offer some direct evidence for the existence of a bleeding or clotting disorder in 26 of the 50 patients:

Findings	Number of patients
Abnormal coagulation battery	9
Abnormal platelets	21
History or clinical observations of abnormality	11

There was some alteration in hemostasis as well. Considering the high incidence of alcoholism and other disorders, we then speculated about the possible existence of other bleeding and clotting abnormalities which we were unable to measure at that particular time. With excessive alcohol consumption in humans, intravascular red-cell agglutination is known to occur. Sludging and stasis have been observed in the small vessels of the eye, as have microhemorrhages. It is interesting that with excessive ingestion a marked thrombocytopenia occurs within a few hours, followed by rebound thrombocytosis when alcohol is withdrawn. When significant amounts of alcohol are consumed, especially in binge drinking, platelet counts will fluctuate markedly. An increase in fibrinolytic activity is also well known, especially (for some reason) following ingestion of beer.

Many coagulation factors are produced in the liver. Likewise, many coagulation abnormalities are associated with liver disease. For example:

Prothrombin deficiency	Factor X deficiency
Factor V deficiency	Factor XI deficiency
Factor VII deficiency	Thrombocytopenia
Factor IX deficiency	Increased fibrinolytic activity

As stated, 21 of our 50 patients had serious liver disease. Not all were sclerotic or had a large fatty liver, but they suffered from deficiency states of prothrombin. Several of the clotting factors, as well as thrombocytopenia and increased fibrinolytic activity, can occur with liver disease.

With hyperuricemia, increased platelet adhesiveness is common. Increased platelet turnover, increased plasma thromboplastin activity, and activation of the Hageman or clotting factor may also occur. Alcohol consumption compounds the problem, as it tends to raise the blood uric-acid level as well.

Several of our patients had hyperlipidemia, which is associated with such bleeding and clotting problems as marked acceleration of thrombus formation, decreased clotting time, modification of the thromboplastin generation time, and increased fibrinogen and clot retraction.

Nine patients in this study had undergone steroid therapy. This suggested to us that the underlying disorder for which steroids were given might have been of equal or even greater importance to the etiology of bone necrosis than the steroids themselves. Steroids, as one knows, may be prescribed for everything from the common cold to gout. In our patient population they had been administered for the following disorders:

Disorder	Number of patients
Thrombocytopenia	2
Thrombocythemia	1
Polycythemia	1
Systemic lupus erythematosus	1
Discoid lupus erythematosus	1
Gout	3

The two patients receiving steroids for thrombocytopenia had done so on a relatively long-term basis. Was the thrombocytopenia (in one case with 5000 platelets) more a contributory factor in the bone necrosis than the steroids were? It might be mentioned that aseptic bone necrosis has been reported in systemic lupus in the absence of steroid therapy. Steroids do not play an important role in the treatment of gout, so possibly the coagulation abnormalities associated with hyperuricemia rather than steroids contribute to the development of bone necrosis.

We therefore came to regard femoral-head necrosis as a skeletal expression of a systemic disease, or diseases, which by a variety of different events may result in sludging, thrombosis, or hemorrhage in an area of very susceptible blood supply.

REFERENCES

Boettcher, W. G., Bonfiglio, M., Hamilton, H. H., Sheets, R. F., and Smith, K. (1970). Non-traumatic necrosis of the femoral head: Part I. Relation of altered hemostasis to etiology. J. Bone Joint Surg. 52-A, 312.

Boettcher, W. G., Bonfiglio, M., and Smith, K. (1970). Non-traumatic necrosis of the femoral head: Part II. Experiences in treatment. J. Bone Joint Surg. 52-A, 322.

OSTEONECROSIS ASSOCIATED WITH METABOLIC DISEASE AND CORTICOSTEROID THERAPY

JOHN PAUL JONES, JR.

Mechanisms responsible for osseous ischemia may involve such changes in functional requirements as anemia, hypoxia, vasospasm, and hypotension; or a sudden increase in the tissue's metabolic demands; or, more probably, mechanical disturbances (*e.g.*, sudden and complete interruption or occlusion of vessels by traumatic severance, compression, endarteritis, thrombosis, or embolism). Various physiological and metabolic abnormalities have been considered by the author, and a hypothesis was formulated to determine whether a common etiology exists in nontraumatic fat embolism of bone in adults as a possible initiating event in the pathogenesis of nontraumatic avascular necrosis (Jones, 1971).

Fat embolism has been observed in the decompression-sickness syndrome, during crises in sickle-cell hemoglobinopathies, and in hypercortisonism, alcoholism, and pancreatitis, each of which may be complicated by avascular necrosis (Jones and Engelman, 1966). It is known that under certain circumstances the liver may be a major fat depot. In patients with acute fatty metamorphosis, the liver may be composed principally of neutral fat and may weigh more than 5000 gm, which is about 20 times the amount of fat that can be extracted from the adult human femur and tibia combined (Peltier, 1956). Lynch *et al.* (1959) demonstrated that 1 ml of liquid fat could result in 10 million fat emboli 40 μ in diameter.

Both clinical studies (MacMahon and Weiss, 1929; Hill, 1961) and experimental ones (Hartcroft and Ridout, 1951; Owens and Northington, 1962) indicate that the fatty liver is capable of spontaneously releasing large numbers of embolic-sized fat globules into hepatic venous channels after rupture of fatty cysts into adjacent sinusoids and central veins.

The liver is more heavily perfused by circulating blood volume than any extremity, which facilitates extensive drainage of fat globules through hepatic venous outflow tracks. Moreover, pancreatic enzymes, upon entering portal venous radicals in patients with pancreatitis, could conceivably cause further release of intravascular fat from fat-laden hepatic cells.

After penetrating the pulmonary vascular bed, fat emboli enter vessels supplying the brain, kidneys, and all other bodily organs and tissues, including those parts of the skeleton that are the most vulnerable to avascular necrosis. In general, these areas derive their nourishment from only a few primary vessels, principally terminal arteries with relatively poor circulation.

Only those metabolic disturbances known to be commonly associated with nontraumatic osteonecrosis in a working population between the ages of 20 and 60 years will be reviewed, since individuals with these conditions should be comprehensively evaluated on preemployment examinations before exposure to dysbaric phenomena. Dysbaric osteonecrosis, Gaucher's disease, Legg-Calvé-Perthes syndrome, radiation exposure, pregnancy, and other rarely associated entities will not be discussed.

CLINICAL OBSERVATIONS

Alcoholism

The commonest source of continuous, low-grade, and relatively asymptomatic showers of systemic fat emboli is probably the alcohol-induced fatty liver (Lynch *et al.*, 1959; Kimble, 1961). Osseous avascular necrosis may be specifically associated with alcoholism. Thirty patients with idiopathic osteonecrosis, all with a history of prolonged, excessive alcohol consumption, were studied in various hospitals in the San Francisco–Oakland Bay area. Osteonecrosis was diagnosed by roentgenograms in all 30 and confirmed histologically in 19. Of the patients 18 were Caucasian, 11 black, and 1 Chinese; 24 were male and 6 female; and their mean age was 47 years. Of the 30 patients, 27 had significant hepatomegaly, and 22 of 24 patients had abnormal bromsulphalein retention. Six of a sample

of 8 had hypertriglyceridemia, and fatty metamorphosis was demonstrated histologically in 7 of 9 livers examined. Evidence of systemic fat embolism was found in 9 of 19 patients. Lipuria was detected in 8 cases, probable intravascular fat globules in resected femoral heads were seen in 2 instances, and emboli were found at autopsy in 1 case.

In the sampling of 30 patients, there were 77 lesions (Fig. 1); bilateral symmetry was marked. Of the necrotic lesions 56% were in femoral heads, as seen in Fig. 2, and 11% in humeral heads. Metadiaphyseal infarctions within the distal femur and proximal tibia accounted for nearly one-third of the lesions.

Although Axhausen (1928) was probably the first to report osteonecrosis in an alcoholic patient, Vignon *et al.* (1960) reported that 5 of their 9 patients with idiopathic necrosis had a significant history of alcoholism; Mankin and Brower (1962) reported a similar history in 3 of 5 patients with osteonecrosis. Serre and Simon (1962) and Patterson *et al.* (1964) found that, respectively, 19% and 17% of their patients with avascular necrosis had a significant history of alcoholism. Malka (1966) noted that 3 of his 6 patients with femoral-head necrosis were alcoholics.

The majority of the 27 patients in Thibodeau's review (1968) of 41 hips with avascular necrosis were alcoholics. Of 50 patients with idiopathic ischemic necrosis of the femoral head reported in the Swiss Multi-Center Study, at least 6 were alcoholic with chronic liver disease (Zinn, 1971). Hartmann (1971) noted that 7 of 38 patients in the Swiss study had hyperlipidemia. In our experience the hyperlipidemias associated with alcoholism have been predominantly Type IV (Fredrickson and Lees, 1965), comprising chylomicrons and pre-beta lipoproteins.

Schreiber (1972) documented a 23-year-old heroin addict with bilateral idiopathic avascular

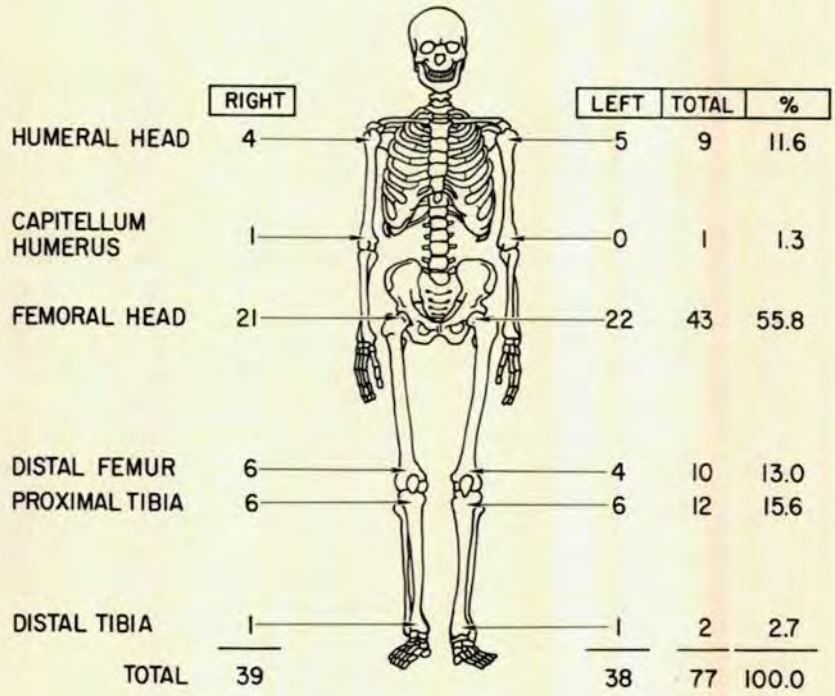

FIG. 1. Skeletal distribution of 77 osteonecrosis lesions, diagnosed roentgenographically, in 30 alcoholic patients. (Jones, 1971. Illustration courtesy of publisher.)

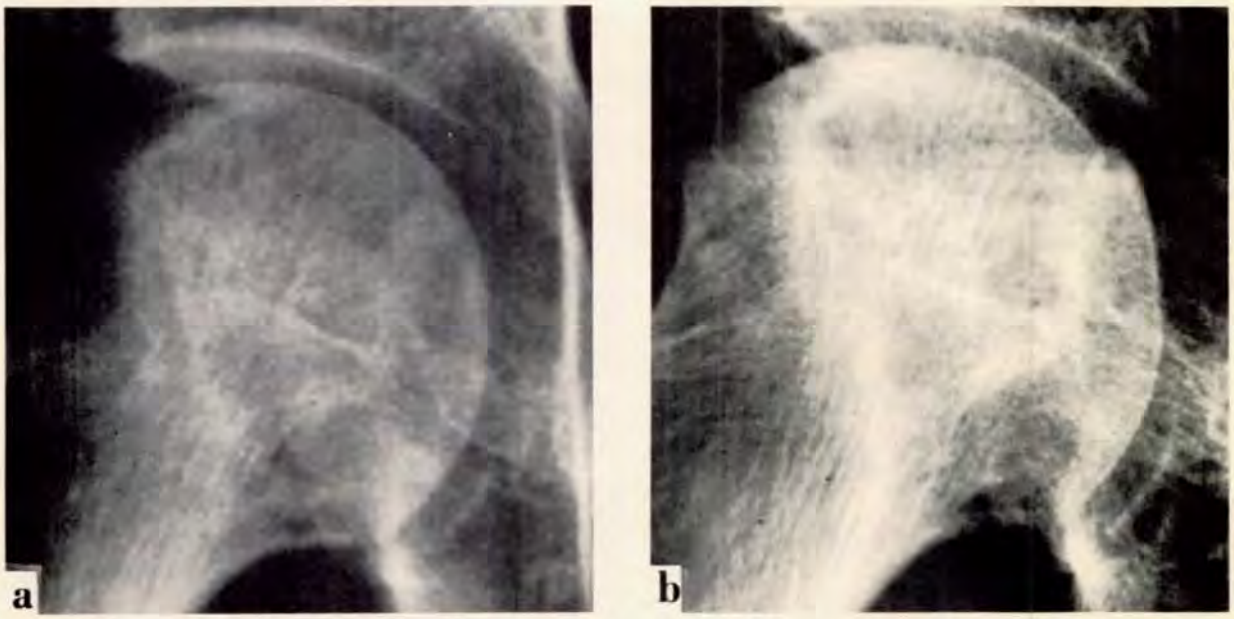

FIG. 2. A-P projections of R femoral head of male alcoholic. (*a*) Visible are scattered radiolucencies with minimal sclerosis and no gross evidence of architectural distortion. (*b*) Vascular necrosis and segmental collapse of irregular articular surface have occurred 13 months later.

necrosis of the femoral head. The association of acute and chronic liver disease with heroin dependency is well known. Laboratory evidence of hepatic dysfunction has been reported in up to 75% of parenteral heroin addicts (Norris and Potter, 1965). Stimmel *et al.* (1972) studied hepatic dysfunction in 46 heroin addicts and found that 89% had past or present liver disease. Liver biopsies were performed on 12 patients; hepatic injury attributed to alcohol was present in 10, all of whom had significant fatty changes.

Gout and Hyperuricemia

Of 68 patients with idiopathic aseptic necrosis, McCollum *et al.* (1971) reported that 34% had bilateral disease; 85% were male, and the average age of onset was 39.7 years. Of the 68 patients, 26 were alcoholics, 17 had gouty arthritis, and 10 had hyperuricemia. Mauvoisin *et al.* (1955) originally reported the occurrence of aseptic necrosis of the femoral head in a patient with gout. Wissinger (1963) first demonstrated uric-acid crystals in the synovium of the hip of a patient with aseptic necrosis, which was subsequently confirmed by Hunder *et al.* (1968). Rondier *et al.* (1970) investigated blood lipids in 50 patients with gout and found considerably higher levels of mean blood triglycerides, principally Type IV hyperlipoproteinemias.

Boettcher *et al.* (1970) reported excessive alcohol consumption in 37 of 50 patients with nontraumatic femoral-head necrosis. Abnormal bromsulphalein retention was found in 12 of 21 patients with liver disease; gout or hyperuricemia existed in 16 of them. Of 33 patients studied, 10 had significant hyperuricemia.

Pancreatitis

Avascular necrosis has not been reported in acute pancreatitis. However, Immelman *et al.* (1964) reported 3 patients with acute pancreatitis and lytic lesions involving the long bones. They considered these abnormalities secondary to fat necrosis resulting from increased circulating lipase. Blauvelt (1946) believed that these lesions were caused by pancreatic acinar emboli.

Ponfick (1872) first described intramedullary necrosis in a patient with pancreatitis. Gerle *et al.* (1965) reported 6 cases of chronic pancreatitis with avascular femoral-head necrosis. No histological evidence was reported, and all 6 were in patients with chronic alcoholism. Irregular serpentine metadiaphyseal lesions are most likely calcified areas of intramedullary fat ne-

crosis, possibly resulting from the lipolytic action of circulating lipase or the local liberation of pancreatic enzymes from minute pancreatic cell emboli.

Two patients with chronic pancreatitis and probable femoral-head osteonecrosis have been evaluated; both are also chronic alcoholics, and one has hyperuricemia. One can only speculate about the relationship between avascular necrosis and hyperuricemia, gout, pancreatitis, and drug addiction. A direct relationship cannot be proved, because alcoholism with fatty liver and hyperlipemia (Havel, 1969) is often associated with these conditions as well.

Hypercortisonism

Osteonecrosis associated with corticosteroid therapy was first described in 1957 by Pietrogrande and Mastromarino. Jones *et al.* (1965) reported osteonecrosis as a complication in renal transplantation, following which massive corticosteroid dosage is used for a prolonged period. Since then additional cases have been reported (see Table I).

Of those kidney-transplant recipients surviving longer than three months, approximately 6% have developed avascular necrosis affecting one or more bones. The first human lung transplant was performed in 1963 and the first human heart transplant in 1967; no lung or heart recipient has developed osseous avascular necrosis. However, repeat kidney transplantation for graft failure has been a recent development, and the risk of developing necrosis is significantly greater in those patients receiving two or more grafts.

Since 1963, a series of 32 patients who were treated with corticosteroids for various diseases have developed osteonecrosis (Jones, 1971); 13 patients were male and 19 female. The average age when necrosis was diagnosed was 21 years for the transplant group and 43 years for the non-transplant group.

In these 32 patients, 71 lesions were found (Fig. 3). Approximately 25% of the lesions were in non-weight-bearing bones, and about 80% affected the proximal epiphyseal regions of bones (Fig. 4). Less commonly affected sites included the body of the talus, the proximal portion of the carpal scaphoid, and the condyles of the femur (Fig. 5).

Efforts were made to obtain presumptive evidence of systemic fat embolism in 11 of these patients. Such evidence was detected in 6 of them. Fat globules were consistently found in the urine of 5 patients; in 2 of them renal glomerular fat was demonstrated by biopsy. Two patients appeared to have intravascular fat globules in their necrotic femoral heads (Jones, 1971).

Sutton *et al.* (1963) reported 8 cases of corticosteroid-induced osteonecrosis and reviewed 62 others. Sutton (1968) again reviewed the subject and considered aseptic necrosis of bone to be a definite complication of corticosteroid therapy. More than 175 cases had been reported in the world literature by 1971. Fisher and Bickel (1971) noted that all cases have had certain common features: *1*) None was associated with significant trauma; *2*) none was associated with conditions usually considered to cause nontraumatic avascular necrosis; *3*) corticosteroids had been given systemically in excess of physiological requirements for prolonged periods, either reg-

Table I. ANALYSIS OF OSTEONECROSIS AS A COMPLICATION IN RENAL TRANSPLANTATION

Series	Number of kidney transplant recipients	Number of recipients with osteonecrosis	% osteonecrosis
Harrington *et al.* (1971)	204	18	8.8
Cruess *et al.* (1968)	27	10	37.0
Najarian, J. D. (personal communication)	290	8	2.8
Evarts and Phalen (1971)	203	15	7.5
Fisher and Bickel (1971)	70	1	1.4
Irby and Hume (1968)	140	6	4.3
Bravo *et al.* (1967)	60	5	8.3
Totals	994	63	6.3

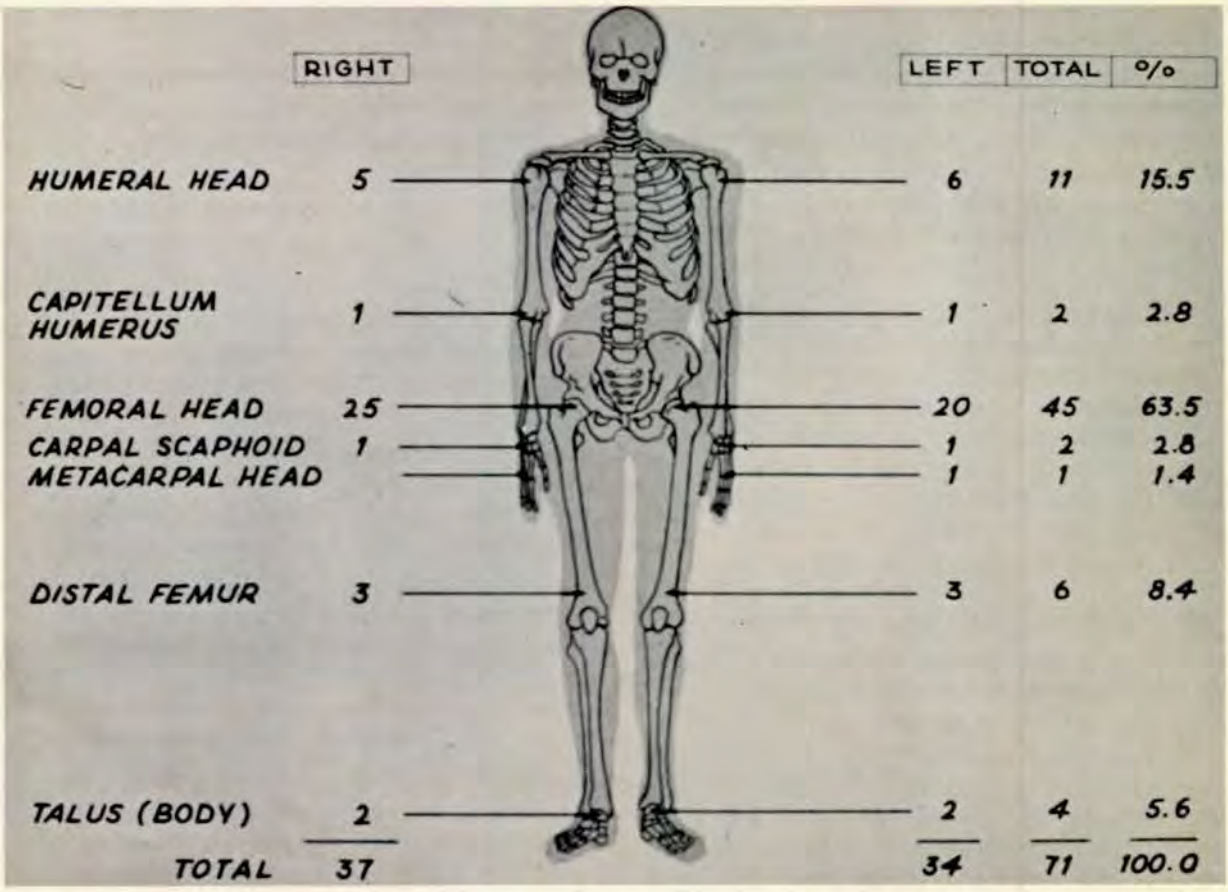

FIG. 3. Skeletal distribution of 71 osteonecrosis lesions, diagnosed roentgenographically, in 32 patients with hypercortisonism. (Jones, 1971. Illustration courtesy of publisher.)

ularly or intermittently; *4*) the diseases for which the therapy had been used were unrelated to the development of avascular necrosis.

Fisher and Bickel (1971) confirmed previous observations (Jones, 1971) by reporting intravascular fat emboli in 12 of the 25 femoral heads removed from 20 of 77 corticosteroid-treated patients with avascular necrosis seen at the Mayo Clinic from 1950 to 1968. Vasculitis had been proposed as the mechanism for vessel obstruction and subsequent ischemia. But no patient in this series had a clinical diagnosis of vasculitis, either prior to or after corticosteroid therapy. No consistent coagulation defects were noted in 16 patients studied in this series. Bromsulphalein retention was abnormal in 15 of 26 patients tested; however, 25 of the 77 patients receiving corticosteroids were also alcoholics.

Hemoglobinopathies

Diggs *et al.* (1937) first recognized femoral-head abnormalities in patients with sickle-cell disease. Diggs and Anderson (1971), as well as Chung and Ralston (1969), have reviewed aseptic necrosis of the femoral head in sickle-cell anemia and its genetic variants. Chung and Ralston (1971) have also recently reviewed necrosis involving the humeral head associated with sickle-cell anemia (SS hemoglobin) and the sickle-cell variants (SC disease and S-thalassemia). Kimmelstiel (1948) suggested that a decrease in oxygen tension sufficient to cause sickling of the red blood cells—*i.e.*, Po_2 below 60 mm Hg in sickle-cell anemia, or O_2 tension of 15 mm Hg or below in sickle-cell trait (AS hemoglobin) — would lead to circulatory stasis productive of thrombosis and occlusion of the epiphyseal blood supply.

FIG. 4. Shoulders of patient receiving corticosteroids for immunosuppression following renal transplantation: (*a*) subchondral radiolucent crescent line with minimal structural collapse and subjacent sclerosis affecting L humeral head; (*b*) obvious structural collapse with articular incongruity in R humeral head.

FIG. 5. A-P projection of R knee of patient receiving high-dosage corticosteroids for immunosuppression following renal transplantation. Subchondral osteochondritic lesion (arrow) affects central third of R medial femoral condyle with minimal gross distortion of joint space.

The frequency of femoral-head involvement observed as SS disease has varied from 0% in the 120 cases studied by Cockshott (1963) in West Africa to 12% in the 51 cases studied by Tanaka and co-workers (1956) in the United States. On the other hand, hip involvement in SC disease has been found to vary from 20% to 68% by Barton and Cockshott (1962) and Smith and Conley (1954). Of the 13 patients with sickle-cell hemoglobinopathies and femoral-head necrosis reported by Chung and Ralston (1969), 7 had SS disease, 2 had SC disease, 2 had S-thalassemia, and 2 had sickle-cell trait. Osteonecrosis had been reported earlier by Ratcliff and Wolf (1962) in 2 cases of sickle-cell trait and by Blau and Hamerman (1967) in 1 patient.

Reich and Rosenberg (1953) first reported avascular necrosis of bone in Caucasians with chronic hemolytic anemia due to combined sickling and thalassemia traits, and in blacks with S-Thal disease by Golding and co-workers (1959). In addition, osteonecrosis has been found in the hereditary persistence of fetal hemoglobin associated with the sickle-cell gene (SF) by Conley *et al.* (1963) and by Jacob and Raper (1958). Moseley and Manly (1953) concluded that there was no direct correlation between the severity of the hemoglobinopathy and the occurrence of bone necrosis in their 5 cases.

Roentgenograms of the shoulders and hips were performed by Jones and Johnston (1972) on 38 patients with various hemoglobinopathies, 7 of whom (18%) had evidence of avascular necrosis. Two of 21 patients with SS hemoglobin had involvement of the femoral head (Fig. 6 and 7), whereas 3 of 13 patients with SC disease had osteonecrosis. In 2 of 4 patients with S-Thal disease, roentgenographic evidence of avascular necrosis was found.

It is generally considered that the pathogenesis of necrosis in the sickle-cell hemoglobinopathies is as follows: In the presence of lowered O_2 tension the sickle hemoglobin causes increased blood viscosity, stasis, capillary thrombosis, and, finally, infarction. It is conceivable that small intraosseous vessels are thrombosed many times throughout life. But collateral blood supply and regenerative capacity, especially in the young

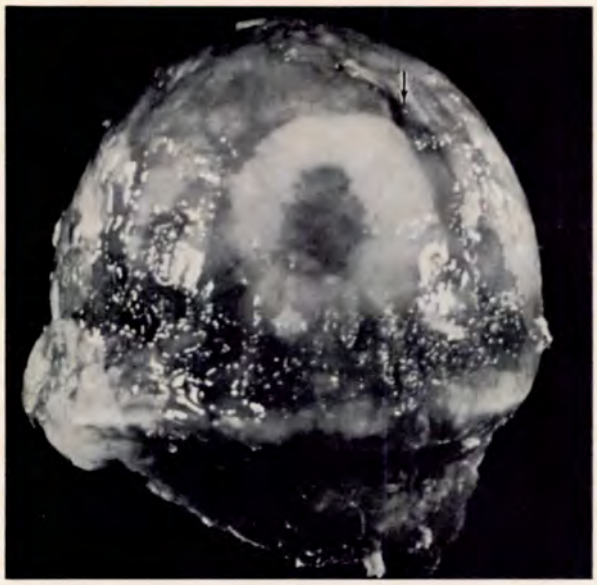

FIG. 6. Gross appearance of anterior-superior quadrant of L femoral head of 28-year-old black female with sickle-cell hemoglobinopathy. Small cleft (arrow) extends through cartilage medial to the light ring-shaped area with dark central discoloration, affecting cartilage and subchondral bone of necrotic zone.

individual, may prevent manifestations of bone necrosis, whereas frequent thromboses probably result in clinically obvious osteonecrosis.

Unfortunately, few femoral- or humeral-head specimens from patients with the sickle-cell hemoglobinopathies have been available for histological examination. Sherman (1959) studied 3 specimens from SS patients and suggested that hip-joint destruction depends on several mechanisms, all secondary to local damage to extremely small vessels. However, no investigator has actually found sickled erythrocytes within vessels adjacent to the necrotic area, although Tanaka *et al.* (1956) found blood vessels thrombosed within the necrotic area, which they assumed were caused by the sickling phenomenon. Chung and Ralston (1969) examined bone specimens from 2 patients, which had histological evidence of avascular necrosis but were without sickle-cell thromboses.

Reynolds (1965) suggested that, following sickle-cell crises, intravascular sickling occurs, resulting in increased blood viscosity and vascular stasis with progression to tissue ischemia and infarction. In the absence of bone-marrow and/or fat emboli, however, on tissue examination he noted no overt thromboses in the classic pathological sense.

Charache and Page (1967) studied the frequency of demonstrable marrow necrosis in SS patients, and noted that bone-marrow infarction is not necessarily an irreversible event in patients with sickle-cell disorders. Bone-marrow aspirations revealed that infarction is probably a relatively common event in the painful crises of sickle-cell disorders, occurring 1 to 3 days after the onset of pain. Inflammatory reaction was present 3 to 7 days after the onset of pain, followed by a phase of hypocellularity lasting 1 to 2 weeks after the crisis began. Within 1 month following a crisis, the bone-marrow cavity was repopulated by normal hematopoietic tissue.

Myerson (1959) established that the incidence of SS disease was approximately three times greater than that of SC disease in the American black population — *i.e.*, 1:1000 and 1:3000, respectively. Nevertheless, the incidence of avascular necrosis is higher in SC disease, but the crises are fewer and milder with no acceleration of erythrocyte destruction. In addition, osteonecrosis involving the femoral and humeral heads is uncommon in children with hemoglobinopathies who are under age 15.

Between 1953 and 1965 Charache and Page (1967) autopsied 6 SC and 12 SS patients. Bone-marrow necrosis and pulmonary-marrow and pulmonary-fat embolism were found in 3 of the SC patients and 2 of the SS patients. It is thought that fat embolism is less common in SS than in the genetic variants because the marrow in sickle-cell anemia is red and cellular (erythroid hyperplasia), containing little fat, whereas in sickle-cell trait (or in combination diseases) it is predominately fatty.

There are at least 17 reports of fat embolism complicating the sickle-cell hemoglobinopathies, particularly SC disease. The most recent include Graber (1961), Rywlin *et al.* (1963), and Diggs (1967), who suggest that the sequence of events productive of bone-marrow and fat emboli is as follows: There is massive sickling of erythrocytes in bone-marrow capillaries and sinusoids, cessation of blood flow in focal areas, hypoxia, endothelial injury with edema, hemorrhage, and the exudation of leukocytes with liberation of proteolytic enzymes, cellular degeneration and disintegration, and probable fibrinolysis. The increase in intramedullary pressure drives fat globules in the semiliquid marrow into intraosseous

FIG. 7. Gross sagittal sections of L femoral head of patient with SS hemoglobin, at level of *fovea centralis*, revealing irregular subchondral lesions in superior region of head and fracture cleft (arrow) extending into cartilage. Note marked erythroid hyperplasia of bone marrow.

veins, which are maintained patent by their attachment to the rigid trabecular and cortical bone. Jones and Johnston (1972) are studying an alternative hypothesis, which attributes the increased incidence of avascular necrosis affecting epiphyseal regions (particularly in SC disease) to possible blockade of terminal intraosseous vessels by intermittent systemic fat emboli arising from fatty bone marrow.

There is insufficient evidence to implicate sickle-cell trait (AS) as a predisposing condition for the development of osteonecrosis. AS is present in 8% to 10% of American blacks (Myerson, 1959). The coexistence of any two relatively common but unrelated entities in five reported patients with AS and avascular necrosis may therefore be purely coincidental.

Antecedent Unrelated Injuries

Individuals who experience multiple major, apparently unrelated injuries may incur a higher risk than normal of developing idiopathic ischemic necrosis of the femoral head. Two patients who had sustained multiple fractures and subsequently experienced idiopathic bone infarctions were observed by Kahlstrom *et al.* (1939). Jones (1971) and G. E. Sims (personal communication) each reported on a patient who had experienced idiopathic osteonecrosis of the right femoral head following multiple unrelated trauma. It is conceivable that in these instances multiple episodes of unrecognized traumatic fat embolism may have been the pathogenic mechanism.

Neither of these cases had clinical or roentgenographic evidence of prior hip fractures or dislocations, but it is possible that a nondisplaced femoral-neck fracture was missed at a time when attention was directed toward treatment of other injuries. Although fatigue (stress) fracture of the femoral neck was first reported by Blecher (1905), this entity is relatively uncommon. Prior to 1966 only 124 femoral-neck fatigue fractures had been reported in the literature. Devas (1965) and Blickenstaff and Morris (1966) recently reviewed the world literature; the latter reported 41 such fatigue fractures in 36 patients. They recognized that posttraumatic femoral-head avascular necrosis is extremely unlikely in incomplete or nondisplaced fatigue fractures, which

usually heal with progressive sclerosis (endosteal and/or periosteal callus).

Occlusive Vascular Disease

Although relatively few divers or compressed-air workers have severe occlusive vascular disease, advanced arteriosclerosis should be checked on in preemployment examinations. The reason is that osteonecrosis has been reported following the Leriche syndrome (Hughes *et al.*, 1971), thrombotic occlusion and intimal thickening (Hirsch, 1938), and vascular occlusion resulting from athero-emboli from distant atheromatous plaques (Bucky, 1959; Siller and Matthews, 1963; Bullough *et al.*, 1965). A review of many patients without evidence of osteonecrosis but with severe arteriosclerosis affecting the aorto-iliac portion of the vascular system leads to the conclusion that the association is probably relatively rare, in view of the number of individuals suffering from severe arteriosclerosis.

SUMMARY

Persons employed in deep-diving activities, hyperbaric-chamber operations, or compressed-air work are subject to dysbaric osteonecrosis. But there are certain other systemic and metabolic abnormalities associated with nontraumatic osseous avascular necrosis that likewise cause disabling juxta-epiphyseal lesions and asymptomatic metadiaphyseal lesions that are virtually indistinguishable from those of dysbaric osteonecrosis. However, once an individual has been exposed to dysbaric phenomena, any lesion that subsequently develops will unfortunately be attributed to the occupational exposure.

Therefore, applicants who have conditions associated with nontraumatic osteonecrosis, as well as previous dysbaric exposure, should be thoroughly evaluated during the preemployment examination. Many of these disturbances have been reviewed — alcoholism, gout, hyperuricemia, pancreatitis, hyperlipemia, hypercortisonism, hemoglobinopathies, earlier injuries, and occlusive vascular disease — all of which can be found in an otherwise healthy population of working men.

REFERENCES

Axhausen, G. (1928). Uber anamische infarkte am knochensystem und ihre bedeutung für die lehre von den primären epiphyseonekrosen. Arch. Klin. Chir. 151, 72-98.

Barton, C. J., and Cockshott, W. P. (1962). Bone changes in hemoglobin SC disease. Amer. J. Roentgenol., Radium Therapy Nucl. Med. 88, 523-532.

Blau, S., and Hamerman, D. (1967). Aseptic necrosis of the femoral heads in Sickle-A hemoglobin disease. Arth. Rheum. 10, 397-402.

Blauvelt, H. (1946). A case of acute pancreatitis with subcutaneous fat necrosis. Brit. J. Surg. 34, 207-208.

Blecher, A. (1905). Uber den einfluss des parademarsches auf die entstehung der fussgeschwulst. Med. Klin. 1, 305.

Blickenstaff, L. D., and Morris, J. M. (1966). Fatigue fractures of the femoral neck. J. Bone Joint Surg. 48-A, 1031-1047.

Boettcher, W. G., Bonfiglio, M., Hamilton, H. H., Sheets, R. F., and Smith, K. (1970). Nontraumatic necrosis of the femoral head. J. Bone Joint Surg. 52-A, 312.

Bravo, J. F., Herman, J. H., and Smyth, C. J. (1967). Musculoskeletal disorders after renal homotransplantation: A clinical and laboratory analysis of 60 cases. Ann. Intern. Med. 66, 87-104.

Bucky, N. L. (1959). Bone infarction. Brit. J. Radiol. 32, 22-27.

Bullough, P. G., Kambolis, C. P., Mascove, R. C., and Jaffe, H. L. (1965). Bone infarctions not associated with caisson disease. J. Bone Joint Surg. 47-A, 477.

Charache, S., and Page, D. L. (1967). Infarction of bone marrow in the sickle cell disorders. Ann. Intern. Med. 67, 1195-1200.

Chung, S. M. K., and Ralston, E. L. (1969). Necrosis of the femoral head in sickle cell anemia and its genetic variants. J. Bone Joint Surg. 51-A, 33-58.

Chung, S. M. K., and Ralston, E. L. (1971). Necrosis of the humeral head associated with sickle cell anemia and its genetic variants. Clin. Orthop. 80, 105-117.

Cockshott, W. P. (1963). Dactylitis and growth disorders. Brit. J. Radiol. 36, 19-26.

Conley, C. L., Weatherall, D. J., Richardson, S. N., Shepard, M. K., and Charache, S. (1963). Hereditary persistence of fetal hemoglobin: A study of 79 affected persons in 15 negro families in Baltimore. Blood 50-A, 1577.

Cruess, R. L., Blennerhassett, Jr., MacDonald, F. R., MacLean, L. D., and Dossetor, J. (1968). Aseptic necrosis following renal transplantation. J. Bone Joint Surg. 50-A, 1577-1590.

Devas, M. B. (1965). Stress fractures of the femoral neck. J. Bone Joint Surg. 47-B, 728-738.

Diggs, L. W. (1967). Bone and joint lesions in sickle-cell disease. Clin. Orthop. Rel. Res. 52.

Diggs, L. W., and Anderson, L. D. (1971). Aseptic necrosis of the head of the femur in sickle cell disease. In Idiopathic Ischemic Necrosis of the Femoral Head in Adults. Chapter VII. pp. 107-111. Ed. Zinn, W. M. Stuttgart, Germany: Thieme.

Diggs, L. W., Pulliam, H. N., and King, J. C. (1937). Bone changes in sickle cell anemia. Southern Med. J. 30, 249.

Evarts, C. M., and Phalen, G. S. (1971). Osseous avascular necrosis associated with renal transplantation. Clin. Orthop. 78, 330-335.

Fisher, D. E., and Bickel, E. H. (1971). Corticosteroid-induced avascular necrosis: A clinical study of seventy-seven patients. J. Bone Joint Surg. 53-A, 859-873.

Fredrickson, D. S., and Lees, R. S. (1965). A system for phenotyping hyperlipoproteinemia. Circulation 31, 321-327.

Gerle, R. D., Walker, L. A., Achord, J. L., and Weens, H. S. (1965). Osseous changes in chronic pancreatitis. Radiology 85, 330-337.

Golding, J. S., MacIver, J. E., and Went, L. N. (1959). Bone changes in sickle cell anemia and its genetic variants. J. Bone Joint Surg. 41-B, 711-718.

Graber, S. (1961). Fat embolization associated with sickle cell crisis. Southern Med. J. 54, 1395-1398.

Harrington, K. D., Murray, W. R., Kountz, S. L., and Belzer, F. O. (1971). Avascular necrosis of bone after renal transplantation. J. Bone Joint Surg. 53-A, 203-215.

Hartcroft, W. S., and Ridout, J. H. (1951). Pathogenesis of the cirrhosis produced by chlorine deficiency: Escape of lipid from fatty hepatic cysts into the biliary and vascular systems. Amer. J. Path. 27, 951-970.

Hartmann, G. (1971). The possible role of fat metabolism in idiopathic ischemic necrosis of the femoral head. In Idiopathic Ischemic Necrosis of the Femoral Head in Adults. Chapter X. pp. 140-144. Ed. Zinn, W. M. Stuttgart, Germany: Thieme.

Havel, R. J. (1969). Pathogenesis, differentiation and management of hypertriglyceridemia. Advan. Internal Med. 15, 117-154: Yearbook.

Hill, R. B. (1961). Fatal fat embolism from steroid-induced fatty liver. New Engl. J. Med. 265, 318-320.

Hirsch, E. F. (1938). Arterial occlusion with aseptic necrosis of bone. Arch. Surg. 37, 926-943.

Hughes, E. C., Jr., Schumacker, H. R., and Sbarbaro, J. L. (1971). Bilateral avascular necrosis of the hip following Leriche syndrome. J. Bone Joint Surg. 53-A, 380.

Hunder, G. G., Worthington, J. W., and Bickel, W. H. (1968). Avascular necrosis of the femoral head in a patient with gout. J. Amer. Med. Assn. 203, 47-49.

Immelman, E. J., Bank, S., Krige, H., and Marks, I. N. (1964). Roentgenologic and clinical features of intramedullary fat necrosis in bones in acute and chronic pancreatitis. Amer. J. Med. 36, 96-105.

Irby, R., and Hume, D. M. (1968). Joint changes observed following renal transplants. Clin. Orthop. 57, 101-114.

Jacob, G. F., and Raper, A. B. (1958). Hereditary persistence of foetal haemoglobin production and its interaction with sickle cell trait. Brit. J. Haematol. 4, 138.

Jones, J. P., Jr. (1971). Alcoholism, hypercortisonism, fat embolism and osseous avascular necrosis. In Idiopathic Ischemic Necrosis of the Femoral Head in Adults. Chapter VIII. pp. 112-132. Ed. Zinn, W. M. Stuttgart, Germany: Thieme.

Jones, J. P., Jr., and Engleman, E. P. (1966). Osseous avascular necrosis associated with systemic abnormalities. Arthr. Rheum. 9, 728-736.

Jones, J. P., Jr., Engleman, E. P., and Najarian, J. S. (1965). Systemic fat embolism after renal homotransplantation and treatment with corticosteroids. New Engl. J. Med. 273, 1453-1458.

Jones, J. P., Jr., and Johnston, J. O. [1972]. Unpublished data.

Kahlstrom, S. C., Burton, C. C., and Phemister, D. B. (1939). Aseptic necrosis of bone: II. Infarction of bones of undetermined etiology resulting in encapsulated and calcified areas in diaphyses and in arthritis deformans. Surg. Gynec. Obstet. 68, 631-641.

Kimble, S. T. (1961). Fatal nontraumatic fat embolism in an alcoholic. Med. Ann. D.C. 30, 283-287, 314.

Kimmestiel, P. (1948). Vascular occlusion and ischemic infarction in sickle cell disease. Amer. J. Med. Sci. 216, 11-19.

Lynch, M. J. G., Raphael, S. S., and Dixon, T. P. (1959). Fat embolism in chronic alcoholism: Control study of incidence of fat embolism. Arch. Path. 67, 68-80.

McCollum, D. E., Mathews, R. S., and O'Neil, M. T. (1971). Gout, hyperuricemia and aseptic necrosis of the femoral head. In Idiopathic Ischemic Necrosis of the Femoral Head in Adults. Chapter IX. pp. 133-139. Ed. Zinn, W. M. Stuttgart, Germany: Thieme.

MacMahon, H. E., and Weiss, S. (1929). Carbon tetrachloride poisoning with macroscopic fat in pulmonary artery. Amer. J. Path. 5, 623-630.

Malka, S. (1966). Idiopathic aseptic necrosis of the head of the femur in adults. Surg. Gynec. Obstet. 5, 123.

Mankin, H. J., and Brower, T. D. (1962). Bilateral idiopathic aseptic necrosis of the femur in adults: "Chandler's disease." J. Hosp. Joint Dis. 23, 42-57.

Mauvoisin, F., Bernard, J., and Germain, J. (1955). Aspect tomographic des hanches chez un goutteux. Rev. Rhum. 22, 336.

Moseley, J. E., and Manly, J. B. (1953). Aseptic necrosis of bone in sickle-cell disease. Radiology 60, 656-665.

Myerson, R. W. (1959). Incidence and significance of abnormal hemoglobins. Amer. J. Med. 26, 543.

Norris, R. F., and Potter, H. (1965). Hepatic inflammation in narcotic addicts. Arch. Environ. Health 11, 662-668.

Owens, G., and Northington, M. (1962). Liver lipid as a source of post-traumatic embolic fat. J. Surg. Res. 2, 283-284.

Patterson, R. J., Bickel, W. H., and Dahlin, D. C. (1964). Idiopathic avascular necrosis of the head of the femur: A study of fifty-two cases. J. Bone Joint Surg. 46-A, 267-282.

Peltier, L. F. (1956). Fat embolism: I. The amount of fat in human long bones. Surgery 40, 657-660.

Pietrogrande, V., and Mastromarino, R. (1957). Osteopatia da prolungato trattamento cortisonico. Ortop. Traumatol. 25, 791-810.

Ponfick, E. (1872). Uber die sympathischen erkrankungen des knochenmarkes bei inneren krankheiten. Arch. Path. Anat. 56, 534-556.

Ratcliff, R. G., and Wolf, N. D. (1962). Avascular necrosis of the femoral head associated with sickle cell trait (AS hemoglobin). Ann. Intern. Med. 57, 299.

Reich, R. S., and Rosenberg, N. J. (1953). Avascular necrosis of bone in Caucasians with chronic hemolytic anaemia due to combined sickling and thalassemia traits. J. Bone Joint Surg. 35-A, 894-904.

Reynolds, J. (1965). The Roentgenological Features of Sickle Cell Disease and Related Hemoglobinopathies. pp. 95-105. Springfield, Ill.: C. C. Thomas.

Rondier, J., Truffert, J., Le Go, A., Brouilhet, H., Saporta, L., de Gennes, J. L., and Delbarre, F. (1970). Goutte et hyperlipidémies (étude portant sur 50 goutteux et sur 50 sujets non goutteux). Revue Européenne d'études cliniques et biologiques 15, 959-968.

Rywlin, A. M., Block, A. L., and Werner, C. S. (1963). Hemoglobin C and S disease in pregnancy: Report of a case with bone marrow and fat emboli. Amer. J. Obstet. Gynec. 86, 1055-1059.

Schreiber, S. N. (1972). Extremity complications of heroin addiction. J. Bone Joint Surg. 54-A, 1578-1579.

Serre, H., and Simon, L. (1962). L'ostéonécrose primitive de la tête fémorale chez l'adulte: II. Etiologie et patholgenie. Rev. Rhum. 29, 536-545.

Sherman, M. (1959). Pathogenesis of disintegration of the hip in sickle cell anemia. Southern Med. J. 52, 632-637.

Siller, T. N., and Mathews, W. H. (1963). Atheromatous embolization to the proximal end of the femur in man and in experimental animals. Can. J. Surg. 6, 511-515.

Smith, E. W., and Conley, C. L. (1954). Clinical features of the genetic variants of sickle cell disease. Bull. Johns Hopkins Hosp. 94, 289-318.

Stimmel, B., Vernace, S., and Tobias, H. (1972). Hepatic dysfunction in heroin addicts: The role of alcohol. J. Amer. Med. Assn. 222, 811-812.

Sutton, R. D. (1968). Aseptic necrosis of bone: A complication of corticosteroid therapy. In Drug-Induced Diseases. Vol. 3. pp. 171-176. Ed. Myer, L., and Peck, H. M. Springfield, Ill.: C. C. Thomas.

Sutton, R. D., Benedak, T. G., and Edwards, G. A. (1963). Aseptic bone necrosis and corticosteroid therapy. Arch. Internal Med. 112, 594-602.

Tanaka, K. R., Clifford, G. O., and Axelrod, A. R. (1956). Sickle cell anemia (homozygous S) with aseptic necrosis of femoral head. Blood 11, 998-1012.

Thibodeau, A. A., and Ames, D. L. (1968). Idiopathic avascular necrosis of the femoral head in adults. J. Bone Joint Surg. 50-A, 836.

Vignon, G., Duquesnél, J., Drogue, M., and Vezat, Y. (1960). Les nécroses primitives de la tête fémorale chez l'adulte (à propos de 9 observations). Rev. Lyon. Med. 9, 1177-1183.

Wissinger, H. A. (1963). Gouty arthritis of the hip joints. J. Bone Joint Surg. 45-A, 785.

Zinn, W. M. (1971). Clinical picture and laboratory findings. In Idiopathic Ischemic Necrosis of the Femoral Head in Adults. pp. 9-33. Ed. Zinn, W. M. Stuttgart, Germany: Thieme.

DISCUSSION 4

Dr. WALDER: I should just like to put Dr. Jones's and Dr. Boettcher's presentations into proper perspective for the divers present, because there are probably some of this group who know little or nothing about medicine.

These two speakers both emphasized the importance of alcohol as a causative agent in bone necrosis. I would agree that alcohol is one factor that may be associated with aseptic bone necrosis, but there is also good evidence that the disease is associated with such conditions as steroid therapy, sickle-cell anemia, diabetes, cirrhosis of the liver, hepatitis, ionizing radiation, alcaptonuria, pancreatitis, Gaucher's disease, trauma, rheumatoid arthritis, gout, syphilis, and arteriosclerosis.

Probably most compressed-air workers and possibly all divers fit into the definition of an alcoholic that has just been given. (I think that I probably fit into it as well!) What we really need, before we can come to any conclusions about this matter, is a controlled study of equal numbers of alcoholics and divers to see if there is a statistical difference between the two groups in the incidence of bone necrosis. No doubt alcohol is a factor, but I do not think that it is a very important factor.

In England we examined a control group of 120 men who were about to be employed as caisson workers. They were of the same age, build, and drinking habits as those already employed as caisson workers. We did not find one bone lesion amongst the 120, so that — in my country, at least — we would not be prepared to attach much importance to alcohol in the etiology of bone necrosis.

Dr. FAIRCHILD: Do you feel that there would not even be an exacerbation of bone necrosis with excessive alcohol intake, comparable to the effect of cigarette smoking in pulmonary diseases (*e.g.*, asbestosis and berylliosis)?

Dr. WALDER: I admit that alcohol may be a minor secondary factor.

Another point is this: I am much impressed with the Washington State tables and the results that we have seen from them. But it is important to remember that, in England, we work an 8-hr shift. The men actually work for 8 hr under pressure and then undergo decompression. This is not the case with the Washington State tables, except at pressures less than 18 psig.

The so-called 8-hr shift of the Washington State tables includes the decompression time, so that the time of work under maximum pressure decreases as work pressure increases. For example, at 30 psig the period of actual work lasts only 5 hr. I think that we must wait until we have sufficient facts before we can compare the British Blackpool tables and the U.S. Washington State tables realistically.

PART V

EXPERIMENTAL STUDIES

EXPERIMENTALLY INDUCED OSTEONECROSIS IN MINIATURE SWINE

KENT H. SMITH
PHYLLIS STEGALL

Ohta *et al.* (1965) have reported on the incidence of aseptic bone necrosis in professional divers at Ariake Bay in Japan. The Bay's seabed, from which shellfish are harvested from October until March, lies at a depth of from 10 to 30 meters.

There are approximately 400 professional divers living in Takesaki, a small village on Ariake Bay. At 16 to 17 years of age, the boys begin training as divers. By the age of 18 to 20, they are working as professional divers and continue as such until they are about 40 to 45 years old. Each diver spends two 4-hour shifts on the sea bottom, interrupted by a 30- to 60-minute rest period during the noon meal. During his underwater work shift, the diver never surfaces.

Of the 301 Ariake Bay divers examined, 50.5% showed some form of bone lesions radiographically. Men between the ages of 20 and 29 years had a 35% incidence of demonstrable bone lesions; those between 30 and 39 years, a 68% incidence; those between 40 and 49 years, a 78% incidence; and those 50 and over, a 71% incidence.

To study further the observed incidence of osteonecrosis in relation to compression–decompression stress, we exposed miniature swine to standard profiles of 60 FSW for 6 hours. The profile was repeated daily with a decompression rate of 30 feet per minute (fpm) for 35 to 50 "dives." Initially the animals tolerated the exposures with no external signs of decompression sickness. After 25 to 30 dives, however, the animals began to manifest signs of bends after each one, although they did not always require recompression. To protect the animals' lives, the decompression rate was reduced to 1.33 fpm at this point. Even with this prolonged decompression period, dysbarism did occur in some animals.

Hemodynamic and blood-chemistry studies included platelet count, complete blood count, hematocrit, hemoglobin, reticulocyte count, clotting times, prothrombin time, partial thromboplastin time, quantitative fibrinogen, and platelet adhesiveness. Serum studies included uric acid, alkaline phosphatase, serum glutamic oxaloacetic transaminase (SGOT), lactic acid dehydrogenase (LDH), creatine phosphokinase (CPK), calcium, and phosphorus. Lipid chemistries included phospholipids, triglycerides, cholesterol, cholesterol esters, and total lipids.

Red and white cell counts, hematocrit, hemoglobin, and reticulocyte counts showed no significant changes following these exposure profiles. Control and postdive platelet counts for four animals are shown in Fig 1. All four showed a



FIG. 1. Platelet changes in a group of 4 miniature pigs simultaneously exposed to 60-FSW/6-hr profiles, followed by 2-min decompression. Samples drawn after Dives 11, 26, and 43 are compared with baseline values.

decrease from their predive control sample following the chamber exposures. An additional animal — which was serially measured during a 60-FSW/6-hr exposure profile with a 30-fpm decompression rate — had a control platelet count of 430,000/mm³. One hour postdive the count had dropped to 320,000/mm³. The 24-hr count was 200,000/mm³, and the 48-hr count, 120,000/mm³. The control platelet count of another pig was 400,000/mm³ after he had "sur-

Preceding page blank

faced" from 60 FSW/6 hr, but the count had decreased to 74,000/mm³ one hour later.

Clotting, prothrombin, and partial thromboplastin times showed no significant changes. In the case of one typical pig, quantitative fibrinogen levels increased markedly after the 15th dive, following which the decompression rate was changed from 1.33 fpm to 30 fpm (Fig. 2). Platelet adhesiveness increased as much as 38% following these same exposures. Note that the exposure profiles underwent several changes throughout the period of this animal's diving history.

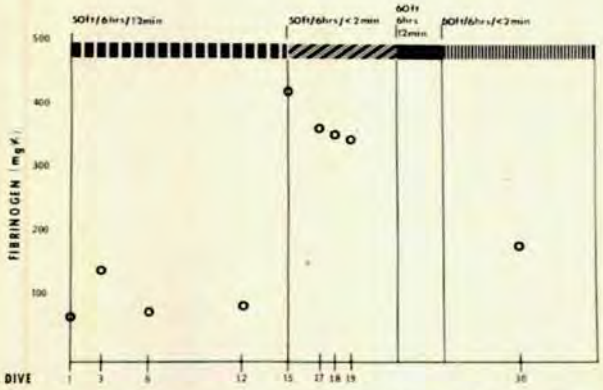

FIG. 2. Fibrinogen responses of TRF-strain miniature pig (Sarah) after her first fast decompression. From a control value of 73 mg %, fibrinogen level was elevated to 427 mg % in sample drawn 1 hr after surfacing in 2 min from 50 FSW/6 hr.

Uric acid, alkaline phosphatase, SGOT, LDH, calcium, and phosphorus values showed no significant change following these exposures. Creatine phosphokinase measurements, which were routinely elevated as the number of exposures increased, are shown in Fig. 3. Phospholipids, triglycerides, cholesterol, cholesterol esters, and total lipid values revealed no significant change.

As the purpose of these experiments was to produce aseptic bone necrosis, they were conducted on the tacit assumption that bends is a decompression phenomenon, probably caused by an inadequate decompression procedure. Although it was intended to induce dysbarism in the animals, it was not intended that the exposures be fatal. Nonetheless several animals were lost to acute decompression sickness after 35 to 40 asymptomatic exposures.

There now follows a brief radiographic history and histopathologic study of several typical animals.

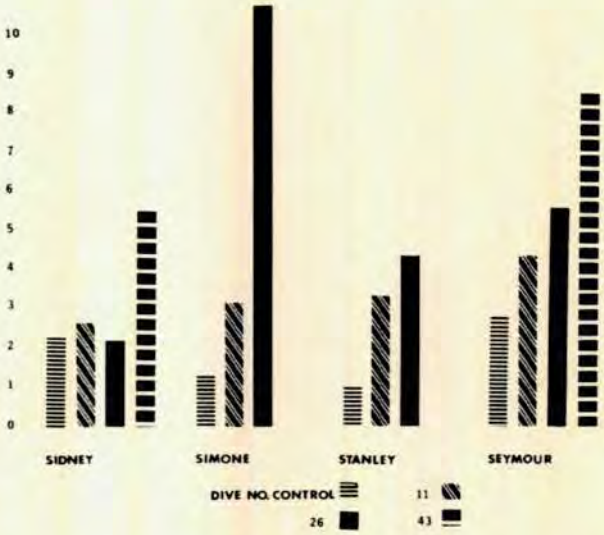

FIG. 3. Creatine phosphokinase levels in a group of 4 miniature pigs simultaneously exposed to 60 FSW/6-hr profiles with 2-min decompression. Changes after Dives 11, 26, and 43 are compared with baseline values.

1. Sarah, a 3-year-old TRF-strain miniature pig, underwent a series of 35 exposures. The control radiographs of her femoral and humeral heads and shafts were reported unremarkable. By 22 April 1971 (Fig. 4*a*) — 2½ months after her initial hyperbaric exposure — a slight irregularly marginated radiolucency, measuring 3 cm, appeared in the subtrochanteric area of her left femur. Sclerotic areas of bony trabeculation developed in the metaphyseal portion of the femurs bilaterally by 1 July 1971. Further progression in the densities, which now had the definite appearance of bone infarcts, was reported on 14 September 1971 (Fig. 4*b*). Specimens removed from one femur at biopsy on 25 September 1971 contained nonviable cortical and cancellous bone (Fig. 5) and fat necrosis (Fig. 6). (The radiograph shown in Fig. 7 demonstrates the biopsy site.) A diagnosis of aseptic bone necrosis was made.

By November 1971 Sarah began to limp on her right front leg. A radiograph taken that month revealed an irregular sclerotic deformity in the proximal shafts of the humeri, predominantly on the right. Further progression in the femoral bony infarcts was also noted at that time. Fol-

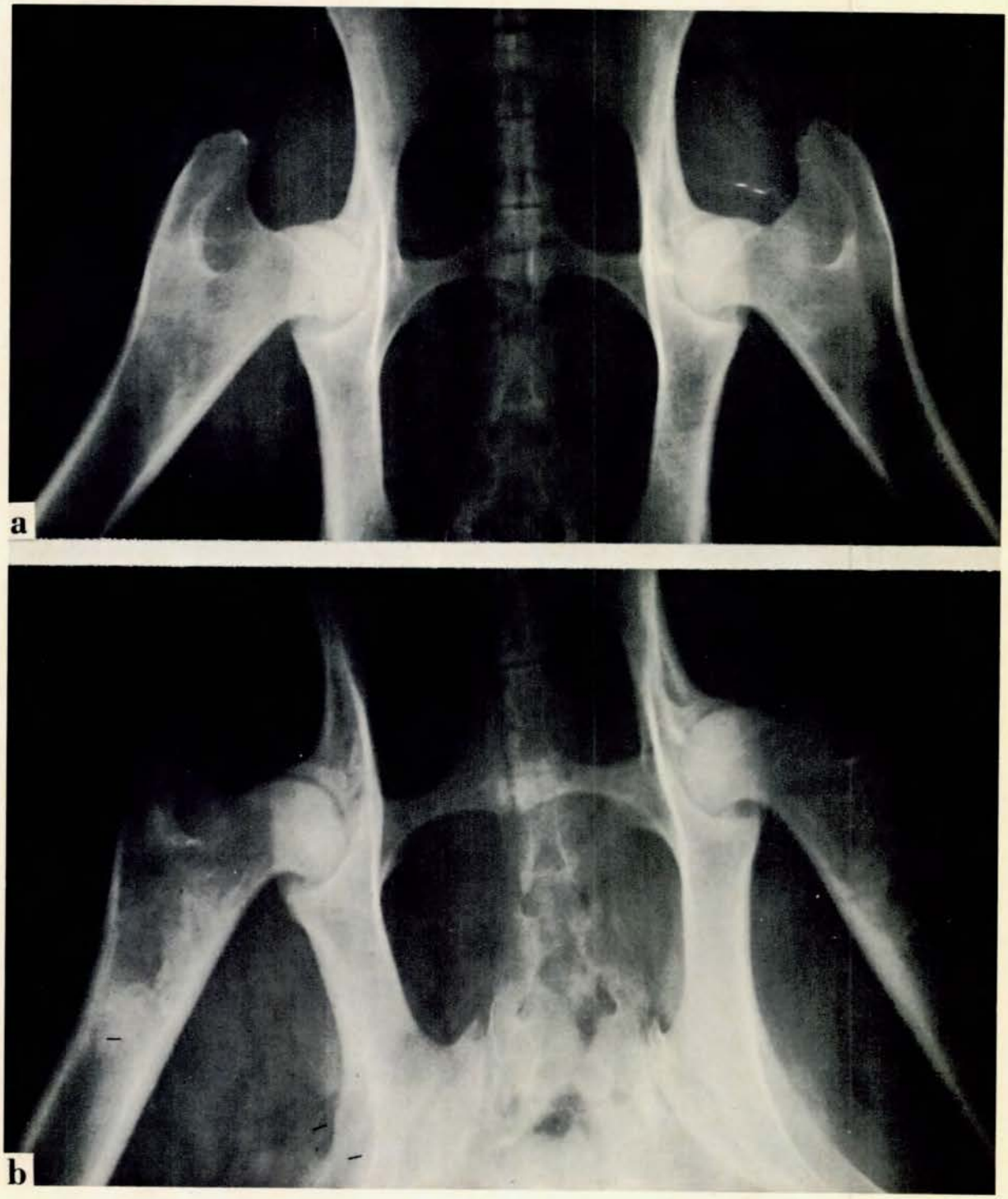

FIG. 4. Femurs of miniature pig Sarah. (*a*) Irregularly marginated lucency (arrow) appeared in subtrochanteric area of L femur 2½ months after animal was first exposed to compression-decompression stress; (*b*) 5 months later, lesion in L femur had progressed and a second lesion appeared in R femur.

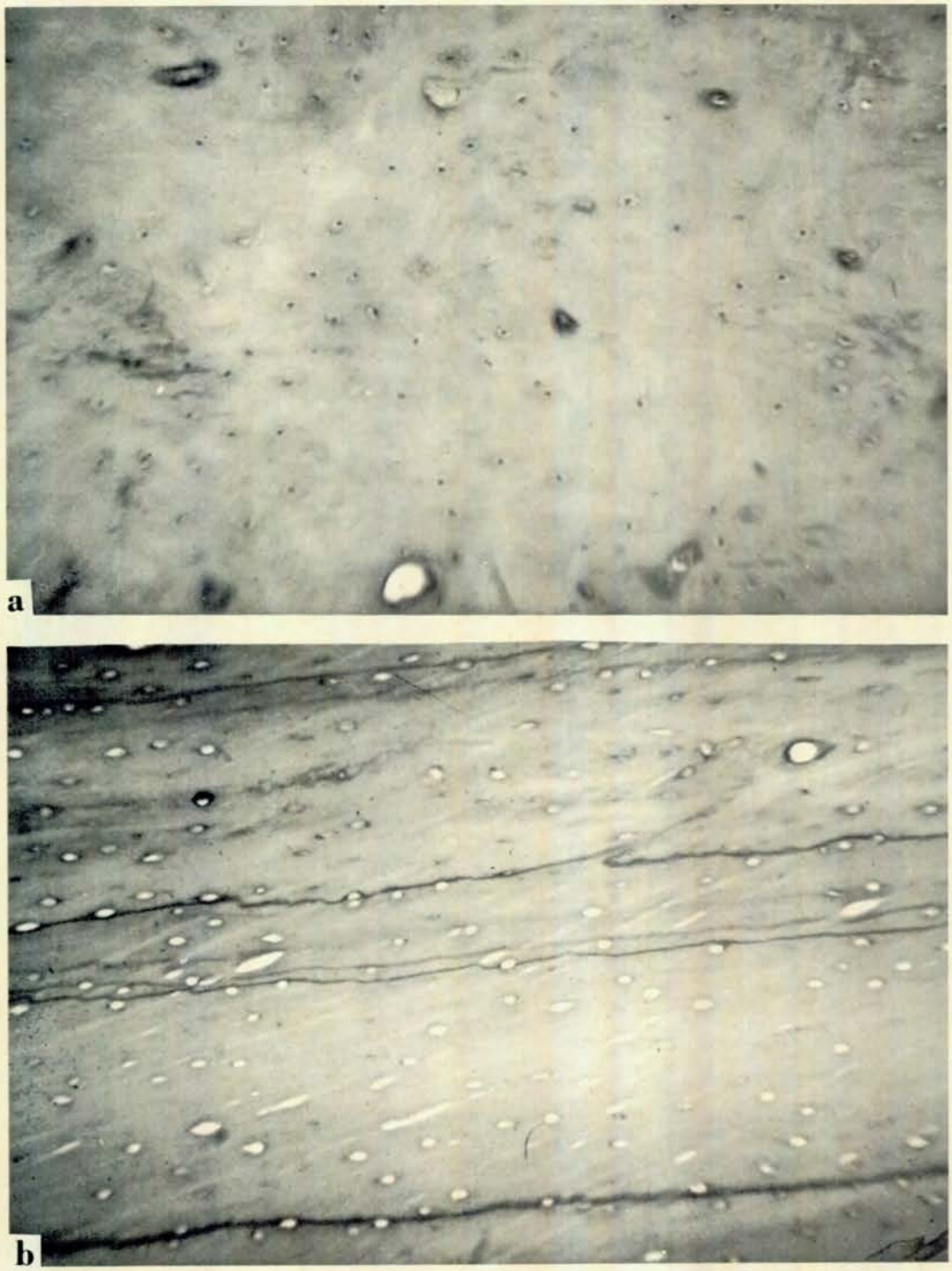

FIG. 5. Biopsied specimens from femur of miniature pig Sarah. (*a*) Small black dots are osteocytes within lacunae of bony matrix in normal specimen. (*b*) White spaces are lacunae devoid of osteocytes, a picture consistent with appearance of aseptic bone necrosis. Larger white spaces are Haversian canal systems whose vessels have degenerated.

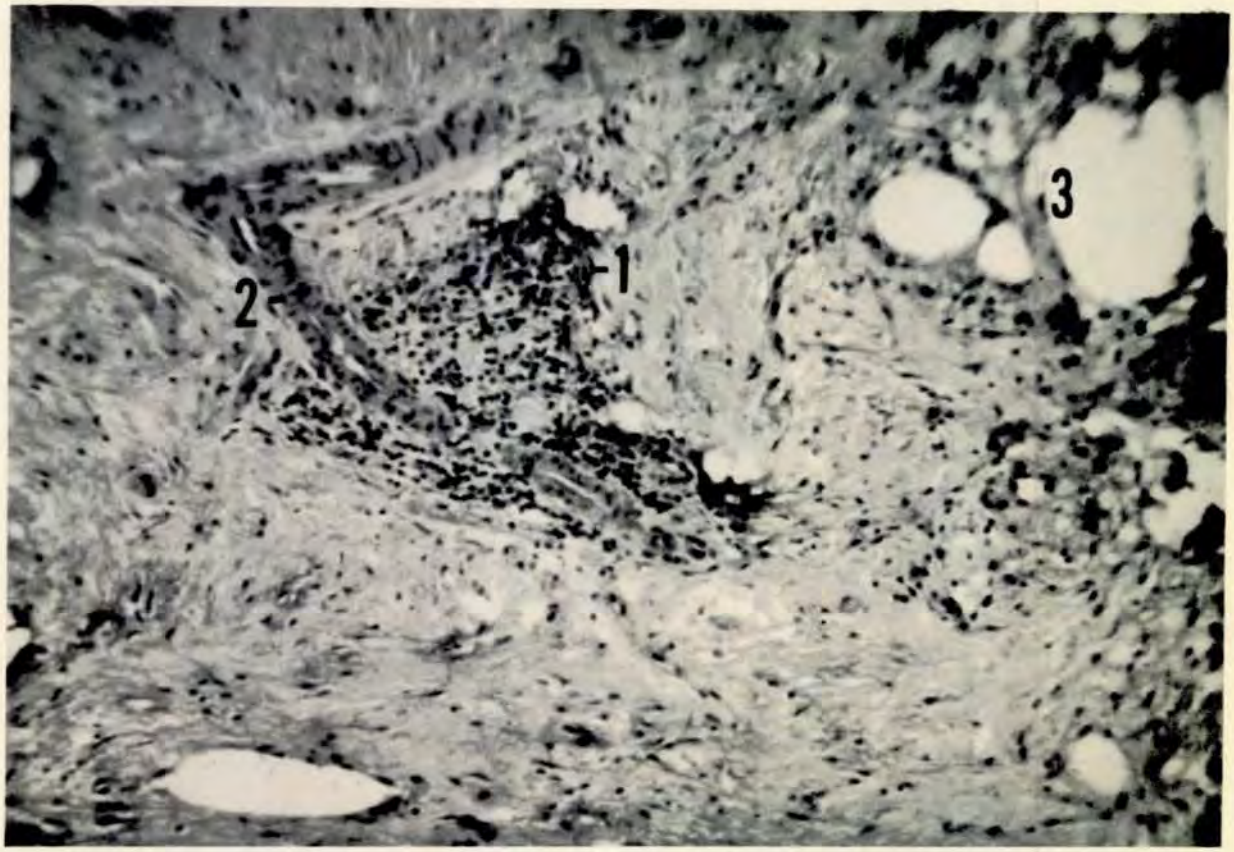

FIG. 6. Fat-marrow necrosis in biopsied specimen of pig femur (Sarah). Lymphocytic infiltration is seen (1) in early stage of fibrosis with compression of a small vessel and (2) in dense tissue. In area marked (3) are seen a few normal fatty marrow cells.

low-up films in January 1972 showed progression in trabecular distortion and periosteal reaction in the femoral midshafts with some remottling and healing occurring around the biopsy site. Humeral radiographs showed increased cortical thickening as well as endosteal and periosteal proliferation (Fig. 8).

2. Sidney, a 2-year-old Hormel-strain miniature pig, underwent 80 dives. After 33 exposures over a period of two months, a bilateral radiolucency was discovered in one femoral metaphysis. After 44 dives, radiographs showed definite new, mixed, sclerotic, and radiolucent patterns in the metaphyseal areas of both femurs. There were, as well, new findings of endosteal proliferation with calcification in one humerus (Fig. 9) — the probable result, in our opinion, of the animal's continuous exposure to an inadequate decompression profile.

3. Bentley, a 3-year-old Hanford-strain miniature pig, developed a severe case of decompression sickness on the 22nd dive. He remained paraplegic after four days of treatment and was then sacrificed. Histologic studies revealed bubbles, plasma pooling, red-cell aggregation, and platelet clumps indicative of possible disseminated intravascular coagulation.

4. Simone, a 2-year-old Hormel-strain miniature pig, died of acute decompression sickness within an hour after surfacing from her 48th dive. Areas of advanced bone necrosis, not seen radiographically, were found in a histologic study of her tissues; there was intravascular vacuolation throughout her whole system. Since these

FIG. 7. Further progression in sclerotic bony infarcts in femurs of miniature pig Sarah; radiograph taken 7 months after that in Fig. 4*a*. Site of biopsy, performed 2 months earlier, is marked by arrow.

FIG. 8. Irregular sclerotic deformities in proximal humerus of miniature pig Sarah, consistent with aseptic bone necrosis developing bilaterally in femurs. X-ray was taken 9 months after that in Fig. 4*a* and almost 3 months after that in Fig. 7.

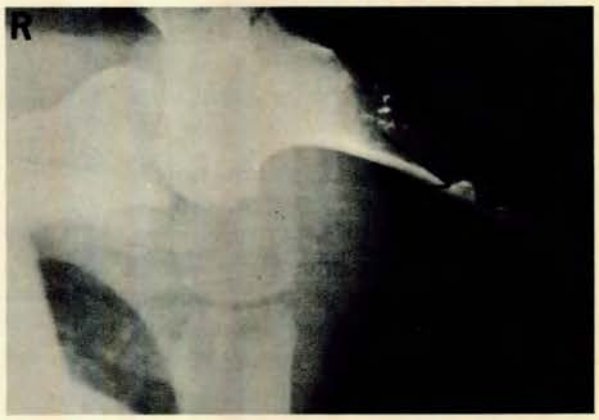

FIG. 9. Humerus of Hormel-strain miniature pig (Sidney) after 44 "dives," revealing endosteal proliferation and scattered calcifications.

spaces did not take up a fat stain, it is possible that the vacuoles were bubbles. New appositional bone containing osteocytes being laid down around a section of dead bone is seen in Fig. 10.

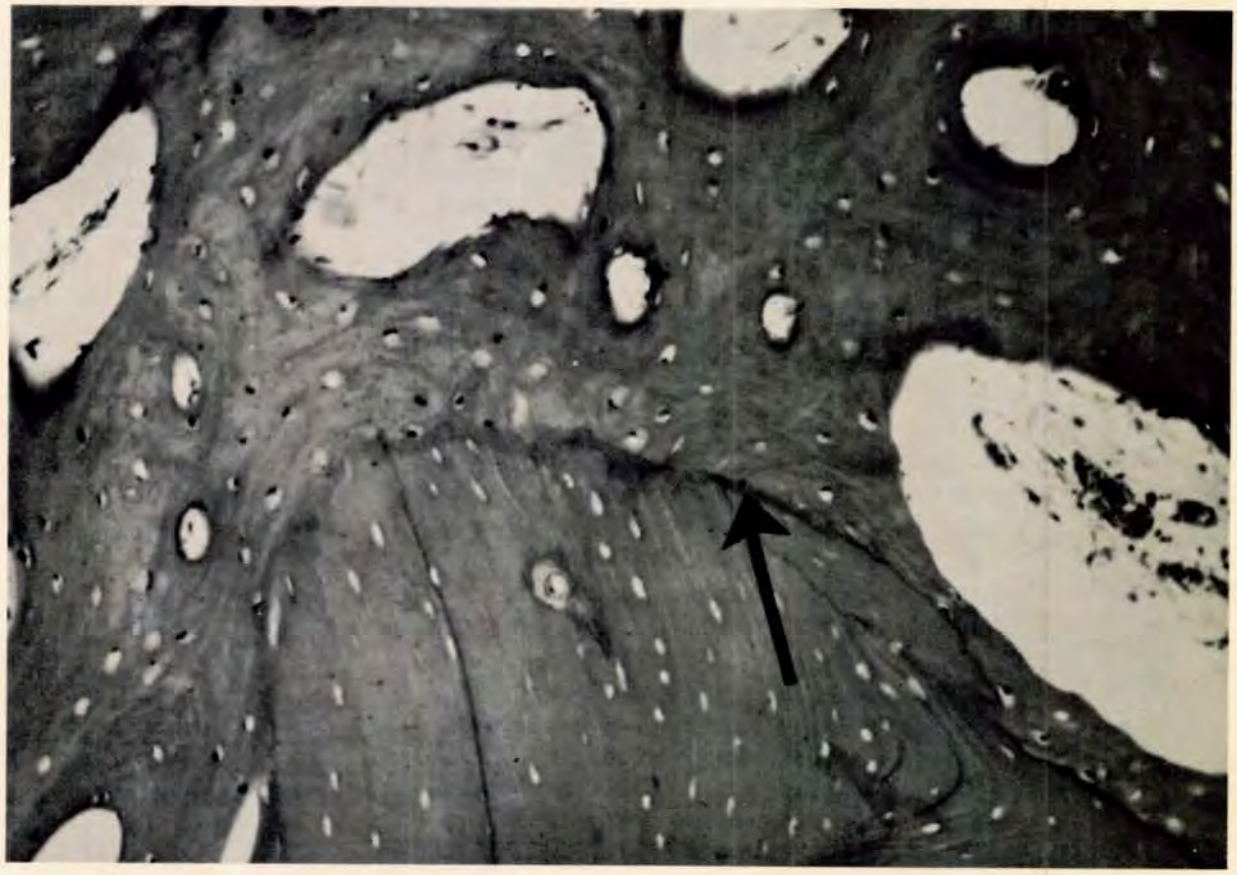

FIG. 10. New appositional bone formation in miniature pig (Simone) occurring on nonviable bone structure with definite line of demarcation (arrow). This animal had no radiographic evidence of necrosis.

As illustrated in this study, the most profound consequence of exposure to inadequate decompression profiles is aseptic bone necrosis. The study also produced initial evidence of severe hematologic changes, which occur simultaneously with bubble formation or as a result of it. All links in the chain stretching from initial hyperbaric insult to osteonecrosis have, of course, not been identified. Nevertheless, the connection between bubble formation — with alterations in the clotting mechanism — and the resulting infarcts in the small vasculature supplying nutrition to bone cells is generally recognized.

Ongoing studies are being designed to investigate and isolate more specifically the observed hemostatic and cellular alterations that occur when decompression rates are inadequate. Only then can the gap be filled between bends and bubbles on the one hand and bone necrosis on the other.

REFERENCE

Ohta, Y., Matsunga, H., and Shigeto, O. [1965]. Divers in Japan and their bone lesions. Unpublished data.

EXPERIMENTALLY INDUCED OSTEONECROSIS IN ANIMALS

DENNIS N. WALDER

Kent Smith is to be congratulated on being the first to produce and demonstrate bone lesions in large mammals following multiple exposures to high pressure. The difficulty in inducing dysbarism-related osteonecrosis experimentally in these animals has been a stumbling block in the study of the disease for many years. Dr. Smith's success is unlikely to be repeated in every laboratory, however, as it appears that mini-pigs, with which his work was done, are so ferocious that it takes a brave man to insult them repeatedly!

Interestingly enough, the osteonecrotic lesions found in these mini-pigs do not appear to be identical with either form of the disease known to be typical in man. Two distinct types of lesions are seen in experienced divers and compressed-air workers. In one, the subcortical regions of the heads of the humerus and femur are involved (Fig. 1). In the other, the shafts of the femur and tibia are affected, so that the changes are localized primarily in the medullary cavity (Fig. 2).

FIG. 1. Juxta-articular lesions of aseptic osteonecrosis in all 4 major joints of compressed-air worker.

FIG. 2. Osteonecrotic medullary lesion at lower end of human femoral shaft.

Preceding page blank

Whether or not the lesions seen in Dr. Smith's mini-pigs and those seen in man have similar causality, it is still necessary to determine their etiology. Are all these lesions the result of interruptions in blood circulation within bone — for instance, by gas bubbles or other embolic material arising as a secondary phenomenon in decompression? Or is there some other explanation, such as osmotic pressure effects or hormonal disturbances?

Many research workers over the years have attempted to find answers to these questions by experiments in which animals have been exposed to hyperbaric conditions, but success has been minimal. In an effort to throw light on this problem, therefore, the effect of mechanically interfering with the blood supply to the femoral head in sheep has been investigated at the University of Newcastle upon Tyne's Department of Surgery.

In all, 18 sheep were operated upon. The lateral or superior epiphyseal vessels to one femur and its capsule were cut. The femoral head was thereafter supplied only by a small leash of vessels known as the medial or inferior epiphyseal vessels; possibly a few vessels passing through the ligamentum teres were left as well.

The 18 sheep were then put out to graze, and both hip joints of each animal were X-rayed at regular intervals. Eight of the 18 sheep developed radiologically detectable lesions, about which there could be no doubt, in the femoral head of the side operated upon. Six developed radiological signs that may or may not have indicated lesions; and four developed no abnormalities, despite the gross operative procedure.

The first radiological signs in the sheep appeared after approximately 2 months, but it took about 3 months before it was possible to identify positively the changes as being osteonecrotic lesions. The progress of the lesions was then followed for 3 to 4 months and, in some cases, for as long as 19 months. Unexpectedly, rather than the lesions becoming more and more pronounced radiologically, they regressed. In fact, some of the lesions observed for the longest period of time ultimately could not be detected radiologically at all. Insofar as the radiological changes are concerned, the lesions apparently repaired themselves completely.

In man, osteonecrotic lesions progress at different rates — sometimes very slowly. Figure 3 of the chapter entitled "Management and Treatment of Osteonecrosis" (Walder, this volume) shows just how slowly these changes may occur — in this instance, in the humeral head of a compressed-air worker over a period of five years. Even after so long a period, the surface of the humerus has not collapsed. It is possible that the man's condition may never deteriorate to the extent that he will require surgical treatment.

By contrast, other lesions develop very quickly. As an example, the humeral head shown in Fig. 3 was normal in February 1967. Four months

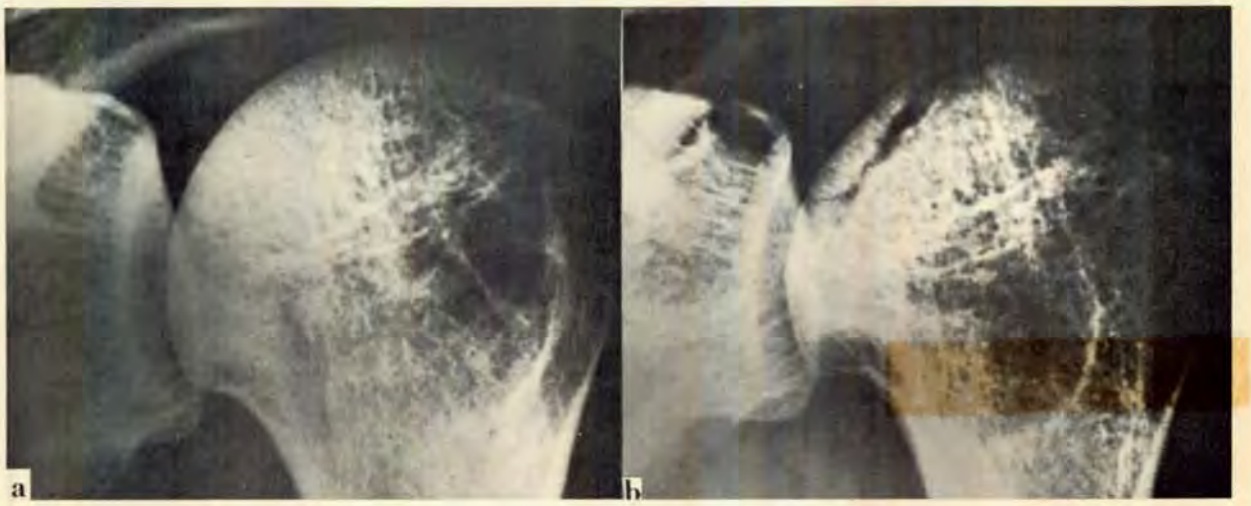

FIG. 3. (*a*) Lesion in humeral head, which (*b*) rapidly deteriorated over period of 4 months.

later a lesion had advanced to such an extent that pieces of bone were flaking off. Just one month later, further severe changes were evident.

Osteonecrosis in animals not only can progress very quickly, but also can resolve itself. One must be careful not to miss similar changes in man, however slow or subtle. The following interesting case illustrates this fact:

An experienced compressed-air worker unfortunately suffered a bronchospasm during a decompression; he developed decompression sickness and died. At the postmortem examination, one of his femoral heads was removed for histological examination. Transverse sections of this piece of bone are shown in Fig. 4. A slab radiograph revealed a typical lesion of osteonecrosis at the articular surface, demonstrated by a band across the head of the bone with what appears to be relatively normal bone tissue deeper in the head. On microscopic examination, however, a large area was found. It consisted of dead trabeculae on top of which new bone had been laid down. In other words, histological evidence is that a very much larger area of the bone was involved in the osteonecrotic process than is apparent from the X-ray, presumably because natural repair had occurred. The crosshatching shows the area of the head that, from the histological evidence, has been dead in the past.

In the case of this compressed-air worker, enormous repair had taken place, just as occurred with the sheep in our experimentation. In fact, it is tempting to postulate that bones can become damaged in decompression, then repair themselves without anything abnormal ever being detected by radiological examination. The results of our work with sheep tend to support this hypothesis.

It is more difficult to sever specific blood vessels to the lower end of the femur to produce lesions in it than in the femoral head. An attempt was therefore made to reproduce this type of lesion by using artificial emboli — namely, glass beads, 120 microns in diameter, which were introduced into the common iliac artery of rabbits. Figure 5 shows the lines of these beads, which have embolized the marrow, giving rise to histological changes similar in appearance to those seen in osteonecrotic lesions affecting the lower ends of the human femora.

The work being done at the University of Newcastle upon Tyne appears to complement that of Dr. Smith in Seattle. In the study of dysbarism-related osteonecrosis, both experimental approaches are necessary in the attempt to *1*) sub-

FIG. 4. Femoral head with subcortical lesion. (*a*) Slab radiograph shows apparent limits of osteonecrosis; (*b*) histological section shows same limits; and (*c*) histological section is crosshatched to show extent of area originally involved in osteonecrosis.

stantiate the hypothesis that the disease is caused by blockage of the blood vessels; and *2*) refute the contention that agents *not* connected with vascular supply to bone are important in the production of this condition.

FIG. 5. Microfocal radiograph of rabbit femoral shaft showing glass beads of 120-micron diameter in descending branch of nutrient artery.

EXPERIMENTALLY PRODUCED OSTEONECROSIS AS A RESULT OF FAT EMBOLISM

JOHN PAUL JONES, JR.
LEO SAKOVICH
CARL E. ANDERSON

Circumstantial evidence is accumulating to indict continuous or intermittent fat embolism of bone as a possible initiating event in the evolution and pathogenesis of avascular necrosis. On the basis of Virchow's belief that investigation of a disease condition should be concentrated on the dynamic process rather than on the end result, experimental studies were undertaken with the hypothesis that fat embolism of bone may be an initiating event in producing osteonecrosis (Jones, 1971).

This hypothesis has been partially confirmed by Jaffe and co-workers (1972), who administered corticosteroids systemically to rabbits over a period of 9 weeks. They found significant intraosseous fat embolism after 3 weeks, which was predominantly confined to subchondral capillaries of the humeral and femoral heads. These findings agree with those of Moran (1962), who identified intravascular fat emboli in the kidney, brain, and lung in his corticosteroid-treated rabbits, beginning at 3 weeks. However, no histological or roentgenographic evidence of aseptic necrosis was found by Jaffee *et al.* (1972), although the relatively short follow-up period may have been a limiting factor. Despite osteoporosis, there was no evidence of vasculitis or local changes consistent with a hemorrhagic diathesis.

Mankin *et al.* (1972) concluded that systemic corticosteroids do not impair chondrocyte viability, although they significantly interfere with matrix protein and polysaccharide synthesis of rabbit articular cartilage.

Additional support for this hypothesis has recently been reported by Fisher *et al.* (1972), who also produced hypercortisonism in rabbits. Hyperlipemia developed, which was associated with increasing fatty metamorphosis of the liver and secondary pulmonary and systemic fat embolism. Fat embolism of subchondral arterioles and capillaries of the femoral and humeral heads was demonstrated in 40 of the 60 treated animals. Furthermore, a significant increase in osteocytic death was found on histological examination of these heads. Despite marked osteoporosis, which developed during the six-month study, there was no evidence of intramedullary hemorrhage or thrombosis, vasculitis, inflammation, or fractures.

Fat embolism in rabbit femora has been demonstrated for five weeks after a single infusion of fat into the distal aorta (Jones and Sakovich, 1966). Further studies have been performed in an attempt to demonstrate avascular necrosis resulting from intraosseous fat embolism, since several investigators, using various compression–decompression techniques, had previously been unable to produce dysbaric osteonecrosis in experimental animals.

MATERIAL AND METHODS

In addition to the 26 rabbits that, as previously reported, showed evidence of intraosseous fat embolism (Jones and Sakovich, 1966), four other animals were infused to obtain long-term results. An average dose of 1.2 ml of Lipiodol (iodized oil, U.S.P.) was infused into the distal aortas of the animals over a period averaging 22.5 minutes. The 30 rabbits either died or were killed at various intervals, ranging from immediately after infusion to 26 weeks later (Table I).

Similar studies were made of four control rabbits. Two were anesthetized but not subjected to the operative or infusion procedures. Another underwent the operative procedure with ligation of the left common femoral artery, but without insertion of a catheter. The fourth had an infusion catheter inserted, but no Lipiodol was infused. Each control animal was killed within two hours of the procedure.

Autogenous rabbit or human fat was not infused in these preliminary experiments. Fat

Table I. LIPIODOL DOSAGE AND INTERVAL BETWEEN INFUSION AND DEATH CORRELATED WITH HISTOLOGICAL EVIDENCE OF FAT EMBOLISM AND AVASCULAR OSTEONECROSIS IN RABBIT FEMORA

Animal No.	Killed or died	Interval between infusion and death	Infusion amount (ml)	Infusion duration (min)	Histological evidence of fat embolism*	Histological evidence of avascular osteonecrosis
1	D	0 min	1.0	30	Marked	None
2	D	10 min	1.0	25	Marked	None
3	D	90 min	2.2	18	Marked	None
4	D	12 hr	1.0	30	Marked	None
5	D	17 hr	1.0	17	Marked	None
6	K	17 hr	2.2	21	Marked	None
7	D	18 hr	1.0	25	Marked	None
8	D	24 hr	1.0	25	Marked	None
9	D	35 hr	2.0	20	Marked	None
10	K	44 hr	2.2	20	Marked	None
11	D	56 hr	1.5	20	Marked	None
12	D	68 hr	1.0	25	Marked	None
13	D	83 hr	2.0	20	Marked	None
14	D	84 hr	1.0	20	Marked	Trace
15	D	84 hr	1.5	20	Marked	None
16	D	4½ days	1.0	20	Moderate	Trace
17	K	6 days	1.0	25	Moderate	Trace
18	D	7½ days	1.0	20	Moderate	Trace
19	K	10 days	1.0	23	Moderate	Trace
20	K	2 weeks	1.0	20	Moderate	Slight
21	K	3 weeks	1.0	25	Moderate	Trace
22	K	4 weeks	1.0	20	Moderate	Slight
23	K	5 weeks	1.0	25	Moderate	Marked
24	K	6 weeks	1.0	25	Slight	Marked
25	K	8 weeks	1.0	25	Trace	Marked
26	K	10 weeks	1.8	20	None	Slight
27	K	17 weeks	1.0	20	None	Slight
28	K	21 weeks	1.0	22	None	Trace
29	K	24 weeks	1.0	20	None	Trace
30	K	26 weeks	1.0	30	None	Trace
		Average:	1.2	22.5		

*Jones and Sakovich, 1966

obtained from human long bones and subcutaneous tissues is almost entirely neutral, a high proportion of its fatty-acid constituents being unsaturated (Peltier *et al.*, 1956). Lipiodol is different from rabbit and human cellular lipids (Forestier, 1927; Strain and Berliner, 1964), since it is a vegetable neutral fat (poppy-seed oil) in which the unsaturated fatty acids have been iodinated to the extent of 40% by weight. Although both mammalian fat and Lipiodol assume embolic-sized proportions when introduced into the bloodstream, there are differences in molecular heterogeneity and in such physical characteristics as relative viscosity, specific gravity, solubility, and surface tension, which would alter some of the experimental findings. This possibility will be explored in later studies in which autogenous mammalian fats will be used.

Postmortem pelvic roentgenograms were taken of the undissected rabbits with the hind limbs

fixed in normal hip posture, *i.e.*, flexion, abduction, and external rotation (Wilkinson, 1962). Densitometric studies were performed with the Macbeth-Ansco Densitometer. Even though the vascularity of the L proximal femur had been partially compromised by the operative procedure, comparative measurements were taken from the A-P view of the pelvis, and the relative density of the R and L femoral heads was evaluated. In general, the lower the densitometric value (by transmitted light), the greater the osseous roentgenographic density. If a roentgenogram was technically acceptable, with respect to the variables of exposure and equivalent positioning of the femora and pelvis in relation to the beam, then a relative densitometric difference of 0.05 units or more between the R and L femoral heads was considered significant (Table II).

The normal vascular system supplying the proximal femur of the adult rabbit is shown in Fig. 1. The opportunity to obtain collateral circulation in the rabbit femoral head is limited, since the entire head is intracapsular. The only sources of blood supply are through the medial epiphyseal artery of the ligamentum teres, through the epiphyseal vessels from the periosteal attachment of the capsule to the margin of the head, and through the metaphyseal vessels. The R femur was the only bone studied for evidence of avascular necrosis. It was disarticulated and removed for examination; frozen histological sections, as well as fixed hematoxylin and eosin-stained sections, were prepared.

Radioautographs were also made of sections of the proximal R femur from all rabbits killed 5 weeks or longer after the Lipiodol infusion, except the animal killed at 10 weeks. Radioactive phosphorus (sodium phosphate ^{32}P) at a dose of 10 microcuries per kilogram of body weight was injected intravenously 1 hour prior to necropsy. Radioactive phosphorus is a preferential bone-seeking isotope. If the intraosseous circulation is adequate, maximum uptake in the femoral head probably occurs within 1 hour after administering ^{32}P intravenously (Boyd, 1964; Boyd and Calandruccio, 1963). The method of Salomon and Ray (1964) was modified because the relatively short half-life of ^{32}P (14.3 days) necessitated briefer exposures (7 to 14 days). The formalin-fixed bone blocks were embedded with methylmethacrylate and immersed in either Eastman-Kodak NTB3 or Ilford L-4 liquid emulsion (Kopriwa and LeBlond, 1962). After immersion, the sections were coated with emulsion and stained with the methylene blue-azure method of Bélanger (1961).

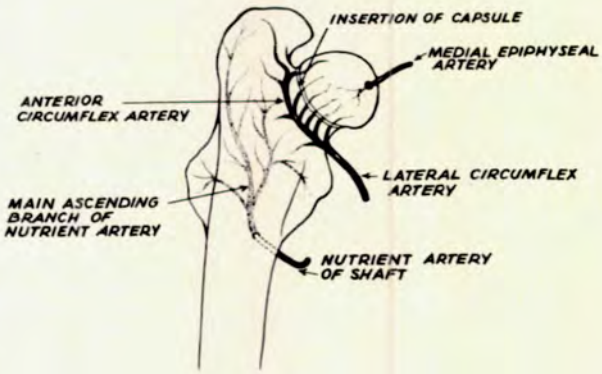

FIG. 1. Blood supply to femoral head in adult rabbit, which in many ways resembles arterial supply to human femoral head (Kistler, 1934; Lemoine, 1957; Rokkanen, 1962; Trueta and Harrison, 1953).

Table II. COMPARISON OF ROENTGENOGRAPHIC DENSITY OF FEMORAL HEADS OF CONTROL AND EXPERIMENTAL ANIMALS (DENSITOMETRIC UNITS)

	Weeks after infusion	Density of femoral head Left	Right	Difference in density*
Control Rabbits	No infusion	1.12	1.12	0.00
Experimental Rabbits	Less than 5	1.38	1.37	0.01
	5	1.43	1.40	0.03
	6	1.32	1.21	0.11
	10	1.55	1.41	0.14

*A difference in roentgenographic density of 0.05 units or more is considered significant.

RESULTS

Mortality

Fifteen of the 30 rabbits died during the course of these experiments, 14 within the first 4½ days after the infusion (Table I). Their deaths could be attributed in some degree to pulmonary and systemic fat embolism. Rabbits surviving the first 4½ days usually lived, after which time few fat emboli were found in the brain and kidneys even though marked pulmonary embolism was still present (Fig. 2). Evidence that a fat globule

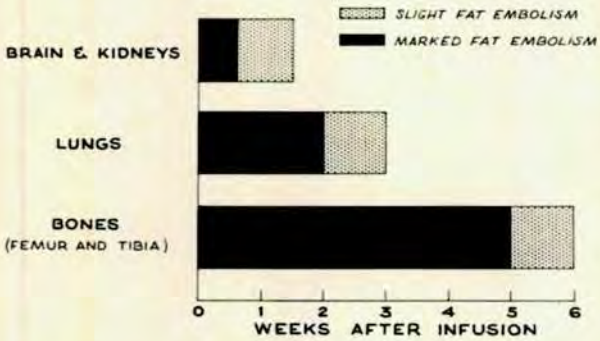

FIG. 2. Persistence of embolic fat in various rabbit organs after Lipiodol infusion.

was both intravascular and embolic was supported by its deformation into an oval or cylindrical configuration (Fig. 3), which indicated intravascular penetration and terminal impaction. The average Lipiodol dose administered to the animals that died (1.28 ml) did not differ significantly from the average dose infused into the 15 rabbits that lived (1.21 ml) (Table I).

Roentgenographic Findings

Minute intraosseous accumulations of radiopaque Lipiodol had previously been demonstrated in the undecalcified bone *in vivo* from 0 to 35 hours after infusion. Pelvic roentgenograms were not evaluated for evidence of osteosclerosis or early avascular necrosis during the first week after infusion because of potential difficulties in interpretation. There was no evidence of mottled or cystic radiolucencies, epiphyseal fragmentation, collapse, depression (flattening), subchondral fracture, angulation deformity, or secondary degenerative change in any of the control or experimental animals.

Naked-eye examination and magnification of the roentgenograms (up to × 40) with a Zeiss

FIG. 3. Deformed Lipiodol embolus 17 hr after infusion, impacted in capillary within epiphyseal region of femoral head, thereby blocking intraluminal blood flow (Animal 5, modified Felton stain, X 2000).

stereoscopic dissecting microscope revealed a questionable increase in roentgenographic density (osteosclerosis) in the R femoral heads of those animals killed at 6 and 10 weeks after the Lipiodol infusion (Fig. 4).

FIG. 4. Hips of Animal 26, killed 10 weeks after 20-min infusion of 1.8 ml of Lipiodol. (*a*) Slight osteosclerosis is present throughout R femoral head, compared with (*b*) less dense bone of L femoral head.

Densitometric determinations revealed a very slight increase in the relative radiodensity of the subchondral bone of the R femoral head, as compared with the L, at both 6 and 10 weeks after infusion. The greatest difference in relative density of the femoral heads was at 10 weeks after

infusion (0.14 unit) and at 6 weeks, although slightly less (0.11 unit) (Table II). There was no significant density change before 5 weeks or in the control rabbits.

Gross Appearance

No gross external alterations attributable to avascular necrosis were found in the R femur in any of the control or experimental rabbits.

Histological Findings

Control Animals. No ischemic or necrotic changes were seen either in the marrow cellular elements or in osteoblastic or osteocytic (osteogenetic) components of the femora from the four control rabbits. Scattered empty osteocyte lacunae were occasionally seen, primarily in interstitial lamellae.

Rabbit bone differs somewhat from human bone in that boundaries of individual osteons are not as prominent. Small Haversian canals can be seen, but concentric cylinders of lamellar bone and cementing lines are not as distinct as in human compact bone. The Haversian canals may encase one or two capillaries, the walls of which are composed of a single endothelial layer. In some of the smaller canals the capillary may occupy over 50% of the cross-sectional area. In the control animals, rarely was more than one layer of thin osteoblasts found lining the Haversian canals or covering trabecular and endosteal surfaces.

Small numbers of microscopic fissures, or microcracks (5 to 10 per section), were found between lamellae in otherwise intact trabeculae. These microcracks were present within the interior of the trabeculae; they did not appear to extend to bony surfaces adjoining the marrow spaces.

Lipiodol-infused Animals. *Immediately* after infusion, dilation and engorgement of several marrow sinusoids and capillaries were noted, indicating passive congestion. No hemorrhage in the marrow was apparent. Multiple fat globules were found in marrow capillaries and sinusoids shortly after the infusion (Fig. 5).

From 12 to 44 hours after infusion there was evidence of intraluminal erythrocyte disintegration and focal intracellular disorganization, plus disintegration involving the hematopoietic marrow. Islands of marrow cells showed loss of basophilic and nuclear staining. Fat cells and osteogenetic cells appeared normal.

From 56 to 83 hours after infusion, many hematopoietic cells had indistinct cytoplasmic borders (or they were missing altogether), homogenous coagulated cytoplasm, and condensed (pyknotic) or swollen (karyolytic) nuclei. Or they appeared as cloudlike masses of eosinophilic cell ghosts (Fig. 6). Minute areas of hematopoietic granular debris and acellular fibrinous necrosis were also noted (Fig. 7).

FIG. 5. Multiple Lipiodol fat globules within metaphyseal marrow, capillaries, and sinusoids of femoral head, 90 min after infusion (Animal 3, modified Felton stain, X 100).



FIG. 6. Large cloudlike mass of eosinophilic cell ghosts of metaphyseal bone marrow, 68 hr after Lipiodol infusion, indicating focal infarction (Animal 12, hematoxylin and eosin stain, X 65).

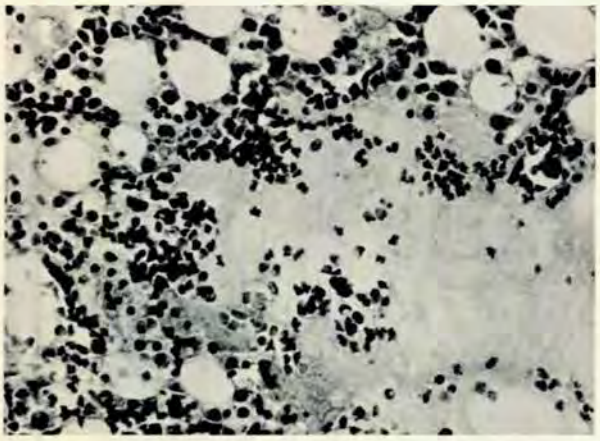

FIG. 7. Area of hematopoietic granular debris, 83 hr after Lipiodol infusion, with cellular ghosts and fibrinous necrosis (Animal 13, hematoxylin and eosin stain, X 380).

At 4½ days there was a slight decrease in marrow fat cellularity without focal necrosis. Scattered passive congestion, fibrin thrombi, and dissolution of vascular walls were evident. Osteocytes appeared normal, but few osteoblasts were found.

At 6 days even less marrow-fat cellularity was apparent and there were scattered areas of fatty liquefaction necrosis, with fat-cell dissolution and, in the metaphyseal marrow, cystic spaces or oil sacs of various sizes.

At 10 days necrosis of fat cells caused metaphyseal marrow fat to diminish.

By 2 weeks there was an increased number of microscopic cracks (20 to 30 per section) in the proximal metaphyseal marrow. The earliest microcracks were arranged linearly along the cementing lines in the interval between adjacent, concentric lamellae and, particularly, at the junction of two or more trabeculae. There was scattered focal loss of hematopoietic and adipose tissue pattern with fibrinous necrosis.

At 3 weeks diffuse intracellular disorganization and loss of cellular detail continued, especially with respect to marrow elements. No noteworthy osteocytic necrosis was found at this time.

At 4 weeks less osteoblastic proliferation was found. Along the periphery of the proximal femoral metaphysis there was minimal invasion by vascular granulation tissue, especially underlying some endosteal cortical surfaces. The osteocytic nuclei of several metaphyseal trabeculae were pyknotic or missing, especially in the surface lamellae.

At 5 to 8 weeks after infusion, there was histologic evidence of bone necrosis. Irregular foci of coagulation necrosis of marrow elements, representing focal infarctions, involved the epiphyseal region of the femoral heads. There was loss of tissue pattern in the intertrabecular spaces and autolysis with dissolution of cellular constituents in focal areas.

The borders of the infarcted areas had indistinct lines of demarcation. Bone and intertrabecular marrow spaces immediately beneath the articular cartilage of the femoral head were not extensively involved at 5 weeks, although separate scattered foci were apparent in the epiphysis (Fig. 8).

FIG. 8. Small anemic infarction lying within subchondral marrow of femoral head, 5 weeks after Lipiodol infusion. Trabecular microcracks and superficial cleavage planes are apparent, with sequestration of small fragments of bone into marrow space (Animal 23, hematoxylin and eosin stain, X 200).

At 6 and 8 weeks the punctate foci of necrotic debris had extended into the subchondral bone. During this period there were occasional oil cysts. The necrotic marrow spaces contained amorphous masses of granular debris, including necrotic bone fragments (Fig. 9). Although occasional macrophages were found, osteoclastic removal of bone was not extensive. There was no appositional new-bone formation and a minimum of peripheral fibroblastic proliferation. At least one-third of the lacunae in the subchondral bone of the femoral heads were devoid of osteocytic nuclei. Loss of nuclei was particularly evident within the interstitial and superficial trabecular lamellae.

FIG. 9. Focal marrow infarctions and liquefaction necrosis, 6 weeks after Lipiodol infusion, with formation of small oil cysts in epiphyseal regions of femoral head (Animal 24, hematoxylin and eosin stain, X 100).

There was evidence of trabecular microdamage in the infarcted zones. Multiple microcracks (75 or more per section) were found at 5, 6, and 8 weeks. During this period it appeared that the microcracks had extended to trabecular surfaces, resulting in cleavage planes (Fig. 10) which separated the more superficial concentric lamellae.

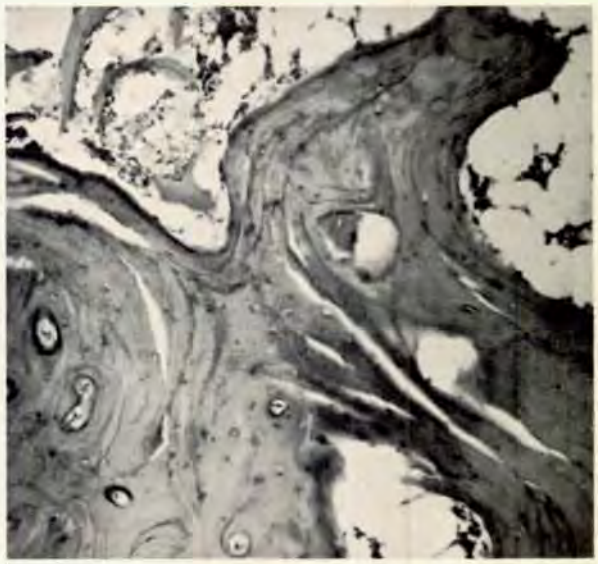

FIG. 10. Epiphyseal region of femoral head, 8 weeks after Lipiodol infusion, showing multiple microcracks separating along cleavage planes to trabecular surfaces (Animal 25, hematoxylin and eosin stain, X 200).

These superficial cleavage planes and the fragmentation of superficial lamellae (trabecular microfractures) were not found in the control animals.

Most of the fragmented bony spicules had lost their eosinophilic properties and were devoid of viable-appearing osteocytes. Thinning of bony trabeculae associated with superficial lamellar fragmentation was maximal at 8 weeks. Only ischemic changes were found in the distal metaphyseal and epiphyseal regions of the femur.

The articular cartilage appeared normal in staining characteristics, surface smoothness, layer thickness, and the number, size, distribution, and nucleation of the chondrocytes.

Beginning at 10 weeks after infusion there was evidence of regeneration of the ischemic and necrotic bone and marrow. Localized areas of osteoblastic activity were found with appositional new-bone formation.

Although an increased number of microcracks was noted at 10 and 17 weeks, there were few new fragmented and necrotic bone spicules. The size and number of fatty parenchymal elements in the proximal femoral metaphyseal regions continued to decrease. Although the hematopoietic cellular elements of the marrow had been recon-

stituted, there was still evidence of focal osteocytic death. Only about one-third of the subchondral lacunae were filled with viable-appearing osteocytes. There was no significant intertrabecular fibroblastic proliferation or connective-tissue scars. There were very few ghostlike cells or fatty cysts and little granular debris. Although liquefaction necrosis of fat cells had been previously observed, no calcified lipid was detected.

By 17 weeks few ischemic or necrotic changes were evident. The abnormal cells and the small amount of interstitial fibrous tissue had disappeared; the sinusoidal bed was restored and normal hematopoiesis apparently had been resumed. A marked proliferation of small adipose cells with enlarged nuclei was noted at this time.

At 21 to 26 weeks extensive reossification had occurred. The plump osteoblasts were two and three layers deep, covering the trabecular surfaces (Fig. 11) and walls of the Haversian canals.

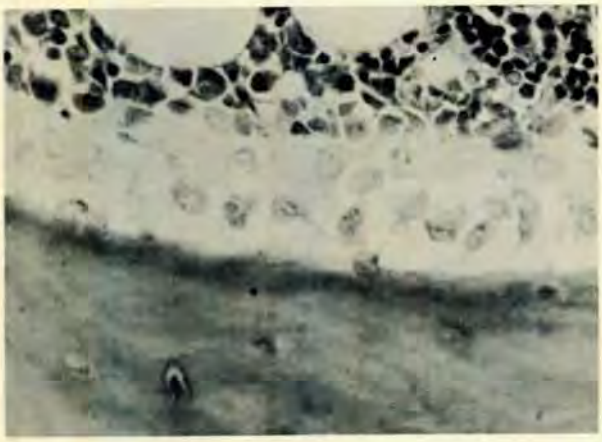

FIG. 11. Osteoblastic proliferation and appositional bone formation with normal marrow elements, 24 weeks after Lipiodol infusion (Animal 29, hematoxylin and eosin stain, X 900).

About a third of the lacunae were still vacant in the proximal subarticular cancellous bone at 21 weeks. Provisional new-bone formation was irregular and extensive; the deposits, of various sizes, were unevenly spaced.

Except for the persisting decreased numbers of osteocytes in the subchondral bone of the femoral head after 21 weeks, no evidence of focal infarcts remained (Fig. 12). Hematopoietic and fatty cellular elements appeared normal, although trabecular and cortical bone continued to show

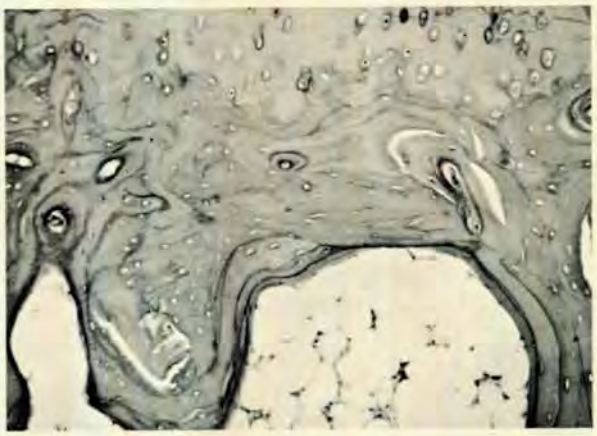

FIG. 12. Subchondral bone of femoral head of rabbit, 24 weeks after Lipiodol infusion. Marrow appears normal; there are increment lines with superficial lamellae containing viable-appearing osteocytes. Intratrabecular microcracks and lack of osteocytes will be noted in subchondral lacunae (Animal 29, hematoxylin and eosin stain, X 140).

histologic evidence of osteocytic necrosis. Regeneration of the hematopoietic and fatty marrow had occurred without organization of the infarcts or substitution by dense fibrous scar tissue (myelofibrosis).

Radioautographic Findings

The Eastman-Kodak NTB3 liquid emulsion yielded better results in qualitative radioactive autography than did the Ilford L-4 emulsion, presumably because of its greater sensitivity in delineating the emission of beta radiation from ^{32}P (Kopriwa and LeBlond, 1962).

Control Animals. Radioautograms of the control femora showed diffuse trabecular- and cortical-bone labeling with ^{32}P. Isotope accumulation was especially evident in areas immediately adjacent to capillaries.

Lipiodol-infused Animals. *At 5 to 8 weeks* there was spotty labeling of cortical bone and minimal labeling of trabecular bone in these animals, especially in the superficial lamellae within the necrotic foci. There was no labeling of the intertrabecular devitalized femoral-head fragments. Slight perivascular labeling was apparent in the bone adjacent to the necrotic focal infarctions.

From 17 to 26 weeks isotopic labeling was similar to that found in the control femora. Su-

perficial trabecular lamellae were labeled, but scattered areas lying deep within the interior of trabeculae remained unlabeled.

DISCUSSION

Avascular necrosis was not found in the femoral diaphyseal, distal metaphyseal, or epiphyseal regions of these rabbits. Although Lemoine (1957) produced osteochondritic changes in the upper femoral epiphysis of the rabbit after dividing the main capsular artery, similar changes could not be elicited in the distal femoral epiphysis, presumably because of the extent of collateral vasculature between the main artery and epiphyseal vessels.

Because of the great vascularity of bone, experimental division of an extraosseous vessel does not, except in isolated instances, simulate occlusion by emboli of that vessel's endings (Kistler, 1935). Because of the adequacy of extraosseous and intraosseous collateral vessels, ligation of the nutrient artery to the long bones of experimental animals only temporarily decreases intramedullary pressure and blood flow. End-arteries with few anastomoses favor embolic occlusion (Fernando and Movat, 1964). End-arteries are thought to be present beneath open epiphyseal plates and articular cartilages, which probably accounts for the frequent occurrence of metaphyseal and subchondral metastatic infarctions and necrosis. In these experiments, the emboli had especially obstructed subchondral arterioles and capillaries.

In addition to findings directly related to Lipiodol embolism and vascular tamponade, the femoral heads of the experimental animals revealed progressive evidence of focal tissue death and fragmentation. Passive congestion was evident throughout the first week after infusion. The earliest evidence of tissue death occurred within 48 hours and consisted of intraluminal erythrocyte shrinkage and degeneration and focal areas of hematopoietic marrow-cell disruption. Thereafter, until the tenth week after infusion, progressive focal necrosis and disorganization were evident, involving all marrow and bone elements.

At varying time intervals, the following sequence of tissue responses was observed:

1. Coagulation necrosis of hematopoietic marrow elements with focal disorganization.
2. Disappearance of adipose membranes, liquefaction necrosis of fatty-marrow elements with quantitative fat-cell loss, and appearance of cysts filled with liquid fat.
3. Disappearance of all osteoblasts from the trabeculae in large segmental or focal areas.
4. Degeneration of osteocyte nuclei with cellular shrinkage and, in some areas, complete disappearance of osteocytes.
5. Increasing numbers of fissures or microcracks in the bony metaphyseal trabeculae, with separation along the cementing lines and sequestration into the marrow spaces of many small fragments of dead bone.

Artifactitious tissue distortion, possibly resulting from technical processing, could also account for trabecular fragmentation. However, comparison of experimental and control animals revealed significant microdamage in the former at 5, 6, and 8 weeks. Several of the fragmented bony spicules had lost their eosinophilic properties and were devoid of viable-appearing osteocytes. Certainly additional studies, made with a variety of bone-processing techniques and tests for bone viability, are essential to verify the existence and significance of microdamage.

Bone and marrow infarction was localized in metaphyseal and epiphyseal regions of the femoral head. The majority of fat emboli had been found in arterioles and capillaries of these same regions from 2 to 6 weeks after the Lipiodol infusion.

After Lipiodol-fat embolism of intraosseous vessels, the following sequence of events is thought to result in bone necrosis. Tissues formerly supplied with blood for their nutrition become progressively hypoxic as the oxygen content of the stagnant blood is exhausted. It has been demonstrated experimentally that within 3 to 5 minutes after a sudden, complete interruption of blood supply to the femoral head, the viable cells have consumed all available oxygen (Woodhouse, 1964). Marrow capillaries and sinusoids become atonic and dilate. As they dilate they fill with blood and appear congested.

Lacking adequate collateral circulation, arterial and capillary occlusion produces focal anemic infarctions. As the process continues, infarcted tissues in the femoral-head region die because of anoxia and chemical injury from accumulated catabolic products, and they undergo coagulation and liquefaction necrosis.

Loss of structural integrity within a cell is irreversible and indicates unequivocal death (Johnson, 1964). However, osseous tissues do not all die simultaneously. Death is dependent upon the inherent susceptibility of the particular tissue to acute anoxia. The most sensitive parenchymal elements, the hematopoietic cells, therefore succumb first.

In our animals, slight focal evidence of marrow necrosis first appeared at 56 hours after

infusion. Marrow fat cells next showed focal changes, with liquefaction necrosis and formation of oil cysts, as well as cellular diminution 6 days after infusion; these changes were especially pronounced at 5 through 10 weeks. No osteoblasts were found lining trabecular surfaces in segmental infarcted areas at 4 through 8 weeks. Slight degeneration of the osteocyte nuclei, with cellular shrinkage and ultimate disappearance from lacunae, was first noted at 2 and 4 weeks. Osteocytes may be more resistant to hypoxia than are other osseous cellular elements. It is speculated that those osteocytes within concentric lamellae farthest from Haversian vessels are particularly susceptible to ischemia. Osteocytes within interstitial extra-Haversian bone, or in superficial lamellae of individual osteons, probably manifest the greatest degree of necrosis (Fig. 13).

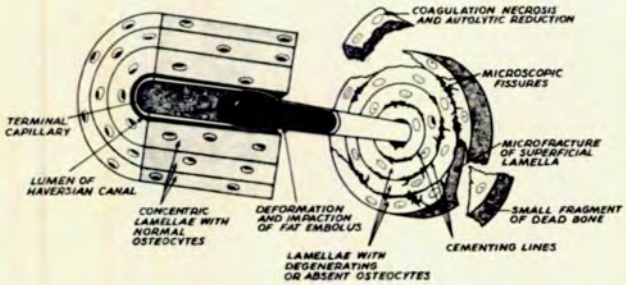

FIG. 13. Hypothetical mechanism whereby intraosseous fat embolism may result in osteonecrosis. (Jones, 1971. Illustration courtesy of publisher.)

However, the fact that osteocyte nuclei are stainable is not evidence of viability (Ray, 1964). Nor is the presence of scattered empty lacunae — as were occasionally noted in the interstitial lamellae of the control rabbits — evidence of bone death. It is therefore very difficult, if not impossible, to assess osteocyte viability on the basis of cellular morphology or staining characteristics. Kenzora (1972) performed radioautographs of cancellous and cortical bone from the femora and humeri of adult rabbits incubated with H^3-proline and H^3-cytidine. Only 65% of all osteocyte lacunae incorporated isotope immediately following total loss of all exogenous nutrition (19% of osteocytes did not incorporate isotope and 16% of lacunae were empty). Four days after loss of nutrition, no cells were labeled (60% of lacunae were empty and 40% were filled with cells). Biochemical determinations of DNA showed loss of osteocyte viability beginning about 4 hours after infarction.

Ascenzi and Bonucci (1971) determined fiber-bundle direction in successive lamellae and were the first to develop a micromechanical technique for determining shearing strength of fiber bundles in individual osteons. Swedlow and Katz (1972) also studied the ultrastructural properties of bone, using a combination of investigatory techniques. They found that strength and stiffness of bone are significantly related to collagen-fiber orientation. Regions with longitudinal or steeply spiraling collagen fibers are stronger and have higher elastic moduli than regions with more transverse fiber orientation. At the interlamellar interface, fiber alignment may change abruptly from circumferential to radial, and there may be a 90° change of fiber orientation between adjacent lamellae. It is likely that interlamellar microcracks are more likely to result from shearing stresses applied to adjacent lamellae having a marked change in fiber orientation.

Although microcracks were first observed in experimental animals by Rutishauser and Majno (1950), they have also been found routinely in bone from normal human adults (Frost, 1960). They are thought to develop when bones are cyclically loaded by muscle and body-weight forces during daily physical activity. These forces may cause interlamellar compression and shearing stresses that disrupt interlamellar bonds, resulting in microfatigue and trabecular microdamage.

Frost (1964) emphasized the importance of early detection and repair of microcracks in otherwise intact trabeculae. He considered osteocytes the logical key in microdamage detection, since microscopic cracks usually occur normally in extra-Haversian bone or inside trabeculae. Living osteocytes are thought to signal the activation of mesenchymal (osteoprogenitor) cells, which cause osteoclasts and osteoblasts to respond and repair the microdamage. Isolated instances of healing trabecular fractures have been found in human femoral heads by Todd and co-workers (1972).

In our experimentation, irregular accretions of woven bone were found surrounding the undisplaced trabecular fractures, evidence of repair with active new bone formation. There was complete reconstitution of the marrow; resolution occurred with little evidence of fibrous tissue substitution. With progressive revascularization of posttraumatic necrotic lesions, the fibroblastic network of granulation tissue (including capil-

laries and cells) ordinarily fills marrow spaces rapidly, tending to polarize toward bone surfaces. These cells then differentiate to become osteoblasts and produce new bone.

In subchondral bone, which is aptly called *cortex*, revascularization occurs through formation of extensive cutting cones in a process similar to that involved in primary bone healing. A dead bone trabecula is coated with a layer of woven bone, which may then be covered by a layer of living lamellar bone. However, classic revascularization of necrotic foci did not occur in the present study. Fibroblastic elements had vanished and the marrow appeared essentially normal at 17 weeks. The only indication of previous infarction was foci of osteocytic death.

It is interesting to correlate, chronologically, the histological evidence of fat embolism and focal osteonecrosis in the femoral heads of rabbits (Table I). Six weeks after a single shower of intraosseous fat emboli, evidence of the initiating event had vanished when there was focal necrosis. When the necrotic or healing heads were excised six weeks or later after the embolic shower, there was little or no evidence of the initiating event (Jones, 1971).

In these experiments, focal avascular necrosis was shown to result from fat embolism of bone. A single episode of fat emboli, even with temporary systemic recycling of the fat globules, did not produce gross or roentgenographic evidence of necrosis. Histologic evidence of necrosis in the rabbit is rather short-lived before regeneration of marrow occurs, although restitution of osteocytes is slower. But if the femoral head were to be bombarded with another shower of fat emboli 8 to 10 weeks after an initial episode, it is conceivable that additional minute bone infarctions would prevent healing. They might, as well, coalesce and result in gross architectural abnormalities.

Dysbarism, Fat Embolism, and Osteonecrosis

Nitrogen bubbles have been considered the primary factor in the etiology of dysbarism and related osteonecrosis. However, Kahlstrom and co-workers (1939) were unable to produce bone infarctions in the hind legs of dogs by arterial air embolism. Gersh *et al.* (1944) and Colonna and Jones (1948) failed to produce avascular necrosis in compression–decompression experiments, despite the presence of enlarging gas bubbles in bone marrow and within intramedullary vessels.

Reeves and co-workers (1972) reported on a series of 732 compressions involving 19 dogs; decompression sickness developed approximately 50% of the time. Roentgenograms of shoulder and hip joints were undertaken annually for five years, at which time necropsy was performed. Examination revealed no gross or microscopic evidence of osteonecrotic cortical or cancellous bone.

Bond and associates (1965) studied the hemodynamic alterations produced by intra-arterial gas emboli. They found that N_2 emboli initially cause vascular constriction and, probably, temporary obstruction. These events are followed by decreased resistance, interpreted as vascular relaxation, which persists until the emboli are removed either by traversing the capillary bed or by dissolution in the blood. Probably no more than 10% to 15% of the vessels remain blocked after gaseous embolism (Duff *et al.*, 1954). Nitrogen bubbles liberated from marrow fat are confined within the rigid medullary cavity and may build up sufficient intramedullary pressure to compress intraosseous vessels. Hills and Straley (1972) found experimentally that soon after compression there is a definite increase in bone blood flow and a decrease in marrow pressure, which seem to reverse soon after decompression. But the duration and extent of the ischemia they observed were only temporary and not considered sufficient to initiate osteonecrosis.

Shim *et al.* (1967) likewise were unable to produce dysbaric osteonecrosis experimentally in rabbits, despite a regimen of compression–decompression three times a week for four months in a hyperbaric chamber. Cystic lesions observed in the bone marrow of only one animal were similar to those reported by Colonna and Jones (1948). The evidence was insufficient to implicate these lesions as manifestations of osteonecrosis. Postmortem examinations revealed many gas bubbles within the blood vessels and tissue spaces of animals that died during the experiment, but none were found in the surviving animals. However, fat emboli were found in the lungs of most of the animals that died as well as in the lungs of the survivors.

Relative to the 1967 study (Shim *et al.*), fat stains were made of the proximal femur, lung, brain, liver, kidney, and heart of the animals involved (Jones and Shim, 1972). No evidence of intraosseous fat embolism of the femoral heads was found. Evidence of systemic fat embolism was insignificant, although pulmonary fat embolism was marked in the multiple compression–decompression group. There was also evidence

FIG. 14. Bone marrow of rabbit which died 1 hr after multiple compression-decompressions, revealing degenerating fat cells adjacent to capillary sinusoids (Oil Red O stain, X 250; tissue courtesy of Shim *et al.*, 1967).

of degeneration of marrow fat cells adjacent to sinusoids (Fig. 14). Occasional gas bubbles and probable intravascular fat globules were noted within the bone marrow of a rabbit that died within one hour following multiple compression–decompressions (Fig. 15).

Gersh *et al.* (1944) and Gersh (1945) demonstrated N_2 bubbles in adipose tissues following decompression sickness. Fat cells were subsequently disrupted by bubbles and depot fat was then mobilized in the blood. Cockett *et al.* (1972) documented fat embolism in the lungs, liver, and kidneys of dogs following overcompression to 165 ft for 1 hour and rapid decompression at the rate of 7 psig/min. There were also significant elevations of cholesterol, phospholipids, triglycerides, and total lipids 3 hours after "surfacing." LeQuire *et al.* (1959) decompressed rabbits and demonstrated increased cholesterol in the fat emboli that developed. Such levels of cholesterol, they believed, could not be derived from depot fat alone, and they suggested that the emboli were formed from unstable serum lipid.

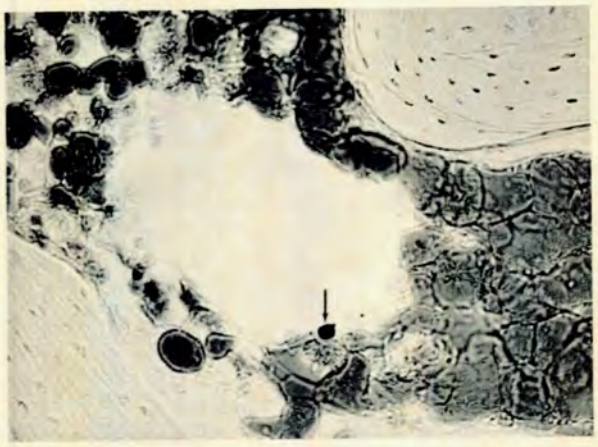

FIG. 15. Bone marrow of rabbit that died 1 hr after multiple compression-decompressions. Large gas bubble is seen adjacent to capillary-sinusoid, with a probable intravascular fat globule (arrow) (Oil Red O stain, X 200; tissue courtesy of Shim *et al.*, 1967).

Pauley and Cockett (1970) analyzed features common to fat embolism and dysbarism, including the virtually identical symptoms of the two syndromes and the latency period preceding their onset. Transcutaneous ultrasound (Doppler) measurements will demonstrate intravascular gas bubbles *in vivo* in the dysbarism syndrome (Evans *et al.*, 1972). Yet Kelly and coworkers (1972) (also using noninvasive ultrasound probes) have detected, in both dogs and humans, intravascular fat globules *in vivo* in the femoral venous effluent from a fracture. Blood tests revealed hyperlipemia and lung biopsies revealed fat embolism, which correlated well with ultrasonic recordings for fat globules.

Nitrogen bubbles probably trigger an elaborate chain of secondary events. Although the decompression-sickness syndrome initiated by N_2 is essentially reversible with recompression, certain secondary hemodynamic side effects are not thus reversible — including the fat-embolism syndrome. The coexistence of fat embolism and human dysbarism had been previously reported by several investigators (Haymaker and Davison, 1950; Haymaker and Johnston, 1955; Sillery, 1958; Rait, 1959; Odland, 1959; Robie *et al.*, 1960).

The strongest evidence supporting the concept that fat emboli are at least partially derived from disrupted adipose or other fatty-tissue depots (fatty liver or bone marrow) is the presence of marrow fragments within pulmonary vasculature following decompression. Pauley and Cockett (1970) studied the role of lipids in dysbarism. They concluded that changes in lipid stability probably occur because of injury to the fatty liver resulting from expanding N_2 bubbles. They suggested that unstable lipids, extruded from the liver, may form emboli and occlude the

pulmonary and systemic vasculature. Rheological changes — *i.e.*, sludging and aggregation of red-blood cells and platelets — are caused by unstable lipids and bubbles, resulting in impaired tissue perfusion, vascular damage, and fibrin thrombus propagation.

Philp and co-workers (1971) suggested that plasma lipids tend to disappear after rapid decompression. Philp *et al.* (1972) reviewed the interaction between blood and foreign surfaces, including gas bubbles. They suggested that intravascular proteins, platelet adhesion and aggregation, and coalescence and adhesion of plasma lipids to the blood–gas interface could contribute to fat embolism in dysbarism.

It is speculated that intraosseous fat embolism of terminal vessels then occurs, followed by focal intravascular coagulation and propagation of fibrin thrombi proximal to the occluding globule(s). The mechanism underlying the process may involve the release of some thromboplastin-like tissue material in response to cellular injury, with consequent activation of the coagulation process and incorporation of platelets in fibrin.

This response is thought to involve the interaction of vascular subendothelium and platelets to form the provisional hemostatic plug, followed by fibrin stabilization of the plug through coagulation (Harker and Slichter, 1972). In both the fat-embolism and dysbarism syndromes, destruction of both platelets and fibrinogen increases, resulting in thrombocytopenia and other hematological correlates. Fat embolism is known to precipitate disseminated intravascular coagulation (Lasch, 1969). The latter often goes unrecognized, because platelets and fibrinogen may be maintained at near-normal levels by compensatory increases in their production.

Pauley and Cockett (1970) noted that without recompression therapy, decompressed dogs survive when treated with Rheomacrodex (low-molecular-weight [40,000] dextran) or intravenous heparin (2 mg/kg). Hypothermia, which is effective in treating fat embolism, also appeared useful in treating dysbarism (Cockett *et al.*, 1965). The beneficial effects of dextran may be attributed to its capacity to clear plasma of coalescing lipid molecules, whereas the lipolytic action of heparin is attributed to activation of lipoprotein lipase. Gowdey and Philp (1965) also evaluated pharmacological adjuncts to recompression therapy. They suggested that heparin's capacity to reduce the incidence and severity of dysbarism is more likely associated with its lipemia-clearing activity than with its anticoagulant properties.

Pathophysiology

After these observations were synthesized, a hypothetical scheme was devised regarding the pathophysiology of dysbaric osteonecrosis. Nitrogen bubbles coalesce unstable lipids at the blood–gas interface and/or cause the disruption and liberation of depot fat. These events result in intermittent systemic (intraosseous) fat embolism (Jones and Sakovich, 1966), which has been shown experimentally (Jaffe *et al.*, 1972; and Fisher *et al.*, 1972) to involve both the humeral and femoral heads, followed by intravascular coagulation, fibrin thrombus propagation, focal marrow necrosis, osteon anoxia, and osteocytic death.

Dead osteocytes cannot detect microdamage; therefore, no signal for repair is transmitted to osteoclasts and osteoblasts (Frost, 1964), which may have also been adversely affected by ischemia and necrosis. There is either insufficient repair, or no repair, of the microdamage. Microdamage is repeated, and the pathophysiology worsens, causing trabecular thinning, gross trabecular fragmentation, and fractures, with coagulation necrosis, autolytic reduction, and, inevitably, segmental subchondral collapse of functional significance.

SUMMARY

Focal and minute regions of avascular necrosis in bone and marrow have been produced in the metaphyseal and epiphyseal zones of the right femoral heads of rabbits by a single infusion of 1.2 ml of Lipiodol into the distal aorta. Fat emboli persisted up to 5 weeks after infusion and were particularly evident within subchondral vessels of the femoral head.

The presence of osteonecrosis was determined by roentgenographic, histologic, and radioautographic methods. Slightly increased bone density of questionable significance was observed at 6 and 10 weeks after infusion. The uptake of radioactive phosphorus was markedly reduced in the infarcted zones.

Histologically, necrosis involved all marrow and osseous elements in the infarcted regions. The earliest ischemic changes were detected at 4 days; by 10 weeks active repair was apparent. Hematopoietic marrow elements showed coagulation necrosis. Marrow fat cells were reduced in number and displayed liquefaction necrosis with the formation of oil cysts. Epiphyseal and

metaphyseal trabeculae lost osteoblastic lining cells. This loss was associated with death of osteocytes, formation of microfractures, and sequestration into the marrow space of many small fragments of dead bone. Although bone-marrow components had been completely regenerated by 17 weeks, foci of osteocytic death persisted.

The significance of these preliminary experimental findings remains unknown, since it is still not certain if tissue or intravascular gas bubbles are the primary cause of dysbaric osteonecrosis. It is known, however, that bubbles may have some secondary effect, such as the production of pulmonary and systemic (intraosseous) fat embolism, associated with fibrin thrombus propagation, and red-cell and platelet aggregation. It is speculated that the etiological agent in dysbaric osteonecrosis may not be reversible with recompression therapy alone, but may also require the use of various lipid-clearing agents.

ACKNOWLEDGMENTS

This investigation was supported by grants from the United States Public Health Service (AM-08897) and from the Medical Education and Research Fund from the University of California School of Medicine, San Francisco.

REFERENCES

Ascenzi, A., and Bonucci, E. (1971). A micromechanic investigation on single osteons using a shearing strength test. Israel J. Med. Sci. 7, 471-472.

Bélanger, L. F. (1961). Staining processed radioautographs. Stain Tech. 36, 313-317.

Bond, R. F., Durant, T., and Oppenheimer, M. J. (1965). Hemodynamic alterations produced by intra-arterial gas emboli. Amer. J. Physiol. 208, 984-992.

Boyd, H. B. (1964). The use of radioactive phosphorus (P^{32}) to determine the viability of the femoral head. Part I. In Proceedings of the Conference on Aseptic Necrosis of the Femoral Head, St. Louis. pp. 193-196. Washington, D.C.: U.S. Public Health Service.

Boyd, H. B., and Calandruccio, R. A. (1963). Further observations on the use of radioactive phosphorus (P^{32}) to determine the viability of the head of the femur: Correlation of clinical and experimental data in 130 patients with fractures of the femoral neck. J. Bone Joint Surg. 45-A, 445-460.

Cockett, A. T. K., Nakamura, R. M., and Kado, R. T. (1965). Physiological factors in decompression sickness. Arch. Environ. Health 11, 760-764.

Cockett, A. T. K., Pauley, S. M., Pilmanis, A., and Roberts, A. P. (1972). Formation of lipid emboli after significant decompression. Abstract. Fifth Symposium on Underwater Physiology, Freeport, British Bahamas.

Colonna, P. C., and Jones, E. D. (1948). Aeroembolism of bone marrow: Experimental study. Arch. Surg. 56, 161-171.

Duff, F., Greenfield, A. D. M., and Whelan, R. F. (1954). Observations on the mechanism of the vasodilatation following arterial gas embolism. Clin. Sci. 13, 365-376.

Evans, A., Barnard, E. E. P., and Walder, D. N. (1972). Detection of gas bubbles in man at decompression. Aerospace Med. 43, 1095-1096.

Fernando, N. V., and Movat, H. Z. (1964). The fine structure of the terminal vascular bed. II. The smallest arterial vessels: Terminal arterioles and metarterioles. Exp. Molec. Path. 3, 1-9.

Fisher, D. E., Bickel, W. H., Holley, K. E., and Ellefson, R. D. (1972). Corticosteroid-induced aseptic necrosis. II. Experimental study. Clin. Orthopaed. 84, 200-206.

Forestier, J. (1927). Clinical results in diagnosis by iodised oil (lipiodol) injections. Edinburgh Med. J. 34, 147-158.

Frost, H. M. (1960). The presence of microscopic cracks in bone, in vivo. Henry Ford Hosp. Med. Bull. 8, 25-35.

Frost, H. M. (1964). The etiodynamics of aseptic necrosis of the femoral head. In Proceedings of the Conference on Aseptic Necrosis of the Femoral Head, St. Louis. pp. 393-413. Washington, D.C.: U.S. Public Health Service.

Gersh, I. (1945). Gas bubbles in bone and associated structures of guinea pigs decompressed rapidly from high-pressure atmosphere. J. Cell. Comp. Physiol. 26, 101-117.

Gersh, I., Hawkinson, G. E., and Rathbun, E. N. (1944). Tissue and vascular bubbles after decompression from high pressure atmospheres — correlation of specific gravity with morphological changes. J. Cell. Comp. Physiol. 24, 35-70.

Gowdey, C. W., and Philp, R. B. (1965). Etiology and treatment of experimental decompression sickness with special reference to body lipids. Milit. Med. 130, 648-652.

Harker, L. A., and Slichter, S. J. (1972). Platelet and fibrinogen consumption in man. New Eng. J. Med. 287, 999-1005.

Haymaker, W., and Davison, C. (1950). Fatalities resulting from exposure to simulated high altitudes in decompression chambers: Clinicopathologic study of 5 cases. J. Neuropath. Exper. Neurol. 9, 29-59.

Haymaker, W., and Johnston, A. D. (1955). Pathology of decompression sickness. A comparison of the lesions in airmen with those in caisson workers and divers. Milit. Med. 117, 285-306.

Hills, B. A., and Straley, R. (1972). Aseptic osteonecrosis: A study of tibial blood flow under various environmental conditions. Aerospace Med. 43, 724-728.

Jaffe, W. L., Epstein, M., Heyman, N., and Mankin, H. J. (1972). The effect of cortisone on femoral and humeral heads in rabbits: An experimental study. Clin. Orthopaed. 82, 221-228.

Johnson, L. C. (1964). Histogenesis of avascular necrosis. In Proceedings of the Conference on Aseptic Necrosis of the Femoral Head, St. Louis. pp. 55-79. Washington, D.C.: U.S. Public Health Service.

Jones, J. P., Jr. (1971). Alcoholism, hypercortisonism, fat embolism and osseous avascular necrosis. In Idiopathic Ischemic Necrosis of the Femoral Head in Adults. Chapter VIII. pp. 112-132. Ed. Zinn, W. M. Stuttgart, Germany: Thieme.

Jones, J. P., Jr., and Sakovich, L. (1966). Fat embolism of bone: A roentgenographic and histological investigation, with use of intra-arterial lipiodol, in rabbits. J. Bone Joint Surg. 48-A, 149-164.

Jones, J. P., Jr., and Shim, S. S. [1972]. Unpublished data.

Kahlstrom, S. C., Burton, C. C., and Phemister, D. B. (1939). Aseptic necrosis of bone. I. Infarction of bones in caisson disease resulting in encapsulated and calcified areas in diaphyses and in arthritis deformans. Surg. Gynec. Obstet. 68, 129-146.

Kelly, G. L., Dodi, G., and Eiseman, B. (1972). Ultrasound detection of fat emboli. Surg. Forum 23, 23-25.

Kenzora, J. E. (1972). The osteocyte: Living, dying, dead. A histologic, functional study. J. Bone Joint Surg. 54-A, 1126.

Kistler, G. H. (1934). Sequences of experimental infarction of the femur in rabbits. Arch. Surg. 29, 589-611.

Kistler, G. H. (1935). Sequences of experimental bacterial infarction of the femur in rabbits. Surg. Gynec. Obstet. 60, 913-925.

Kopriwa, B. M., and LeBlond, C. P. (1962). Improvements in the coating technique in radioautography. J. Histochem. Cytochem. 10, 269-284.

Lasch, H. G. (1969). Therapeutic aspects of disseminated intravascular coagulation. Thromb. Diath. Haemorrh. Suppl. 36, 281-293.

Lemoine, A. (1957). Vascular changes after interference with the blood flow of the femoral head of the rabbit. J. Bone Joint Surg. 39-B, 763-777.

LeQuire, V. S., Shapiro, J. L., LeQuire, C. B., Cobb, C. A., Jr., and Fleet, W. F. (1959). A study of the pathogenesis of fat embolism based on human necropsy material and animal experiments. Amer. J. Path. 35, 999-1015.

Mankin, H. J., Zarins, A., and Jaffe, W. L. (1972). The effect of systemic corticosteroids on rabbit articular cartilage. Arth. Rheum. 15, 593-599.

Moran, T. J. (1962). Cortisone-induced alternations in lipid metabolism. Arch. Path. 73, 300-312.

Odland, L. T. (1959). Fatal decompression illness at an altitude of 22,000 feet. Aerospace Med. 30, 840.

Pauley, S. M., and Cockett, A. T. K. (1970). Role of lipids in decompression sickness. Aerospace Med. 41, 56-60.

Peltier, L. F., Wheeler, D. H., Boyd, H. M., and Scott, J. R. (1956). Fat embolism. II. The chemical composition of fat obtained from human long bones and subcutaneous tissue. Surgery 40, 661-664.

Philp, R. B., Inwood, M. J., and Warren, B. A. (1972). Interactions between gas bubbles and components of the blood: Implications in decompression sickness. Aerospace Med. 43, p. 946-953.

Philp, R. B., Schacham, P., and Gowdey, C. W. (1971). Involvement of platelets and micro-thrombi in experimental decompression sickness: Similarities with disseminated intravascular coagulation. Aerospace Med. 42, 494-502.

Rait, W. L. (1959). The etiology of post-decompression shock in air crewmen. U.S. Armed Forces Med. J. 10, 790-805.

Ray, R. D. (1964). Viability of bone. In Proceedings of the Conference on Aseptic Necrosis of the Femoral Head, St. Louis. pp. 145-153. Washington, D.C.: U.S. Public Health Service.

Reeves, E., McKee, A. E., Stunkard, J. A., and Schilling, P. W. (1972). Radiographic and pathologic studies for aseptic bone necrosis in dogs incurring decompression sickness. Aerospace Med. 43, 61-66.

Robie, R. R., Lovell, F. W., and Townsend, F. M. (1960). Pathological findings in three cases of decompression sickness. Aerospace Med. 31, 885-896.

Rokkanen, P. (1962). Role of surgical interventions of the hip joint in the aetiology of aseptic necrosis of the femoral head: Experimental study. Acta Orthop. Scand., Suppl. 58, 1-107.

Rutishauser, E., and Majno, G. (1950). Lesion osseuses par surcharge dans le squelette normal et pathologique. Bull. Schweiz. Akad. Med. Wiss. 6, 333-342.

Salomon, C. D., and Ray, R. D. (1964). Concomitant microradiographic, autoradiographic and histologic observations on undecalcified bone. Stain Tech. 39, 373-380.

Shim, S. S., Patterson, F. P., and Kendall, M. J. (1967). Hyperbaric chamber and decompression sickness: An experimental study. Can. Med. Assoc. J. 97, 1263-1272.

Sillery, R. J. (1958). Decompression sickness. Arch. Path. 66, 241-246.

Strain, W. H., and Berliner, W. P. (1964). Radiologic diagnostic agents: A compilation. Med. Radiogr. Phot. 40 (supplement), 63-78.

Swedlow, D. B., and Katz, L. (1972). Compact Haversian bone: Correlational study on the ultrastructural and microstructural levels of organization. J. Bone Joint Surg. 54-A, 1126.

Todd, R. C., Freeman, M. A. R., and Pirie, C. J. (1972). Isolated trabecular fatigue fractures in the femoral head. J. Bone Joint Surg. 54-B, 723-728.

Trueta, J., and Harrison, M. H. M. (1953). The normal vascular anatomy of the femoral head in adult man. J. Bone Joint Surg. 35-B, 442-461.

Wilkinson, J. A. (1962). Femoral anteversion in the rabbit. J. Bone Joint Surg. 44-B, 386-397.

Woodhouse, C. F. (1964). Dynamic influences of vascular occlusion affecting the development of avascular necrosis of the femoral head. Clin. Orthop. 32, 119-129.

CHANGES IN RHEOLOGY OF ANIMALS FOLLOWING VARIOUS PRESSURE EXPOSURES

M. Mason Guest
Charles H. Wells II
Ted P. Bond

Changes in blood flow and perfusion of bone have been implicated by several participants in this Symposium as a possible cause of aseptic necrosis. Direct observation and recording of blood flow in bone are not very feasible. However, it is a reasonable assumption that, in decompression sickness, blood flow is altered in a characteristic way in all organs and tissues. The observation and recording of flow in a thin tissue, such as the mesentery, permit better resolution of photographic images than is possible in thicker, more opaque tissues.

A syndrome characterized by decreased microcirculatory perfusion, pronounced erythrocyte-aggregate formation, increased blood viscosity, and increased flow through arteriovenous shunts occurs in animals subjected to any of a variety of physically traumatic conditions (Knisely *et al.*, 1945; Bigelow *et al.*, 1949; Replogle, 1969; Schoen *et al.*, 1971). This report describes studies designed to investigate further the characteristics of an apparently similar syndrome that, published reports suggest, might occur in dysbarism (Wagner, 1945; Heimbecker *et al.*, 1969; Wells *et al.*, 1971).

METHODS

Adult mongrel dogs (18) ranging in weight from 9 to 14 kg were anesthetized with sodium pentobarbital, subjected to 5% O_2 in N_2 at 90 psi for one hour, and then decompressed without stops at 9 psi/min. Before compression the mesentery of each animal was exposed by a midline abdominal incision, and one carotid artery was catheterized with a polyethylene catheter for blood-sample collection. Microcirculatory flow in the mesenteric tissue was recorded cinephotomicrographically before compression and periodically throughout the first two hours after decompression. Filming rates ranged from 24 to 300 frames/sec. Magnifications of ×10 to 90 were used (Bond and Guest, 1971*a*). Single-frame 35-mm photomicrographs were also obtained.

Arterial blood samples were collected before compression, immediately after decompression, and 60 minutes thereafter. The viscosity of heparinized aliquots of this blood was determined with a cone-plate (Wells-Brookfield LVT) viscometer maintained at 37°C at 6 shear rates ranging from 230 to 5.75 sec^{-1}. Lee-White coagulation times (Lee and White, 1913), fibrinogen concentrations (Ware *et al.*, 1947), one-stage prothrombin times (Quick, 1957), partial thromboplastin times (Rodman *et al.*, 1958; Bond *et al.*, 1962), and euglobulin lysis times (Celander and Guest, 1964) were also determined for each sample. Data derived from samples collected before compression were compared (student's test for paired data) with those from samples collected either immediately after decompression or one hour later. Several animals failed to survive long enough for collection of the one-hour postdecompression sample. Consequently, 18 sets of data were used for the comparison of precompression and immediate postdecompression values, but only 8 sets of data were used for comparison of precompression and one-hour postdecompression values.

A second study was undertaken to determine the effect of an enlarged air–liquid interface on plasma. Blood collected from mongrel dogs was citrated and centrifuged, and the plasma divided into two aliquots. One aliquot was assayed by the same coagulation and fibrinolytic methods used with the decompressed dogs. The other was foamed by shaking it with air in a test tube with an orbital shaker for five minutes. This sample was then separated into liquid and foam phases and the foam allowed to revert to a continuous liquid phase. Both portions of the sample were then assayed for coagulation and fibrinolytic factors, as previously described.

RESULTS AND INTERPRETATION

Projecting cinematographic images of the mi-

crocirculation in the mesentery of the dog at the rate of 24 frames/sec — images that had been filmed at rates up to 300 frames/sec — permitted slow-motion analyses of changes during the post-decompression period. The cinefilms failed to reveal any blocking of capillaries or larger microvessels by gas bubbles. Bubbles approximately 10 microns in diameter were regularly observed, but these readily passed through capillaries with no indication that they directly affected the velocity of flow. It may therefore be concluded that, under the conditions imposed in these experiments, obstructive gas embolization in the microcirculation of the mesentery was essentially nonexistent during and following decompression.

Notwithstanding the absence of a direct effect of gas bubbles on flow in microvessels, an altered flow was abundantly evident in the post-decompression period (Fig. 1). The features of the altered flow were evidence of aggregation of erythrocytes (especially in venules), a decrease in velocity of formed elements in arterioles and venules, and a reduction in the number of active capillaries. One hour after decompression a significant increase in blood viscosity over precompression values was found at each shear rate measured (Fig. 2). In this same time period the hematocrit increased from 33.6±1.0 to 42.1±3.0 (Table I).

Changes in the character of microvessel flow one hour after decompression were similar to those observed in a variety of shocklike states induced by crush or traumatic handling of tissues (Knisely *et al.*, 1945), burns (Bigelow *et al.*, 1949; Schoen *et al.*, 1971), the intravenous infusion of endotoxin (Bond and Guest, 1971*b*), and the slow intravenous infusion of thrombin or thromboplastin (Guest and Bond, 1968). Following any one of these experimental insults to normal circulatory function, hematocrit increases, erythrocytes form aggregates, velocity of formed elements is reduced, and fewer capillaries contain moving erythrocytes.

A possible interpretation for the similarity in the microcirculatory response in each of the shocklike states, including decompression sickness, is that common mechanisms are responsi-

FIG. 1. Photomicrograph of omental vessels of dog, postdecompression, with erythrocyte aggregation altering blood flow.

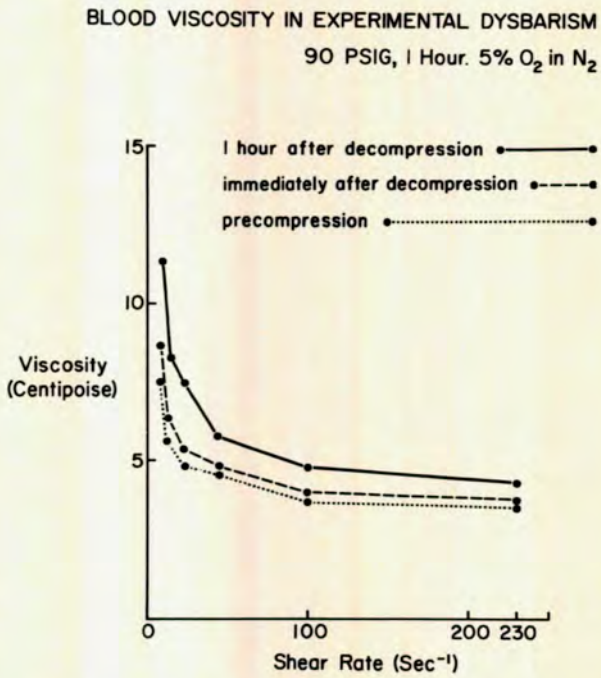

FIG. 2. Blood viscosity at various shear rates immediately after decompression and one hour thereafter.

Table I. BLOOD COAGULATION STUDIES IN DOGS FOLLOWING DECOMPRESSION*

	Precompression, all animals	Immediately after decompression, all animals	Precompression values, animals surviving 1 hr after decompression	Postdecompression values, animals surviving 1 hr
Plasma fibrinogen concentration (mg %)	329±14	318±18	324±25	306±33
Lee-White coagulation time (min)	5.8±0.3	6.0±0.8	5.9±0.5	4.8±0.4
Prothrombin one-stage time (sec)	11.4±0.3	11.7±0.3	11.7±0.4	11.9±0.4
Partial thromboplastin time (sec)	36.6±2.1	39.2±2.6	34.7±2.5	42.5±5.3
Hematocrit	34.3±1.4	34.9±1.3	33.6±1.0	42.1±3.0
Euglobulin units**	82±7***	85±8	97±11	172±30

*Wells *et al.*, 1971. Values presented are means and standard errors of means.
**Euglobulin units are equal to reciprocal of euglobulin lysis time, × 100.
***The mean fibrinolytic activity of samples collected precompression from those animals subsequently surviving less than 1 hr postdecompression was 69±8 euglobulin units.

ble. In each shock state, tissue damage occurs. In some types of shock, tissue damage is the primary insult. In others — such as hemorrhagic shock, thrombin or thromboplastin infusion, and decompression sickness — it may be secondary. It may result from decreased tissue perfusion, with consequent tissue hypoxia, culminating in the release of thromboplastin from damaged cells, or from activation of the coagulation system via other pathways.

If cells (particularly the endothelial cells lining blood vessels) are damaged either by physical trauma or through ischemia and hypoxia, thromboplastic lipoproteins from cell membranes may be released into the circulating blood. Consequently, some activation of the extrinsic pathway for the conversion of prothrombin to thrombin may occur with resultant formation of fibrin. The hypothesis is presented here that a portion of the fibrinogen adsorbed on the erythrocytes (Traber and Kolmen, 1965) is converted to fibrin and that fibrin strands tie the cells together into aggregates.

Although disseminated intravascular coagulation has not been unequivocally demonstrated in dysbarism, some evidence of its existence has been reported (Holland, 1969; Philp *et al.*, 1971). In the present study a significant increase in partial thromboplastin times occurred ($P<0.05$, student's test for matched pairs) from mean precompression values of 34.7±2.5 sec to 42.5±5.3 sec for samples collected one hour after decompression. This finding suggests sufficient activation of the coagulation process to cause depletion of Factor VIII, as observed by Penick and coworkers (1958) in dogs with experimentally induced disseminated intravascular coagulation.

To investigate the possibility that bubbles, as a consequence of their air–liquid interfaces, are responsible for the observed changes in partial thromboplastin times, normal dog plasma was foamed by shaking in air. The results obtained in coagulation assays performed prior to and after foaming are presented in Table II. Prolonga-

Table II. BLOOD COAGULATION STUDIES OF FOAMED DOG PLASMA*

	Plasma before foaming	Foamed plasma	
		Foamed fraction	Fluid fraction
Plasma fibrinogen concentration (mg %)	394±25	399±25	395±25
Prothrombin one-stage time (sec)	11.2±0.5	11.4±0.5	11.1±0.5
Partial thromboplastin time (sec)	46.2±2.9	47.5±3.0	55.4±3.8
Euglobulin units	66.2±4.0	68.0±4.0	61.0±3.6

*Wells *et al.*, 1971. Values are means and standard errors of means.

tion of partial thromboplastin times similar to that observed in decompressed dogs was found in the foamed plasma. It appears probable that the gas–liquid interfaces act as a foreign surface to bring about activation of Factor XII (contact factor).

Further support for the concept that fibrin formation plays an etiologic role in dysbarism may be inferred from the assays of fibrinolytic activity. The precompression euglobulin units measured in dogs surviving one hour or more after decompression were significantly greater ($P < 0.05$) than the values obtained from dogs that succumbed within an hour after decompression (Table I). Those animals with a greater potential for fibrinolytic activation (larger number of euglobulin units) can be expected to lyse fibrin more effectively. Thus if fibrin blocks flow by bonding erythrocytes into aggregates, as seems probable, then animals that can more effectively lyse fibrin strands are better protected from the potential lethality of dysbarism.

SUMMARY

The cinephotomicrographic and blood-viscosity determinations reported here, together with the studies of several other investigators, implicate erythrocyte aggregation as a cause of reduced microvessel flow in dysbarism. Although the etiological factors responsible for this aggregation in dysbarism as well as in other kinds of shock have not been completely identified, fibrin strands, acting to tether cell to cell, are reasonable candidates. Supporting this hypothesis is an altered partial thromboplastin time, both in decompressed dogs and in foamed plasma, together with the high survival rate in animals having a greater potential for fibrinolytic activation.

REFERENCES

Bigelow, W. G., Heimbecker, R. O., and Harrison, R. C. (1949). Intravascular agglutination (sludged blood), vascular stasis and sedimentation rate of the blood in trauma. Arch. Surg. Chicago 59, 667.

Bond, T. P., and Guest, M. M. (1971*a*). High speed cinephotomicrography of the microcirculation. In Cinematographic Techniques in Biology and Medicine. Ed. Burton, A. L. New York: Academic Press.

Bond, T. P., and Guest, M. M. [1971*b*]. Unpublished observations.

Bond, T. P., Levin, W. C., Celander, D. R., and Guest, M. M. (1962). "Mild hemophilia" affecting both males and females. N. Engl. J. Med. 266, 220.

Celander, D. R., and Guest, M. M. (1964). Euglobulin lysis time. In Blood Coagulation, Hemorrhage and Thrombosis. p. 249. Ed. Toncantins, L. M., and Kazal, L. A. New York: Grune and Stratton.

Guest, M. M., and Bond, T. P. (1968). Release of thromboplastin after thermal injury. Ann. N. Y. Acad. Sci. 150, 528.

Heimbecker, R. O., Lemire, G., Chen, C. H., Koven, I., Leask, D., and Drucker, W. R. (1968). Role of gas embolism in decompression sickness — A new look at "the bends." Surgery 64, 624.

Holland, J. A. (1969). Discussion of disseminated intravascular coagulation in decompression sickness. Rep. 585, U.S. Naval Submarine Medical Center, Groton, Conn.

Knisely, M. H., Eliot, T. S., and Block, E. H. (1945). Sludged blood in traumatic shock. Arch. Surg. Chicago 51, 220.

Lee, R. I., and White, P. D. (1913). Clinical study of coagulation time of blood. Amer. J. Med. Sci. 145, 495.

Penick, G. D., Roberts, H. R., Webster, W. P., and Brinkhous, K. M. (1958). Hemorrhagic states secondary to intravascular clotting. Arch. Pathol. 66, 708.

Philp, R. B., Schacham, P., and Gowdey, C. W. (1971). Involvement of platelets and microthrombi in experimental decompression sickness: Similarities with disseminated intravascular coagulation. Aerospace Med. 42, 494.

Quick, A. J. (1957). Hemorrhagic Diseases. p. 451. Philadelphia: Lea and Febiger.

Replogle, R. L. (1969). The nature of blood sludging and its relationship to the pathophysiological mechanisms of trauma and shock. J. Trauma 9, 675.

Rodman, N. F., Jr., Barrow, E. M., and Graham, J. B. (1958). Diagnosis and control of hemophilioid states with partial thromboplastin time (PTT) test. Amer. J. Clin. Pathol. 29, 525.

Schoen, R., Kolmen, S., Wells, C., and Bond, T. P. (1971). Blood viscosity alterations following thermal injury. J. Trauma 11, 619.

Traber, D. L., and Kolmen, S. N. (1965). Absorption of fibrinogen onto erythrocyte surfaces. Texas Rep. Biol. Med. 23, 782.

Wagner, C. E. (1945). Observations of gas bubbles in pial vessels of cats following rapid decompression from high pressure atmospheres. J. Neurophysiol. 8, 29.

Ware, A. G., Guest, M. M., and Seegers, W. H. (1947). Fibrinogen: With special reference to its preparation and certain properties of the product. Arch. Biochem. 13, 231.

Wells, C. H., Bond, T. P., Guest, M. M., and Barnhart, C. C. (1971). Rheologic impairment of the microcirculation during decompression sickness. Microvascular Res. 3, 162-169.

SOME PHYSIOLOGICAL ASPECTS OF DYSBARISM-INDUCED OSTEONECROSIS

BRIAN A. HILLS

The prevention of dysbarism-induced osteonecrosis has proven elusive because the mechanism initiating the disease remains essentially unknown.

It seems generally agreed that the pathology is consistent with a previous state of ischemia (McCallum *et al.*, 1966). This sequence raises the question of whether ischemia is the cumulative effect of exposure to compressed air, or whether there is a certain finite probability of "triggering" the mechanism on each exposure. Unfortunately, it is a difficult statistical problem to differentiate between these two circumstances on the basis of clinical evidence, since both are compatible with the known increase in incidence of the disease as the number of pressure exposures increases (McCallum *et al.*, 1966). However, the fact that the disease can be induced by a single exposure (James, 1945) suggests the "triggering" mechanism.

This immediately raises the *vital question of whether the ischemia occurs within a day or so of the precipitating exposure to increased pressure.* If it does, then one should look at mechanisms of infarction caused by intravascular bubbles, fat emboli, and thrombi. Hypotheses based upon each of these potential embolic agents have been carefully examined by other participants in this Symposium. However, if any of these agents were responsible for dysbaric osteonecrosis, then one would expect a more random distribution than is found in the sites of bone lesions (Elliott and Harrison, 1971). One would also expect evidence of infarction in other organs.

On the other hand, if ischemia does not occur at the time of exposure, then it is necessary to look for a much more subtle form of insult to bone occurring at that time. This view is supported by clinical literature, which suggests an altogether longer time course for the onset of lesions than that predicted on the basis of vascular occlusion precipitated by exposure to pressure.

If one adopts this second view, it then becomes necessary to consider what microscopic change might be induced in bone at some stage of the compression–pressure–decompression sequence that could initiate the disease process to produce ischemia perhaps months or years later. One process that is a particularly sensitive indicator of normal bone physiology is the rate of mineralization. Moreover, it has been pointed out that any initiation of nonregulated deposition of hydroxyapatite at pressure is likely to continue slowly after exposure (Hills, 1970*a*), since the component ions are known to be in supersaturated solution under normobaric conditions (Strates and Neuman, 1958).

This type of reasoning has led to two hypotheses regarding the mechanisms that induce delayed ischemia. The first is based upon the finding that collagen is cross-linked to a different form by elevation of the inspired oxygen partial pressure (Sobell, 1971), which could then have different nucleation characteristics in subsequent mineral precipitation. However, no significant evidence of aseptic osteonecrosis has been reported in subjects who have received oxygen therapy at normal atmospheric pressure.

The alternative hypothesis for delayed ischemia (Hills, 1970*a*; 1971*a*) is based upon the recognized hypersensitivity of the mineralization process to local water content (Neuman and Neuman, 1958). This hypothesis rests largely on the fact that differential concentrations of gases can induce osmosis across various sections of excised tissues (Hills, 1971*b*), including nitrogen across articular cartilage (Hills, 1971*a*). Moreover, bones are known to be good osmometers when the foramina are sealed with wax (Hills, 1972*b*). Thus it has been argued that, if water can be readily shifted in and out of bone, then there are probably large shifts within, causing subtle changes not becoming manifest until much later. Such arguments have led to the experimental program described below. The experimentation was designed not only to compare osmosis induced by diving gases with that induced by nitrous oxide and alcohol, but also to obtain

basic physiological data on bone under hyperbaric conditions.

In the first series of experiments, the osmometer shown in Fig. 1 and described in detail by

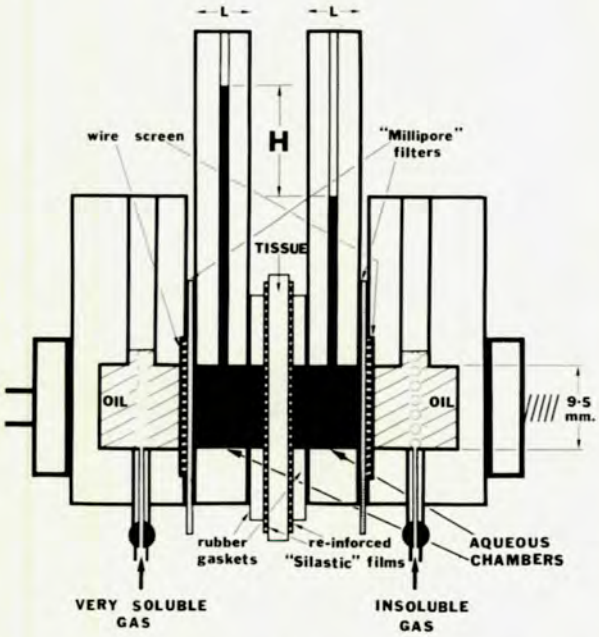

FIG. 1. The osmometer for steady-state induction of osmosis by gases. (Hills, 1970*b*. Illustration courtesy of publisher.)

Hills (1971*b*) was used. With one exception it is essentially a conventional osmometer consisting of two saline-filled chambers separated by the particular tissue being investigated. In this osmometer, the remote ends of the chambers are in contact with oil compartments, but oil and saline are prevented from mixing by capillary action in the Millipore filters placed at each boundary. A very soluble gas (*e.g.*, nitrous oxide) is continuously bubbled through one oil compartment and a relatively insoluble gas (*e.g.*, nitrogen) though the other. Hence each chamber acts not only as a source of one gas but also as a "sink" for the other. This has the effect of maintaining a steady-state total gas-concentration gradient across both aqueous chambers and the tissue section. Saline is found to move in the direction of increasing gas concentration — an effect that is reversed upon switching the two gases.

The tissues studied in this experimentation included bladder, peritoneum, and articular cartilage. Measurement of osmotic pressure permitted an estimate of a minimum value for the reflexion coefficient for both gas and tissue. Osmotic pressure is an index of the degree of a tissue's "leakiness" with respect to a particular gas, with limits of 0 for no selectivity to 1 for a perfectly semipermeable membrane. It can be seen in Fig. 2 that the value of 0.051 derived

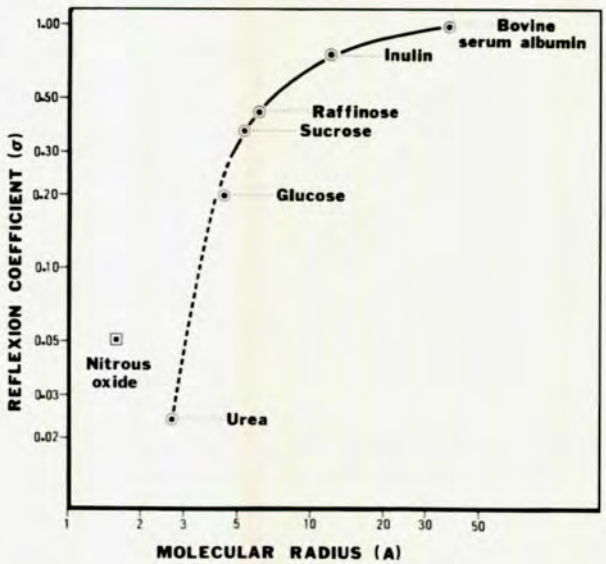

FIG. 2. The reflexion coefficients for several nonvolatile solutes (Davson, 1964) compared with the value derived for nitrous oxide. (Hills, 1972*b*. Illustration courtesy of publisher.)

for nitrous oxide in peritoneal tissue (Hills, 1972*b*) lies almost on the extrapolation line of known values for various nongaseous substances across toad-bladder tissues (Davson, 1964). This finding suggests that gases are no different from other solutes of comparable molecular weight in their ability to induce osmosis.

The next question is whether transient concentration gradients of inert gases *in vivo* resulting from rapid ambient-pressure change can cause a significant shift of water *in vivo* before they are dissipated by diffusion. It is assumed that the fluid then resumes its original distribution in consequence of normal homeostatic mechanisms. A study was therefore made of the kinetics of osmosis induced by gases across articular cartilage by using the apparatus shown in Fig. 1 (Hills, 1972*b*). The results revealed that fluid

transfer rates were about 800 to 900 times greater than predicted on the basis of simple molecular diffusion of water. This finding is consistent with the results of other tests involving induction of osmosis by nonvolatile solutes (Mauro, 1960), and suggests that fluid transfer is hydrodynamic rather than diffusive in nature.

These several findings indicate that even the transient gas-concentration gradients resulting from rapid pressure change can produce an appreciable displacement of fluid. The osmotic concept can be combined with the filtration characteristics of the tissue barrier to give the time course of this fluid shift (Hills, 1972*a*), as shown in Fig. 3.

the features of hyperbaric arthralgia (Hamilton *et al.*, 1966; Fenn, 1969), or "dry joints," in which fluid can be envisaged as shifting out of the avascular joint capsule toward the relatively well-perfused adjacent tissues — *viz.*, the synovium and head of a bone. Selectivity of articular cartilage to gas transmission has already been described.

If such fluxes of water occur between bone and surrounding tissues, they could also occur between local regions of differential blood flow *within* the bone. Shaft lesions certainly seem to follow the general contours of the diaphysis (McCallum *et al.*, 1966) and, hence, the concentric distribution anticipated for zones of equal

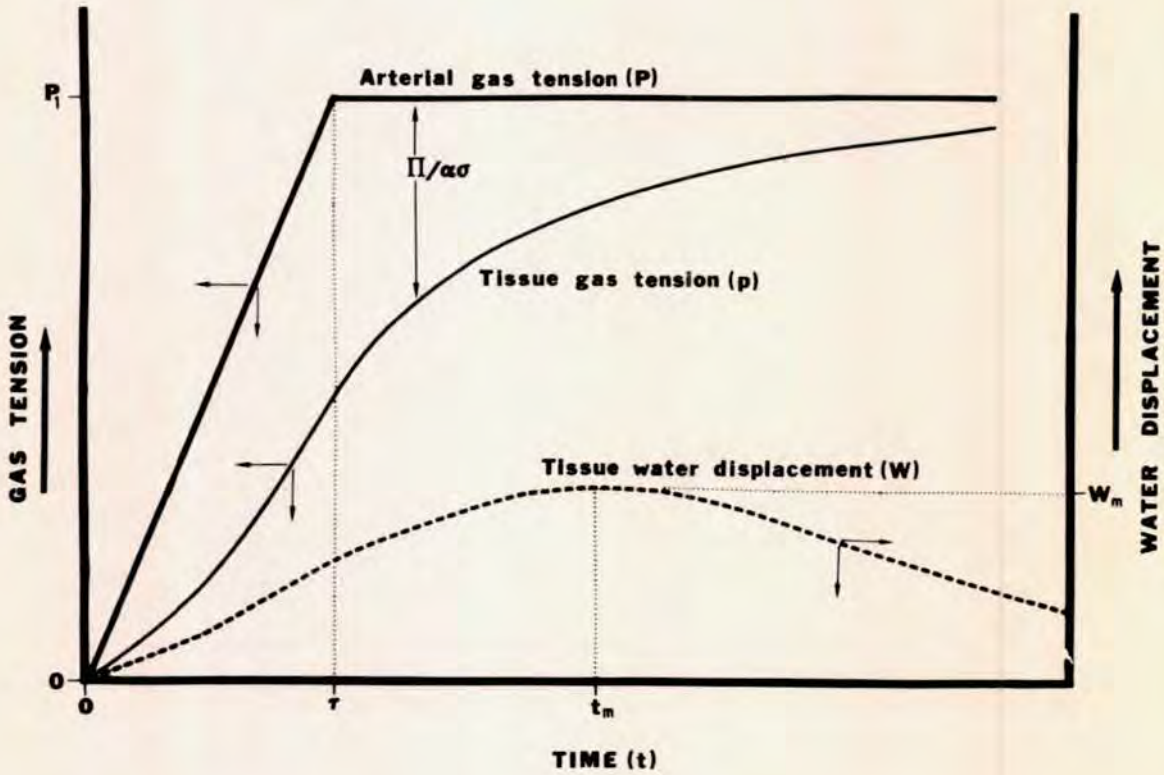

FIG. 3. Time courses predicted for blood and tissue gas tensions, their difference, and resulting fluid displacement. (Hills, 1972*a*. Illustration courtesy of publisher.)

In the particular case of diving to a given depth, analysis would predict a general movement of water toward the better perfused areas, the peak displacement being greater with faster compression. The prediction is compatible with

perfusion. The distribution in blood flow to the ends of a bone appears much less regular, as we see in the femoral head of a guinea pig (Fig. 4) perfused with Micropaque via the common iliac artery just before death. This X-ray film was

FIG. 4. Femoral head of guinea pig perfused with Micropaque via common iliac artery.

taken by using the new technique whereby a very high-intensity source of radiation is placed close to the bone to project a greatly magnified image upon a plate held some distance away.

If the foregoing emphasis upon gas-induced fluid shifts is, in fact, relevant to dysbarism-related osteonecrosis, then rapid changes of pressure should be avoided. Implicated is either or both the compression or the initial phase of decompression to the first stop — *i.e.*, the long rapid first "pull" toward the surface advocated in conventional diving tables. This hypothesis concerning fluid shifts might also explain the occurrence of dysbaric osteonecrosis in the absence of symptoms (*e.g.*, bends), generally agreed to be caused by gas-phase formation (Griffiths, 1969; Walder, 1969).

There appears to be no evidence linking the incidence of bone lesions and the incidence of dysbarism — with one exception: Elliott and Harrison (1971) have reported a positive correlation in a relatively small group of Royal Naval divers. However, this correlation becomes negligible when statistical tests are repeated using only the data on men who have participated in normal diving — that is, after those involved in experimental diving are excluded. Experimental exposures tend to be deep and are typically followed by a rapid initial phase of decompression. These circumstances would induce both extensive osmotic shifts of fluid and the formation of "silent" bubbles, which are difficult to resolve at the shallower stops (Hills, 1970*b*).

In caisson work, however, the records of the tunneling projects on the U.S. West Coast and the vast mass of data now being collected by the U.K. registry of compressed-air workers show no significant correlation between the occurrence of bone lesions and decompression sickness. Moreover, a comparison of two large tunneling projects in England (McCallum *et al.*, 1966), in which like numbers of men worked at similar pressures and followed the same decompression schedules, raises an important question. Why did one group have double the incidence of dysbaric osteonecrosis of the other, while the bends incidence tended to be in the opposite direction?

A definite difference among the various U.K. projects is the rate of pressure change, the procedure being to go as fast as the size of the lock and the valves connecting it to the tunnel or the outside permitted. This protocol is altered only when a man fails to "clear his ears." Chambers and the inlet and exhaust valves controlling their pressure vary greatly from site to site, once again implicating rate of pressure change. When compression and the initial phase of decompression are slower, there appears to be a lower incidence of dysbaric osteonecrosis, as shown in this Symposium by J. Leon Sealey with the Washington State tables.

Perhaps the operation involving the most rapid pressure change, both increasing and decreasing, is submarine escape. It might therefore be of particular significance that bone lesions have been identified in two Royal Naval officers who regularly practice this escape routine (Elliott and Harrison, 1971).

All of this clinical evidence implicating compression or rapid initial decompression to the first stop is compatible with the osmosis hypothesis. However, if gas-induced osmosis occurs within bone, then fluid shifts, and any consequent changes in physiological parameters, should be both transient and reversible. To measure the effect on intramedullary pressure of compression–pressure–decompression exposures, a series of tests was conducted at Duke University (Harrelson and Hills, 1970). In nine mongrel dogs the mid one-third of the femoral diaphysis was cannulated. Intramedullary pressure was measured

and, at the same time, arterial and venous pressures from the femoral vessels of the contralateral limb were monitored. The mean values for about 20 runs are shown in Fig. 5.

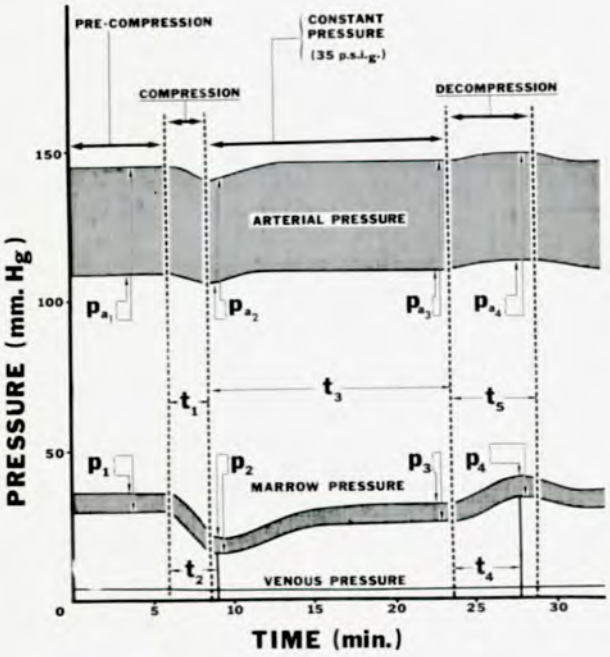

FIG. 5. Variation in intramedullary, arterial, and venous pressures in the dog femur at all stages of hyperbaric exposure. (Harrelson and Hills, 1970. Illustration courtesy of publisher.)

The results showed an initial fall in intramedullary pressure upon compression, with a subsequent return to the preexposure level over the next 10 to 15 minutes. Upon decompression, the intramedullary pressure rose initially and then returned to preexposure level over the next 10 to 15 minutes. Significant correlations were also found between peak rise and rate of compression as well as between peak fall and rate of no-stop decompression. Both effects were greater than could be explained on the basis of arterial or venous pressure changes.

These observations are consistent with the transient, reversible nature of osmosis and its rate dependence on pressure change, as predicted in Fig. 2. Moreover, a switch from air to an 80% N_2O–20% O_2 breathing mixture under normobaric conditions produced the same transient response that compression did in intramedullary pressure. An intravenous injection of 20% ethanol in saline had the same effect, but there was also an appreciable fall in arterial pressure associated with it.

Another basic physiological parameter studied during all phases of exposure to compressed air was bone blood flow (Hills and Straley, 1972). The flow was monitored in the tibiae of mongrel dogs and rabbits by using a device whereby the blood convectively cooled a thermistor heated slightly above body temperature (Shaw, 1963). Cold-shot methods (Lowe, 1968) were also employed. These tests showed a transient rise in bone blood flow upon compression and a transient fall upon decompression. The switch to an 80% N_2O–20% O_2 breathing mixture had the same effect on blood flow that compression did, while upon return to air breathing the flow followed a time course similar to that of decompression. Thus bone blood flow, in view of its response to N_2O, reveals reversible and transient changes that are a function of gas solubility rather than absolute pressure.

The fact that intramedullary pressure and bone blood flow varied in opposite directions with compression and decompression can be interpreted according to the "vascular waterfall" concept applied to the lung by Permutt *et al.* (1962). At least this is so if the intramedullary pressure of bone can be regarded as the counterpart of the hydrostatic alveolar pressure when the effective perfusion pressure is then the arterial–intramedullary pressure difference.

If compression or the initial phase of rapid decompression is indeed responsible for dysbaric osteonecrosis because of gas-induced osmotic shifts of water, then it is interesting to speculate upon the mechanism whereby these shifts can initiate delayed ischemia. Our recent work on mineral precipitation *in vitro* shows that it is only necessary to remove about 5% to 10% of water to induce spontaneous nucleation of crystals. Moreover, pyrophosphate, which is known to inhibit this nucleation process in bone (Neuman and Neuman, 1958), appears to lose part of that function in the presence of alcohol. Alcohol is a known osmotic agent and one well recognized as a factor in idiopathic aseptic osteonecrosis (Kelly, 1969).

In the absence of any conclusive evidence for a physiological mechanism in dysbaric osteonecrosis, the experimentation described above would at least indicate that either or both rapid compression and decompression are better avoided. Furthermore, it would still appear to be a gross

assumption to list dysbaric osteonecrosis as a consequence of failure to allot adequate time to the various decompression stops.

ACKNOWLEDGMENT

This work was supported by contract N00014-67-A-0251-0015 from the Office of Naval Research.

REFERENCES

Davson, H. (1964). A Textbook of General Physiology, 3rd ed. London: Churchill.

Elliott, D. H., and Harrison, J. A. B. (1971). Aseptic bone necrosis in Royal Navy divers. In Underwater Physiology. Ed. Lambertsen, C. J. New York: Academic Press.

Fenn, W. O. (1969). The physiological effects of hydrostatic pressures. In The Physiology and Medicine of Diving and Compressed Air Work. Ed. Bennett, P. B., and Elliott, D. H. pp. 36-59. London: Bailliere, Tindall & Cassell.

Griffiths, P. D. (1969). Clinical manifestations and treatment of decompression sickness in compressed-air workers. In The Physiology and Medicine of Diving and Compressed Air Work. Ed. Bennett, P. B., and Elliott, D. H. pp. 451-463. London: Bailliere, Tindall & Cassell.

Hamilton, R. W., MacInnis, J. B., Noble, A. D., and Schreiner, H. R. (1966). Saturation diving at 650 feet. Ocean Systems, Inc., Tonawanda Research Laboratory, Tonawanda, New York, Technical Memorandum B-411.

Harrelson, J. M., and Hills, B. A. (1970). Changes in bone marrow pressure in response to hyperbaric exposure. Aerospace Med. 41, 1018-1021.

Hills, B. A. (1970*a*). Gas-induced osmosis as an aetiologic agent for inert gas narcosis, gouty arthritis and aseptic bone necrosis induced by exposure to compressed air. Rev. Subaquat. Physiol. Hyperbar. Med. 2, 3-7.

Hills, B. A. (1970*b*). Limited supersaturation versus phase equilibration in predicting the occurrence of decompression sickness. Clin. Sci. 38, 251-267.

Hills, B. A. (1971*a*). Osmosis induced by nitrogen. Aerospace Med. 42, 664-666.

Hills, B. A. (1971*b*). Gas-induced osmosis as a factor influencing the distribution of body water. Clin. Sci. 40, 175-191.

Hills, B. A. (1972*a*). Peak osmotic water displacement induced by gases in tissue. Phys. Med. Biol. 17(2), 277-287.

Hills, B. A. (1972*b*). Clinical implications of gas-induced osmosis. Arch. Internal Med. 129, 356-362.

Hills, B. A., and Straley, R. S. (1972). Aseptic osteonecrosis: A study of tibial blood flow under various environmental conditions. Aerospace Med. 43, 724-728.

James, C. C. M. (1945). Late bone lesions in caisson disease: Three cases in submarine personnel. Lancet 2, 6-8.

Kelly, P. J. (1968). Anatomy, physiology and pathology of the blood supply to bones. J. Bone Joint Surg. 50-A, 766-783.

Lowe, R. D. (1968). Problems in the measurement of blood flow by thermal dilution. In Blood Flow through Organs and Tissues. Ed. Bain, W. H., and Harper, A. M. pp. 6-10. Edinburgh: Livingstone.

McCallum, R. I., Walder, D. N., Barnes, R., Catto, M. E., Davidson, J. K., Fryer, D. I., Golding, F. C., and Paton, W. D. M. (1966). Bone lesions in compressed air workers. J. Bone Joint Surg. 48-B, 207-235.

Mauro, A. (1960). Some properties of ionic and nonionic semipermeable membranes. Circulation 21, 845-858.

Neuman, W. F., and Neuman, M. W. (1958). The Chemical Dynamics of Bone Mineral. Chicago: University of Chicago Press.

Permutt, S., Bromberger-Barnea, B., and Bane, H. N. (1962). Alveolar pressure, pulmonary venous pressure and the vascular waterfall. Med. Thoracalis 19, 239-260.

Shaw, N. E. (1963). Observations on the intramedullary blood flow and marrow pressure in bone. Clin. Sci. 24, 311-318.

Sobell, H. (1971). Effect of hyperbaric oxygen-nitrogen mixtures. O.N.R. Program on Underwater Physiology report ACR-175, Arlington: Dept. of the Navy.

Strates, B., and Neuman, W. F. (1958). On the mechanisms of calcification. Proc. Soc. Exptl. Biol. Med. 97, 688-691.

Walder, D. N. (1969). The prevention of decompression sickness in compressed-air workers. In The Physiology and Medicine of Diving and Compressed Air Work. Ed. Bennett, P. B., and Elliott, D. H. London: Bailliere, Tindall & Cassell.

DISCUSSION 5

Dr. JONES: In my opinion the experimental work presented here today is quite excellent. But I would like to raise a question relative to Dr. Kent Smith's work with the mini-pig Bentley, which had developed bubbles in the region of the arterioles four days after a dive.

As you all know, alcohols are fat solvents. In our posttraumatic fat-embolism studies, we have noted that on the H&E sections all the fat emboli are washed out. They appear as negative artifacts, which may actually look like gas bubbles. We worked with Shim, Copp, and Patterson (1968), who were able consistently to produce marked intraosseous gas bubbles by rather rapid decompressions, but were unable to produce histological evidence of avascular necrosis. I was fortunate enough to be able to review their material. They did consistently develop rather substantial fat embolism in tissues, including kidney and lung, in virtually every animal. Certainly if they have had systemic fat embolism in these other tissues, it could go to bone. So I should like Dr. Smith to use our techniques or to have the opportunity myself of seeing some of his pathological material and staining these areas for fat.

In our experience and in that of several other investigators, thrombocytopenia is one of the first hematological abnormalities to follow traumatic fat embolism, and has been attributed to microvascular coagulation or deposition of fibrin thrombi. As early as 24 to 48 hours, we have seen a marked reduction in platelet count, down to 50,000. And, of course, disseminated intravascular coagulation has been recently well documented clinically and experimentally in fat embolism.

There is normally osteocyte death *in vivo;* Frost (1960) has shown this in intratrabecular lamellae. I don't think that the absence of osteocytes in itself is definitely an indication of necrosis, particularly if there is a rather marked inflammatory response with giant cells. Saponification of intramedullary diaphyseal fats occurs, and I think this has been shown in the diaphyses of experimental animals.

Our consulting hematologist, Dr. Ralph Wallerstein, and I have been interested in the deposition of these fibrin thrombi distal to occluding fat globules. Following traumatic fat embolism, there are decreases in Factor VIII and Hageman factor, and it is important to recognize — and I think this is probably the critical point — that it takes a minimum of 10 to 12 hours of complete intravascular blockade to show the first histochemical abnormalities representing osteonecrosis or avascular necrosis.

Guest *et al.* (this volume) have, as you know, studied the hemodynamic alterations caused by intravascular gas emboli. But these emboli, when they do block, are quite temporary, remaining perhaps only 2 to 3 minutes. Although vasospasm with reflex hyperemia may occur, blockage of these vessels must last longer than just a few minutes before necrosis can result.

Dr. SMITH: While fat is no doubt often present, there is inconclusive proof at this time to claim that it is causally related to osteonecrosis. Hyperlipidemia or fat embolus is present in the circulatory system in many conditions in which it is not pathologic; lipolysis is continually taking place. We profess a bubble-etiology hypothesis, bubbles which can be detected electronically and then visually and acoustically presented — thanks to Dr. Spencer and the Doppler ultrasound bubble detector. Bubbles can be heard rushing through the circulatory system, human as well as animal, following standard decompression profiles.

That one sees these bubbles histologically is in question. One cannot focus up and down on a 35-mm slide. One cannot see what configuration the tissue space really has. Whether or not it was a fat globule before clearing, I could not definitely say. However, I would say that fat particles in the

bloodstream do not deform red blood cells. When one sees a vacuole in an arteriole that is obviously dilated and deforming red cells, it is indicative of pressure there, and pressure does not build up in a fat globule. We think that the tissue spaces represent bubbles, and the pathologists whom we have examining these slides agree. I am not a pathologist.

Dr. MILES: Well, you partially answered the question. But may I ask you, please, to satisfy Dr. Jones and me: would you stain for fat?

Dr. SMITH: Yes.

Dr. HILLS: I was most interested in Dr. Wells's work, in which he has shown an increase in the viscosity of blood upon decompression. Have you also measured viscosity upon compression? With respect to gas-induced osmosis, we have measured hematocrit at pressure and find hemodilution, whereas there is hemoconcentration upon decompression.

Dr. WELLS: We have measured the viscosities of a limited number of blood samples collected immediately after compression. Although the number of samples studied is small, we have found no indication that changes in viscosity result from the compression process.

Dr. HILLS: Did you return to atmospheric pressure immediately after the compression?

Dr. WELLS: No, we rapidly compressed the animals to 90 psig and held that pressure for one hour before decompression. The decompression rate was held at 9 psi/min until ambient pressure was reached.

Dr. WORKMAN: My question concerns the intramedullary bone-marrow pressures that Dr. Hills has done. In a paper in which he reported this study, I think he also had a few measurements of the intramedullary blood Po_2. To me, at least, it would be reasonable to assume that if there were occlusion of circulation with evidence of increased intramedullary pressure, the Po_2 as a source of ischemia might have been decreased. Was there any evidence of a decrease in Po_2 in the intramedullary blood?

Dr. HILLS: I cannot remember now exactly what those values were. We do not postulate that the slight ischemia seen at that time (Harrelson and Hills, 1970) is responsible for osteonecrosis, because it seemed too transient. At the time, we interpreted intramedullary pressure in terms of bone blood flow. But when we actually measured bone blood flow, we found exactly the opposite (Hills and Straley, 1972).

Dr. MILES: We became interested in intraosseous, or intramedullary, bone pressure a number of years ago as a means of diagnosing avascular necrosis of bone. In this project, we introduced fairly large trocars into the femoral heads — proximal to the fracture site and into the normal femoral head as well — to measure the intramedullary pressure while we did various things to increase and decrease the blood pressure. We found that this method of predicting avascular necrosis was just about as accurate as flipping a coin. Then we realized that we are dealing with a very fluid situation.

It is commonly assumed that the cortex of bone consists of osteons and Haversian systems with a canal extending the length of the cortex. The Haversian system is viewed as extending from the knee joint to the hip joint, which is a good 17 to 18 inches. But in the medullary systems the osteons making up the bone cortex in fact extend only about 4 cm, beginning somewhere on the periosteal surface and ending somewhere on the endosteal surface of the cortex. They receive their blood supply from both periosteal and endosteal sources and, in truth, we do not know which direction the blood flow takes.

Many clinicians take advantage of this circulation, of course, in giving intraosseous fluids, and within a matter of a very few seconds those fluids become a part of the circulating fluid volume. One may perform an intraosseous venogram of the leg by putting a needle into the medial malleolus, and within 8 to 10 seconds the leg veins will be demonstrated. An intraosseous venogram of the thigh will result from putting the needle into the tibial tuberosity, and a venogram of the pelvic veins will result from a needle in the trochanter.

We are thus dealing with a fluid system within the medullary canal of bone. The measurements that we are making of the intramedullary pressure and those that other investigators have made of pH, oxygen tensions, and isotopes are essentially not significantly different from those made of peripheral venous blood. The medullary canal is therefore not apart or separate from the vascular system itself.

Dr. WORKMAN: I am familiar with a few studies that really showed arterial and venous circulation very well, but not capillary circulation. At the Naval Medical Research Institute, Buckles (1968) made a very fine experimental preparation of the cheek pouch of the golden hamster. Some of you have probably seen the film he made following decompression of these animals. He was able to demonstrate gas bubbles forming large columns that completely filled both the venules and arterioles. As far as I know, he was never able to demonstrate any passage of this gas through the capillaries. The columns made contact with the capillary, as well as one could determine, but did not pass through. I suggest that there is a serious question about whether what Guest *et al.* concluded were spherical bubbles passing through capillaries were in fact bubbles. This was a primary question in Buckles' experiment, and I think it was finally concluded that separated plasma with the aggregated cells may have produced some of these bubble artifacts.

Dr. EVANS: I would like to ask something about Dr. Wells's presentation. First of all, I wonder if he could tell us what sort of viscometer he used, as the values for blood viscosity that he quoted are about half the values one would expect for human blood of similar packed-cell volumes (PCV). Secondly, he suggested that the rise in viscosity following decompression might not be completely accounted for by the rise in PCV. There have been several studies of the effects of PCV on the viscosity of blood at various shear rates, including one of our own (Weaver *et al.*, 1969); it should therefore be possible to decide whether this is so or not. Thirdly, I wish to ask Dr. Smith if he found similar rises in PCV following the severe decompressions that his miniature swine were subjected to.

Dr. WELLS: We used a Wells-Brookfield LVT cone-plate viscometer. We certainly agree that blood viscosity, at any shear rate, is strongly influenced by the hematocrit of the sample. In human or dog blood with this hematocrit, we generally find that the viscosity at a shear rate of 230 sec^{-1} (where it becomes essentially Newtonian) is approximately 4 centipoise. I think that you will find these values are in reasonable agreement with those of most investigators using samples of similar hematocrits.

Your suggestion that the viscosity increases which we observed might be due entirely to increased sample hematocrits certainly merits consideration. There is no doubt that it accounts for a major portion of the viscosity increase after decompression. However, I doubt that the factors responsible for blood viscosity can be assessed with sufficient precision to allow us confidently to attribute changes in this variable to alterations in hematocrit alone. Adding to this uncertainty are indications of an increased erythrocyte

aggregation after decompression, which should contribute to an increased blood viscosity.

Dr. EVANS: I quite agree that variations in, say, fibrinogen, which would alter cellular cohesion, do influence viscosity. But for a given fibrinogen concentration, the variation of viscosity at any one shear rate with PCV can be tied down very closely. One can get very nice families of graphs of log viscosity against PCV in which the slopes, in fact, can be related to the shear rate in such a way that one can extrapolate to any shear rate that one wishes. I think it should be possible to get a very precise idea of whether the viscosity change can be accounted for in this way, or whether there is something else to look for.

Dr. McCALLUM: I should like to ask Dr. Kent Smith whether the pigs he is using are susceptible to a bone disease affecting the hip joints, such as occurs in some animals being bred for bacon production. Second, I noted in one of his femoral lesions that there was a periosteal reaction which seemed to me rather different from the sort of thing we normally see in bone necrosis in humans. I wonder if he would care to add any further comments.

Dr. SMITH: First, to answer Mr. Evans' question about packed-cell volume: even in the severe decompression injuries we have had, we have not seen significant increases. However, we have seen some increase in platelet adhesiveness, 37% to 40% in some studies.

Dr. McCallum, the disease condition that you mention may be erysipelas. It is an endemic disease and is one cause of the few bone problems that swine have in the United States.

Dr. McCALLUM: I am not sure that we are talking about the same disease. As I understand it, the veterinary surgeons in Britain do not know what disease causes the problem. They have discussed the possibility of its being an infection, but the feeling seems to be that it is more probably a nutritional disorder. It was causing difficulties in mating large pigs, because the boar could not mount the sow due to the joint disease (Duthie and Lancaster, 1964).

Dr. SMITH: I do not know if this nutritional condition exists in the United States; at least it is not very prevalent if it does exist. The occurrence of bone lesions in our animals correlates well with exposure to compression/decompression. Since no accompanying signs of disease are present, such as erysipelas might produce, we would rule this out very early in a differential diagnosis.

Dr. ALLEN: I should like to raise a point about the animal model of the dog. A few years ago, we were able to show that blood in the dog spleen has a hematocrit twice that of blood in the large vessels (Allen and Reeve, 1953). With appropriate stimulation, this reservoir of red cells will empty into the circulation. Barcroft *et al.* showed this earlier (1925), with much simpler techniques. The best model for experiments such as Dr. Hills performed is a dog splenectomized perhaps a month beforehand.

Dr. HILLS: I forgot to mention that we were aware of this problem and used splenectomized dogs in measuring the effects of compression and decompression on hematocrits.

I would like to ask the clinicians a question. Does it seem that the appearance of the first radiological signs of osteonecrosis is really consistent with the occurrence of ischemia at the time of exposure? The answer would help me, at least, to sort out the possible mechanisms in the production of osteonecrosis, because I would think that infarction would then occur within a day or two of exposure.

Dr. KINDWALL: In our surveys all of us are looking for X-ray changes, but Dr. Walder has demonstrated that we must reconsider our concepts about when the insult may actually occur. With histological work he has shown that a much larger area of necrosis is involved than is detected radiologically and that much repair has taken place before we see X-ray evidence. So any relationship that we presume between a lesion and the time of the injury may be quite inaccurate.

Perhaps Dr. Elliott can answer a question. Radiographing volunteers at the Gosport escape training tower would probably be a good means of determining whether rapid compression makes matters worse in terms of aseptic necrosis. These men were compressed within a matter of seconds to between 500 and 600 FSW. Have they been X-rayed?

Dr. ELLIOTT: Yes, and two cases of bone necrosis were found in that group. But at the same time, I hesitate to say whether this finding would indict compression or decompression.

Dr. JONES: I would like to comment on the earliest roentgenographic evidence of necrotic changes following a known inciting event. As far as I am concerned, there are three types of identifiable trauma to bone circulation. The first occurs in those patients who sustain a fracture or dislocation. The second is found in patients who receive exogenous medications known to be associated with necrosis — *e.g.*, corticosteroid-treated patients, principally those treated for immunosuppression. The third occurs in persons who have experienced occupational exposure to dysbarism beginning at a certain point in time.

Dr. Walder has reported that his earliest roentgenographic evidence is 4 months following a specific exposure to compressed air. Our first roentgenographic evidence of necrosis following corticosteroid treatment is at 3 months. There is a great difference of opinion, however, about when the first changes occur following, say, a displaced subcapital femoral-neck fracture or a posterior dislocation of the hip. Generally, the earliest changes that I have been able to detect on X-ray, and these have been tomograms, are after 5 to 6 months.

Dr. WALDER: I think that 3½ months is probably the shortest time lapse between the causative insult and the first recognizable radiographic changes of osteonecrosis.

I would like to take up for a moment this question of the rate of compression as opposed to the rate of decompression as the causative factor in the production of osteonecrosis. In 1931 H.M. Submarine *Poseidon* sank in 126 ft of water. There was difficulty in filling the escape compartment with water to equalize the pressures within and without the vessel, and it was 2½ hours before the first men were able to escape. Thus there was a very slow rate of compression. Once the men had escaped they made a rapid ascent to the surface — a good example of slow compression followed by rapid decompression (James, 1945). Three of them were traced some years later and all had osteonecrosis affecting several bones.

I would also like to comment on the film shown with the Guest, Wells, and Bond presentation (this volume), in which bubbles in the mesenteric vessels of a dog were demonstrated. Perhaps all details of the experiments were not given, but one would not necessarily expect either decompression sickness or subsequent bone necrosis to follow the occurrence of the bubbles demonstrated, unless the animal's tissues were saturated with gas. Surely, what happens in man in a decompression is that, if free bubbles are generated, they go round the circulation until they come to a tissue heavily saturated with gas. In that tissue they expand and get stuck. They have then cut off

blood supply to the very bit of tissue in which they are lodged so that they have set up a vicious circle.

Dr. MILES: I would also like to discuss this matter of time. Of course, no one can tell us when a cell is alive or when it is dead. No one can tell us which enzyme, when present, indicates viability of the cell but, when absent, indicates necrosis of the cell; or which enzyme, when present in small amounts, indicates that the cell is sick yet is going to survive, but when present in smaller amounts means that the cell is sick and going to die.

Kuhlman and Miller (1967) did some very sophisticated work — the best that I know of — using microchemical techniques on various enzymes and on ATP. Their concept was that once ATP was expended, there were no means whereby the cell might regenerate these important enzymes.

If the premise is valid, it would appear that bone can survive 6 to 7 hours of ischemia without becoming necrotic. The reparative process occurring between that time, when biochemical death is apparent, and 8 to 10 days later, when the diagnosis of osteonecrosis can be made microscopically, is called creeping substitution. This substitution, when in large enough an area, makes the diagnosis of osteonecrosis possible radiographically some 3 to 6 months later. It is apparent that we must find another method of determining cellular death, which can then be applied clinically or biochemically earlier in patients with suspected osteonecrosis.

In addition, Dr. Walder very wisely commented that the extent of necrosis is much greater than that which appears in the roentgenogram at a very late date. Microscopically, one can see that all — or perhaps 80% to 90% — of the larger area has been replaced, with only a small area of necrosis remaining.

Such difficulty in interpreting roentgenograms led to an argument in orthopedic literature about whether the femoral head followed an "all-or-none" principle after femoral-neck fracture — that is, whether the entire femoral head becomes necrotic following a fracture (or perhaps up to 95%, excluding that area around the fovea capitis femoris). Current orthopedic literature now contains many examples indicating that the femoral head may not follow this "all-or-none" principle. These examples suggest that there may be focal areas of necrosis anteriorly, posteriorly, or superiorly, which may reflect isolated and incidental occlusion of one of the superior, or lateral, epiphyseal vessels. This might indicate that focal necrosis is the real problem.

REFERENCES

Allen, T. H., and Reeve, E. B. (1953). Distribution of "extra plasma" in blood of some tissues in the dog as measured with P^{32} and T-1824. Amer. J. Physiol. 175, 218-223.

Barcroft, J., Harris, H. A., Orahovats, D., and Weiss, R. (1925). A contribution to the physiology of the spleen. J. Physiol. 60, 443-456.

Buckles, R. G. (1968). The physics of bubble formation and growth. Aerospace Med. 39, 1062-1069.

Duthie, I. F., and Lancaster, M. C. (1964). Polyarthritis and epiphyseolitis of pigs in England. Vet. Record 76, 262-263.

Frost, H. M. (1960). *In vivo* osteocyte death. J. Bone Joint Surg. 42-A, 138-143.

Harrelson, J. M., and Hills, B. A. (1970). Changes in bone marrow pressure in response to hyperbaric exposure. Aerospace Med. 41, 1018-1021.

Hills, B. A., and Straley, R. S. (1972). Aseptic osteonecrosis: A study of tibial blood flow under various environmental conditions. Aerospace Med. 43, 724-728.

James, C. C. M. (1945). Late bone lesions in caisson disease. Lancet 2, 6-8.

Kuhlman, R. E., and Miller, J. A. (1967). The biochemical changes preceding tissue death in rats. J. Bone Joint Surg. 49-A, 90-100.

Shim, S. S., Copp, D. H., and Patterson, F. P. (1968). Measurement of the rate and distribution of the nutrient and other arterial blood supply in long bones of the rabbit. J. Bone Joint Surg. 50-B, 178-183.

Weaver, J. P. A., Evans, A., and Walder, D. N. (1969). The effect of increased fibrinogen content on the viscosity of blood. Clin. Sci. 36, 1-10.

PART VI

DIAGNOSIS OF OSTEONECROSIS

RADIOLOGICAL CRITERIA IN DIAGNOSING DYSBARIC OSTEONECROSIS

JOHN A. B. HARRISON

The purpose of this presentation is to define the criteria by which it is possible to make a definitive radiological diagnosis of the lesions of dysbaric osteonecrosis (McCallum *et al.*, 1966). The difficulty in an accurate early diagnosis of these lesions is twofold: Is one looking at a variant of normal bone structure (Blank and Lieber, 1965; Kim and Barry, 1968; Ngan, 1972), perhaps a minor dysplasia of bone; or is one looking at aseptic bone necrosis caused by something other than a dysbaric environment (Bucky, 1959; Golding, 1962, 1966; Edeiken, 1967; Jaffe, 1969)?

Most investigators are now familiar with the following classification of lesions, which frequently precede symptoms. Developed in England by the Medical Research Council's Decompression Sickness Panel, this classification has received fairly wide international acceptance as radiological evidence of early aseptic bone necrosis.

Juxta-Articular

A1 Dense areas with intact articular cortex
A2 Spherical segmental opacities
A3 Linear opacity
A4 Structural failures
  a. Translucent subcortical band
  b. Collapse of articular cortex
  c. Sequestration of cortex
A5 Secondary degenerative arthritis (osteoarthritis)

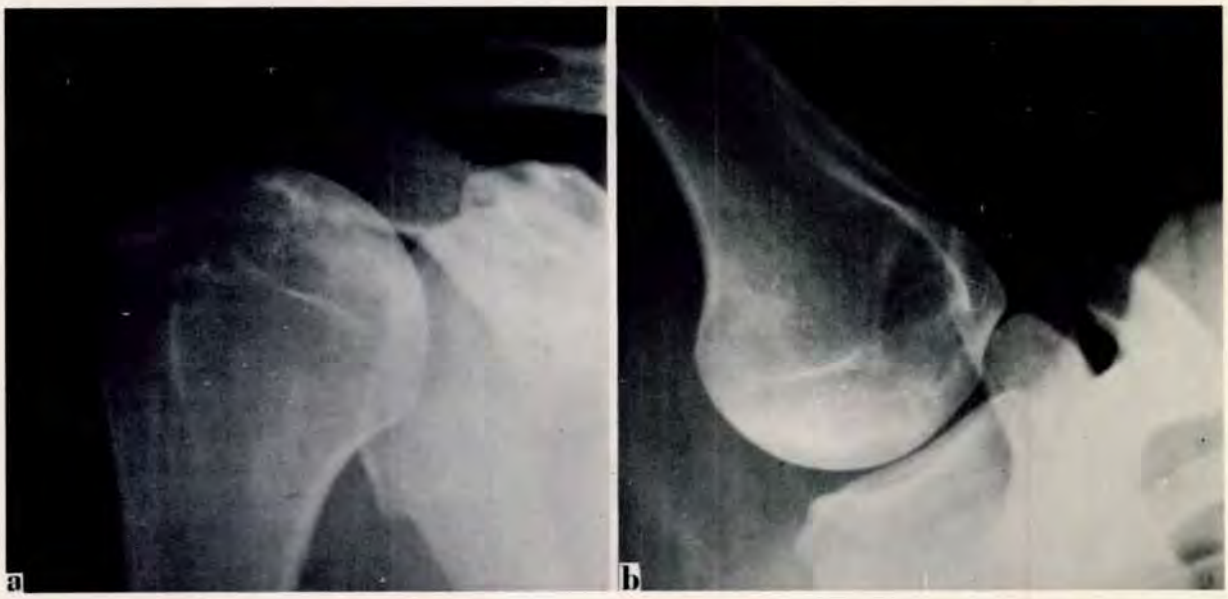

FIG. 1. (*a*) Standard survey X-ray film of a shoulder, in which a juxta-articular lesion can be seen. (*b*) Inferosuperior view of same shoulder, showing lesion more clearly.

Preceding page blank

Head, Neck, and Shaft

B1 Dense areas (*not* bone islands)
B2 Irregular calcified areas
B3 Translucent areas and cysts
B4 Cortical thickening

As Dr. McCallum has mentioned in this Symposium, these criteria have been used in England for a considerable time (Golding *et al.*, 1960; Davidson, 1964; McCallum, 1968; Davidson and Griffiths, 1970; Walder, 1970). One great advantage of their use in a survey of aseptic bone necrosis is their applicability to the whole gamut of lesions caused by exposure to pressure changes. It has been found that this classification applies both to the more extensive, more rapidly developing lesions of caisson workers and to the apparently less serious, more slowly developing lesions found in Royal Naval divers. The individual lesions have been described many times; but, basically, a radiological diagnosis of osteonecrosis can be made when ill-defined densities or translucencies are detected, provided that these changes are definitely pathological.

For those experienced in diagnosing osteonecrosis, the real problem concerns juxta-articular lesions. One can usually be certain about dense areas found close to the articular cortex (A1 lesions). But the exact description of A2 lesions, such as spherical segmental opacities, has long been argued. Opacity is fairly obvious in an advanced lesion; but in an early lesion it is difficult to be certain on a single radiograph. The linear opacity of A3 lesions is somewhat easier to identify. Radiological identification is more certain with the structural failures involved in A4 lesions. Degenerative arthritis caused by aseptic bone necrosis must be distinguished from arthritis of other etiology. It does appear that the joint space is maintained rather longer in degenerative arthritis resulting from dysbaric osteonecrosis than from other causes.

Figure 1*a* shows the standard survey view used for the shoulder, in which a lesion can be seen. The inferosuperior view (Fig. 1*b*) shows this lesion much more clearly, with a lucent area just below the cortex and ill-defined densities in the head. The question of how far to go with radiography immediately arises. The Royal Naval approach is to carry out the initial survey with a minimum number of radiographs and then to investigate any doubtful lesions found with further radiographic projections.

Figure 2 shows the progression of one of the few juxta-articular lesions found among Royal Naval divers. The subject had ceased active

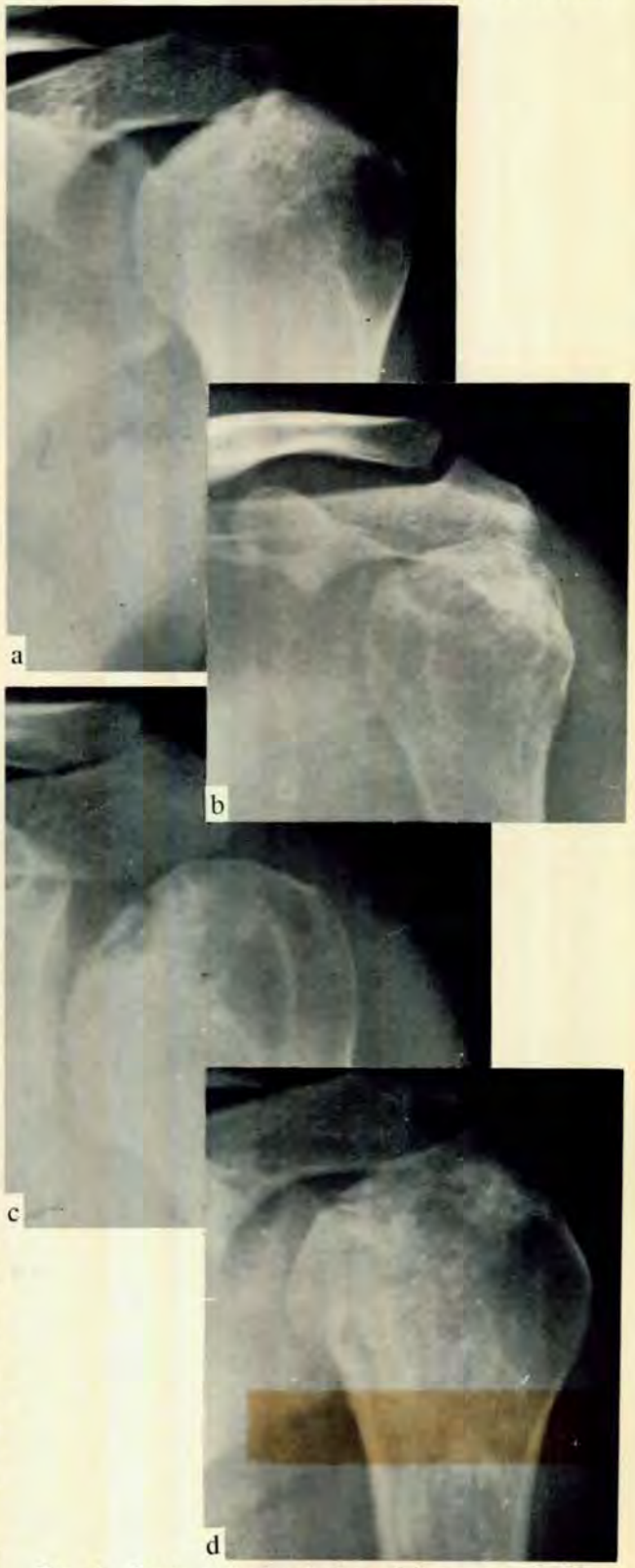

FIG. 2. Juxta-articular lesion of humerus of diver in (*a*) 1960; (*b*) 1963; (*c*) 1964; and (*d*) 1967.

FIG. 3. A-P and lateral views of medullary lesions in femora and tibiae.

diving when he was included in the 1967 X-ray survey conducted by the Royal Navy (Elliott and Harrison, 1970; Harrison, 1971). Once the lesion (which is extensive compared with those found in other RN divers) was found, a search was made of RN X-ray film records for earlier evidence of bone disease in this man. The radiographs made in 1960 and 1963 show earlier collapse of the articular cortex. This degeneration, in which the intact articular cortex collapses into the area of necrosis below, is typical. The 1964 radiograph clearly shows separation in the cortical area. By 1967 the cortex is disrupted and there are widespread opacities and lucencies in the humeral head, indicating a large area of aseptic bone necrosis. Since the subject continued diving after 1960, progression of the disease process in this instance was obviously a relatively slow one, even for a juxta-articular lesion (although this lesion did produce symptoms).

Figures 3 and 4 illustrate lesions in the neck and shaft of the tibiae and femora, which Lent Johnson, M.D. (personal communication, February 1972), suggested should be differentiated. He may be correct in his assertion that, pathologically, there are different types of lesions. But it is not possible to differentiate among them on an ordinary radiograph; it is difficult to state with certainty whether a lesion is in cancellous or medullary bone. *Cortical thickening* is perhaps a crude term, because a radiologist can divide the cortex into periosteal, cortical, and endosteal bone. Perhaps this term should be refined in the classification.

Most of the symptomless lesions found in Royal Naval divers are of the B2 type. These are the irregular calcified areas described in earlier papers (Kahlstrom *et al.*, 1939; Allan, 1943; Poppel and Robinson, 1956). It is difficult to judge to what extent the radiographic record of a lesion accurately reflects its actual extent, as illustrated in Fig. 3 and 4. But it is possible to define radiologically the extent of a femoral lesion much more accurately if a lateral view of the knees is available. A 15″ × 12″ film is used because, in British experience, femoral lesions extend quite a distance up the shaft; the lesions are not quite so extensive in the shaft of the tibia. It is therefore important in a survey to include more of the femora than of the tibiae when X-raying the knee region.

It is not vital to specify a rigid radiographic technique to be used in a survey of divers' bones. Different investigators use different methods, but comparison is facilitated by using standardized radiographic projections. High-quality radiographs with good bone detail are necessary so that any developing minor lesions, which may become apparent only on serial (annual) X-rays, might be assessed. This objective is difficult to achieve in a survey involving large numbers of people, when X-rays are taken in different establishments, and when it is desirable to limit the radiation of the subject.

It has been the practice in RN surveys to take a single A-P X-ray of each shoulder and hip, and A-P and lateral films of the knees. A definite positive lesion has not been found in the hips of RN divers, but it may well be that the frogleg position is rather better than the A-P in revealing these lesions.

A screen film with a Bucky, where suitable, is used. Every effort is made to protect the gonads from ionizing radiation by using a gonadal shield, particularly in projections of the femoral heads. For all projections except the knees, 12″ × 10″ radiographs are used; knees are X-rayed on 15″ × 12″ films (both A-Ps on one and laterals on another).

Because positive identification of early lesions of dysbaric osteonecrosis is difficult, it is important to substantiate the subjective impression by a second reading. The results must obviously be recorded at whatever facility the X-rays are taken in the event that a lesion requiring immediate attention is found. But the films should then be sent to a central registry for reading and comparison with any earlier films of the subject to detect any minor alterations of trabecular structure and density, which are often the earliest signs of a lesion, particularly in the shaft. These lesions have been the ones most frequently found in RN divers.

The actual radiographic instructions used in the RN survey are as follows:

Shoulders

A-P radiographs of each head of humerus and proximal shaft. The trunk is rotated to bring the shoulder in contact with the table with the arm pulled down in a neutral position. Cone to show as much humerus as possible, but bring the lateral diaphragms in as much as possible to show only the head and shaft of the humerus.

Hips

A-P radiographs of each femoral head and proximal shaft. Center over the head of the femur (*i.e.*, 1″ below the midpoint of a line joining the anterior-superior iliac spine and upper border of the pubis symphysis. Cone with the light beam diaphragm to give a 4″ × 4″ result. The feet should be at a 90° angle with the table top.

Knees

A-P and lateral radiographs of each knee, including the distal femur from its midpoint and the proximal tibia and fibula to about the midpoint.

Instructions to the three or four centers at which the X-rays are taken stress that the humeral head must be clear of such structures as the acromion and the edge of the glenoid. The problem of overlapping is the same in the hip, which is why the frogleg position may possibly be better than the A-P projection as a single view of that joint. With the knee, it is primarily important to get good bone detail, including a fairly lengthy portion of the femoral shaft, as was said.

A three-year survey of 383 clearance divers completed by the Royal Navy in 1969 initially revealed 16 divers with positive lesions of osteonecrosis and 11 divers with doubtful ones. Further investigation was concentrated on the lesions in the 11 doubtful cases; by tomographs and further radiographic projections, 4 doubtful cases were eliminated. These 4 men have continued diving since 1970 and have had further annual X-rays; in our opinion they have remained radiologically negative. This reduction of doubtful cases from 11 to 7 resulted from further radiologic investigation leading to an altered opinion regarding the lesions. Of the remaining 7 doubtful cases, only 3 so far have had further radiological investigation and they remain doubtful. Two cases have not yet been traced for further X-ray (they have left the Navy). And 2 have not yet been X-rayed again.

Because of the possible differential diagnosis of dysbaric osteonecrosis, the following control sample of 100 nondiving naval personnel in the same age groups as the RN diver sample was X-rayed:

Rank	Age	Number
Lieutenant Commander	31 to 47	6
Lieutenant	23 to 30	11
	34 to 45	4
Sub-Lieutenant	29 to 34	2
Chief Petty Officer	32 to 49	9
Petty Officer	25 to 39	28
Leading Seaman	20 to 33	20
Able Seaman	to 30	20

It is felt that the samplings were comparable in every way, yet the control group revealed none of the bone lesions found in the X-ray films of the RN diving population.

The extensive differential diagnosis listed below tabulates pathological conditions in which aseptic bone necrosis undoubtedly occurs. From a radiological standpoint, however, the differential diagnosis is probably of significance only in the diseases marked with a single asterisk; in those marked with a double asterisk, the exclusion of other causes by diagnostic means presents a difficulty:

Diabetes mellitus	Trauma
**Chronic alcoholism	Rheumatoid arthritis
**Hypercorticism	Autoimmune arthritides
Cirrhosis	Gout
Hepatitis	Ionizing radiation
*Blood dyscrasia	*Syphilis
*Gaucher's disease	**Chandler's disease
*Chronic pancreatitis	Arteriosclerosis
Caisson's disease	

There are, of course, other conditions in which aseptic bone necrosis occurs, but most of them can be accurately identified by radiology or by other methods of investigation. In all events it is felt that such conditions are not of common concern in naval divers.

Figure 5 illustrates another aspect of the differential diagnosis of osteonecrosis: *i.e.*, differentiating osteonecrotic lesions from other localized bone lesions. It was originally considered that the defined sclerotic area in this film of the fibula was a positive B2 lesion. But the Newcastle MRC decompression registry contained no X-rays of lesions in the fibular neck. We therefore remained doubtful, even though it is known that the Japanese have found lesions in the fibular neck in divers (Nagai and Ibata, 1965; Matsunaga and Shigeto, 1967; Asahi *et al.*, 1968). At this stage of reading the films, nothing was known of the diver's history. Although he had done some "dry" dives, he had been exposed to pressure changes mainly at high altitudes. A needle biopsy was carried out and the lesion proved to be an enchondroma.

Since completing the 1967–1969 survey we have continued X-raying a similar sample of RN divers annually. An extract of the results, shown in Table I, reflects the development of a lesion in serial observation. The recorded change is based not on radiological interpretation but on the appearance of the lesion itself. In 1967, Case 46 had, it was thought, a possible lesion in the left lower femur; by 1971 there were positive

FIG. 4. A-P and lateral views of lesions in distal femora.

Table I. PROGRESSION OF LESIONS IN TWO CASES TAKEN FROM RN OSTEONECROSIS SURVEY

Case no.	Year of X-ray	X-ray classification	Humerus (head and shaft) R	Humerus (head and shaft) L	Femur (upper) R	Femur (upper) L	Femur (lower) R	Femur (lower) L	Tibia (upper) R	Tibia (upper) L
46	1967	–	–	–	–	–	–	?	–	–
46A	1971	+	–	–	–	–	B2	B2	–	–
105	1967	?	–	–	–	–	?B2	–	–	?B2
105A	1971	+	–	–	–	–	B2	?B2	–	B2

lesions in both lower femurs. In the interim the subject had been in the United States doing extensive diving in the SeaLab program. The U.S. Navy kindly sent us films taken in 1970 and 1971, in which a slight progression was evident between the two dates.

In Case 105, the survey similarly revealed two doubtful lesions in 1967 that, by 1971, had extended and were considered positive. The management of a doubtful case detected in our survey is different from that of a positive case. In our records, the notation *doubtful lesion* indicates that the existence of a lesion is uncertain and serial observation is necessary for a definitive

FIG. 5. Lesion in fibula of diver, originally thought to be B2 lesion, but shown on biopsy to be enchondroma.

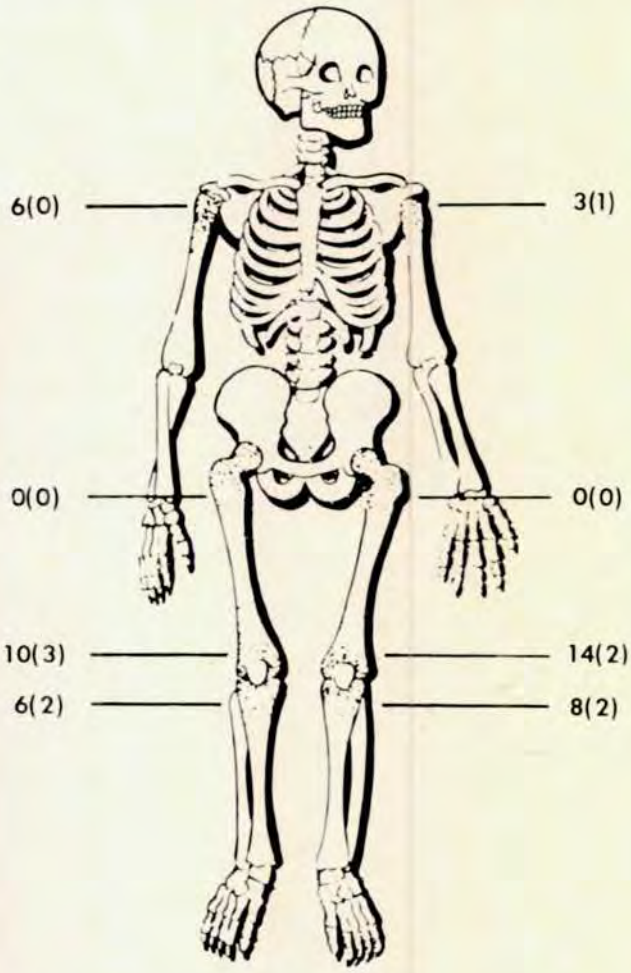

FIG. 6. Final determination (31 December 1971) of distribution of osteonecrosis lesions found in 19 positive cases among 383 clearance divers in 1967-1969 Royal Navy survey: 47 positive lesions and 10 doubtful ones (latter noted in parentheses).

diagnosis. This procedure is probably far more relevant in surveys of civilian divers than in the closed community of naval divers. In either group, a doubtful case needs closer surveillance than a single doubtful lesion.

Since the RN survey was completed (in 1969), three additional cases of osteonecrosis have developed in the sample, bringing the total of positive cases to 19. The distribution of lesions is shown in Fig. 6. In our early reading of the films some doubtful lesions were found in the hips in several divers, rather like those that Dr. Fagan has illustrated in this Symposium. But it is now our opinion that the lucent areas near the capsule attachment are not caused by aseptic bone necrosis. In some cases several positive lesions are evident; multiple lesions help greatly in making a definitive diagnosis in a particular case.

In Fig. 7 is shown the distribution of lesions in the cases still considered doubtful at the conclusion of the survey. It may be that the shoulder lesions are both difficult to detect and less common in divers.

The radiological classification set out in the beginning of this paper is the one that we should like to see adopted for all X-ray surveys, both of caisson workers and divers. A radiologist might find this classification quite difficult to apply in individual cases and to particular lesions. It may be impossible to classify precisely a mixed lesion as being A1 or A2. But an accurate analysis of the very minor change in the trabecular structure in an attempt at classification does help in detecting the early lesions of osteonecrosis.

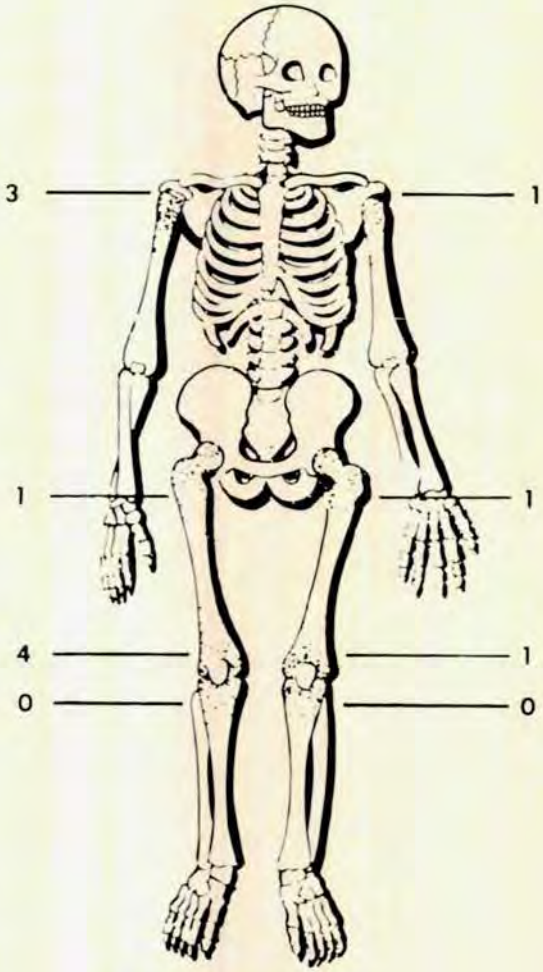

FIG. 7. Final determination (31 December 1971) of distribution of suspected lesions in seven doubtful cases among 383 clearance divers in 1967-1969 Royal Navy survey.

REFERENCES

Allan, J. H. (1943). Decompression disease of bone. J. Aviation Med. 14, 105.

Asahi, S., Ohiwa, H., and Nashimoto, I. (1968). Avascular bone necrosis in Japanese diving fishermen. Bull. Tokyo Med. Dental Univ. 15, 247-257.

Blank, N., and Lieber, A. (1965). The significance of growing bone islands. Radiology 85, 508.

Bucky, N. L. (1959). Bone infarction. Brit. J. Radiol. 32, 22.

Davidson, J. K. (1964). Radiology in decompression sickness in the Clyde Tunnel. Scot. Med. J. 9, 1.

Davidson, J. K., and Griffiths, P. D. (1970). Caisson disease of bone. X-ray Focus 10, 2-11.

Edeiken, J., Hodes, P. J., Libshitz, H. I., and Weller, M. H. (1967). Bone ischemia. Radiol. Clin. N. Amer. 5 (3), 515-529.

Elliott, D. H., and Harrison, J. A. B. (1970). Bone necrosis — An occupational hazard of diving. J. Roy. Naval Med. Serv. 56, 140-161.

Golding, F. C. (1962). The shoulder — The forgotten joint. Brit. J. Radiol. 35, 149-158.

Golding, F. C. (1966). Radiology and orthopaedic surgery. J. Bone Joint Surg. 48-B, 320.

Golding, F. C., Griffiths, P., Hempleman, H. V., Paton, W. D. M., and Walder, D. N. (1960). Decompression sickness during construction of Dartford Tunnel. Brit. J. Ind. Med. 17, 167.

Harrison, J. A. B. (1971). Aseptic bone necrosis in naval clearance divers: Radiographic findings. Proc. Roy. Soc. Med. 64, 1276-1278.

Jaffe, H. L. (1969). Ischemic necrosis of bone. Med. Radiogr. Phot. (Kodak) 45, 58.

Kahlstrom, S. C., Burton, C. C., and Phemister, D. B. (1939). Aseptic necrosis of bone. Surg. Gynec. Obstet. 68, 129.

Kim, S. K., and Barry, W. F., Jr. (1968). Bone islands. Radiology 90, 77-78.

McCallum, R. I. (1968). Decompression sickness: A review. Brit. J. Ind. Med. 25, 4.

McCallum, R. I., Walder, D. N., Barnes, R., Catto, M. E., Davidson, J. K., Fryer, D. I., Golding, F. C., and Paton, W. D. M. (1966). Bone lesions in compressed air workers. J. Bone Joint Surg. 48-B, 207-235.

Matsunaga, H., and Shigeto, O. (1967). Divers in Japan and their bone islands. Special Service for Industrial Injuries Reports.

Nagai, S., and Ibata, H. (1965). X-ray study of aseptic bone necrosis resulting from decompression sickness. Naval Scientific and Technical Information Centre 26753 (1970), Transl. 2140, Ministry of Defence, UK. Unclassified.

Ngan, H. (1972). Growing bone islands. Clin. Radiol. 23, 199.

Poppel, M. H., and Robinson, W. T. (1956). Roentgen manifestations of caisson disease. Amer. J. Roentgenol., Radium Therapy Nucl. Med. 76, 74.

Walder, D. N. (1970). Caisson disease of bone in Great Britain. In Proceedings of the Fourth International Congress on Hyperbaric Medicine, Japan. pp. 83-88. Baltimore: Williams & Wilkins.

DISCUSSION 6

Dr. ELLIOTT: I should like to add two relevant points. Although the Royal Navy still takes these X-rays annually, we have considered reducing the frequency to once every two or three years for men who perform only normal diving and are considered to have a very low incidence of bone necrosis. But when a diver who spends most of his time working within the safe limits of the table is then exposed to an unusual hazard, because of decompression sickness or experimental diving, he would then fall into another category in which annual films become essential.

The second point, on which insufficient emphasis was laid, is the great care with which Surgeon Captain Harrison and his colleagues have read these X-ray films. They were first read independently by two radiologists experienced in this condition and the results compared. The two then met to review any films on which there was disagreement. This procedure led to much firmer diagnoses. Thus the referral of films to a center of radiological expertise is another important feature of such surveys.

Dr. EVANS: I should like to comment on Dr. Elliott's remarks about the frequency of X-ray examinations. Dr. Philip Griffiths (Decompression Sickness Central Registry) asked me to commend to this meeting the practice of having X-ray examinations of the joints of those men who are particularly at risk made at six-month intervals rather than only once annually. By men at risk he no doubt meant experimental divers and people working in high-pressure air.

Dr. MILES: I should like to emphasize a point that Prof. Walder has made. When one sees lesions of A2, A3, A4, and B2 dimensions, the lesions have usually been present a long while and most of the femoral or humeral head has already been replaced. Structural failure, as has been demonstrated, comes at the point where the joint surfaces can no longer take the stresses applied to them. Radiologic findings at this time do not demonstrate the amount of necrosis present years previously.

Dr. WALDER: As presented by Dr. Harrison (pp. 151-152, this volume), there are essentially two types of pathological changes in osteonecrosis:

A The so-called juxta-articular lesions, which are within reach of the articular surface of a bone and are therefore potentially disabling; and

B Lesions of the head, neck, and shaft of a bone, which never cause disability.

Insofar as is presently known, it is a matter of chance whether or not an *A* lesion proceeds to disable a man.

In Fig. 1 through 8 are illustrated the various types of osteonecrosis lesions, as classified by the MRC Decompression Sickness Council. [These illustrations, reproduced through the courtesy of the University of Newcastle upon Tyne, are important for two reasons. First, they are selected from the MRC files and hence are official. Second, they concern compressed-air workers rather than divers, such as the sample in Dr. Harrison's survey. —Eds.]

Dr. McCALLUM: Credit must be given to Dr. Griffiths because, to my knowledge, he was the first to spot endosteal thickening next to a necrosis lesion (Fig. 7).

Dr. MILES: I find that a major problem in orthopedics is that one set of terms is used in the radiology department, a second set in the clinic, and a third one in the pathology department. An example of beautifully descriptive orthopedic terminology is the "soap-bubble" appearance of giant-cell tumors and other benign lesions. But I have yet to hear a pathologist speak

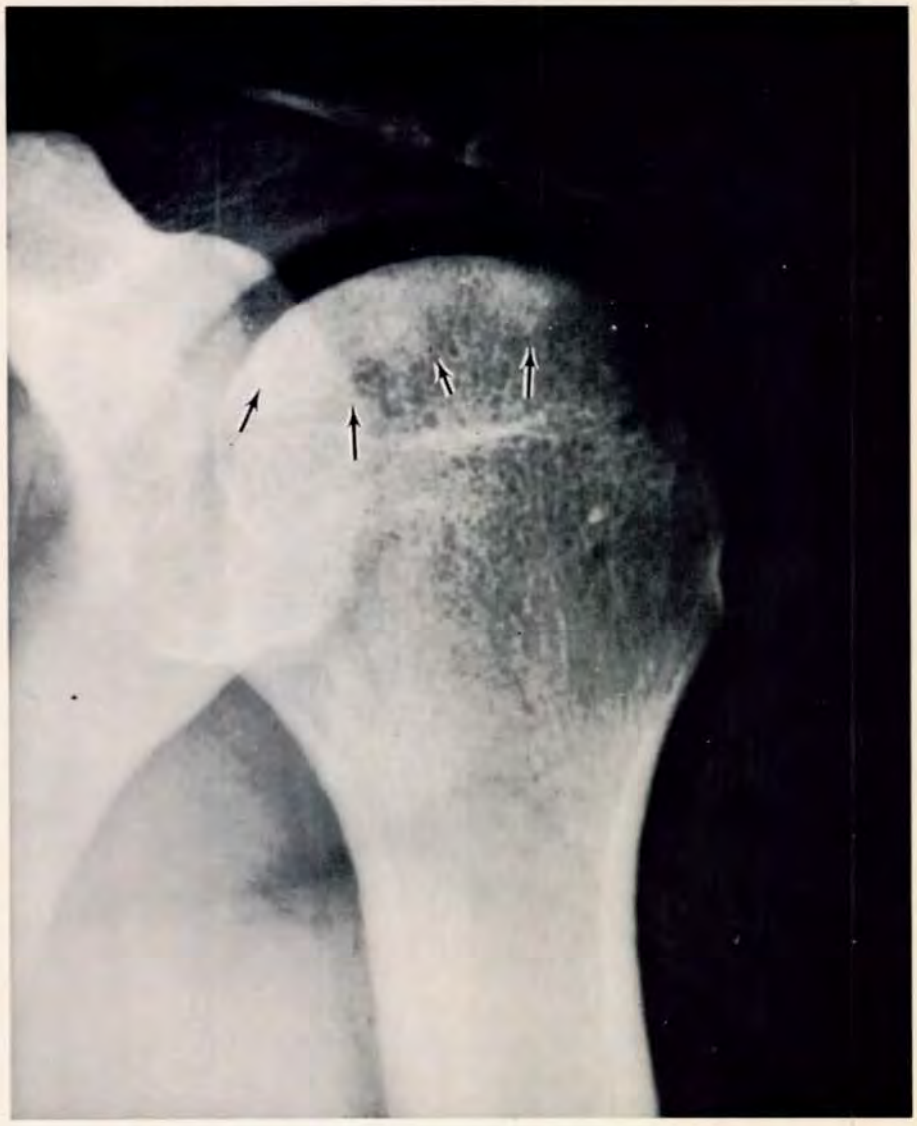

FIG. 1. A1 lesions: *dense areas,* with intact articular cortex. At the top of the humerus are two areas where the trabecular pattern is blurred. The edge of the cortex looks "woolly." These changes represent what I believe Dr. Miles refers to as a *wedge infarct.*

of "soap bubbles" in bone! Another example is a "snowcap" lesion on the humeral head, a term I suspect a pathologist would not use. We have to choose our words carefully so that they have meaning in all of these departments.

I should like to discuss Prof. Walder's X-rays. In his book on bone pathology, Jaffe (1958) says that there are four things the roentgenogram reveals about a lesion. First, where it is with regard to the entire structure of the bone — *i.e.*, is it endosteal, medullary, or periosteal; or is it in the epiphyseal

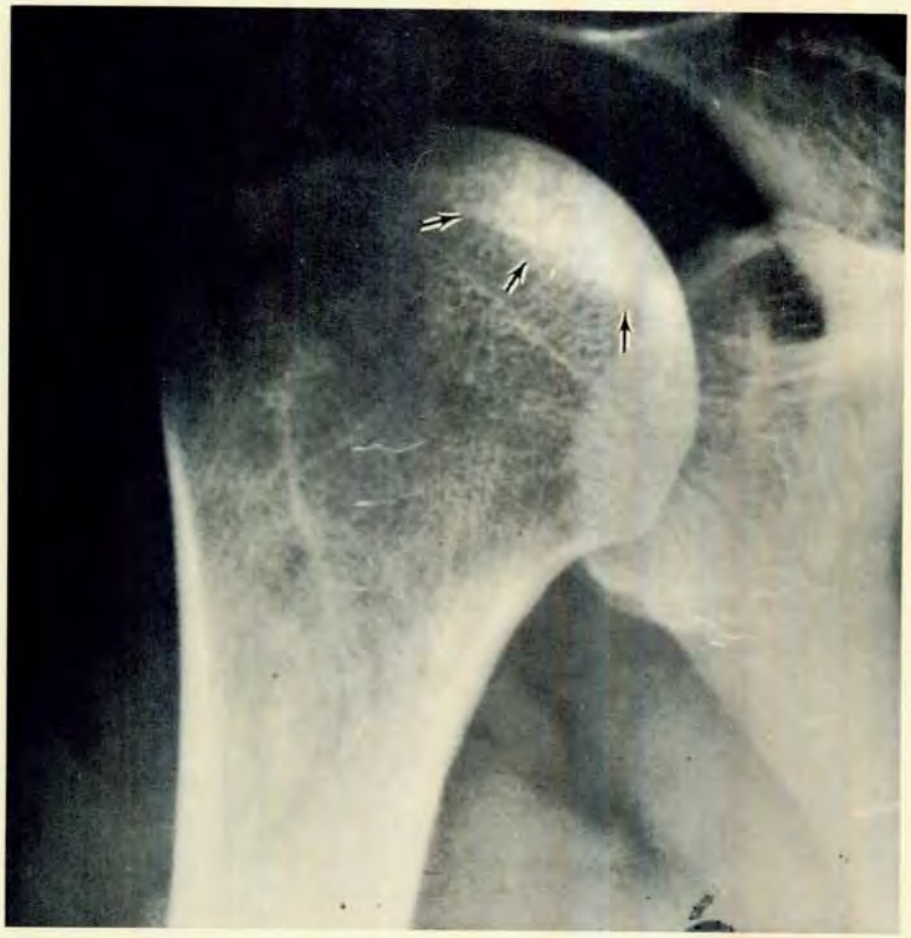

FIG. 2. A2 lesion: *spherical segmental opacity*. Originally called a *snowcap lesion*, it may remain symptomless.

ossification center, the metaphysis, or the diaphysis — and, of course, is it single or multiple? Second, what is the lesion doing to the host? Third, how is the host reacting to it? Fourth, what is its relative density?

To expound on these observations, I would say that the lesions in Fig. 2 are in the epiphyseal ossification center and are multiple. What has the lesion done to the host? The trabecula in the epiphyseal ossification center and the metaphyseal region has been destroyed in the area of the lesions. What is the host's reaction? It appears to be making a large amount of new bone.

Figure 3 shows a lesion of tremendous reaction. I would assume that this is a fairly early lesion; ultimately it may well progress to a fracture, as seen in Fig. 4*a*. The reactive bone in Fig. 4*b* has surrounded the area of dead bone, creating three sides of a rectangle; the cortex over the area of dead bone has remained unchanged. This represents the host bone's attempt to wall off the dead bone.

If the osteonecrotic process continues, particularly if trauma is associated

FIG. 3. A3 lesion: *linear opacity*. The dense line marked with arrows represents the lesion. The extremities of such linear opacities characteristically extend to the cortical margin.

with it, the state shown in Fig. 4*a* is reached. Note the area of sequestration and the crescent sign. That will become a pathologic fracture, which frequently occurs at the junction between living and dead bone, through the zone of replacement. But pathologic fracture may also occur through necrotic bone itself, as is well illustrated in Fig. 4*b*. At the superior portion (where one sees the depression in the articular cortex) the fracture is, I think, quite obviously at the junction between the zones of replacement and total necrosis. The snowcapped area to the left, over the dome of the humeral head, is obviously necrotic bone. I am sure Prof. Walder would agree that the areas of the greater and lesser tuberosities were necrotic and have been replaced, and that this advancing replacement has progressed almost to the area of the pathologic fracture.

I would describe the lesion in Fig. 4*c* as having begun within the epiphy-

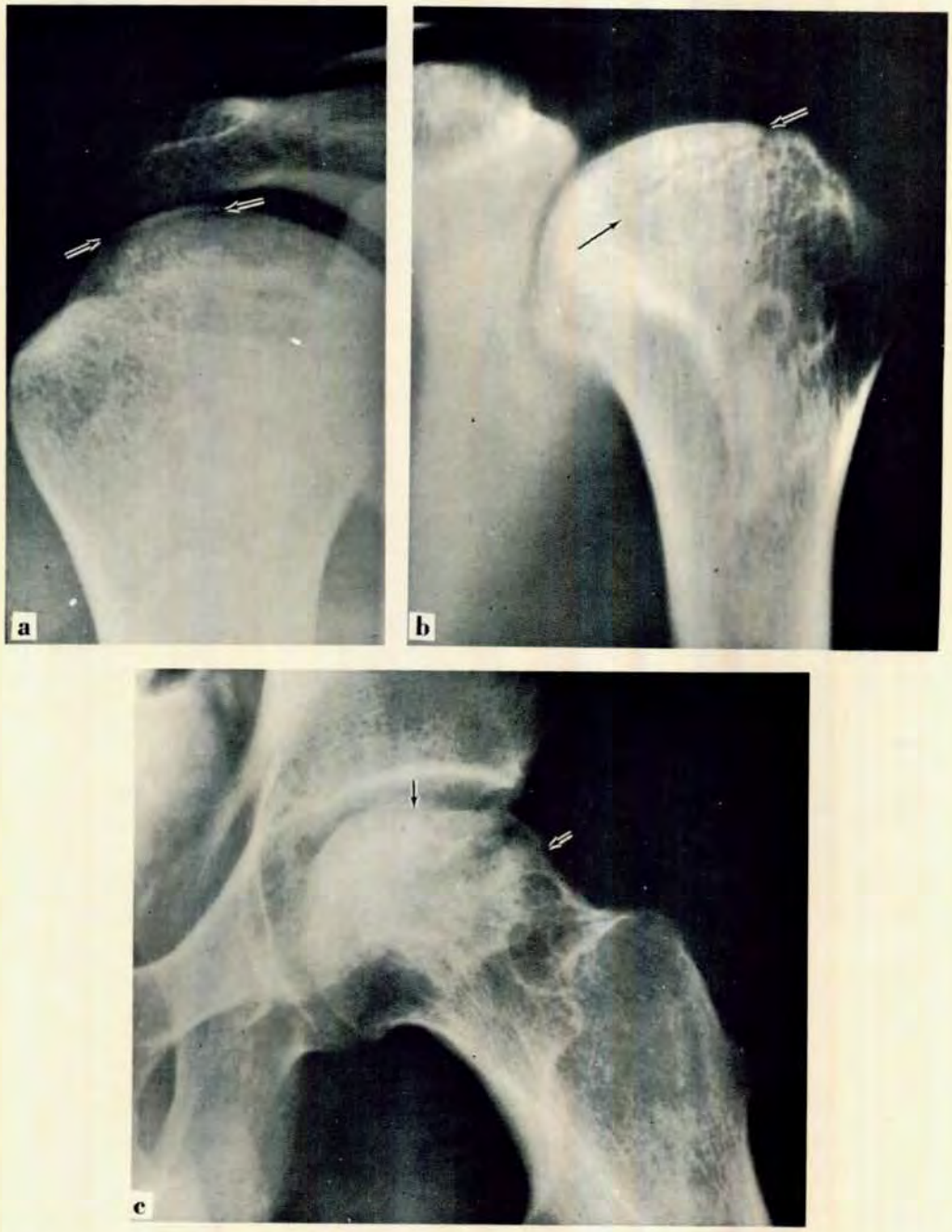

FIG. 4. A4 lesion: *structural failures.* (*a*) *Translucent subcortical band.* This lesion (between arrows) is sometimes called a *crescent sign.* Situated just under the articular cortical surface, the translucent line indicates that a sliver of the cortical surface is about to detach. (*b*) *Collapse of the articular cortex* or *subchondral depression.* Tomogram shows a fracture line (arrows) developing between the sclerotic part of the bone above, which is being depressed into the humeral head, and surrounding bone cortex. (*c*) *Sequestration of the cortex.* A loose piece of dead articular cortex has been pushed into the body of the femoral head, causing the latter to appear flattened (arrows).

FIG. 5. A5 lesion: *osteoarthritis.* This condition can supervene on any lesion in which disruption of the articular surface has occurred. In osteonecrosis the cartilage often remains viable, so that a joint space of reasonable size often continues to be radiologically visible despite signs of severe osteoarthritis. It is my observation that the cartilage seems to persist even longer in caisson disease than in similar orthopedic conditions.

seal ossification center, within the metaphysis of the femur. There is a vast amount of necrosis and an excellent demonstration of replacement, which has proceeded from a more distal site proximally toward the acetabulum. As a result of walking and other stresses, a fragment has broken off, producing an osteochondritis dissecans. The cartilage space remains intact, and will for years, as in the case of a completely necrotic femoral head proximal to an area of femoral-neck fracture.

When the fracture has united and the head is replaced, and this replacement has proceeded proximally to the articular cortex, the problem of what has happened to the articular cartilage arises. If the articular cartilage continues to receive nutrition from synovial fluid, it remains viable. The cartilage space will remain intact and the result good. The articular cartilage is dependent upon the synovial fluid and survives because of that. On the other hand, if the articular cartilage is dependent upon subjacent capillary loops — which penetrate the articular cortex up to the zone of provisional calcification — the cartilage will be replaced after the head is replaced. The

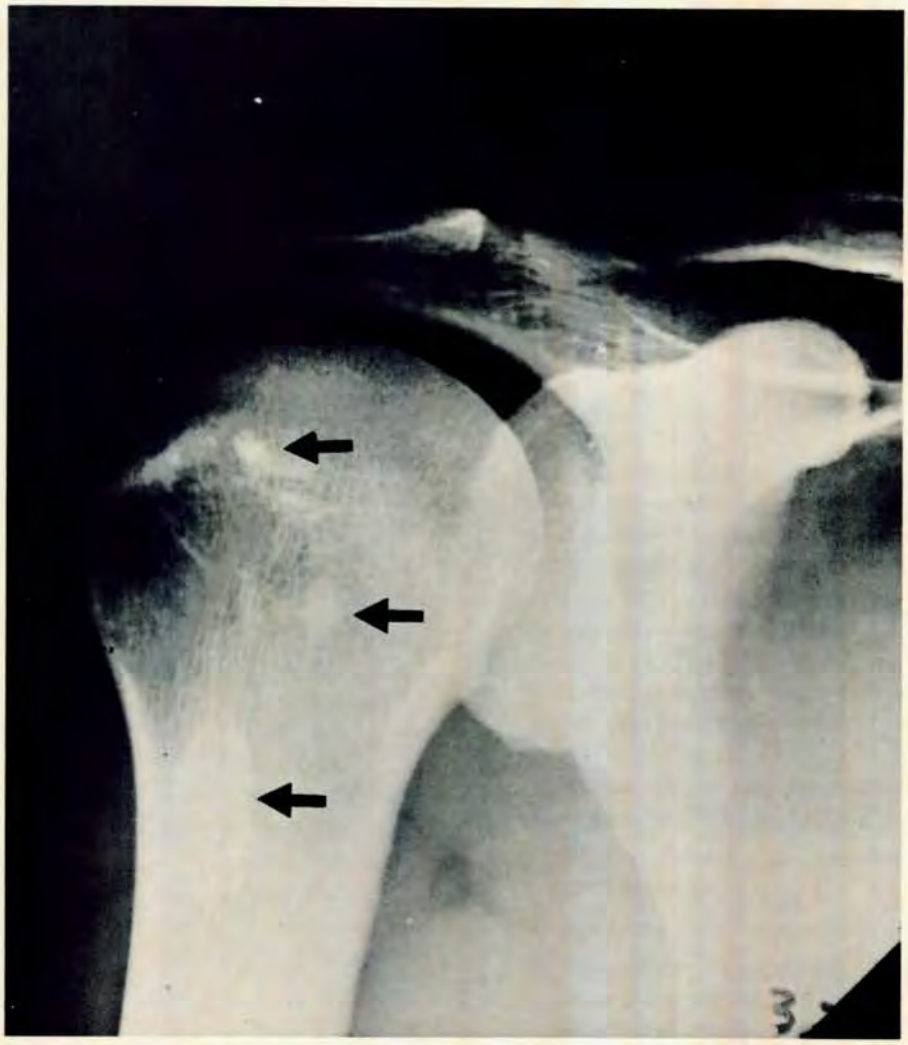

FIG. 6. B1: *dense areas*. These areas can be seen just at and below the junction of the humeral head and shaft. They are typical of the osteonecrotic lesions seen in such sites, and it is unlikely that they will ever cause disability.

end result is the severe osteoarthritis and great degenerative change of the A5 category demonstrated in Fig. 5.

It is perhaps not fair to discuss someone else's slides, but I think it extremely important to make our terminology mutually understandable among the many disciplines of a hospital.

Dr. WALDER: I am delighted that Prof. Miles is in general agreement with what I have said; it suggests that the MRC Decompression Sickness Panel's classification is a workable one. We would all benefit from the use of a single agreed classification.

Dr. HARRISON: We should make it quite clear that the X-ray films shown in this discussion are those of caisson workers, not divers. The lesions

FIG. 7. B2: *irregular calcified areas.* This condition is commonly seen in divers. Sometimes the appearance is that of rather foamy areas in the medulla at the lower end of the femur, often with a calcified margin. Similar lesions are often found at the upper end of the tibia. Sometimes femoral lesions have a hardish scalloped edge around a translucent area. Endosteal thickening frequently accompanies these lesions.

are very much the same in both groups, except that hip lesions seem quite uncommon in divers.

FIG. 8. B3: *translucent areas and cysts.* A single cyst (arrow) is usually seen in the femoral neck. Sometimes a line of small cysts appears at the point where the hip-joint capsule attaches to the femoral neck. These irregularities may also be found at the junction of the shoulder-joint capsule and humeral neck. Dr. Campbell Golding believes that these multiple lesions are not osteonecrotic, but, rather, that they relate to past damage at the point of a capsule's insertion into the neck of a bone.

Dr. MILES: As an orthopedist, I should like to make a distinction between impairment and disability. We can measure impairment of function quantitatively — *e.g.*, loss of joint motion and shortness and atrophy of muscles. Disability, on the other hand, relates to job performance, a parameter that physicians have great difficulty in measuring. For example, a violinist with a stiff fifth finger on his left hand is totally disabled, but an elevator operator is not. One is also reminded that a man with no muscles in his legs became president of the United States four times. I submit that that is a measure of the ability rather than the disability of a man.

Mr. GALERNE: Why do you make a distinction between caisson workers and divers?

Dr. ELLIOTT: There is a real difference in bends threshold between the two groups and in the decompression tables used. This may be because there are distinct differences in the type of work that they do and the pressure exposures that they undergo. The distinction may seem artificial, but it is practical.

Dr. MILES: I rather shudder at the tendency to attach names to pathological findings and then forget about them as though the problem were

solved. I, for one, do not know what a bone island is; the term has no pathologic meaning. I would prefer to call it something else, but I do not know what.

Dr. HARRISON: An alternative description would be "a compact area of cortical bone surrounded by normal cancellous bone." "Bone island" does seem a bit shorter!

REFERENCE

Jaffe, H. L. (1958). Tumors and Tumorous Conditions of Bone. New York: McGraw-Hill.

BONE SCANS WITH FLUORINE-18 IN DIAGNOSING OSTEONECROSIS IN DIVERS

RALPH J. GORTEN
ROBERT N. COOLEY

Radionuclide scans are frequently requested clinical procedures because they provide, easily and nontraumatically, information about focal areas of disease in various internal organs. Scans of the skeletal system have achieved clinical acceptance because they demonstrate with considerable sensitivity the presence of primary or metastatic tumors. Considerable interest has developed recently at the University of Texas Medical Branch (UTMB) and its Marine Biomedical Institute in evaluating the sensitivity of bone scans as an additional tool to radiography in the diagnosis of osteonecrosis. Accordingly, some of the Gulf of Mexico divers radiographed by the UTMB for osteonecrosis were also submitted to radionuclide bone-scan surveys.

This type of investigation is possible because of the commercial availability of salts of fluorine-18 (^{18}F), which are safe for human use. This bone-seeking radionuclide has several advantages over the previously used salts of strontium-85 (^{85}Sr). The most significant of them is a markedly reduced radiation dose per millicurie (mCi) to the bone, bone marrow, and total body. In this country, bone scans with ^{85}Sr are permitted only in patients with diagnosed malignancies in whom a search for metastases is warranted. With ^{18}F, on the other hand, it is possible to study with safety a variety of benign disease processes, including osteonecrosis.

The radionuclide used in the UTMB studies was purchased as sterile, pyrogen-free sodium fluoride from Medi-Physics, Inc., in California, where it is produced in a cyclotron by deuteron bombardment of neon (Harper *et al.*, 1971).

The bone-crystal structure shown in simplified form in Fig. 1 demonstrates the mechanism by which radiochemicals can be used as tracers in studies of bone metabolism (Neuman and Neuman, 1958). It is possible to substitute radioactive calcium for the stable calcium normally deposited in bone, but none of the calcium isotopes is suitable for scanning purposes. Therefore, ^{85}Sr and strontium-87m (^{87m}Sr), which follow pathways similar to those of calcium, have been widely used as scan agents (Charkes, 1970; DeNardo *et al.*, 1972).

Fluoride ions, on the other hand, can be exchanged with the hydroxyl ions in bone crystal, as shown in Fig. 1. The process goes through various stages (Neuman and Neuman, 1958). In only a few seconds or minutes, fluoride ions pass from plasma through extracellular fluid to the hydration shell surrounding bone crystal. Rate of transit is limited mainly by the blood supply to a particular portion of a bone. The next step — passage of the ions through the hydration shell to the crystal surface — takes several hours, and actual incorporation into the interior of bone crystal takes days or weeks. But

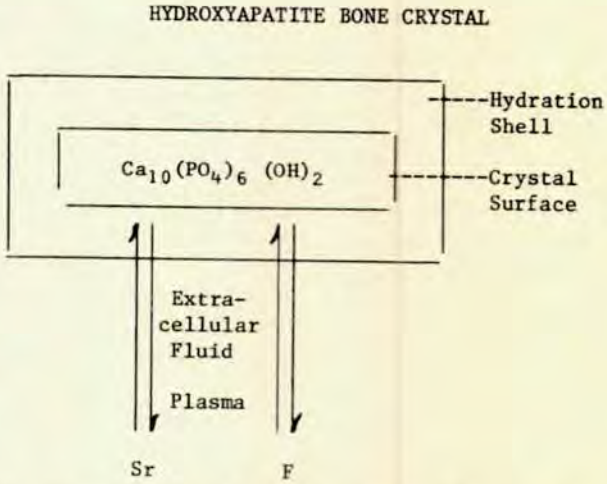

FIG. 1. Simplified schematic of hydroxyapatite crystals, which are deposited in osteoid tissue by proliferating osteoblasts. Arrows show pathways of exchange for the most common bone-seeking chemicals, strontium and fluoride, used for radionuclide scanning.

Preceding page blank

once the fluoride ions reach the hydration shell, they are sufficiently localized in bone for scanning purposes. At this point, therefore, the distribution of radioactive ^{18}F demonstrates the areas of increased bone metabolism (Blau *et al.*, 1972).

Certain areas in a scan may appear to have greater radioactivity concentration than others, a circumstance thought to be caused either by increased blood supply to that region and/or by increased bone-crystal exposure (Blau *et al.*, 1972; French and McCready, 1967). The latter may be the result of osteoblastic or osteolytic activity in a certain portion of a bone. Osteolytic activity is thought to increase activity in the adjacent bone, and therefore both osteoblastic and osteolytic lesions are demonstrated on a bone scan as areas of increased radioactivity (Blau *et al.*, 1972).

To choose the optimum time to start scanning, one must remember that the uptake of ^{18}F in bone is very rapid, reaching almost maximum within one hour (Blau *et al.*, 1972). On the other hand, only 50% (approximately) of the fluoride becomes concentrated in the skeletal system; the remainder, at this early stage, is still primarily in the blood, which means that some time must be allowed for the blood concentration to be reduced via urinary excretion. This decrease occurs much more rapidly with fluorine than with strontium (Blau *et al.*, 1972). Thus, in addition to the short physical half-life (110 minutes), which permits larger tracer doses, the major advantages of fluorine are its rapid deposition in bone and its rapid clearance from the blood by the kidneys. Compared with the strontium isotopes, fluorine provides much better contrast between focal bone disease and vascular tissues.

The bone-seeking radionuclides used frequently for imaging purposes are compared in Table I. An advantage of ^{85}Sr is its physical half-life of 65 days, making it feasible to purchase the tracer commercially well in advance of intended use. However, the long half-life is also a major disadvantage because it involves protracted radiation exposure to the skeletal system. Since this exposure is significant, ^{85}Sr dosage is generally limited to 0.1 mCi and its use restricted in this country to adult patients with known malignancy (Charkes, 1970). Given the small radioactive dose, the external count rate is understandably low compared with most other modern scan techniques, necessitating rather slow scan speeds and lengthy patient studies. The energy level is somewhat higher than is desirable for imaging, but it is acceptable for rectilinear scanning with properly selected collimators. Strontium's slow blood clearance makes it advisable to wait three to seven days between administration of tracer and performance of the scans. Yet another disadvantage of strontium is that much of it is excreted into the intestinal tract. For examination of the pelvic and lumbosacral region, therefore, the patient must undergo thorough bowel cleansing.

Strontium-87m has a shorter half-life than strontium-85 and can therefore be given in larger

Table I. COMPARISON OF FREQUENTLY USED BONE-SEEKING RADIONUCLIDES

	^{85}Sr	^{87m}Sr	^{18}F	^{99m}Tc
Source	Reactor	^{87}Y generator	Cyclotron reactor	^{99}Mo generator
Chemical form	$SrNo_3$	$SrHCO_3$	NaF	Tc poly-phosphate
Half-life (physical)	65 days	2.8 hr	1.85 hr	6 hr
Photon energy (kev)	513	388	511	140
Dose (mCi)	0.1	4	4	10
Bone localization	30%	30%	50%	40%
Delay	5 days	1 hr	2 hr	4 hr
Preparation	bowel, void	—	void	void
Maximum CPM	2K	—	40K	20K
Radiation dose — bone	3.6r	0.6r	0.6r	0.4r
Radiation dose — marrow	1.1r	0.6r	0.6r	0.1r
Radion dose — body	0.4r	0.2r	0.1r	—

doses — up to 4.0 mCi. Count rates, scan speeds, and radiation exposure to the bone, marrow, and body are within acceptable limits. But its clearance from the blood is very slow, making it more difficult to distinguish focal bone lesions from normal or abnormal vascular regions with elevated count rates (Charkes *et al.*, 1964).

Fluorine-18 overcomes most of these disadvantages. It has a physical half-life of less than two hours, making the radiation exposure quite acceptable for doses in the range of 4.0 mCi. The count rates permit rapid scan speeds. Acceptable scan views can be obtained in a matter of minutes rather than hours. Because excretion is via the urine, the bladder and sometimes the kidneys appear in bone scans. Consequently, a small portion of the pelvis cannot be evaluated completely for focal bone disease.

The value of ^{18}F scans in detecting skeletal abnormalities has been studied mainly in patients with malignant tumors. Scans proved to be in agreement with radiographic findings, or were more sensitive in detecting bony metastases, especially in early stages of disease (Blau *et al.*, 1972). Aseptic necrosis is included in the list of nonmalignant focal bone diseases that may reveal scan abnormalities (O'Mara and Baker, 1973). Little is known about the relationship between stages of development in osteonecrosis and recognizable accumulations of bone-scan tracers. If one were willing to extrapolate what has been described or is known about the mechanisms of scan abnormalities in bone tumors, one would expect that only the more active stages of necrosis would be associated with significant scan findings. This problem deserves further study.

The observations made during the early phase of the UTMB osteonecrosis project involved rapid total-body survey scans and selected regional scans on seven professional divers. The findings in these surveys were compared with roentgenograms made of the same divers, which were interpreted by Dr. Charles Fagan, M.D., and are reported on p. 177 *ff.* of this volume. The scans of two of these subjects will be discussed.

Figure 2*a* shows anterior and posterior total-body scans of one diver. Certain normal areas of fluoride deposition are visible on the anterior view in the skull and facial bones, sternum and sternoclavicular joints, shoulders, bladder, pelvis, and hip joints. On the posterior view, the vertebral column is more easily recognizable, as are the scapulae, rib cage, sacroiliac and hip joints, and, to a lesser extent, the knee joints. A definite abnormal finding is the marked asymmetry of radioactive fluoride concentration in the shoulders; there is much more in the right than in the left. The difference in the pelvic region is more subtle; somewhat more tracer has accumulated in the right ilium and/or the right femoral head than in the contralateral location. The difference, which is more recognizable on the anterior view than on the posterior, is subtle but significant.

X-ray films of this diver revealed evidence of osteonecrosis as manifested by a collapse of the articular cortex and sclerotic and lucent modeling of the right humeral head. There is an associated and complicating osteoarthritis with spur formation (Fig. 2*b*). In location this corresponds to the scan abnormality. A subtle abnormality in the left humeral head seen in the X-ray was not revealed by scanning. X-rays of the hips (Fig. 2*c*) reveal no abnormality.

In the second diver, the difference between the two shoulders in the scan findings is more subtle (Fig. 3*a*). There is slightly more tracer in the right shoulder than in the left. The concentration on the right is not necessarily darker than on the left, but the medium gray area is larger. This difference is so subtle that it was originally interpreted as being within normal limits. The interpretation was made prior to inspection of the roentgenograms. Nothing else on the scans looks asymmetrical or suggests other possible abnormality. But both shoulders of this subject appear abnormal on X-ray, the right much more so than the left (Fig. 3*b*). Radiographs of the hips reveal a lytic lesion in the left femoral neck (Fig. 3*c*).

Of the scans performed on the other four divers, two were normal and two abnormal. In general, correlation between X-rays and scans was similar to that of the first two divers. Wherever a scan showed an abnormality, the X-ray did as well. But several subtle abnormalities were revealed radiographically that were not detected on the bone scans.

Comparison of lesions demonstrated by radiological and scanning techniques suggests that, at this stage of our investigation, scans can detect most areas of aseptic necrosis, but not all. The radionuclide imaging procedures apparently detect early or incipient stages of osteonecrosis. As the disease progresses, however, and scar tissue has formed and blood supply decreased, the scans are less likely to show abnormality than roentgenograms.

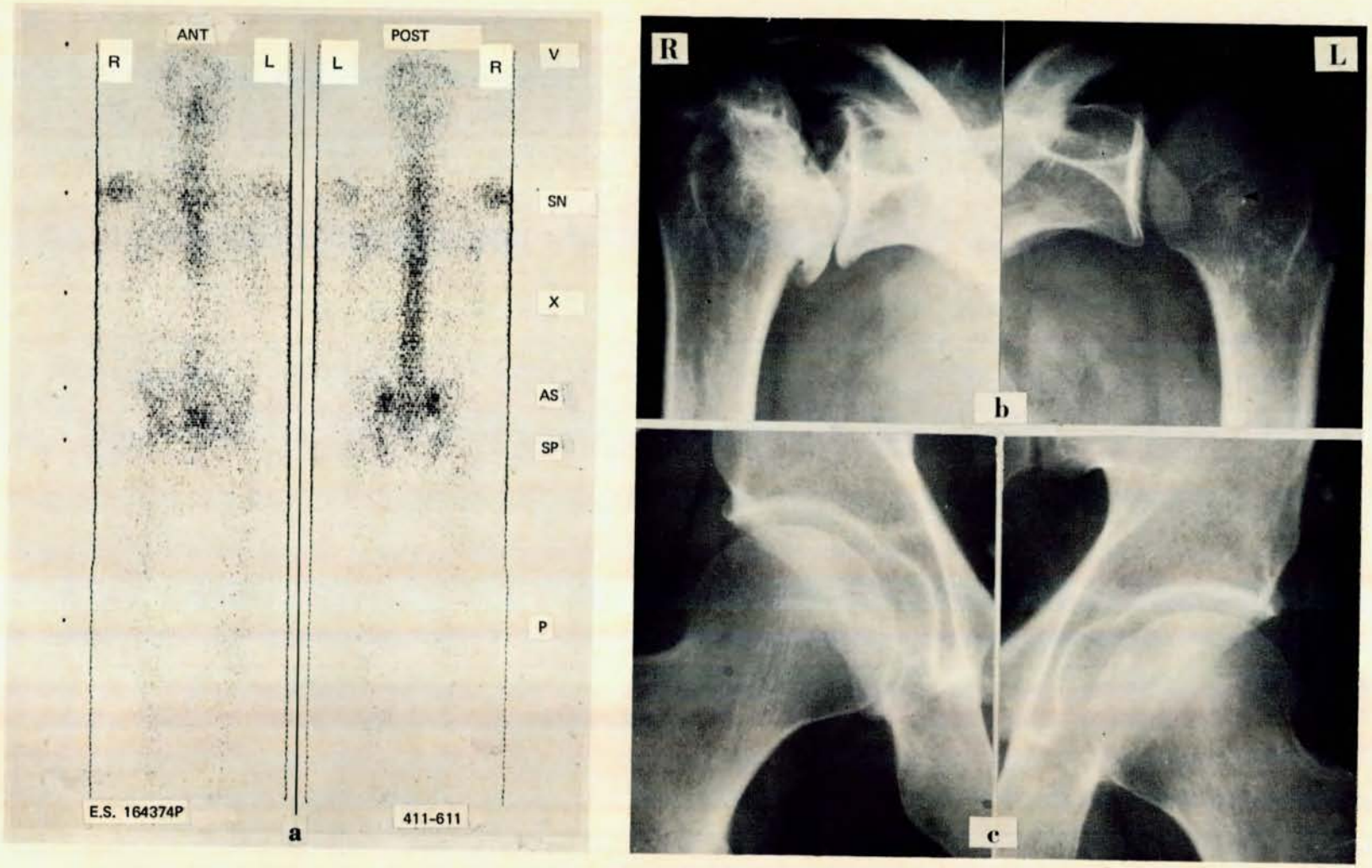

FIG. 2. (*a*) Anterior and posterior total-body survey scans of diver begun 2 hr after an intravenous dose of 2.8 miCi of $Na^{18}F$. Note abnormal areas of increased tracer concentration in R shoulder and in region of R femoral head and/or R ilium. (Abbreviations for anatomic levels: V, vertex; SN, suprasternal notch; X, xiphoid process; AS, anterosuperior iliac spine; SP, symphysis pubis; P, patella.) (*b*) Shoulder radiographs with arrow pointing to abnormally dense area in L humeral head. This area of old osteonecrosis did not appear on radionuclide scans. (*c*) Hip roentgenographs reveal no abnormalities.

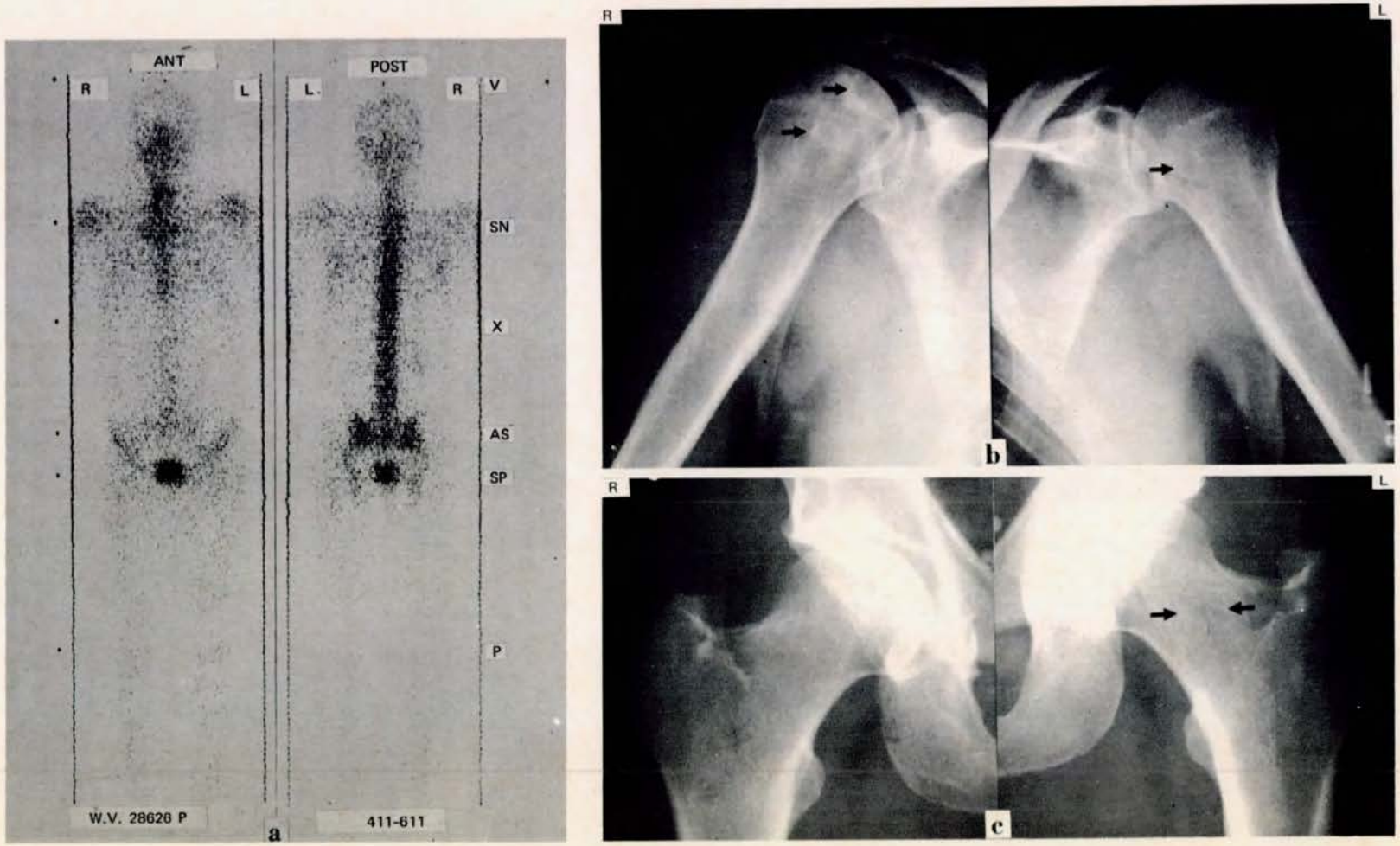

FIG. 3. (*a*) Anterior and posterior total-body survey scans of diver begun 2 hr after intravenous dose of 3.7 mCi of Na^{18}F. Note subtle difference in tracer concentration in the two shoulders. (*b*) Shoulder X-rays revealing radiodensities in R and L humeral heads (arrows). (*c*) Hip X-rays revealing radiolucent area in L femoral neck (arrows).

Scans and radiographs in combination will quite likely enable much more accurate diagnosis of the disease than when one technique alone is used. Experience with serial scans involving larger numbers of divers is required before the actual sensitivity of imaging procedures in detecting various stages of aseptic necrosis can be properly evaluated.

REFERENCES

Blau, M., Ganatra, R., and Bender, M. A. (1972). ^{18}F-fluoride for bone imaging. Seminars Nucl. Med. 2, 31-37.

Charkes, N. D. (1970). Bone scanning: Principles, technique, and interpretation. Radiol. Clin. N. Amer. 8, 259-270.

Charkes, N. D., Sklaroff, D. M., and Bierly, J. (1964). Detection of metastatic cancer to bone by scintiscanning with strontium 87-m. Amer. J. Roentgenol., Radium Therapy Nucl. Med. 91, 1121-1127.

DeNardo, G. L., Jacobson, S. J., and Raventos, A. (1972). ^{85}Sr bone scan in neoplastic disease. Seminars Nucl. Med. 2, 18-30.

French, R. J., and McCready, V. R. (1967). The use of ^{18}F for bone scanning. Brit. J. Radiol. 40, 655-661.

Harper, P. V., Lembares, N., and Krizek, H. (1971). Production of ^{18}F with deuterons on neon. J. Nucl. Med. 12, 362-363.

Neuman, W. F., and Neuman, M. W. (1958). The Chemical Dynamics of Bone Mineral. Chicago: University of Chicago Press.

O'Mara, R. E., and Baker, V. H. (1973). The use of radiography and radionuclides in metastatic skeletal disease. Appl. Radiol. 2, 17-20.

XERORADIOGRAPHY AS A TECHNIQUE FOR DIAGNOSING OSTEONECROSIS

CHARLES J. FAGAN
EDWARD L. BECKMAN

Xeroradiography is a relatively unfamiliar but not completely new method of radiological investigation. One may define xeroradiography as a technique in which photoconductors and electrostatic charges are used to record X-ray images. Selenium, although normally a good insulator, becomes a charge conductor under the action of light or ionizing radiation. Whereas a conventional X-ray plate consists of a film in a cassette, a xeroradiographic plate consists of a positively charged metal surface coated with selenium. When this plate is exposed by use of conventional X-ray equipment, the roentgen rays cause a runoff, proportional to their intensity, of the charge area on the plate that they strike. The charge plate is dusted with negatively charged powder, producing an image similar to that seen on a standard roentgenogram. The image can be preserved by transferring it to paper or by photographing it (Wolfe, 1969).

Some of the advantages reported for xeroradiography over conventional radiography are these:

1. A standard radiographic film in a cardboard holder will delineate a wire mesh of only 100 lines per inch, whereas a xeroradiograph will record a mesh of 1200 lines/inch.
2. An electrostatic phenomenon, termed the

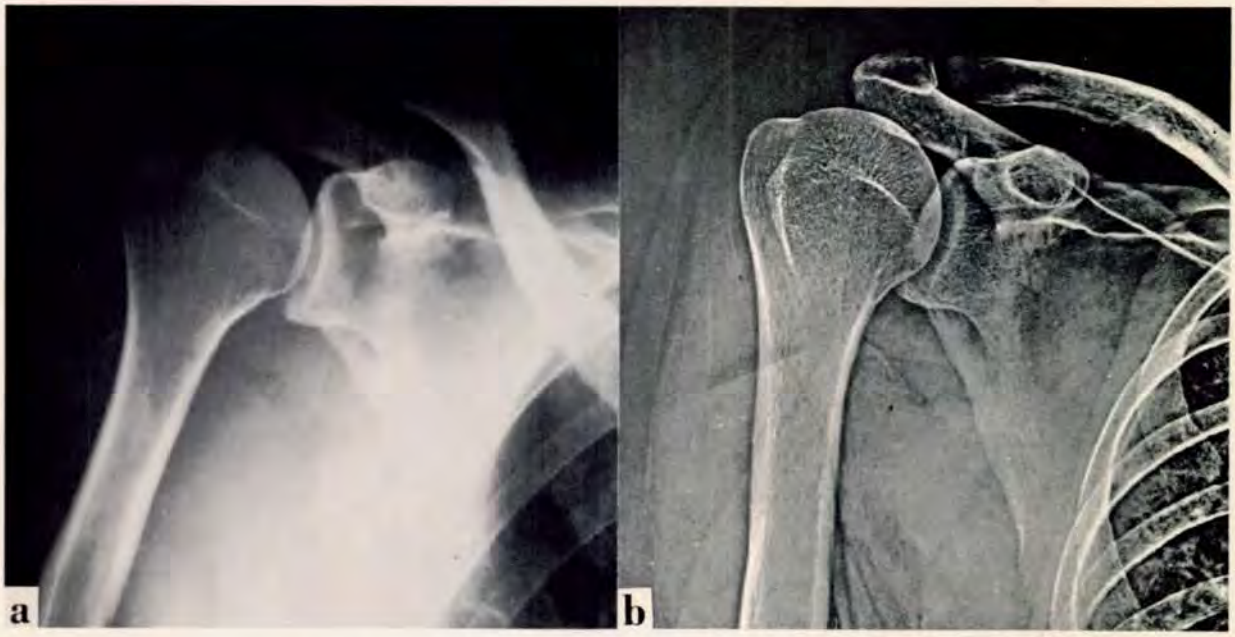

FIG. 1. Roentgenographic bone survey of a Gulf of Mexico diver, which proved negative for osteonecrosis. (*a*) Frontal projection on conventional film of L shoulder, compared with (*b*) xeroradiogram.

edge enhancement effect, accentuates borders or areas of different densities. Specifically, differences in density within a structure — *e.g.*, a fracture line in bone, the edge of a dominant mass density in the breast, or an opaque foreign body in soft tissues — are all readily recorded on the xeroradiogram (Wolfe, 1968; Woesner and Sanders, 1972).

3. Xeroradiography permits a wide range of exposure factors. For example, a range of 20 kv is possible without deterioration of the image quality. Thus precision in setting up the exposure factors is not as critical in xeroradiography as it is in conventional radiography.
4. A single roentgenogram does provide, to be sure, a wide range of bone and soft-tissue detail. By comparison, a single lateral xeroradiogram of the neck (for example) vividly demonstrates soft-tissue structures, the bony parts, and structures outlined by air. If one uses conventional radiography to obtain the same information, at least two exposures — one for soft-tissue detail and one for bony detail — would be necessary. Furthermore, the xeroradiograph is of value in some cases in eliminating the need for tomographic sections, which impart a relatively higher radiation dose to the patient than xeroradiography does.
5. The xeroradiogram is processed in a lighted room, eliminating the need for the darkroom equipment of conventional radiography.

The main disadvantages of xeroradiography are these: First, the radiation required to develop a xeroradiographic image is considerably greater

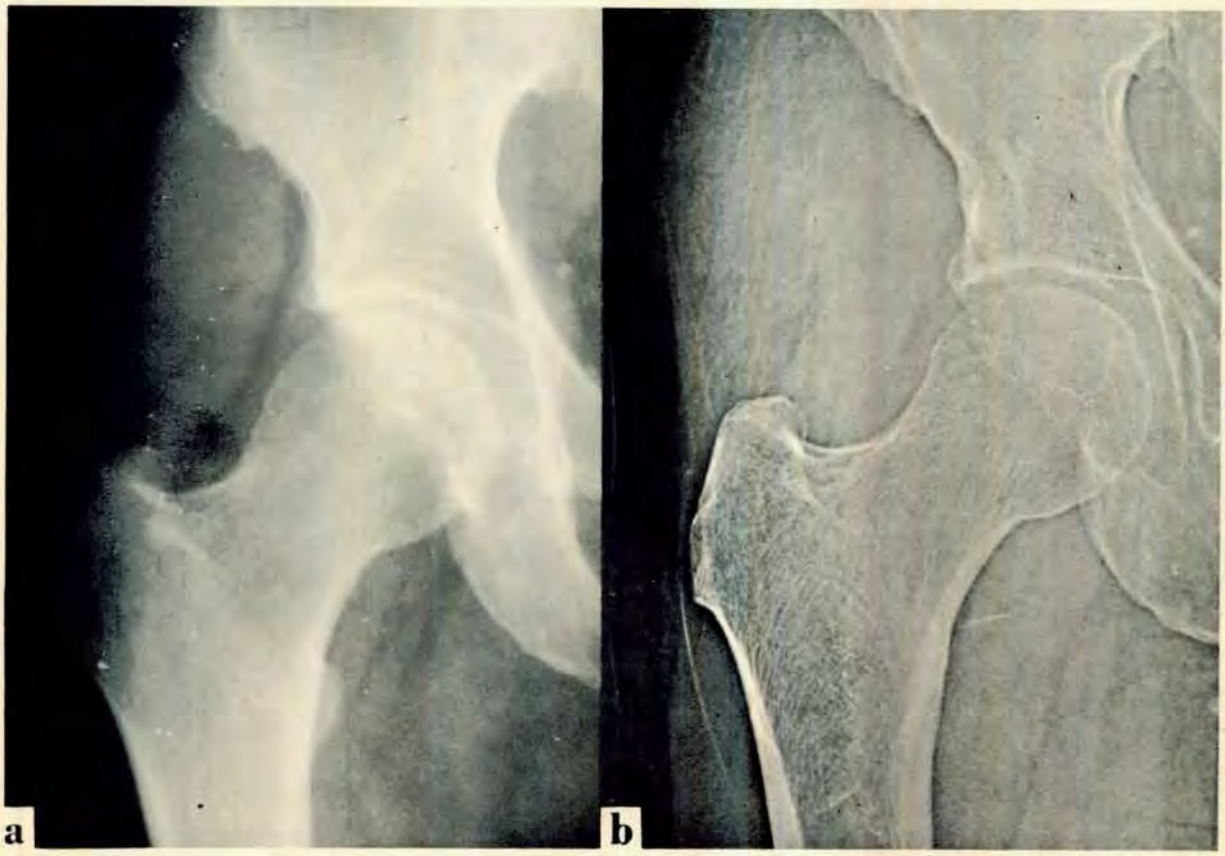

FIG. 2. Same diver as in Fig. 1. Comparison of (*a*) frontal roentgenogram of R hip with (*b*) xeroradiogram of R hip.

than that required in roentgenography with film-intensifying screens. Accordingly, an exposure of the shoulder results in a fivefold increase in radiation dosage to the patient; of the hip area, a sevenfold increase; and of the knee area, a twofold increase. Second, there are reports of low contrast and loss of fine detail in skeletal work. There is not universal agreement, however, that these objections are entirely valid (Wolfe, 1969).

In an attempt to judge the ultimate value of xeroradiography as a diagnostic tool in the detection of osteonecrosis, a limited number (seven) of xeroradiographic studies was made and then compared with similar projections made with conventional roentgenographic techniques.

TECHNIQUE

The present xeroradiographic osteonecrosis survey consisted of the same projections typically made in a roentgenographic survey — specifically, frontal projections of the shoulders and hips, and frontal and lateral projections of both knees (Martel and Sitterley, 1969). In some instances, frogleg projections of the hips were made. Exposure factors of the shoulders were in the 70-85 KVP, 20-40 MAS range; in the hips, 85-100 KVP, 100-150 MAS range; and in the knees, 75-90 KVP, 10-30 MAS range. The xeroradiograms were then compared with existing roentgenograms made of the same areas.

FIG. 3. Same diver as in Fig. 1. Frontal projection of L knee on (*a*) conventional roentgenogram and on (*b*) xeroradiogram.

FIG. 4. Same diver as in Fig. 1. Lateral projection of L knee on (*a*) conventional roentgenogram compared with (*b*) xeroradiogram.

DISCUSSION

A comparison is made in Fig. 1 through 4 of roentgenograms and xeroradiograms of subjects in whom no osteonecrosis was diagnosed. The excellent detail of soft-tissue and skeletal parts in the xeroradiogram initially generated enthusiasm about the technique. When xeroradiograms and roentgenograms were compared in cases of a positive diagnosis of osteonecrosis (Fig. 5 and 6), however, detail in the actual area of disease on the former was disappointing.

In yet another case (Fig. 7), the subtle circular cystic formation in the right humeral shaft, which is evident on the roentgenogram, is seen on neither the negative nor positive xeroradiograms. However, the general bony detail depicted on the positive-image xeroradiogram is superior to the detail on the negative-image

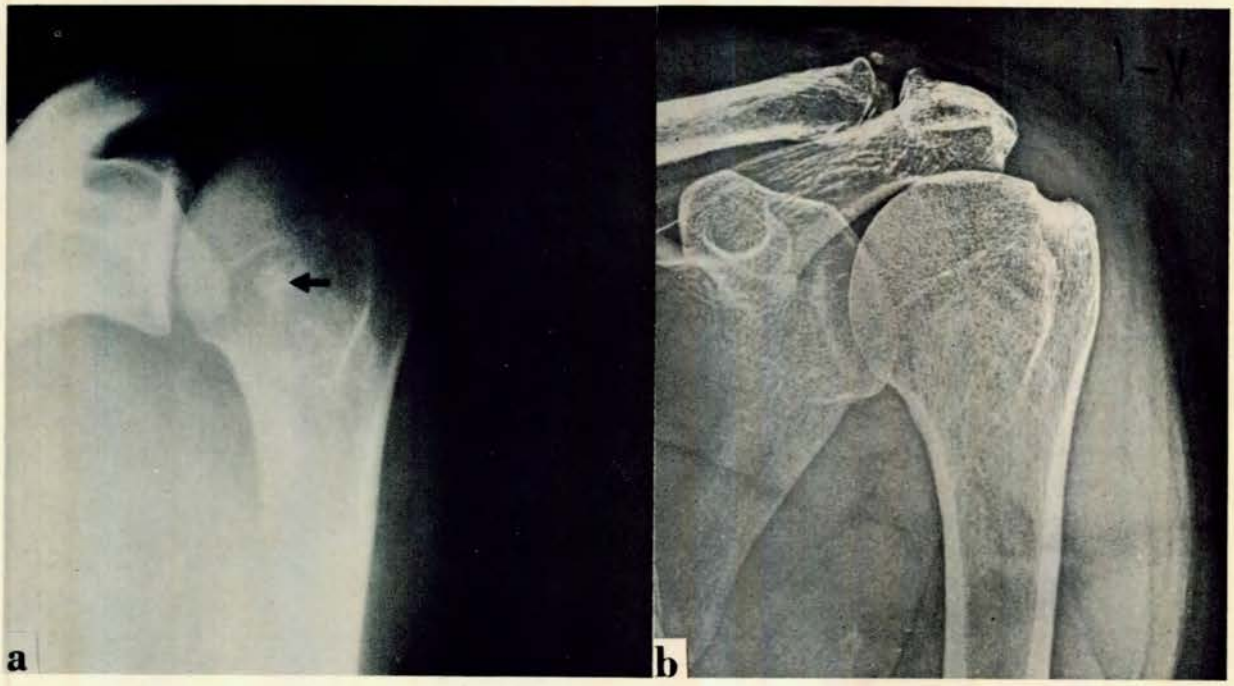

FIG. 5. Bone survey of a Gulf of Mexico diver, which proved positive for osteonecrosis. (*a*) Conventional roentgenogram of L shoulder (osteonecrotic area marked with arrow) required less exposure of subject and demonstrates lesions as well, if not better, than (*b*) the xeroradiogram.

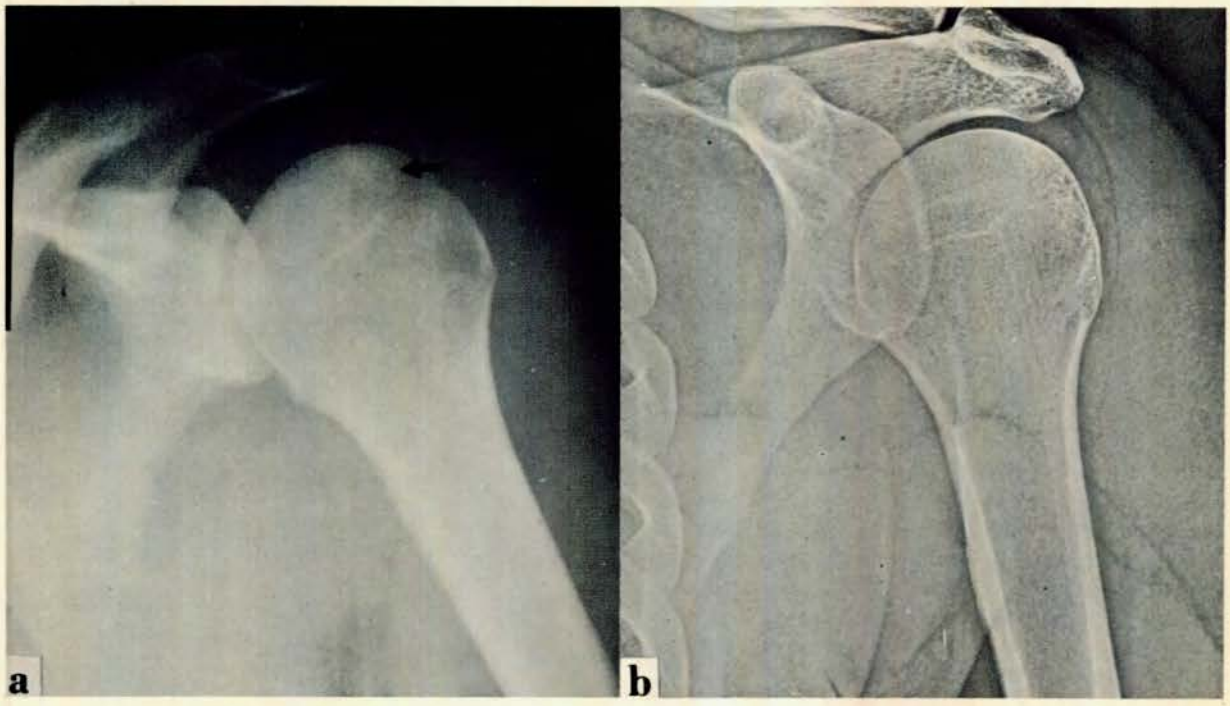

FIG. 6. (*a*) Subtle area of osteonecrosis (arrow) in juxta-articular area of R humerus of diver, as demonstrated roentgenographically. (*b*) Lesion is not evident on xeroradiogram.

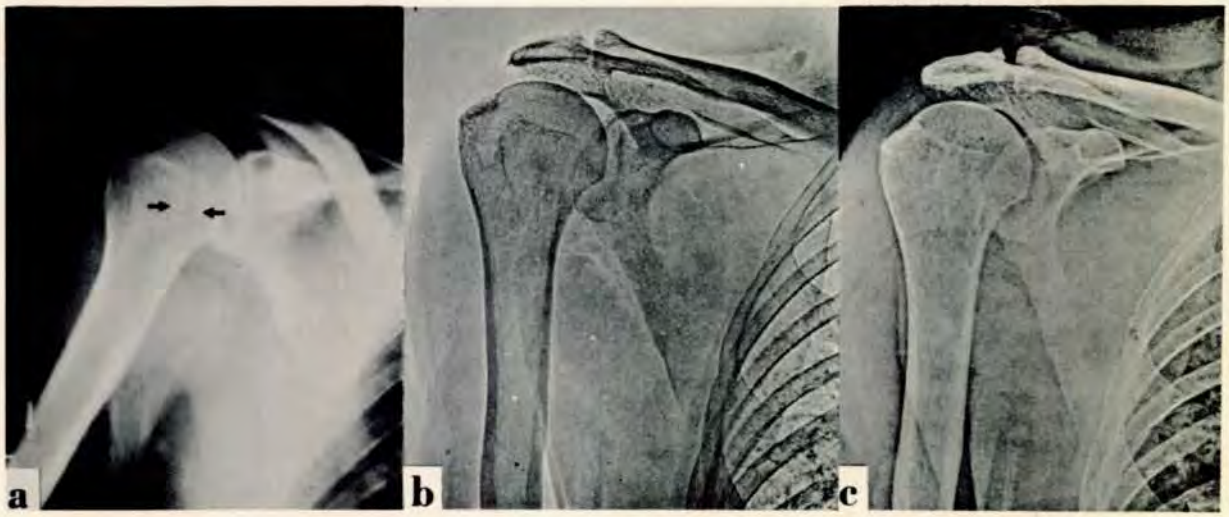

FIG. 7. (*a*) Conventional roentgenogram demonstrates subtle circular cystic formation in R humeral head of diver. Finding is not evident on either (*b*) positive or (*c*) negative xeroradiogram. Note, however, better bone detail on positive xeroradiogram in comparison with negative one.

xeroradiogram. As a result, if xeroradiography is to be used for bone work, such as in an osteonecrosis survey, it appears that positive imaging is superior to negative imaging.

CONCLUSION

Although the number is small, these comparisons of conventional radiography and xeroradiography suggest that the latter is not sufficiently useful as a diagnostic tool to justify the greater radiation exposure inherent in its use. This conclusion should, perhaps, be regarded as tentative, until further evidence supporting the usefulness of xeroradiography in connection with the diagnosis of osteonecrosis is accumulated.

REFERENCES

Martel, W., and Sitterley, B. H. (1969). Roentgenologic manifestations of osteonecrosis. Amer. J. Roentgenol., Radium Therapy Nucl. Med. 106 (3), 509-522.

Woesner, M. E., and Sanders, I. (1972). Xeroradiography: A significant modality in the detection of nonmetallic foreign bodies in soft tissues. Amer. J. Roentgenol., Radium Therapy Nucl. Med. 115, 636-640.

Wolfe, J. N. (1968). Xeroradiography of the breast. Radiology 91 (2), 231-239.

Wolfe, J. N. (1969). Xeroradiography of the bones, joints and soft tissues. Radiology 93 (3), 583-587.

ADDITIONAL DIAGNOSTIC TECHNIQUES

JOHN PAUL JONES, JR.

A comprehensive clinical history and physical examination of an individual whose prospective employment might involve the risk of osteonecrosis should include assessment of any disease in his background known to have an association with avascular necrosis. If routine roentgenograms are positive or questionable with respect to articular involvement, or if an employee later becomes symptomatic even though his X-ray films reveal no evidence of osteonecrosis, appropriate medical consultation is suggested. Additional diagnostic techniques may then be recommended, as follows.

LABORATORY TESTS

When laboratory tests are indicated, the patient is usually hospitalized. These procedures may include: a complete blood count, urinalysis, sedimentation rate, multiphasic chemistry panel, rheumatoid-arthritis agglutination test, lupus erythematosus preparation, serum uric-acid determination, serum hemoglobin electrophoresis, liver-function panel (including bromsulphalein retention, serum alkaline phosphatase, and SGOT), liver biopsy, serum amylase, serum lipase, chemical fractionation of lipids (including serum cholesterol, triglycerides, and phospholipids), four-hour glucose-tolerance test, platelet count, prothrombin time, and partial thromboplastin time.

When nontraumatic fat embolism is suspected, additional blood and urine tests are performed. Methods currently used for the detection of lipiduria (Peltier, 1965) may not be sufficiently sensitive to detect low-grade traumatic or nontraumatic fat embolism (Fig. 1). Fat is not a normal constituent of urine (Beams, 1956), nor do fat globules appear in the urine in experimental hyperlipidemia (Scuderi, 1939). A simple qualitative ether-extraction method has been developed (Jones, 1972) that is specific, provided caution is taken to avoid false-positive results due to nonembolic fat in the urine. Since the presence of cellular elements — oval fat bodies, fatty casts, fatty epithelial cells, and fatty degenerating leukocytes (sudanophils) — or of fat-

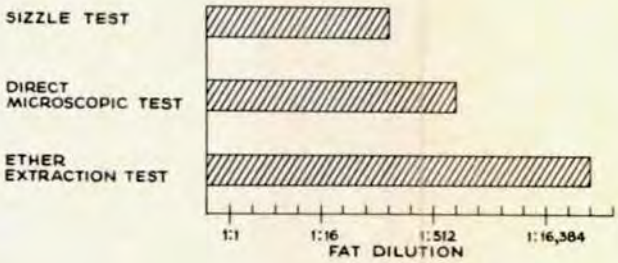

FIG. 1. Comparative sensitivity of tests for urine-fat determinations.

containing fungi (*Candida albicans*) invalidates the results, microscopic examination of urinary sediment is essential in all cases. Fat contamination of the glassware or solutions used in the test by soaps or oily lubricants must be avoided. Similarly, paraffin containers are not to be used for collecting specimens.

A simple test, in which plasma is stained for fat, has recently been developed (Nice, 1972) and may also be useful in the diagnosis of nontraumatic fat embolism. The most definitive means of diagnosing systemic fat embolism *in vivo* is by performing fat stains of percutaneous renal biopsy specimens.

When rheumatoid arthritis, gouty arthritis, septic arthritis (pyarthrosis), or osteomyelitis is suspected, a diagnostic arthrocentesis with synovianalysis is performed. It includes appropriate cultures, polarized light examination for uric-acid crystals, and determination of a rheumatoid factor.

SPECIALIZED RADIOLOGIC TECHNIQUES

Tomography

Tomography is performed when routine roentgenograms appear normal or questionable (Fig. 2). Tomograms performed of early juxta-articular lesions, before there is any evidence of gross architectural distortion or articular incongruity, often show cone-shaped lesions. The apex of the

Preceding page blank

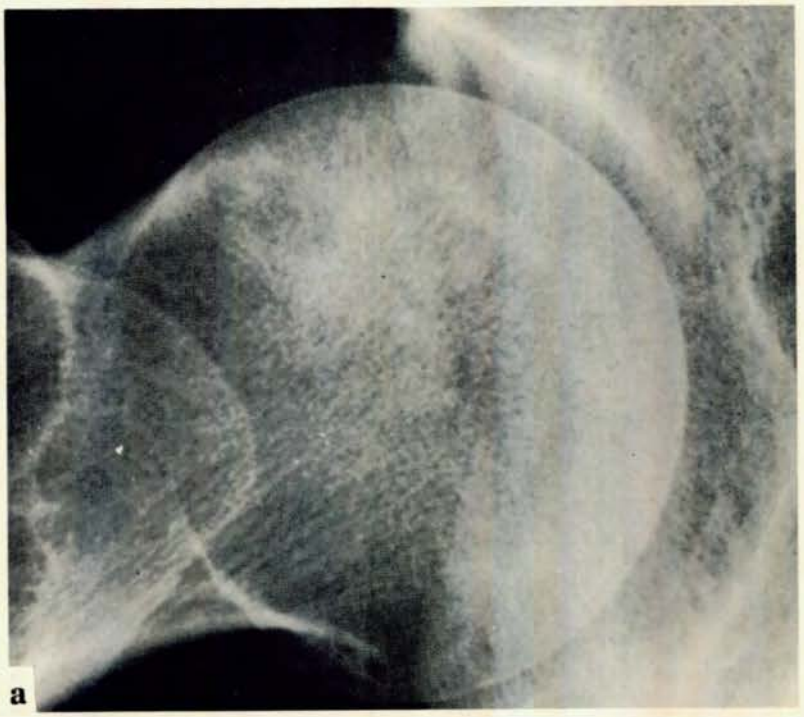

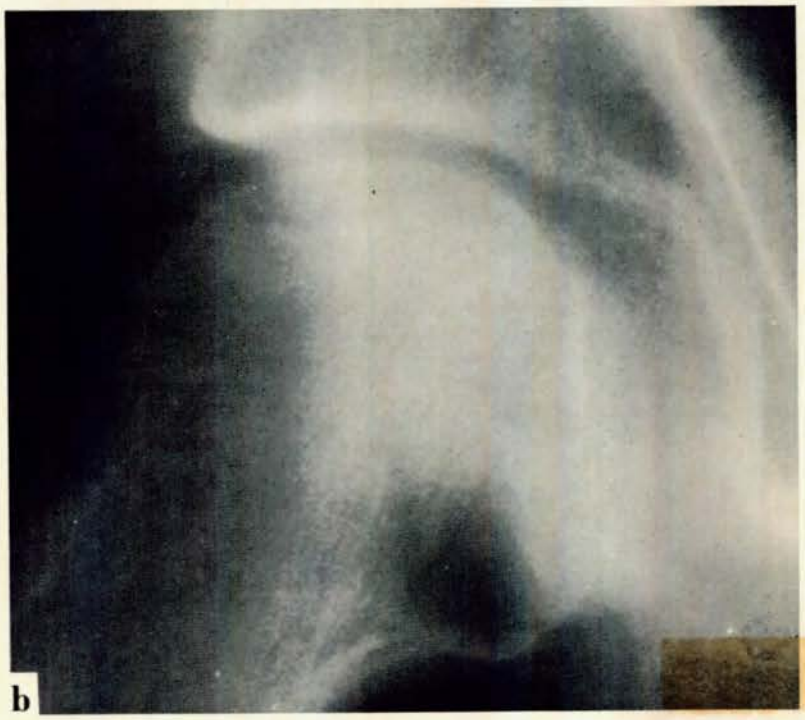

FIG. 2. R femoral head of patient who developed Type I decompression sickness near end of 600- and 650-ft dives. (*a*) Lateral roentgenogram 3½ yr later shows diffuse area of central rarefaction surrounded by patchy sclerosis involving anterior portion of head and extending from region of obliterated epiphyseal line to subchondral region. (*b*) These findings were confirmed on A-P tomogram, which reveals obvious subchondral irregular radiolucency and sclerosis without evidence of segmental collapse.

wedge is usually near the center of the obliterated epiphyseal line with the base of the lesion underlying the articular cartilage. In addition, areas of diffuse or marginal sclerosis or spotty rarefaction are often noted.

Positioning patients for tomography of the humeral head to avoid glenoid superimposition requires a 45° anterior oblique projection. To lift the angle of the acromion away from the humeral head, and to avoid superimposition of the coracoid process, the X-ray tube is tilted 15° inferior, with the humerus in full internal and external rotation. The full external rotatory view in the anterior-inferior-oblique projection (Inman-Temple-Jones) reveals lesions within the central third of the humeral head. Classic "snowcap" lesions of the humeral head are likewise revealed by tomograms in this projection.

Radionuclide Bone Scanning

When routine roentgenograms and tomograms still have not resolved the diagnosis, radioactive sodium fluoride (^{18}F) or technetium polyphosphate (^{99m}Tc) bone scans are performed to assess the vascularity of the femoral and humeral heads and the knees. Incorporation of ^{18}F into bone appears to depend on the exchange of fluoride ions with hydroxyl ions, not only at the surfaces but also within the interior of the hydroxyapatite crystals. Initial distribution of ^{18}F within bone is dependent on the blood-perfusion rate.

Inability to demonstrate increased uptake in a lesion indicates delayed revascularization. Incomplete revascularization and repair in the subchondral region of the femoral or humeral head probably account for late structural collapse. Radionuclide scanning is therefore likely to be a more reliable method of estimating circulation to bone than radiographs are, since positive scans are often obtained before distinct X-ray changes appear. The most effective bone-scanning agent for osteonecrosis is probably ^{18}F, since it decays rapidly (its physical half-life is 1.87 hours), which permits scanning with a minimal radiation dose to the patient. In addition, rapid clearance from plasma, rapid urinary excretion, and high specificity for active bone deposition combine to produce excellent contrast between lesion and normal bone. The scanning time is 90 minutes, with a parenteral dose of 30 to 60 millirads for bone scanning.

Another bone-scanning agent is strontium-85 (^{85}Sr). But its physical half-life is long — 65 days — and its turnover rate in bone, slow, resulting in long scanning times. Radioactive strontium (^{87m}Sr), like radioactive fluoride (^{18}F), subjects the patient to minimal irradiation, thereby permitting studies of nonmalignant conditions. But ^{87m}Sr is expensive and has 95% retention during the first few hours, which results in relatively high background radiation. Radioactive calcium (^{47}Ca) has not proven effective in the scanning-image evaluation of osteonecrosis. Recently ^{99m}Tc has been found to provide very satisfactory skeletal imaging of early lesions; it is, furthermore, less expensive and more available than ^{18}F.

SPECIAL SURGICAL PROCEDURES

When routine roentgenograms, tomograms, or radionuclide scans reveal juxta-articular lesions without evidence of articular incongruity, whether the patient is symptomatic or not, certain diagnostic procedures may be performed through a small lateral thigh incision, usually with spinal anesthesia and with biplane roentgenographic localization.

Radioactive Phosphorus (^{32}P) Uptake Study

This technique is adapted from Boyd and Calandruccio (1963) and involves radioactive phosphorus (^{32}P), which emits beta rays. It is a bone-seeking isotope, with a half-life of 14.3 days and a soft-tissue penetration of 7 mm.

Approximately 90 minutes prior to surgery, 500 microcuries of a buffered solution of ^{32}P are administered intravenously. Under biplane roentgenographic control, a calibrated localization pin is drilled into the area of the lesion in a femoral (or humeral) head and is replaced by a surgical scintillation detector probe (Fig. 3*a*).

The probe has a cesium iodide crystal that is sensitive to beta emission, and its handle encloses a photomultiplier tube and preamplifier. The probe is lightweight, cold-sterilized, and more sensitive than the Geiger-Müller instrument, and it can be used with any standard rate meter. The recorded radiation is derived from bone immediately surrounding the probe tip.

The uptake of ^{32}P in a femoral-head lesion (Fig. 3*b*) is recorded, and the probe is then withdrawn to the trochanteric region (Fig. 3*c*) where an uptake is recorded for comparison. A trochanter-to-head (T/H) ratio is calculated, expressing uptake by the lesion in comparison with uptake by a segment of bone with an unimpaired blood supply.

If circulation to the lesion is interrupted, there is little uptake for at least two hours following the injection of ^{32}P, while there will be sufficient uptake in the trochanteric region for comparative purposes. Predictions of viability derived from

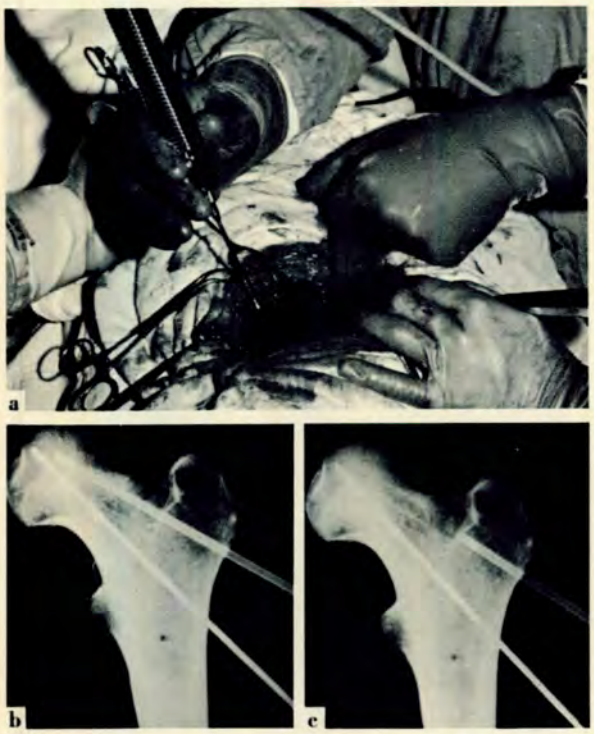

FIG. 3. (*a*) Scintillation probe being introduced into femoral head through predrilled hole in lateral cortex. (*b*) Sensitive cesium iodide tip of scintillation probe is localized in dry specimen of proximal femur, indicating usual location for femoral-head determinations. (*c*) Comparative location of probe for trochanteric ^{32}P uptake readings.

T/H ratios of less than 3/1 and of nonviability from readings of 6/1 or more are approximately 90% accurate. Certain modifications of this method were made after examination of 28 patients with intertrochanteric or femoral-neck fractures in an attempt to predict posttraumatic avascular necrosis of the femoral head (Jones and Bovill, 1972).

Well-demarcated, wedge-shaped subchondral lesions surrounded by a substantial zone of marginal sclerosis show no significant radioactivity within the subchondral region (T/H ratio exceeds 6/1). On the other hand, there is often indirect evidence of hypervascularity immediately subjacent to the sclerotic margin (T/H ratio, 1/1.5), suggesting that the revascularization process has not been successful in penetrating the lesion's fibrous avascular boundary.

Differential Oximetry and Intramedullary Pressure Determinations

Probe oximeters have been used without success in measuring differential oxygen tensions between a lesion and the greater trochanter (Woodhouse, 1962). Currently a simpler method is used, whereby a cannula and obturator are inserted into the lesion within the femoral (or humeral) head; heparinized blood specimens are obtained from the affected region and the greater trochanter. The patient breathes alternately room air and 100% O_2 by mask, and comparable specimens of blood are obtained from the trochanteric region. If the lesion has sufficient vascularity, O_2 tension of the aspirated blood will ordinarily increase significantly with 100% O_2 inspiration. Often, however, attempted aspiration of the lesion results in a "dry tap."

Next, the obturator is reintroduced and a simple three-way stop-cock and spinal-fluid manometer are added to the cannula. The intramedullary blood pressure in the lesion itself is not important. But the presence or absence of fluctuations in manometric pressure caused by arterial pulse pressure is significant. The absence of manometric fluctuations within the lesion, and their presence in the trochanteric region, are considered confirmatory evidence of avascularity (Miles, 1959).

Intraosseous Phlebography

Since veins and arteries follow a close and essentially parallel course in the femoral head, neck, and joint capsule, venography provides indirect information regarding the arterial blood supply of the femoral head.

Intraosseous phlebography (venography) is more reliable than arteriography for detecting osteonecrosis (Rook, 1953). Veins, even small retinacular branches, can be detected roentgenographically more clearly than the corresponding arteries. Veins are more fragile than arteries; and if a typical venous pattern is present, it is likely that the corresponding arterial tree is also present.

The affected hip is placed in neutral or external rotation to minimize intra-articular pressure (Soto-Hall and Johnson, 1964). It is quite important that the injection cannula not penetrate the articular cartilage of the femoral head. Approximately 5 cc of 50% Hypaque is introduced in about 15 seconds, and A-P roentgenograms are taken during and following the injection (Hulth, 1958; Hulth and Johansson, 1962).

The iodized contrast medium is injected di-

rectly into the femoral-head lesion rather than into the trochanteric region (Arlet, 1971). Eberle (1971) doubted the possibility of making reliable predictions on circulatory conditions in the femoral head and neck by means of intratrochanteric phlebography, since drainage from these areas cannot be observed with this technique. The flow of venous blood from an osteonecrotic lesion is invariably reduced or completely arrested, and often greater pressure than usual is necessary to inject the contrast medium. Frequently no venous drainage from the lesion is detected at all, and the contrast material pools within the cancellous bone. Or, if there is a subchondral fracture extending through the necrotic lesion and cartilage, the contrast material pools within the joint itself.

Positive phlebograms are those in which veins arising from the femoral head are immediately filled with contrast medium. In positive circumflex venograms, the retinacular, medial and lateral circumflex, femoral, and external iliac veins are filled. In positive ligamentum-teres venograms, the foveal vein as well as the acetabular, obturator, and internal iliac veins are filled. In certain instances both these systems are filled simultaneously (Fig. 4*a*).

Negative phlebograms are those in which no veins are visible and the contrast medium has flowed into the joint space or remains in the cancellous bone of the head and neck. Venous stasis is associated with femoral-head necrosis. In most cases of nontraumatic necrosis the phlebogram is negative, with a typical trabecular (intramedullary) drainage pattern, inasmuch as the contrast medium flows through the medullary sinus of the femoral neck and trochanteric region. Serial phlebograms demonstrate delayed drainage of the contrast medium with persistent pooling within the femoral head, neck, and proximal shaft (Fig. 4*b*).

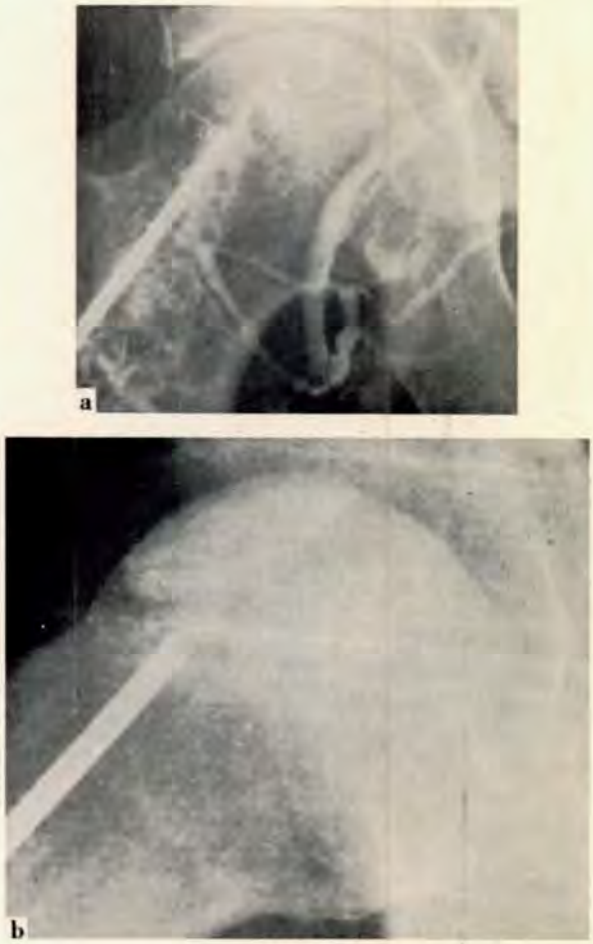

FIG. 4. (*a*) A-P view of R hip taken during intraosseous phlebography, revealing essentially normal immediate venous drainage from periphery of femoral head and neck. (*b*) X-ray film taken 15 min later suggesting residual contrast material (Hypaque) sequestered in avascular-appearing segment. (Jones, 1971. Illustration courtesy of publisher.)

Biopsy Drilling Procedure

Biopsy drilling should be performed to confirm a diagnosis of osteonecrosis if hemodynamic tests are abnormal (Arlet and Ficat, 1971). Early diagnosis is particularly important when necrotic lesions are unaccompanied by gross architectural distortion or articular incongruity, so that irreversible damage may possibly be avoided by using surgical procedures to revascularize the necrotic area.

Furthermore, it is important to biopsy atypical lesions bearing similarity to avascular necrosis, which may actually be a giant-cell tumor, cystic tuberculosis, pigmented villonodular synovitis, chondroblastoma, or calcified enchondroma.

Through a lateral thigh approach a Turkel trephine with obturator is positioned by biplane roentgenograms to the anterosuperior region of the femoral head (where most lesions of idiopathic necrosis are located). The surgeon introduces the trephine into the subchondral bone, advancing and rotating it while verifying its position radiologically (Fig. 5*a*). The biopsy specimen is removed and examined macroscopically. It is then fixed in formalin, decalcified with nitric acid, and embedded in paraffin. Sections

FIG. 5. (*a*) A-P view of R hip of 51-year-old Caucasian male with idiopathic osteonecrosis, showing location of Turkel biopsy drilling trocar in subchondral bone of femoral head. (*b*) High-resolution roentgenogram of osseous cylinder (1 x 5 cm) obtained from femoral head by biopsy drilling. Arrow points to sclerotic (and necrotic) lesions.

are cut along the major axis and stained with hematoxylin-eosin. Occasionally larger biopsy cores are removed for pathological examination. In these instances high-resolution roentgenograms of the cores are obtained prior to sectioning and staining (Fig. 5*b*). The incision may be lengthened proximally and posteriorly to obtain specimens of the capsule and synovium for special additional studies.

SUMMARY

When a comprehensive clinical history and physical examination indicate possible idiopathic or nontraumatic osseous avascular necrosis, additional diagnostic tests are often recommended, including tomography and radionuclide bone scans. The suspected lesion may be confirmed by various tests, such as a differential radioactive phosphorus (^{32}P) uptake study, differential oximetry, intramedullary pressure determinations, intraosseous phlebography, and biopsy for tissue microscopy and microroentgenography.

REFERENCES

Arlet, J. (1971). Pertrochanteric phlebography in primary necrosis of the femoral head in the initial state (Stage I). In Idiopathic Ischemic Necrosis of the Femoral Head in Adults. pp. 152-157. Ed. Zinn, W. M. Stuttgart, Germany: Thieme.

Arlet, J., and Ficat, P. (1971). Biopsy drilling as a means of early diagnosis of idiopathic ischemic necrosis. In Idiopathic Ischemic Necrosis of the Femoral Head in Adults. pp. 74-80. Ed. Zinn, W. M. Stuttgart, Germany: Thieme.

Beams, H. W. (1956). Excretion products: Man. In Handbook of Biological Data. p. 242. Ed. Spector, W. S. Philadelphia: Saunders.

Boyd, H. B., and Calandruccio, R. A. (1963). Further observations on the use of radioactive phosphorus (P^{32}) to determine the viability of the head of the femur: Correlation of clinical and experimental data in 130 patients with fractures of the femoral neck. J. Bone Joint Surg. 45-A, 445-460.

Eberle, H. (1971). Venographic differences in traumatic hip affections and in idiopathic femoral head necroses. In Idiopathic Ischemic Necrosis of the Femoral Head in Adults. pp. 162-167. Ed. Zinn, W. M. Stuttgart, Germany: Thieme.

Hulth, A. (1958). Femoral-head phlebography: A method of predicting viability. J. Bone Joint Surg. 40-A, 844-852.

Hulth, A., and Johansson, S. H. (1962). Femoral-head venography in the prognosis of fractures of the femoral neck. Acta Chir. Scand. 123, 287-297.

Jones, J. P., Jr. (1971). Alcoholism, hypercortisonism, fat embolism and osseous avascular necrosis. In Idiopathic Ischemic Necrosis of the Femoral Head in Adults. pp. 112-132. Ed. Zinn, W. M. Stuttgart, Germany: Thieme.

Jones, J. P., Jr. [1972]. An improved qualitative test for the detection of lipiduria. To be published.

Jones, J. P., Jr., and Bovill, E. G., Jr. [1972]. Unpublished data.

Miles, J. S. (1959). Intramedullary pressure of the femoral head. J. Bone Joint Surg. 41-B, 619.

Nice, G. W. (1972). J. Kansas Med. Soc. 73, 441-443.

Peltier, L. F. (1965). The diagnosis of fat embolism. Surg. Gynec. Obstet. 121, 371-379.

Rook, F. W. (1953). Arteriography of the hip joint for predicting end results in intracapsular and intertrochanteric fractures of the femur. Amer. J. Surg. 86, 404-409.

Scuderi, C. S. (1939). Fat excretion through the kidneys: An experimental study. Arch. Path. 28, 668-675.

Soto-Hall, R., and Johnson, L. H. (1964). Variations in the intra-articular pressure of the hip joint in injury and disease—A probable factor in avascular necrosis. J. Bone Joint Surg. 46-A, 509-516.

Woodhouse, C. F. (1962). Anoxia of the femoral head. Surgery, St. Louis 52, 55-63.

DISCUSSION 7

Dr. GILLEN: What does a scan cost?

Dr. GORTEN: $105.00.

Dr. PAULEY: At Submarine Development Group One [FPO, San Diego, California 92132], we undertook an investigation to see whether aseptic bone necrosis might occur on a subclinical basis immediately following a saturation dive. Eighteen student saturation divers were given predive fluorine-18 scans and long-bone skeletal surveys. Within 72 hours following their initial saturation dive to 180 ft, they underwent a postdive scan. All 18 divers had normal pre- and postdive scans.

On a subsequent saturation dive, a Navy diver suffered decompression sickness at 30 ft during the ascent. A postdive scan (three days after the dive) demonstrated increased activity in both knees and the right femur, sites in which the diver had experienced pain. Roentgenograms of these areas are still negative [November 1972] for bone necrosis. We may have the earliest documented case of aseptic bone necrosis. We will have to follow this diver closely to determine when and if his X-rays turn positive.

We undertook another special study to determine the natural course of aseptic bone necrosis. A SeaLab II diver suffered bends in 1968 and his X-rays were strongly positive for bone necrosis in both femurs. A strontium-85 bone scan was performed in 1970; it was read as being only mildly positive in both femurs. We contacted this subject for a follow-up scan, this time with ^{18}F. The ^{18}F scan was completely negative, but the diver's X-rays now show severe serpiginous calcifications in both femurs. We can therefore say that, within a four-year period, all reactive bone formation has occurred and there is no new bone formation taking place, as evidenced by the negative ^{18}F scan. This gives us some idea about the time it may take for the reparative process to occur following an avascular insult secondary to decompression sickness.

I should like to ask Dr. Miles a question. If we depend on the incorporation of bone-seeking isotopes into bone after necrosis occurs, how soon can we expect reactive bone formation to take place? In other words, how soon would a scan become positive after an infarct?

Dr. MILES: You have raised a very pertinent question regarding the use of these isotopes. From Dr. Gorten's Fig. 1, you can see the reason for the question. The diagram shows the hydration shell around the crystal of bone. The shell is in equilibrium with the extracellular fluid. If the extracellular space is adequately perfused, there will be an exchange between it and the hydration shell; the isotope will be taken up in the hydration shell even if the bone is dead. This was demonstrated by Dr. Robert D. Ray of the University of Illinois. Also, if the isotope has a long enough half-life, it will be incorporated into the crystal. The reaction is a purely chemical one and involves no cellular activity whatsoever. It will therefore take place in dead as well as living bone. Regarding your question about the time lapse, I am totally unfamiliar with this and not competent to answer.

Dr. GORTEN: It is my impression that relative differences in concentration of bone-seeking radioactive tracers, as revealed on scans, are caused by relative differences in blood flow and rate of bone metabolism. This explanation is based on investigations made of fractures and tumors of bone. We might extrapolate this knowledge to explain why areas of bone necrosis can often be recognized on scans as areas of increased tracer concentration. It probably depends on a reaction by the bone immediately adjacent. This

reaction includes increased bone metabolism and therefore causes increased concentration of tracer.

One might guess that there is a brief delay between the inception of necrosis and its appearance on a scan. One might also conjecture that after a period of time the disease process will subside, as might reaction to it by the adjacent bone. The scan might then no longer appear abnormal in that location. Animal studies and serial scans in active divers might provide a more definite answer to these questions.

DISCUSSION 8

Dr. HARRISON: I think that Dr. Fagan was too modest in his presentation. His was a superb demonstration of the xeroradiographic technique. It seems to me that this technique has value when one wants to look at the cortex of bone. Some of the densities that he showed could not in fact be seen in the radiography — particularly, I think, the ones of the knees. On one roentgenogram was a vague area of density in the tibia that worried us, but it was not apparent on the xeroradiogram. Conversely, just below the cortex in some of the xeroradiograms, there were doubtful areas that one could not see on X-ray.

The increase in radiation exposure is colossal in xeroradiography. But obviously the technique ought to be further explored when there are doubtful lesions, particularly near the cortex.

Dr. WALDER: I obtained permission to carry out a radioisotope scan following the injection of strontium-85 into six men with known bone lesions. One of these scans is shown in Fig. 1. The ^{85}Sr was injected on a Saturday morning and the scan made the following Tuesday. The white dots correspond to the centers of the femoral heads. Without a doubt the lesion, which was on the right side, took up ^{85}Sr.



FIG. 1. Strontium scan of pelvis of compressed-air worker showing abnormal activity in R femoral head where there is known to be, on radiological evidence, an osteonecrotic lesion. (Photograph courtesy of University of Newcastle upon Tyne.)

The interesting thing is that ^{85}Sr was taken up by the lesions in all six men, despite the fact that some had existed for three to five years. One might therefore have expected them to be healed and static.

In explanation it has been suggested that, although a lesion may be very old, osteoclastic and osteoblastic activity may still be going on, so that ^{85}Sr uptake will still occur. An alternative possibility may be that ^{85}Sr is taken up even in the absence of a blood supply. A third possibility is that, in an area of restricted blood supply, ^{85}Sr is taken up more slowly than in the rest of the bone and is then eliminated more slowly. It is then this more slowly eliminated isotope that one measures.

In some of the six men in our Newcastle study, the scan findings matched the radiological findings; in others they did not. Wherever an abnormality was revealed radiologically, the scan showed it. But sometimes the scan was positive when the radiograph did not show a lesion.

I thought it worthwhile X-raying a normal person, and used myself as a subject. Radiologically my hips are normal, but I did have a mildly positive strontium scan in both hips. I reconsidered and decided that perhaps I was not so normal after all, in that I have had several exposures to compressed air and "dry" dives. When a control subject — who had never been exposed to compressed air and whose hips were radiologically normal — was scanned, there was no evidence of ^{85}Sr retention.

Can anyone offer any explanation for the ^{85}Sr retention, other than that it is evidence of an osteonecrotic lesion?

Dr. MILES: I can only conjecture about this increased uptake of strontium in an area of necrosis. As I mentioned when Dr. Harrison presented his paper on the radiological aspects of the disease, one sees only the end stage of a very advanced process of creeping substitution and replacement. In those areas there is a great deal of appositional bone formation. Dr. Walder mentioned this sequence in his discussion of the sheep — that, in those areas where radiographic evidence exists, microscopic signs are of a much larger area of involvement, with much appositional bone formation. One would therefore anticipate an increased strontium uptake in the areas of involvement. The strontium scan perhaps indicates the magnitude of the lesion years ago, the degree of tissue response, and the extent of repair.

Dr. JONES: We have employed differential radioactive phosphorus studies using a scintillation probe to evaluate the vascularity of certain femoral-head lesions. There is no significant radioactivity in those epiphyseal lesions walled off by a sclerotic margin (calcified and fibrous tissue). However, increased radioactivity (hypervascularity) is occasionally found after the probe is withdrawn immediately outside the sclerotic margin, with greater radioactivity than is often found in the control area of the greater trochanter.

PART VII

CASE MANAGEMENT AND TREATMENT

MANAGEMENT AND TREATMENT OF OSTEONECROSIS IN DIVERS AND CAISSON WORKERS

DENNIS N. WALDER

In the matter of treating patients with dysbarism-related osteonecrosis, the following questions arise:

—What advice should be given the individual diver or other compressed-air worker with a diagnosis of dysbaric osteonecrosis *1*) at a site where it is unlikely ever to cause symptoms; and *2*) at a site where symptoms may arise, or have already arisen?

—What action may be necessary for a man with hip or shoulder-joint symptoms whose radiographs are normal?

—What is the best treatment for compressed-air workers who have painful and/or disabling lesions?

So little is known about the evolution of the bone changes in osteonecrosis that, at the moment, it is difficult to devise a realistic program of management and treatment. For this reason a central data-gathering organization — such as the Decompression Sickness Central Registry* — is particularly important. It must not be forgotten, as well, that valuable data can often be obtained from the postmortem examinations of compressed-air workers and divers who have died from conditions unrelated to their hyperbaric experience.

*21, Claremont Place, Newcastle upon Tyne NE 2 4AA, England

Advice to Be Given to the Patient with Dysbaric Osteonecrosis

Osteonecrosis at a site not likely to cause symptoms. Lesions in the neck or shaft of a bone, or in its head well away from the articular surface, never (as far as we know) cause symptoms. Treatment is therefore not required, but a crucial question must be answered. Is it advisable for the patient to continue to dive or work in compressed air? No compelling evidence exists upon which to assess the probability that a man with radiographically demonstrable bone lesions will suffer additional bone damage, either in the form of new lesions or the worsening of existing ones, if he continues to work under hyperbaric conditions. The man should be told of the possible consequences of further compressed-air exposure so that he can share in the responsibility for the decision about his future work. It is probably reasonable to allow such a man to continue ordinary diving on air. But he should be excluded from unusual exposures, such as may occur in experimental diving.

Osteonecrosis at a site where symptoms may arise. In the case of a symptomless juxta-articular osteonecrotic lesion in the head of a femur or humerus, it seems reasonable to advise the patient to avoid any further potentially dangerous hyperbaric exposures. Practically, this would mean limiting caisson workers' exposure to pressures at which the risk of bone necrosis is believed to be virtually nil — *i.e.*, below 18 psig. A diver so afflicted should be restricted to oxygen diving, in which (so far as is known at present) there is no risk of bone damage. Because the possibility exists that a man with a juxta-articular hip or shoulder lesion will eventually develop symptoms, the risk of developing osteonecrosis in the other femoral or humeral head must be minimized. The consequences of having symptomatic osteonecrosis of both hip or shoulder joints would be catastrophic. Not only would the patient be unable to continue diving or tunnel work, but he would quite likely be incapable as well of performing other types of manual labor, or he might even become totally incapacitated.

When a juxta-articular lesion — particularly in the head of the femur — has progressed to the extent that it causes pain, the patient will probably be unable to work in any case, and will therefore readily accept the advice to give up compressed-air work or diving.

Action Necessary When Symptoms of Osteonecrosis Are Present but X-rays Are Normal

Occasionally a compressed-air worker or diver will complain of a painful hip or shoulder when nothing abnormal can be seen in the radiographs. In these circumstances special radiographic techniques, such as tomography or xeroradiography,

Preceding page blank

may be helpful. Some orthopedic surgeons believe that venography, biopsy, or radioactive scanning techniques may reveal the presence of osteonecrotic lesions not detectable in X-rays. Whatever technique is used, the primary objective must be to provide the patient with a definite answer about whether he has dysbarism-related osteonecrosis or not.

Treatment of Osteonecrosis

Juxta-articular lesions pose a particularly difficult therapeutic problem. They are usually symptomless until the articular surface is deformed by collapse or indentation, probably because of stress on the damaged area. Thereafter, pain upon movement of the limb is a prominent symptom. If the man is allowed to continue work without treatment, he will almost certainly develop arthritis in addition to the original lesion. The joint will then become so disorganized that it will not only be painful but also severely restricted in movement.

Experience shows that necrotic bone collapses where the greatest stress occurs. One might therefore suggest that, when the early signs of a lesion underlying the articular surface of a bone are found, the joint should be protected from load-bearing; there is always the possibility that lesions can heal spontaneously. However, since relief of load-bearing could mean putting the patient to bed for several months, this treatment cannot be undertaken lightly.

Figure 1 shows the radiographs of a shoulder joint with just a suspicion of a lesion, which becomes more definite in nine months, and then, six months later, is no longer visible. Apparently it has healed. Caution in the last diagnosis is necessary, however, because the radiological technique used in the three films may not have been consistent. If this humeral head were to be examined again by tomography, a lesion might still be seen.

Another difficulty is that, although serial radiographs can demonstrate a lesion growing progressively worse, it is not possible to forecast from a single film whether a particular lesion will progress or remain stationary. In Fig. 2*a*, for example, is the radiograph of a humeral head taken in February 1967, in which changes suggestive of osteonecrosis are very doubtful. But only four months later, the lesion has developed to such an extent that the whole humeral head has disintegrated (Fig. 2*b*). These films are a graphic demonstration of how rapidly some

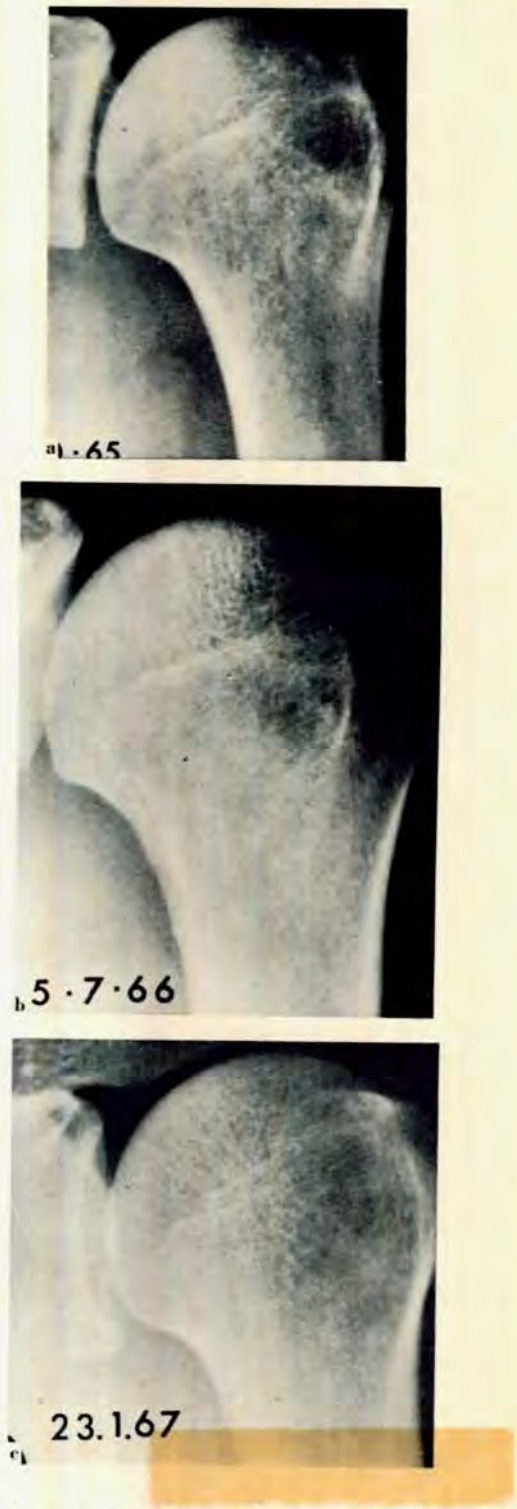

FIG. 1. Apparent healing of osteonecrotic lesion in humeral head of compressed-air worker, showing (*a*) very early lesion under cortical margin; (*b*) more definite lesion 9 months later; and (*c*) 6 months later, when lesion is no longer visible.

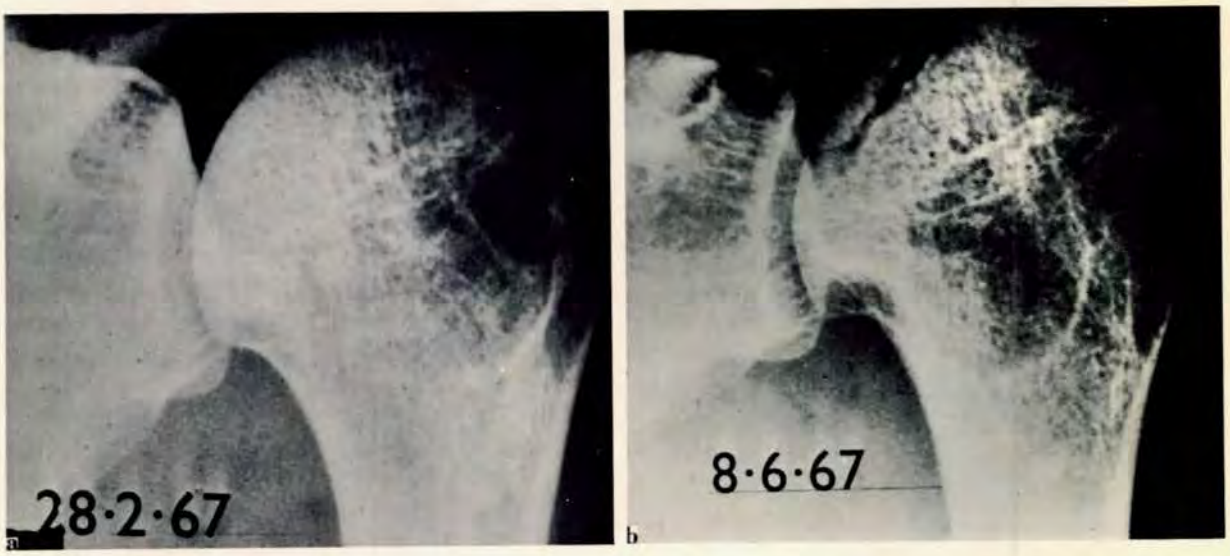

FIG. 2. Rapid progress of osteonecrotic lesion, in which there are (*a*) changes suggesting early lesion; and (*b*) disintegration of humeral head 4 months later.

comparatively mild-looking lesions can advance.

Some lesions, by contrast, remain static for many years. In Fig. 3*a*, a definite lesion can be seen in the head of a humerus; five years later (Fig. 3*b*), the lesion is virtually unchanged. Selection of those subjects who might benefit from relief of load-bearing is therefore not possible at present.

The radiographs shown in Fig. 4 illustrate the progression of a lesion to the point that operative treatment becomes essential. The first shows the humeral head of a man 3 months after he ceased

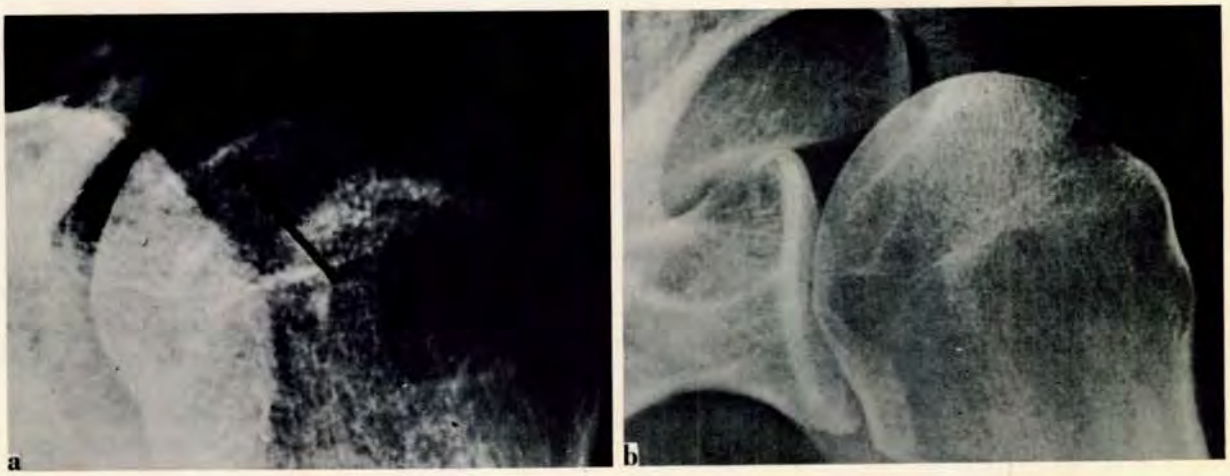

FIG. 3. Humeral head showing static osteonecrotic lesion (*a*) as diagnosed in 1962; and (*b*) 5 years later, in which no change is evident.

FIG. 4. Roentgenograms showing progression of osteonecrotic lesion severe enough that operative treatment is necessary: (*a*) bone island only, 3 months after patient ceased work in compressed air; (*b*) definite dysbarism-related osteonecrosis, in addition to bone island, 19 months after last compressed-air exposure; and (*c*) fragment of bone breaking away, with bone island still present, 22 months after last exposure.

working in compressed air. The small dense area just below the cortical margin is a bone island and is of no consequence. About 16 months later, however — 19 months after his last exposure — there is a definite osteonecrotic lesion, but the bone island has remained unchanged. Then, 22 months after his last compressed-air experience, a piece of necrotic bone is beginning to crack off. The bone island is still unchanged. The orthopedic surgeons ultimately reattached the fragment of bone with a screw and the result was fairly satisfactory. Unfortunately, however, the patient has now developed a lesion in the other shoulder.

(Incidentally, this series of X-rays illustrates the difference between a patch of osteonecrosis and a bone island. The bone island remains static over the years, whereas the lesion gradually progresses until the cortex of the bone collapses, giving rise to symptoms.)

Once operative treatment is indicated, the procedure to be adopted must be considered. But it must be borne in mind that surgical treatment in these cases is not always completely satisfactory.

In our recent experience, 12 patients with a total of 16 joints damaged by osteonecrosis have been operated on. They were all young — around 30 years of age. It was therefore felt that radical treatment, such as total hip-joint replacement (in which both the head of the bone and the articular cup into which it fits are removed and replaced by a prosthesis), was not justified. For the estimated life of an implanted joint prosthesis is only about 10 years.

Techniques less radical than hip replacement were therefore tried. In three patients the osteonecrotic lesion of the femoral head was drilled into from below. Pegs of bone were then inserted through the lesion to shore up the articular cortex (Phemister, 1949; Bonfiglio and Bardenstein, 1958). The results, however, have been unsatisfactory. In one patient it has already been necessary to remove the femoral head and insert a prosthesis. This same procedure will soon have to be followed in the other two patients.

In another two patients with lesions affecting the femoral head, drill holes have been made through the osteonecrotic area of bone into the underlying normal bone to provide channels along which revascularization can occur. Again the results have been very poor, as the patients have gained neither in freedom from pain nor in movement.

Two patients with sequestration of the humeral head have been treated by fixing the displaced necrotic fragment into place with a screw. These results have been encouraging; both men have remained symptom-free and have quite good mobility. Unfortunately, this surgical procedure is not advisable or, perhaps, even possible in the hip because of the problem of weight-bearing. A repair involving screws is not likely to be strong enough to resist the severe stresses encountered in the hip.

Another measure that has been tried in three patients in which sequestration has occurred was simply to remove the dead flake of bone. Although the one hip and two shoulders treated continue to give pain, their mobility is quite good.

The hips of four patients and the shoulder of one have been treated by partial replacement of the joint; only the necrotic head of the bone was replaced by a prosthesis. The results have been extremely satisfactory, although it appears that one hip will eventually need total replacement.

In one case arthrodesis was carried out. In this operation the humeral head was fixed to the shoulder blade (the bone with which it articulates), mobility thereafter depending on mobility of the shoulder blade. This form of treatment has proved satisfactory for the relief of pain and, at the same time, has allowed a surprising amount of movement.

It is clear from this account that, unfortunately, there are too many unknown factors at present to deal satisfactorily with the orthopedic problems posed by dysbaric osteonecrosis. More fundamental information about the initiation, development, and progression of osteonecrotic lesions is urgently required.

REFERENCES

Bonfiglio, M., and Bardenstein, M. D. (1958). Treatment by bone-grafting of aseptic necrosis of the femoral head and non-union of the femoral neck (Phemister technique). J. Bone Joint Surg. 40-A, 1329-1346.

Phemister, D. B. (1949). Treatment of the necrotic head of the femur in adults. J. Bone Joint Surg. 31-A, 55-66.

ORTHOPEDIC MANAGEMENT AND TREATMENT OF OSTEONECROSIS

JOHN PAUL JONES, JR.

These recommendations for management are based upon personal observations of about 135 patients who have nontraumatic avascular necrosis, including 44 patients with dysbarism-related osteonecrosis. Only lesions affecting the juxta-articular or epiphyseal regions of bones will be considered, since intramedullary metadiaphyseal lesions are neither symptomatic nor disabling, and hence require no treatment. However, recognition of metadiaphyseal bone infarctions is important because the tendency in these patients to have coexistent epiphyseal lesions, or subsequently to develop them, is greater than in individuals without metadiaphyseal lesions.

The skeletal distribution of lesions in dysbaric osteonecrosis, in contrast to other illnesses associated with nontraumatic avascular necrosis, involves the humeral head more frequently than the femoral head. Despite the high incidence of symptomatic bends affecting knee joints, the epiphyseal regions of the distal femur and proximal tibia are rarely affected by dysbaric osteonecrosis — a circumstance possibly explained by extensive collateral circulation about the knee joint. To provide a rational approach to the medical and surgical treatment of asymptomatic and symptomatic lesions, it is helpful to consider that the evolution of nontraumatic *(e.g.*, dysbaric) osteonecrosis usually occurs in three stages and that the management is different for each.

STAGE I LESIONS

The patient is usually asymptomatic; routine roentgenograms are often normal, but tomography and radionuclide scintimetry suggest focal avascularity. Pathologically, there is no architectural distortion of the articular surface and only focal abnormalities are present.

Symptoms — such as shoulder or hip (groin) pain, muscle spasm, and joint stiffness — do not necessarily coincide with roentgenographic abnormalities; in fact, symptoms may be lacking altogether. It is extremely important to diagnose osteonecrosis at this early stage. The patient should not be exposed to further dysbaric phenomena until a diagnosis is established. In the meantime, if femoral-head lesions are suspected the patient should remain non-weight-bearing (crutch walking). If humeral-head lesions are suspected, he should avoid overhead lifting or performing heavy manual labor, including, especially, the use of pneumatic-type drilling equipment. Most commonly, the central third and middle portion of the humeral head and the anterosuperior quadrant of the femoral head are involved. Mechanical stress to these joints, particularly in the areas mentioned, should be eliminated.

Once the diagnosis is established, the patient should undergo a program of vocational rehabilitation. He should not be exposed to dysbaric phenomena or be allowed to continue participating in hard manual labor. Routine follow-up roentgenograms and, if necessary, tomograms should be performed at regular intervals — every three to six months. The patient should curtail physical activities to provide mechanical protection of the articular surfaces and, hopefully, to allow sufficient time for intrinsic revascularization of the necrotic lesion to occur.

STAGE II LESIONS

The patient is usually symptomatic with shoulder or hip pain, often with axillary nerve referral or groin pain, frequently with obturator nerve referral and muscle spasm. Radiological appearance is that of irregular radiolucencies, often with marginal densification and evidence of reossification without gross architectural complications — *i.e.*, without rupture of the osteochondral joint surface of the humeral or femoral head (Fig. 1). Diagnosis is essential at this stage if chondro-osseous rupture and irreversible damage are to be avoided.

In this stage there is no evidence of secondary subchondral fracture. The radiolucent crescent-line sign is negative.

Revascularization Procedures

There are currently no satisfactory extrinsic revascularization procedures for the humeral head. However, if tomography and intraosseous

Preceding page blank

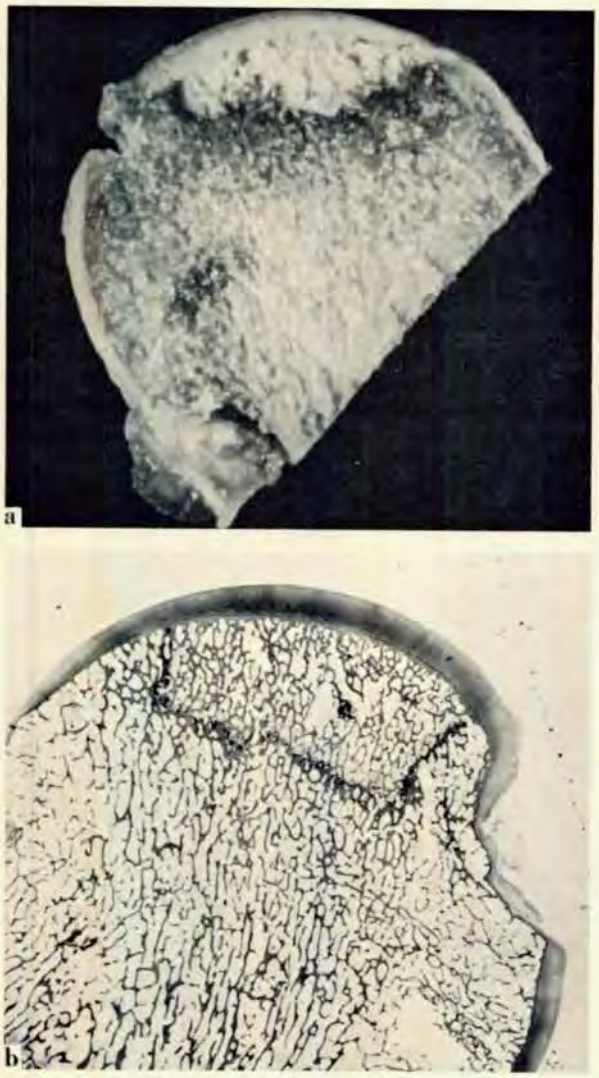

FIG. 1. Gross sagittal section of (*a*) L femoral head, showing Stage II osteonecrosis lesion in anterosuperior quadrant. Chalky necrotic subchondral bone (of toothpaste consistency) is separated from normal bone by dark zone of revascularization. (*b*) R femoral head, at level of fovea centralis, revealing well-demarcated Stage II lesions in superior portion of femoral head, with thickened marginal trabeculae and intertrabecular fibrosis and calcification without gross structural alteration of articular cartilage.

phlebography indicate that the femoral-head cartilage is still intact — *i.e.*, there is no evidence of secondary subchondral fractures — it is still possible, within certain limits, to revascularize segmental necrotic lesions from the cancellous region of the femoral neck. Extrinsic revascularization procedures are possible when the maximum thickness of the necrotic segment does not exceed 15 mm on A-P tomography. If greater than 15 mm, the intrinsic revascularization process will gradually cease and a necrotic area will remain in the subchondral bone (Wagner, 1971).

In an attempt to accelerate the intrinsic revascularization process, the necrotic area in the femoral head is excavated without dislocating the hip joint. Biplane roentgenograms are used to avoid injuring the intact articular cartilage. Wagner (1971) fills the excavated cavity with iliac bone grafts, whereas Bonfiglio and Bardenstein (1958) advocate introducing square-shaped autogenous tibial cortical bone pegs through round holes created in the femoral neck and head. Granulation tissue propagates into the femoral-head lesion through clefts remaining adjacent to the bone grafts.

Jameson (1972) modified the Judet musculo-osseous pedicle transfer (Judet, 1962) for osteosynthesis of femoral-neck fractures in an attempt to revascularize the head (Jones, 1971) (Fig. 2). The quadratus-femoris muscle provides vascularity for the cancellous bone of the intertrochanteric crest, which is introduced through an excavated hole into the femoral-head lesion. Meyers *et al.* (1972) treated 150 displaced femoral-neck fractures with the muscle-pedicle transplant technique and noted a marked reduction in the incidence of late segmental collapse of the head.

With necrotic lesions greater than 15 mm in maximum depth, nonsurgical management is used to protect the shoulder or hip mechanically by *1)* non-weight-bearing or bed rest, with or without traction; *2)* physiotherapy (deep heat and muscle-strengthening range-of-motion exercises); or *3)* muscle relaxants and analgesics. However, D'Aubigne *et al.* (1965) advocated temporary fixation of the acetabulum to the femoral shaft to bypass the head and relieve pressure on it to allow healing.

Boettcher *et al.* (1970) documented five patients treated conservatively by protected weight-bearing in whom the focal necrotic area was small. One patient experienced complete repair without collapse or degenerative change and was asymptomatic at a seven-year follow-up. The hips of the other four patients treated nonsurgically underwent progressive collapse.

Of 38 necrotic femoral heads repaired by drilling and bone-grafting techniques (Phemister,

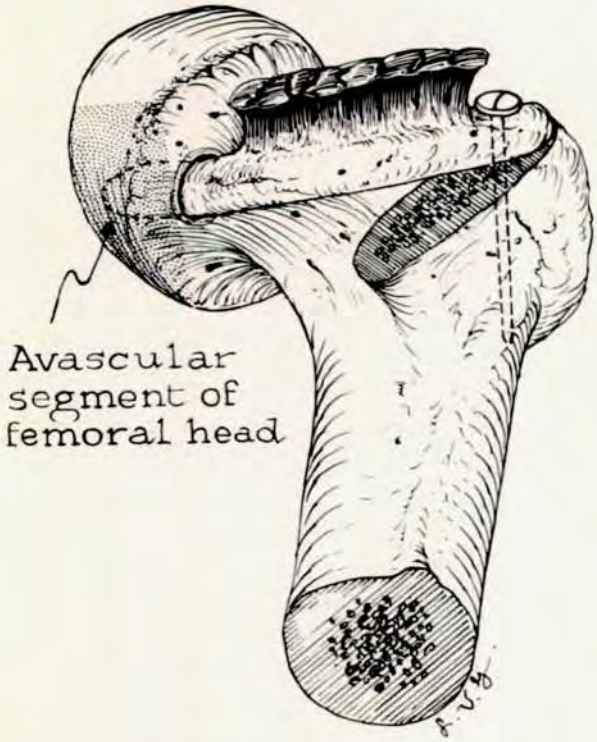

FIG. 2. Judet musculo-osseous pedicle transfer, as modified by R. M. Jameson (1972) — a procedure performed in attempt to revascularize a previously excised segmental defect in anteroinferior quadrant of femoral head, although most often used for lesions in anterosuperior quadrant. Viable cancellous bone from intertrochanteric crest is nourished by vessels supplying quadratus femoris muscle.

1949), six had a normal joint space with no collapse of the subchondral bone preoperatively. These hips had a higher frequency of good results than did those in which there was minimal or moderate preoperative collapse. Final results following bone grafting or musculo-osseous pedicle transfers will be improved if these procedures are performed before collapse occurs, and if the bone graft or viable bone pedicle is accurately positioned in the femoral head without injuring the articular cartilage.

STAGE III LESIONS

The patient is symptomatic. Roentgenograms — particularly external rotation projections of the shoulder and lateral projections of the hip — indicate architectural failure and structural collapse. Often a unipolar or bipolar subchondral fracture is apparent; the radiolucent crescent-line sign is positive (Fig. 3). Once a break has

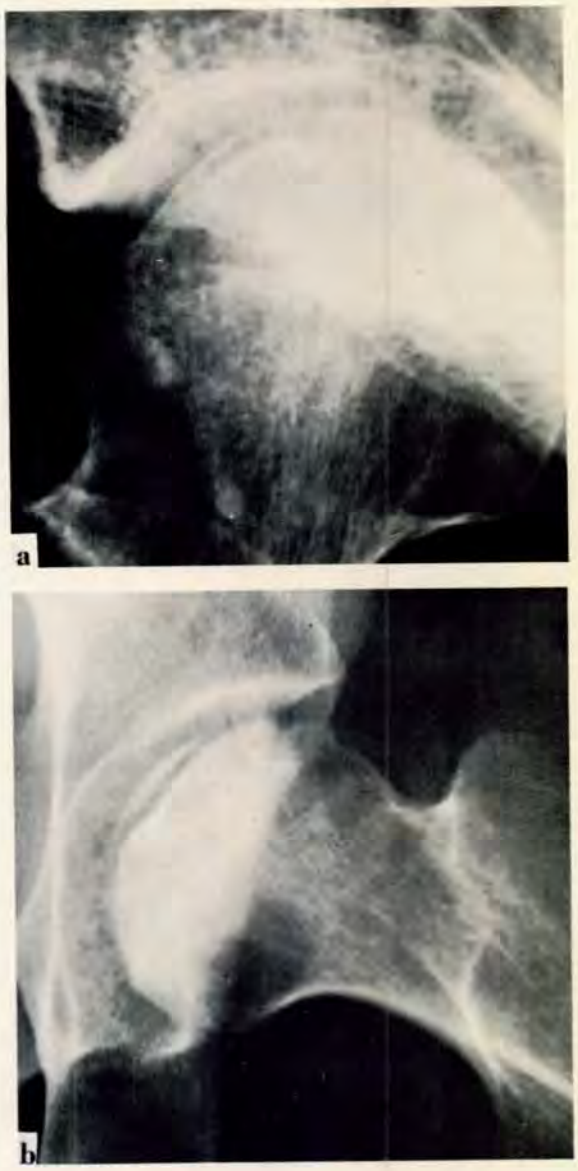

FIG. 3. Lateral roentgenograms of hips with early Stage III osteonecrosis lesions: (*a*) secondary subchondral fracture extending through necrotic bone in anterosuperior quadrant of femoral head in lesion with minimal articular incongruity; (*b*) another positive radiolucent crescent-line sign (translucent subcortical band sign) with dissection of subchondral bone.

occurred in the smooth spherical articular cartilage and subchondral bone, the necrotic lesion is advanced and irreversible. It will inevitably progress to further collapse, with articular incongruity and secondary degenerative changes. Given this damage, the humeral or femoral head is not salvageable (Fig. 4 and 5).

Histological studies indicate that the secondary subchondral fracture propagates through the preexisting necrotic bone and usually extends through the articular cartilage. The margin of the lesion at this stage is principally composed of calcified fibrous tissue interposed between thickened and dead trabeculae.

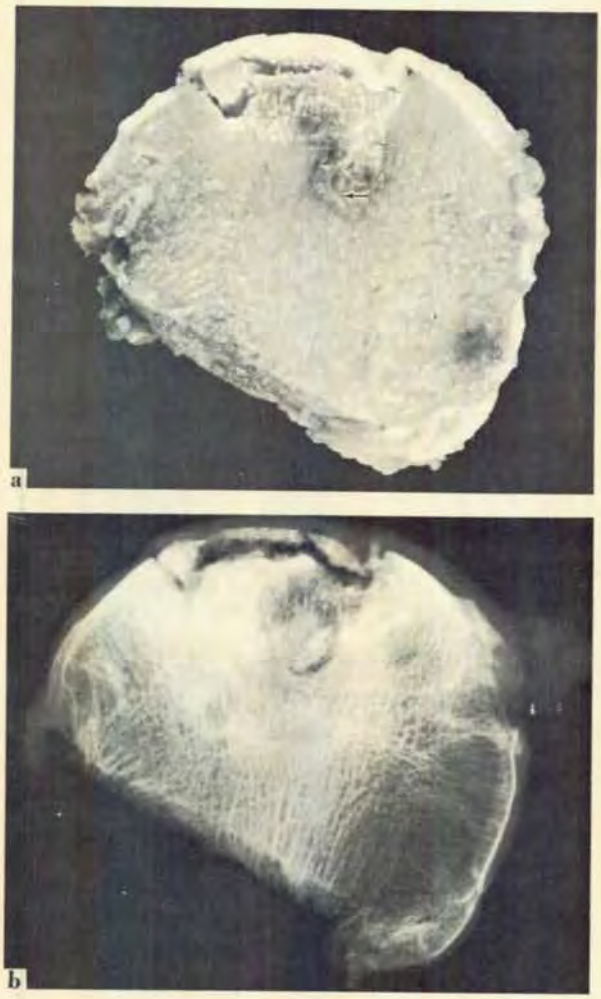

FIG. 4. (*a*) Gross sagittal section of R femoral head, revealing Stage III lesion with subchondral fracture extending through necrotic bone with minimal thinning of cartilage. Small fracture cleft beginning at apex of necrotic lesion is marked with arrow. (*b*) Roentgenogram of same section showing early sequestrum formation with marked osteonecrosis.

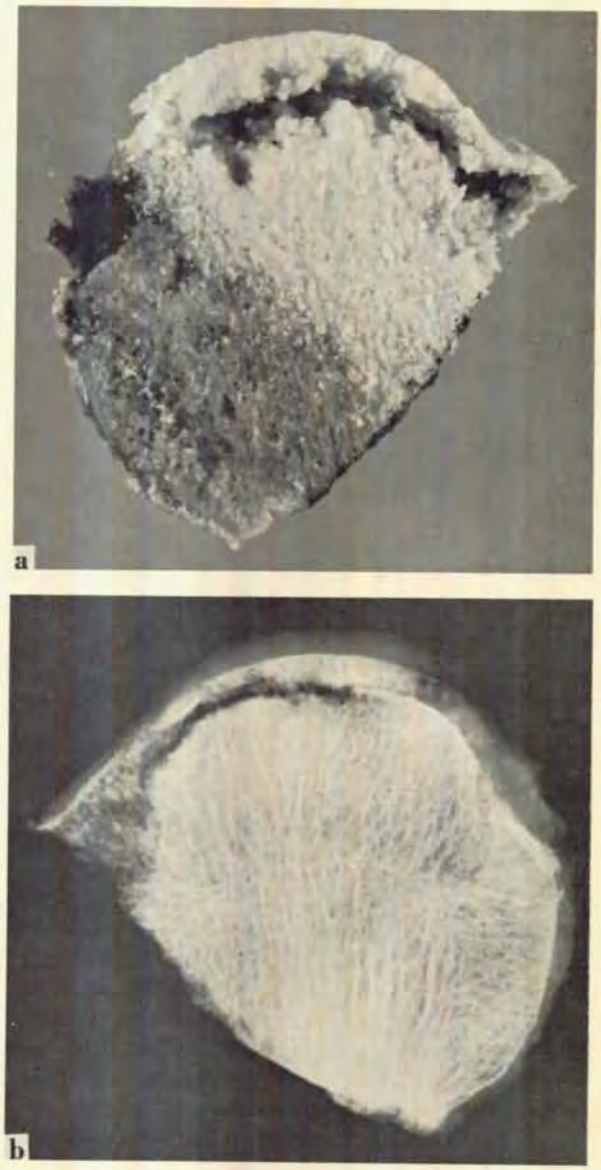

FIG. 5. (*a*) Gross sagittal section of L femoral head, showing large Stage III lesion and extensive subchondral fracture with complete detachment of overlying cartilage; (*b*) high-resolution roentgenogram of specimen showing semilunar fracture.

Once a subchondral fracture develops, osseous fragmentation and sequestrum formation are

progressive (Fig. 6*a*), although the thickness of the articular surface is initially preserved. As subchondral collapse continues, there is subtotal joint destruction (Fig. 6*b*), with advanced

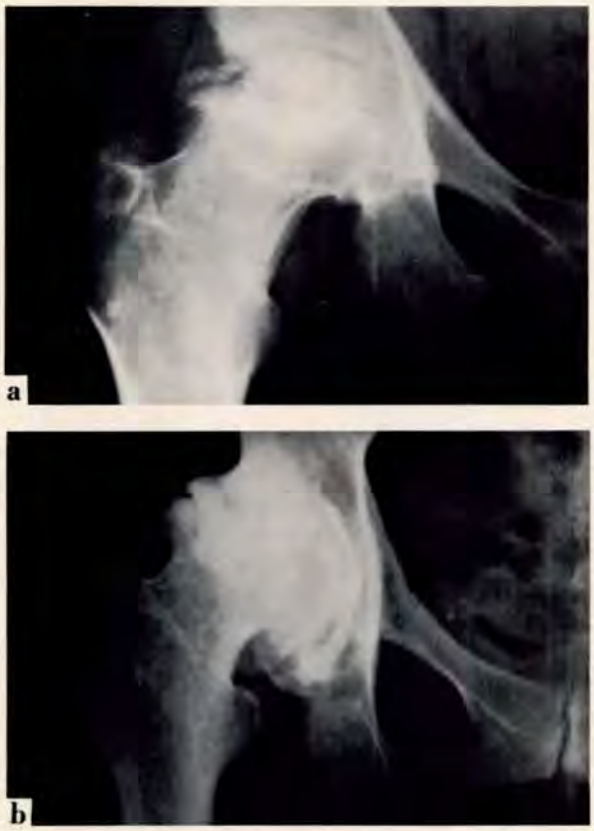

FIG. 6. (*a*) A-P roentgenogram of R hip, indicating Stage III lesion with sequestrum formation. There is central depression and collapse of superior weight-bearing cortex, with marginal osteophyte proliferation but fair preservation of joint space. (*b*) A-P roentgenogram of R hip, showing severe Stage III lesions. There are marked secondary degenerative changes involving the acetabulum as well as virtually complete obliteration of joint space, marked hypertrophic proliferation, and lateral subluxation of femoral head.

changes typical of degenerative arthritis — including a narrowed and incongruous joint space, diffuse hypertrophy with extensive marginal osteophytic proliferation, and large degenerative cysts on either side of the joint (glenoid and acetabulum). In prescribing treatment of Stage III lesions, several factors must be considered — the age, sex, occupation, and general health of the patient; his degree of pain, restriction of motion, deformity, and functional capacity; and the possible bilaterality of the lesions.

Shoulder Joint

Two principal surgical procedures are available for Stage III lesions of the shoulder: hemiarthroplasty with prosthetic replacement, and arthrodesis.

Hemiarthroplasty. In this procedure the humeral head is replaced with a metal prosthesis, which is maintained within the humeral shaft by a stem (Neer, 1963). However, this approach is not advised if there is significant arthritis of the shoulder joint (coxarthrosis) because the glenoid is not altered by the surgery. Satisfactory range of motion and muscle power are often regained following intensive physiotherapy, which is important in those laborers who are required to work with arms lifted.

Arthrodesis. Arthroplasty is not indicated when necrotic lesions of the humeral head are accompanied by degenerative changes of the glenoid or adhesive capsulitis and fibrous ankylosis of the shoulder joint. Arthrodesis — fixation of joint surfaces by fusion — is functionally superior under these circumstances, and a combined intra-articular and extra-articular procedure is preferred. The most serviceable position for glenohumeral arthrodesis allows sufficient scapulothoracic motion for the arm to fall to the side and traverse a range of motion of 90° abduction, 80° flexion, and 90° internal rotation (Gill, 1931).

Hip Joint

Four major surgical procedures are effective in the treatment of nontraumatic (*e.g.*, dysbaric) osteonecrosis of the hip joint: osteotomy, hemiarthroplasty, arthrodesis, and total hip replacement. Cup (mold) arthroplasty (Johnston and Larson, 1969) is now rarely indicated for osteonecrosis since the functional end result remains unpredictable. The principal reason is that any necrotic bone of the femoral head remaining beneath the cup may continue to die, resulting in progressive absorption, settling, and painful shortening of the femoral neck.

Osteotomy. Osteotomy (McMurray, 1935; and Pauwels, 1965) is designed to create a more satisfactory articulating surface between the femoral head and acetabulum, since more normal cartilage is brought into contact at weight-bearing areas. Romer and Wettstein (1971) per-

formed intertrochanteric osteotomies on 36 patients with idiopathic osteonecrosis. They concluded that the results were good in 65% of patients with unilateral hip disease and in 50% of those with bilateral necrosis of the femoral head. In their opinion the varus osteotomy usually has a better final result than the valgus osteotomy.

Osteotomy often relieves hip pain by producing more diffuse loading stresses on the femoral head. It is indicated for those patients having early Stage III lesions of dysbaric osteonecrosis with structural failure, and for young patients in whom arthrodesis may be undesirable. Pauwels's method of preoperative evaluation and the use of a compression device for internal fixation are essential in an osteotomy.

Arthrodesis. This procedure is indicated in young working men with unilateral involvement, since partial or total prosthetic-replacement arthroplasties are usually not performed in patients under 50 years of age. However, arthrodesis is difficult. The avascular femoral head does not contribute substantially to a solid fusion, so that fibrous rather than bony ankylosis often results. Arthrodesis is often the preferred treatment for younger patients, because a total hip arthroplasty may later be performed with satisfactory results.

Arthrodesis provides a stable and pain-free hip for the vigorous individual who must work while on his feet. Degenerative arthritis of the ipsilateral knee and low back complicates hip arthrodesis, especially as the patient becomes older. Of course, arthrodesis is contraindicated in individuals with bilateral hip disease, which is a frequent occurrence in those exposed to dysbaric phenomena. The possibility of subsequent involvement of the opposite hip should therefore be taken into account.

Hemiarthroplasty. The diseased femoral head is replaced with a metal ball, which is maintained in the shaft by a stem. The device was originally developed by the Judet brothers (1950); since then, several other devices have been used, including the Austin Moore, Thompson, and Eicher endoprostheses.

This procedure is indicated for those individuals with severe, extensive involvement of the femoral head when the acetabulum is normal. The prognosis in hemiarthroplasty is affected by acetabular cartilage deterioration resulting from unsatisfactory prosthetic ball and acetabular fit; imperfect sphericity on surface finish; the necessity for satisfactory acetabular subchondral support to prevent migration of the prosthesis; and variability in the prosthetic materials. The prognosis is further influenced by prosthetic loosening in the femoral shaft resulting from torque at the stem tip, a mismatch of the modulus of elasticity, unsatisfactory stem length, and associated systemic disease, particularly osteoporosis.

The reasons for failure of this procedure are important, since either the prosthesis loosens or sinks into the femur or it protrudes into the acetabulum, or both. The approach therefore has no place in present-day treatment of osteonecrosis when secondary degenerative arthritis is present (Fig. 6*b*). Salvati and Wilson (1972) evaluated 195 patients with noncemented femoral-head replacements for an average follow-up period of 9.6 years. They observed the best results in patients operated on for necrosis of the femoral head with intact acetabular cartilage.

Arthroplasty. Total hip replacement (both femoral-head and acetabulum) is indicated in those patients over 50 years of age in whom severe collapse of the femoral head is accompanied by secondary degenerative changes involving the acetabulum. Such changes include narrowed and incongruous joint spaces, with extensive osteophyte and cyst formation and lateral subluxation of the hip joint. Charnley (1970*b*), McKee and Watson-Farrar (1966), and Ring (1971) have developed this operation to its present usefulness. Results of total hip arthroplasty in patients with complicated Stage III osteonecrosis are very encouraging, since there is virtually complete relief of pain, restoration of stability, and good motion postoperatively. Hip pain is eliminated because all movement is between the insensitive surfaces of the prosthetic parts. Painful reactive sclerosis and pelvic migration of the femoral component are prevented, and the dimensions of a normal hip joint are often restored.

Methyl methacrylate is used for bonding the components. It prevents motion, loosening, and settling of the prosthesis. Furthermore, it distributes the pressure of superincumbent weight and abductor-muscle tension more evenly to the pelvis and femur, thus avoiding high stress points that may be painful. Combined prostheses are of two kinds. One is high friction — *e.g.*, the Tronzo and McKee-Farrar devices (Fig. 7), with metal-to-metal contact. The other is low friction — *e.g.*, the Charnley-Müller, Aufranc-Turner, and Charnley devices, which use a metal femoral component and a high-density polyethy-

FIG. 7. (*a*) A-P view of R hip showing McKee-Farrar total hip system installed; (*b*) McKee-Farrar total hip system with modified Thompson femoral component, a high-friction, metal-to-metal device. (Photographs courtesy of Zimmer USA, Warsaw, Indiana 46580.)

lene acetabular component, each securely fixed to the bone with methyl methacrylate.

Harris (1972) has introduced another total hip system in which the acetabular component is replaceable and may be installed in patients under 50 years of age, a previous contraindication to total hip replacement. Charnley (1970*a*) has found no significant untoward effects from Simplex P bone cement, a pharmacologically inert and insoluble polymer, in over 12 years of clinical application. Simplex P is compatible with tissues, and instances of sensitivity or tissue response to the cement have been extremely rare.

The prognosis in total hip-replacement arthroplasty is dependent upon the wear characteristics of the components, the adequacy of skeletal fixation, and the patient's tolerance of prosthetic debris. But currently there is every indication that a satisfactory total hip-replacement arthroplasty should last for approximately 20 to 25 years. The Ring and Sbarbaro total hip implants are not secured with bone cement and their longevity is yet to be established.

Results of total hip arthroplasty are very encouraging. The hip can be scored with respect to function, pain, stability, limp, and motion, according to the method of Harris (1969); a score of 100 is a perfect or normal hip. Coventry *et al.* (1972) reported a preoperative score of 45.0 and a postoperative score of 89.4 for 333 hips, the conditions of which were followed one year or longer.

SUMMARY

Treatment of nontraumatic (*e.g.*, dysbaric) osteonecrosis has been correlated with clinical, radiological, and pathological stages of progressive involvement of the shoulder and hip joints. There is minimal well-documented evidence to indicate that conservative nonsurgical methods result in spontaneous healing of Stage I and II lesions. Revascularization procedures are indicated for certain Stage II but not for Stage III lesions.

Arthrodesis and intertrochanteric osteotomy of the hip are indicated in patients under age 50 with Stage III lesions and unilateral hip disease, but postoperative rehabilitation is pro-

longed and the final functional results are uncertain. Hemiarthroplasty of either shoulder or hip joints is the treatment of choice when there is no significant arthritic involvement. Arthrodesis of the shoulder and total replacement of the hip are indicated in those individuals with severe Stage III lesions and severe secondary degenerative arthritis.

REFERENCES

Boettcher, W. G., Bonfiglio, M., and Smith, K. (1970). Non-traumatic necrosis of the femoral head: Part II. Experiences in treatment. J. Bone Joint Surg. 52-A, 322-329.

Bonfiglio, M., and Bardenstein, M. D. (1958). Treatment by bone-grafting of aseptic necrosis of the femoral head and non-union of the femoral neck (Phemister technique). J. Bone Joint Surg. 40-A, 1329-1346.

Charnley, J. (1970*a*). Acrylic Cement in Orthopaedic Surgery. 131 pp. Edinburg: Livingstone.

Charnley, J. (1970*b*). Total hip replacement by low-friction arthroplasty. Clin. Orthop. 72, 7-21.

Coventry, M. B., Beckenbaugh, R. D., and Nolan, D. (1972). Experience with two thousand Charnley total hip arthroplasties. J. Bone Joint Surg. 54-A, 1357.

D'Aubigne, R. M., Postel, M., Mazabraud, A., Massias, P., and Gueguen, J. (1965). Idiopathic necrosis of the femoral head in adults. J. Bone Joint Surg. 47-B, 612-633.

Gill, A. B. (1931). A new operation for arthrodesis of the shoulder. J. Bone Joint Surg. 13, 287.

Harris, W. H. (1969). Traumatic arthritis of the hip after dislocation and acetabular fractures: Treatment by mold arthroplasty: An end-result study using a new method of result evaluation. J. Bone Joint Surg. 51-A, 737-755.

Jameson, R. M. [1972]. Unpublished data.

Johnston, R. C., and Larson, C. B. (1969). Results of treatment of hip disorders with cup arthroplasty. J. Bone Joint Surg. 51-A, 1461-1479.

Jones, J. P., Jr. (1971). Alcoholism, hypercortisonism, fat embolism and osseous avascular necrosis. In Idiopathic Ischemic Necrosis of the Femoral Head in Adults. Chapter VIII. pp. 112-132. Ed. Zinn, W. M. Stuttgart, Germany: Thieme.

Judet, J., and Judet, R. (1950). The use of an artificial femoral head for arthroplasty of the hip joint. J. Bone Joint Surg. 32-B, 166-173.

Judet, R. (1962). Traitment des fractures du col du femur par greffe pediculee. Acta Orthop. Scand. 32, 421-427.

McKee, G. K., and Watson-Farrar, J. (1966). Replacement of arthritic hips by the McKee-Farrar prosthesis. J. Bone Joint Surg. 48-B, 245-259.

McMurray, T. P. (1935). Osteoarthritis of the hip-joint. Brit. J. Surg. 22, 716-727.

Meyers, M. H., Harvey, J. P., Jr., and Moore, T. M. (1972). Treatment of displaced fractures of the femoral neck with the muscle pedicle transplant technique: A prospective study and analysis of 150 cases. J. Bone Joint Surg. 54-A, 1351.

Neer, C. S. (1963). Prosthetic replacement of the humeral head: Indications and operative technique. Surg. Clin. N. Amer. 43, 1581-1597.

Pauwels, F. (1965). II. Basis and results of an etiological therapy of osteoarthritis of the hip joint. In IXeme Congress de la Societe Internationale de Chirurgie Orthopedique et de Traumataologic. Part 2. pp. E31-E50, T51-T84. Vienna: Verlag der Wiener Medizinischen Academia.

Phemister, D. B. (1949). Treatment of the necrotic head of the femur in adults. J. Bone Joint Surg. 31-A, 55-66.

Ring, P. A. (1971). Replacement of the hip joint. Ann. Roy. Coll. Surg. 48, 344-355.

Romer, U., and Wettstein, P. (1971). Results of treatment of eighty-one Swiss patients with IINFH. In Idiopathic Ischemic Necrosis of the Femoral Head in Adults. pp. 205-212. Ed. Zinn, W. M. Stuttgart, Germany: Thieme.

Salvati, E. A., and Wilson, P. D., Jr. (1972). Long-term results of femoral head replacements. J. Bone Joint Surg. 54-A, 1355-1356.

Wagner, H. (1971). Treatment of idiopathic necrosis of the femoral head. In Idiopathic Ischemic Necrosis of the Femoral Head in Adults. Chapter XIV. pp. 202-204. Ed. Zinn, W. M. Stuttgart, Germany: Thieme.

DISCUSSION 9

Dr. WORKMAN: I have a question for Dr. Walder. Regarding his films showing the progress of lesions, I wish to know whether these men were exposed to pressure between the time that repeat X-rays were taken and when progress of the lesions was noted.

Dr. WALDER: Some of the men were exposed and some were not. The man with a screw in his shoulder continued working for at least a year after the first changes had been noted. At that time we had not really formulated a precise plan of what to do in these cases. Since then, we have stopped men with juxta-articular lesions from working in compressed air over 18 psi, and we continue to follow them up even when they cease working in compressed air.

Dr. WRIGHT: We are concerned about what to do if we find these lesions in our experimental divers. I am sure that we shall have to stop their doing further experimental diving if we find juxta-articular lesions, but I wonder about lesions remote from the joints. Do we know enough now to predict whether or not they will progress with further diving? Dr. Kindwall mentioned earlier that he allows his compressed-air workers with these lesions to continue work. What do you do in the British Navy or about British tunnel workers?

Dr. ELLIOTT: We have given much thought to this difficult question. The RN is a somewhat protected environment in which there are perhaps better opportunities to deal with these problems than in the commercial world. We follow the principle that shaft lesions, even though they have no clinical significance, do demonstrate the individual's susceptibility to some form of bone damage. We therefore perhaps err on the side of caution, prohibiting any oxy-helium or unduly hazardous diving but allowing the man to continue normal diving.

Our only professional category of diver dives to 250 ft and shallower depths on air within what is known as a "limiting line," which establishes the maximum duration for each depth relative to the estimated safety of the decompression schedule for that exposure. This is the "normal diving" permitted men with shaft lesions. As Prof. Walder has stated, subject to orthopedic review we confine men with juxta-articular lesions to 100%-O_2 diving, enabling them to perform some useful duties without exposing them to any great decompression hazard.

Dr. KINDWALL: Even though workmen's compensation and related litigation are rampant in the United States, I feel justified in allowing men with shaft lesions to go back into the tunnel because they are going back to a different situation from the one in which they developed necrosis. We now use the Seattle tables and no case of necrosis has been reported in the last five years. But the situation in commercial diving is different. If a diver who develops osteonecrosis returns to diving, exposure and decompression procedures remain the same. Therefore the risk is unchanged.

Dr. SEALEY: Two or three suspicious shaft lesions were reported among our men, none of which, as far as I know, has developed. As long as a man had only suspicious shadows that one could not even categorize, we allowed him to continue working in air.

Dr. MILES: Dr. Jones has described how a point-sensitive counter introduced into an avascular area shows essentially no radioactive phosphorus uptake relative to surrounding areas. I said earlier that necrotic bone

will take up the isotopes within the hydration shell if it is well perfused. But if the host bone has walled off the necrotic area, there obviously will be no pickup there. On the other hand, when the counter is withdrawn and then reintroduced, counts are obtained within the necrotic segment. Drilling into that area opens it up and permits it to be adequately perfused with radioactive isotope.

A conference on necrosis of the femoral head was held in St. Louis in January 1964, sponsored by the Surgery Study Section, NIH, Bethesda, Md. Several methods of detecting avascular necrosis with radioactive tracers were presented, including several aimed at incorporation of the isotope into the bone crystal itself. It was hoped that if the bone was actively metabolizing, it would accept such tracers as phosphorus, strontium, or fluorine. These methods proved to be inaccurate.

The results of other methods of detecting avascular necrosis discussed at the conference — *e.g.*, tagging various elements of the circulation, radiographic techniques, intraosseous arteriograms, and intramedullary pressure measurements — were also conceded to be inaccurate. At the end of the conference it was agreed that no one had a good method for determining avascular bone necrosis. This conclusion produced at least one very good result. The NIH study section concerned had been receiving upwards of 100 grant proposals a year for research projects on avascular osteonecrosis. It received only two such requests the next year, and one the next; it has not been bothered since.

I should like to discuss the bone-graft method of treatment for a moment. In his pioneering work Phemister (1949) noted that when a Smith-Peterson nail was introduced into the femoral head in treatment of a femoral-neck fracture, replacement proceeded rapidly along the flanged nail up into the necrotic head. Phemister therefore tried drilling a core of bone out of the femoral head to provide a pathway for rapid revascularization or replacement. He believed that it was necessary to cut the core through the articular cartilage, which Dr. Jones avoids doing, and to direct the plug into an area remote from the weight-bearing surface of the acetabulum in order not to damage the surface. He then put a tibial bone graft in the hole — a square peg in a round hole — leaving channels open for ingrowth of vessels to aid replacement. Orthopedic surgeons who plug the hole as solidly as possible with bone graft are not following the Phemister technique.

Finally, I want to point out a simple difference between the upper and lower extremities. The function of the upper extremities is mobility and that of the lower ones, stability. We therefore favor any operative procedure that will maintain mobility of the shoulder joint — such as resection of the proximal end of the humerus — so that the patient is left with pseudoarthrosis and motion. The joint is unstable, of course, but it preserves the major function of the upper extremity.

Since stability is the aim of surgery of the lower extremity, replacement prostheses for the hip joint are much more highly developed and function much better than shoulder prostheses do. As Dr. Jones has outlined, total hip arthroplasty has thus become a fairly standard procedure (thanks to the British), and we may expect it to be used more frequently.

Mr. EVANS: I have two questions for Dr. Jones. First, are all the beautifully excised femoral heads that you have shown us examples of caisson's disease, or are some of the lesions the result of other forms of aseptic necrosis? Second, has he done any histopathological studies on them to outline the areas that were previously damaged but have repaired themselves in the manner demonstrated by Prof. Walder?

Dr. JONES: In response to the first question, all the pathological specimens involving femoral and humeral heads were taken from patients with nontraumatic conditions associated with avascular necrosis other than dysbaric osteonecrosis. Jaffe (1972) presents an excellent pathological correlation of the skeletal manifestations of the decompression-sickness syndrome.

In response to the second question, I agree with the sequence of events that Prof. Walder has outlined. Pathological analysis of surgical specimens with osteonecrosis usually indicates some evidence of revascularization with appositional new-bone formation. Granulation tissue resorbs dead bone and marrow debris, and deposits cocoons of new trabeculae on dead ones — but only for a certain distance. The reparative process can only go so far, as it may outgrow the blood supply. Therefore, the potential for complete revascularization is limited.

If the patient is young and the avascular lesion is relatively small (less than 15 mm maximum diameter), the reparative process might extend up to the subchondral bone, repairing and revascularizing the entire lesion. But in larger lesions, or lesions resulting from repetitive vascular insults, there may be a "coalescence" of the focal lesions, which are being individually repaired, and a massive lesion may develop that is not capable of being completely revascularized.

Dr. MILES: Dr. Jones has said that replacement "can only go so far." I might say that replacement *does* only go so far. There may be some barriers to replacement, or mechanical or age factors that prevent complete and perfect replacement. We know that in the younger age groups replacement is much better.

REFERENCES

Jaffe, H. L. (1972). Skeletal manifestations of decompression sickness. In Metabolic, Degenerative, and Inflammatory Diseases of Bones and Joints. pp. 659-673. Ed. Jaffe, H. L. Philadelphia: Lea and Febiger.

Phemister, D. B. (1949). Treatment of the necrotic head of the femur in adults. J. Bone Joint Surg. 31-A, 55-66.

PART VIII

VALUE AND FUNCTION OF A MEDICAL REGISTRY

Preceding page blank

MEDICAL REGISTRY FOR BONE NECROSIS IN ENGLAND

R. IAN MCCALLUM
ANTHONY EVANS

The concept of a disease registry is not new. Such a registry for beryllium workers has been in operation in the Massachusetts Institute of Technology since 1952 (Hardy, Rable, and Lorch, 1967). An "exposure to risk" registry (Society of Occupational Medicine, 1971), in which data on all the men employed in a particular industry and on their working environment are collected over a prolonged period of time, is a much broader concept and much more difficult to set up. The Decompression Sickness Central Registry was formed in England in 1964, originally to gather information on compressed-air workers and the contracts under which they were employed. It now includes similar data on divers. The important feature of this Registry is its independence. Not only is it financed by the Medical Research Council, which is a semi-independent body, but also it is situated in a university and may be approached by anyone for information.

The Registry is run by Dr. Philip Griffiths (1971) who brings to it unique attributes, particularly his intimate knowledge of the practical side of compressed-air work and of the tunnelers themselves. The information amassed in the Registry is extremely varied. First of all, there are many personal details about the tunnel workers that help to identify them over a long period, during which they may be employed by different firms in different parts of the country or abroad. There are, for example, 20 Pat Gallaghers on record, and distinguishing one from another on a particular contract may not be easy. The individual records include such particulars as date of birth and occupational background. But as the Registry also maintains details of a strictly medical nature, identification may be assisted by, for instance, radiological peculiarities. Additionally, a signature is obtained on the medical examination form so that a man may be identified from his handwriting. Finally, it is sometimes possible to cross-check with his previous experience in different contracts and different types of work.

The Registry holds most of the recent records of decompression-sickness attacks suffered by those British compressed-air workers who have been treated in a pressure chamber. There is a fairly detailed account of each incidence of bends or Type II decompression sickness, including the working pressure to which the man was exposed beforehand, exposure time, and the type of compression or other therapy used. In addition to a large number of bone radiographs of compressed-air workers and divers, there are on file many chest radiographs taken when the problem of cysts in lung tissue was being investigated (Decompression Sickness Panel, 1971). Autopsy reports are on record for some of the men who died from Type II decompression sickness or air embolism.

Still other information has been gathered on various tunneling contracts. Figure 1 shows the complexity of pressure levels during construction of the Clyde tunnels in Glasgow. Details of all the workers are recorded for the five-year period of that construction project, together with records of their compressions and decompressions, so that the compressed-air experience of any particular man on any particular day is available. With this sort of information the problem occasionally arises of men who are listed as having entered the tunnel but not as having come out, and of men who came out but apparently never entered!

Even in a simple contract of shorter duration (Fig. 2), a large amount of data is collected. Once more, each man's pressure–time exposure is recorded for every day of the contract.

Rather more exotic information is sometimes gathered. In the Tyne tunnel project, for example, complaints were made about water seeping through a work face and causing skin trouble. The matter was investigated and the following pH levels measured:

Preceding page blank

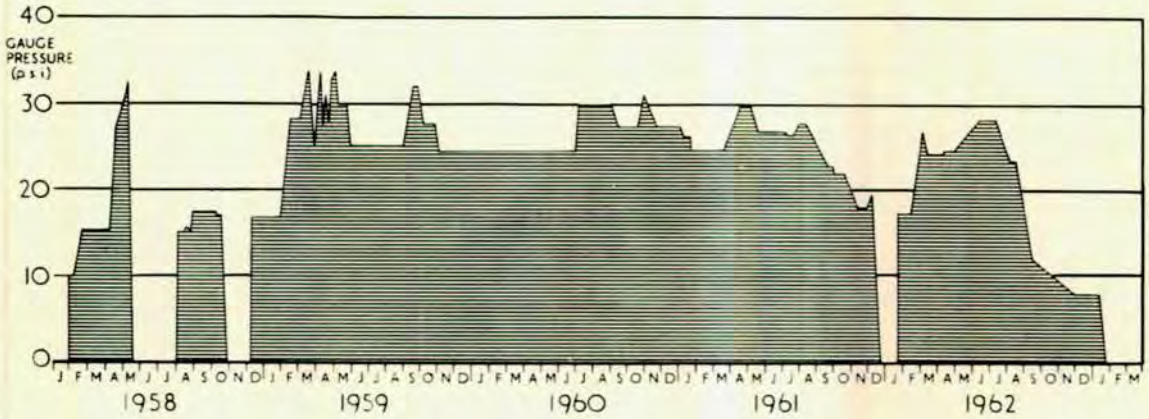

Fig. 1. Pressure exposures experienced by compressed-air workers during construction of two road tunnels under the River Clyde at Glasgow, Scotland.

Sample of Mud	pH
Top seam	7.0
Middle seam	7.5
Bottom seam	11.5
Water extracted from top seam	7.5

On further inquiry it was discovered that quantities of alkaline waste from a chemical plant had been dumped in the area many years earlier.

Obtaining details about the working environment of an individual contract does, of course, require access to various data that belong to the contractor, but contractors have been consistently cooperative. The Registry has designed special forms on which are recorded the medical and other information collected. With the cooperation of the construction firms, the Registry arranges radiographic examinations of the long bones of men working at a contract. But once the contract is finished, follow-up examinations often involve much searching; needless to say, some men are difficult to trace. Furthermore, as radiography has to be arranged in different parts of the United Kingdom, it is necessary to make sure that radiographers understand the type and quality of films needed.

Over a period of time a serial record can be built up of the medical and environmental data relating to men who have worked regularly or intermittently in compressed air. During this time they will probably have moved from one

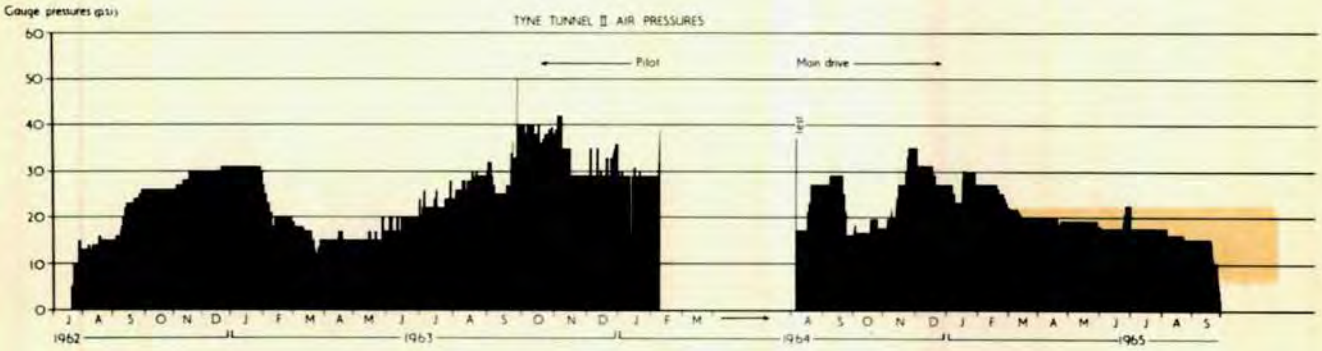

Fig. 2. Pressure exposures experienced by compressed-air workers during construction of a road tunnel under the River Tyne near Newcastle, England.

employer to another as they are employed for contracts in different parts of the country or overseas. It is less easy to acquire long-term follow-up data on men who leave compressed-air work altogether after a brief experience of it. But the two or three years following exposure are probably the most important ones for radiographic examination of bones; if osteonecrosis is going to occur, it will most likely become visible in radiographs made during this time.

The amount of information amassed over the years at the Registry has now grown to such proportions that extraction of specific data — for example, for statistical analysis — has become very time-consuming and inefficient. Consequently, the records are now being translated into machine-readable form for storage and analysis by computer.

The following figures give some indication of the extent of the data available at the Registry. On February 4, 1972, records were being maintained of 9363 British compressed-air workers and 268 commercial divers working for British companies. Of these, 1688 compressed-air workers have had at least one full radiological survey of their joints, and many have had several, making a total of 2464 sets of films. Of these, 200 may be regarded as controls, since they were taken in the course of the preemployment examinations of men without previous exposure to raised pressure. The joints of 229 of the divers have been examined on one or more occasions, for a total of 272 sets of films. In all, the Registry held about 19,000 individual X-ray films in early 1972.

For each contract involving compressed-air work, the Registry typically has on file an initial medical-examination form and an air record for each man. The individual air record is quite comprehensive, showing the pressure and duration of each exposure as well as the occurrence and severity of each attack of decompression sickness. These records have been prepared laboriously by hand from the contract man-lock registers, which are the exposure records that British contractors are obliged by law to keep. Separate records are held of the treatment given following each incidence of decompression sickness occurring during the contract.

All this information, or as much of it as can be considered significant and accurate, is now being transferred by coders onto standardized forms from which punched cards will be prepared so that the data can be transferred to computer storage. The data for many earlier contracts are fairly limited, because only brief initial medical-examination forms are held; but ample provision has been made for storing greater numbers of data in future.

The form shown in Fig. 3 records a man's initial medical examination at the start of work on a new contract. It records blood pressure,



FIG. 3. Standard form and codes used in the Computer Data Bank Project (Decompression Sickness Central Registry) for the initial medical examination of compressed-air workers in the United Kingdom.

standing height, and weight. There was some discussion about including sitting height, which was in fact recorded on at least one recent contract in connection with measurements of leg length. However, since analysis of these data revealed nothing significant, this measurement has been omitted. Skinfold I and II refers to certain examinations conducted at the Tyne tunnel (Decompression Sickness Panel, 1971). Skinfold thickness measurements with Harpenden skin calipers at two sites (arm and back) have confirmed the view that a man's susceptibility to decompression sickness is related to amount of body fat.

A unique 4- or 5-digit number is used to identify each man's records in the computer files. Since the form (Fig. 3) contains not only a code name for the contract but also the employee's works number on that contract, his records can be identified from the number, which is often used in the man-lock registers rather than a name.

In Fig. 4 are shown the forms for two alternative methods of tabulating a compressed-air worker's daily hyperbaric exposure. The upper form, already in use, is prepared from existing individual air records. Considerable coding is obviously involved in thus recording each man's daily experience. Even if the date is reduced to four digits, as shown, 11 marks per exposure must be made, and on a long contract there may be several hundred exposures per man.

With the proposed alternative method (lower form, Fig. 4), which it is hoped to develop in the future, it may be possible to reduce the labor of coding by at least 50%. The initial section merely records the contract and day involved. A daily record can then be kept in terms of lockfuls of men, so that a number after the entry *decompression* will indicate whether it is the first, second, or subsequent one occurring on that 24-hour calendar day. For a given decompression it is only necessary to record the men's works numbers, because all of them will have been decompressed together. Length of exposure will be recorded; in some instances exposure times will be the same, but in others, not. Each form will give the maximum working pressure, whether decanting occurred, the pressure at the start of decompression (which is not always the same as maximum pressure), the time at which it began, the table used, the time at which the chamber door was opened, and details of any cases of decompression sickness that occurred and the treatment administered.



Fig. 4. Alternative forms for tabulating daily hyperbaric exposures: (*above*) individual record of a compressed-air worker currently used by the U.K. Central Registry; and (*below*) the proposed man-lock record of daily hyperbaric exposure.

This alternative method of record-keeping by contract-day is still at the development stage. Currently we are manually abstracting data from

DETAILS OF X-RAY EXAMINATION

Number	
Date of X-ray	
Any necrosis?	
Right shoulder	
Left shoulder	
Right hip	
Left hip	
Right lower femur	
Left lower femur	
Right upper tibia	
Left upper tibia	

Codes

Any necrosis?

3. Positive
2. Suspect
1. No decision
0. Negative

Lesion

9. Not examined
6. Operation - evidence of
5. Broken articular surface
4. Positive juxta-articular
3. Positive medullary
2. Suspect juxta-articular
1. Suspect medullary
0. Normal

FIG. 5. Standard form and codes used by the U.K. Central Registry to record the results of individual radiological examinations of compressed-air workers.

individual man-lock records; by contrast a tentative calculation suggests that, by the alternative method, recording the experience in an average contract of 50,000 man-decompressions should require only about 25% as much coding.

On the form in Fig. 5 — the one of primary interest to this Symposium — are recorded the results of each individual's skeletal bone survey. If there is no necrosis, a zero is entered in the third space; no further marking on that form is then necessary. If necrosis is detected, the appropriate code number is given. Each of the eight remaining blanks must then be filled in according to the lesion code number. Both codes are detailed on the lower portion of the form.

The full A1–5 and B1–4 classification already discussed in these Proceedings is not used at present. But it could easily be incorporated by introducing letter codes, if such refinement were considered necessary.

Obviously there will be no great difficulty in extending the computer-data analysis to the divers covered by the Registry. Their experience will have to be recorded in a slightly different way, because each man's is individual. The variables listed in Part 3A would therefore have to be modified accordingly. But the radiographic examinations and initial medical-examination reports that we already have can be coded and analyzed in exactly the same way.

REFERENCES

Decompression Sickness Panel, Medical Research Council. (1971). Decompression sickness and aseptic necrosis of bone. Brit. J. Ind. Med. 28, 1-21.

Griffiths, P. D. (1971). An exposure to risk registry for compressed air workers. Trans. Soc. Occupational Med. 21, 123-125.

Hardy, N., Rable, E. W., and Lorch, S. (1967). United States Beryllium Case Registry 1952-1966: Review of its methods and utility. J. Occupational Med. 9, 271-276.

Society of Occupational Medicine. (1970). An exposure to risk registry: A memorandum prepared by the Research Panel of the Society. Trans. Soc. Occupational Med. 21, 103-108.

PROPOSAL FOR AN OSTEONECROSIS REGISTRY IN THE UNITED STATES

H. WILLIAM GILLEN

Is a registry needed for aseptic bone necrosis and/or for people who dive professionally? If so, where will the information come from, and then, who will pay for collecting and recording it?

The population at risk in the United States, combining professional divers and caisson workers, is perhaps 5000 men. While the number is not known precisely, it is small compared with the numbers in other industries who are exposed to similar occupational hazards. This disparity must be considered, because there is only a certain amount of time and money available to be spent in collecting data on a single group of individuals for any one purpose.

What kind of information is needed to set up a registry not only of osteonecrosis but also of employment experience in a hyperbaric environment? The person must be identified and his past medical history recorded. Because there is still no general consensus on the etiology of osteonecrosis, many factors will have to be considered so that the reasons why some people get "bone rot" and others do not may eventually be defined. Much initial information will have to be recorded.

In the United States, as is known, such information is confidential and, under normal circumstances, may not be released for public use or even analysis by the individual or organization holding the records. However, under the Occupational Safety and Health Act of 1970, it is possible to require the release of certain information. Perhaps the conditions for release could be expanded to improve the usefulness of the registry.

From a toxicological point of view, much round-figure epidemiology must be considered. Since one does not know what answers are sought after, an almost unlimited number and variety of questions must be asked. Data entries for storage purposes must be broad enough so that information of possible future use will be available.

What benefits might accrue from such a registry? First of all, it might be possible to describe the two groups primarily exposed to hyperbaric pressures — professional divers and tunnel workers — with greater accuracy than is now possible. It would then be known how many people are employed in these industries, what their jobs are, what risks they are exposed to, and what the consequences are of these exposures. Members of the professional diving industry state that their insurance rates are at the maximum because no real information exists to describe what the risks actually are.

The factors or combination of factors causing injuries under hyperbaric exposure are a second kind of information that such a data bank might yield. If the data are adequate and flexible, it should then be possible retrospectively to determine some of the causes related to injuries. There must be good descriptions of the working environments, working conditions, and work experience to make this sort of data bank at all useful.

In the United States at the present time, these data would essentially have to be provided voluntarily, which means that one cannot get the information. It must therefore be collected by regulation and made a requirement of employment. It must then be filed at some central point, so that it can be collated, analyzed, and evaluated. If the information were filed in regional offices, the result would be a dozen different offices doing the same thing. For a bone survey, for example, a man would not receive an employability certificate until X-ray films had been made and filed at a central registry. This approach will probably be necessary if such a registry is to be of any use.

If the data were collected by some form of regulation, there must be some way of protecting and restricting their use by the central registry. Perhaps some of the ideas basic to no-fault automobile insurance could be incorporated. A

Preceding page blank

major prerequisite is that there be employer protection, such as has been extended to mine operators with respect to their employees. Under the federal Coal Mine Health and Safety Act of 1969, the employee is advised if pulmonary lesions are discovered roentgenographically. He then must be moved to a less hazardous environment, above ground, which the employer is obligated to do by regulation. When certain types of abnormalities are revealed by roentgenogram, the miner is automatically pensioned. The whole system is spelled out in the regulations, with the intention of eliminating lawsuits. By contrast, in the diving and tunneling industries at the present time, the employee discusses such matters with no one except his lawyers.

In answer to the first question: yes, there should be a registry, because there is a definable population at risk in a hazardous environment that can be reasonably well described. The population is small enough that a manageable body of data might well supply a variety and quality of information not now available. We have the opportunity at this moment to do something about it.

The second question, "Who will pay for the registry?" must remain, for the present, unanswered.

DISCUSSION 10

Dr. ELLIOTT: Thanks to the initiative of Dr. Jones, a decompression–osteonecrosis data bank for divers was discussed recently in Houston. It was concluded that two separate programs were needed: first, a simplified version, not aimed at perfection, for those who already have some experience, because past history is necessarily unreliable; and, second, a lifelong diving profile on novitiate divers, aimed at completeness. One might hope eventually to have some records on a very few divers over their entire careers. Then one would be able to make a very good retrospective study indeed.

Dr. HARVEY: One group being neglected in discussions of a central registry is the huge number of amateur scuba divers here and abroad. As we learn from a data bank what the risk criteria are, we shall have to educate the public. Some long-range goals of information dissemination are thus inherent in the idea of a central registry.

Since such a diverse group of divers is affected, I think a central registry almost has to be associated with either the Department of Labor or HEW, both of which would have a vested interest. There are several data-collecting centers in the United States — for example, the Navy Diving Accident and Injury Bank at Norfolk and the International Decompression Data Bank at the University of Pennsylvania. But none is ideally suited to establish an osteonecrosis registry (nor, probably, is interested in expanding in that direction at the moment). To get the necessary legal and monetary backing to establish a central osteonecrosis registry, then, a federal agency will have to be associated with the project.

Dr. SEALEY: I have had some experience with the problems associated with the Coal Mine Health and Safety Act of 1969. The Appalachian Laboratory for Occupational Respiratory Disease does have such an organization. Although it could not perhaps legally undertake this project, its methods of identifying, classifying, and recording X-ray findings on computer-readable forms might be of use.

Dr. JONES: Several interested parties from both public and private enterprise attended the small Houston conference regarding a proposed decompression–osteonecrosis data bank. The conclusion was that a data bank established in the United States, with multidisciplinary and international cooperation, would be advantageous for several reasons.

There is a need for reliable liability information concerning the risks of developing osteonecrosis following exposure to dysbaric phenomena. For example, I understand that during construction of the third tube of the Lincoln Tunnel in New York, substantial compensation insurance premiums were paid for every $100 the compressed-air workers received in wages. In the Milwaukee project, I understand that the cost of compensation insurance has become almost prohibitive. For the BART project it was necessary for several insurance companies (Transit Insurance Administrators) to collaborate to underwrite the substantial industrial liability.

I also understand that there is a significant liability problem with private diving firms in the United States. If legislation or incentives of a preventive-medicine nature are established by the Department of Labor or HEW, it will be necessary to convince private diving firms of the advantages of such a registry.

As Mr. Galerne has pointed out, divers employed in navigable waters are considered seamen under the Jones Act and can sue their employers for negligence, rather than accept workmen's compensation benefits. There-

fore, I think we will have to start first with novitiate divers and compressed-air workers, who may constitute the first group to have compulsory, comprehensive preemployment examinations, as Dr. Elliott has suggested. If complete examinations were performed on employees of private diving firms and several lesions were found, the liability of these companies would be substantial. Because the pay scale for experienced divers is also substantial, phasing them into vocational rehabilitation or a retirement program on disability pensions would be quite expensive.

If a decompression–osteonecrosis data bank is established in this country, I believe a consulting group patterned after the MRC Decompression Sickness Panel, which has functioned so effectively in Great Britain, should be formed. Possibly we could become the American arm of the MRC group. This would mean that perhaps quarterly or semiannually the data-bank consultants would meet and review questionable cases and possibly help adjudicate compensation awards. Insurance companies might also participate and, hopefully, insurance premiums would be reduced.

Dr. McCALLUM: All one can say is that the possibility of close liaison in handling information such as this would be most welcome to us in England. I might add a point about disability pensions in England. We have industrial injury benefits, which last for six months. These benefits are distinct from the life pension that may follow in cases of permanent occupational disability.

Dr. Gillen made the point in his presentation that the many factors involved in necrosis make it difficult to decide what sort of data one wishes to collect. We have encountered this problem in determining how much detail should be included in the medical examination of divers or compressed-air workers. There is some danger of flooding oneself with data, with the result that whatever is useful might be completely buried. While the information that we are gathering may seem rather restricted, we are only trying to protect ourselves from being submerged in masses of tables.

Regarding legislative action, we in England have set up our registry on a voluntary basis; one reason is the enormous time lag between deciding if legislation is needed and getting it enacted. We got a bit fed up with talking to officials about revising our compressed-air regulations and took another tack. We are now talking in practical terms about codes of practice.

The basis of this approach is to get professionals in the field to agree to basic minimum standards much higher than government agencies would normally set. Then there is a fair chance of pushing through certain standards as accepted practice. Among these is the use of radiographs of major joints in preemployment examinations. It is already routine for U.K. divers, and we are hoping to persuade civil engineering contractors that it is part of the job to have men X-rayed before they start work.

Legislation may come later, but I do not see how it can ensure follow-up films. Once a man has left a contract, how can one make sure by law that he has his bones X-rayed in two years' time?

Amateur scuba divers present a real problem. We have some contact with them and we will keep information on them in the registry. But they are such unpredictable people that it is difficult to get useable data.

One point that I want to emphasize is the difficulty involved in framing legislation on occupational standards which will ensure the acquisition of data on the problem of osteonecrosis. I suspect that you will have the same troubles in the United States that we encountered in England. When I was here in 1952 there was great pressure to get legislation passed to protect coal miners' health, and it has taken until 1970 to effect it.

Dr. WALDER: As Chairman of the MRC Decompression Sickness Panel, I should like to say that I feel a bit like the young lady who goes out with her boyfriend and instead of being raped receives a proposal of marriage — it is a very pleasant surprise. Of course we would be delighted to help you in any way that we can. I think it is a very good idea because we can each benefit from the other's experience.

I should also like to emphasize what Dr. McCallum has said about legislation. I have a rather gloomy regard for it. Legislation always seems to be terribly cumbersome; and once it's done, it's there for many years. Everyone is loath to alter it in any way. In Great Britain some of us have recently started trying to avoid the need for further legislation by introducing codes of practice. One for diving has just been published, entitled *Principles of Safe Diving Practice*, and another is being prepared *(Medical Code of Practice for Compressed Air Workers)*. The idea is to make it clearly known what should be done. Then, it is hoped, those who do not comply with the standards will be sneered at and, even worse, may suffer in a court of law if action is ever taken against them for negligence.

Mr. FARAH: I represent the International Association of Professional Divers, whose membership numbers somewhat over 400. We have been looking toward some kind of licensing of divers, such as has been discussed here, and of course we would very much like to see something done to stop necrosis. But anybody who has been around our profession at all knows that relations between management and employees have been rather strained, to say the least, over the past few years. It's fine to go around surveying divers for medical and research purposes; but I do not think you are going to convince them that these are the sole purposes for which the information will be used. Divers have seen too many instances when such information has been used in ways other than for their benefit.

Dr. MILES: Our labor unions seem to think that requiring preemployment roentgenograms is like making a man testify against himself. Unions and other organizations in this country would be strongly opposed to preemployment examinations.

Mr. GALERNE: We also face the cost of this physical inspection. Many divers move around from one company to another, and one cannot X-ray every man who is to be employed for only a few days. As an example of another problem, we have in New York absolutely nobody within a radius of maybe 200 miles who is able to look at our X-rays and say definitely if they are all right or not.

In this Symposium I have listened to you gentlemen talking about whether a problem does or does not exist; even *you* do not always agree. If I have a problem some time and go to you, will you give me a positive yes or no? If you say "maybe," I have no choice. I cannot engage the man. He may have a family and need work; but if I give him an X-ray and then take it to somebody who is not sure, I must protect myself and say no. This is a human problem, too. I think we need to work on prevention, because you have not yet said to me what I must do to avoid injury.

Dr. PURDY: We are presently using some of the West Virginia computers for the storage of data in our current occupational health survey of coal miners, and I think the unions are beginning to trust us. NIOSH expects to get its own computer, so we could treat any available osteonecrosis records as confidential. I might add that the amount of data to be stored is less of a problem than actually getting it into the computer. With modern computers there is plenty of space; but you have to figure out

how to get the information into storage easily, which may mean using special forms.

Dr. McCALLUM: I think it is quite clear that we must have some sort of central system, from the employer's point of view as well as from the man's, because he cannot be X-rayed by all and sundry every two or three days. Underlying this discussion has been the different social backgrounds in Britain and the United States. Our unions have a different approach. Compressed-air workers have no specific union in Britain, but the unions representing them do not oppose preemployment examinations. They take the view that such measures are designed to put a man in the right job, depending on his physical capability.

PART IX

ADDITIONAL IMPLICATIONS IN OSTEONECROSIS

MEDICO-LEGAL ASPECTS OF OSTEONECROSIS

JOHN TEED

I shall discuss some of the legal remedies currently applicable to divers in the United States who are suffering from osteonecrosis and how the problem is handled judicially.

The principal remedy available to a diver who sustains a disability as a result of his employment is the so-called Jones Act in combination with the general maritime law. To qualify for relief, an individual must meet certain criteria designating him as a seaman. The term *seaman* has been interpreted so broadly that I have considerable difficulty in imagining a situation in which a diver would not be so classified.

The remedy theoretically imposes a liability upon an employer for negligence or for subjecting a seaman to conditions of unseaworthiness. By negligence is meant the employer's failure to act in a manner that a reasonably prudent employer would under the same or similar circumstances. The second theory, a doctrine of liability without fault, concerns the concept of unseaworthiness, referring to equipment that fails to function as intended.

With respect to the osteonecrosis syndrome, to make a monetary recovery under the Jones Act, a diver must identify a specific incident and attribute to that incident one or both of the concepts of fault — that is, negligence or unseaworthiness. I shall not presume to comment on the medical aspects of osteonecrosis. But the participants of this Symposium are now aware that certain persons appear to have a particular susceptibility to the disease. They may sustain the disability without there having been an identifiable negligent act or omission or an identifiable piece of defective equipment connected with it.

I might add that, if the individual is a seaman, he also has the right to what in law is called "maintenance and cure." This right ensures free medical care and living expenses during the time in which he has not reached maximum recovery. The U.S. Public Health Service provides free medical care for deep-sea seamen, thus satisfying the obligation of cure binding upon a seaman's employer.

A second remedy that a diver may seek under specific circumstances is provided by the Longshoremen's and Harborworkers' Compensation Act. This is a federal compensation statute, administered by the Bureau of Employees' Compensation of the Department of Labor. Its provisions are adjudicated by various deputy commissioners stationed around the country as tribunals. The harborworker, for purposes of this discussion, is defined as a maritime worker who is not a seaman. A man who so qualifies may receive certain compensation benefits, based on whatever disability rating may be adjudicated by the deputy commissioner or by agreement between the insurance carrier and the claimant and/or his attorney.

The third type of remedy that should be mentioned is called a third-party suit. Consider, for example, a diver in the employ of a diving contractor who is working off a vessel owned by a second contractor, such as a pipeline or drilling contractor. Under the law in this instance, the diving equipment becomes an appurtenance of the vessel, and the warranty of seaworthiness applies. A claimant diver may therefore seek compensation from his employer and simultaneously proceed against the second contractor with a negligence or unseaworthiness claim.

To make things more interesting in these cases, the contractor typically comes back against the man's employer with the claim that the employer failed to do his work in a reasonably safe and workmanlike manner, as prescribed by the maritime contractual warranties implied by the law. In effect, the claimant sues the second contractor, who then impleads the employer for indemnity. At the same time, the employer is paying the claimant benefits through his insurance carrier under the Longshoremen's and Harborworkers' Compensation Act. There are currently pending some proposed amendments to the compensation act that may radically alter the action that the second contractor

Preceding page blank

can take against the employer.

There are some other possible remedies, which are somewhat technical — *e.g.*, special contractual arrangements, additional to the usual legal remedies, entered into by the contractor. Diving in certain foreign waters may also, in some circumstances, impose some of those countries' legal remedies. And there are certain situations — for example, diving off a fixed offshore platform — in which the workmen's compensation laws of the adjacent state would be applicable.

I should like to relate some of these legal ramifications to the specific problem of osteonecrosis. First of all, the Jones Act is obviously less than wholly satisfactory in this particular disease because fault must be established before monetary recovery is possible. In practice the courts have simply perverted the concepts of negligence and unseaworthiness to fit almost every situation, based upon a vague humane attitude that a seaman injured in the course of his work should be compensated in some fashion. The real need is for a seaman's compensation act, with appropriate limitations, that will compensate an individual for an industrial injury or illness without reference to the concepts of negligence or unseaworthiness.

With respect to compensation under the longshoremen's act or the various state statutes, I should also like to mention that a functional disability must exist before payment of compensation is required, or, under certain acts (including the longshoremen's), a loss of wage-earning capacity. We have heard in this Symposium that a patient with necrosis of the femoral shaft may well be asymptomatic. The individual may have sustained a systemic insult that has resulted in a weakened shaft. But he may *not* have, from a legal standpoint, a functional disability or loss of wage-earning capacity — unless he is willing to stretch the truth and say that his leg hurts or something of the sort (which is not unheard of, I might add). But if there is no current functional disability or loss of wage-earning capacity, osteonecrosis hardly fits into any of these compensation schemes.

One aspect of these cases is, I think, of particular interest to this Symposium — the very important role played by the medical expert, whether for purposes of prosecution or defense. The usual case has two basic parts: liability (who is responsible?) and damages (how much?). Normally the medical witness is used to help assess damages. He is asked to rate disability, confirm pain and suffering, project future necessary medical or surgical treatment, and give a prognosis. The finder of fact — who may be a judge or jury, or a Department of Labor deputy commissioner under the compensation acts — then has some basis on which to evaluate what the man's disability is worth in dollars.

But the medical expert's role in divers' compensation cases is different, in that he is customarily a primary liability witness. It is often left to him to criticize or ratify the techniques used in decompression, the safety standards that the particular employer imposed on his workers, and so on. I therefore try to involve the medical witness whom I intend using in the case very early, whether it is likely to be settled out of court or come to trial. It has been my experience that most underwriters do the same, because it falls to the medical expert to give us some direction on both the liability and the damages issues.

My experience — and, I think, that of most lawyers — is that doctors are often reluctant to take time from their patients or research projects to assist in matters involved in an adjudicative dispute. It not only is time-consuming but also involves teaching the layman-lawyer a great many fundamental facts of medicine or physiology. Then, at some time that inevitably will be inconvenient to his schedule, the doctor must appear for a deposition or on a witness stand in a trial court. There simply is no compelling reason for doctors to be greatly interested in participating in this legal process — except for one, and I believe that one overrides all the other considerations.

It is this: The quality of justice done before the Deputy Commissioner or in the trial court is absolutely proportional to the quality, objectivity, and fairness of the medical witness involved. If a medical witness of great expertise and high caliber does not participate, time-consuming and inconvenient though it may be, by default this crucial part of the adjudication is left to inexperienced persons, so that the quality of justice is perforce much lower. Or it is left to the charlatan, who is equally willing to testify for the plaintiff or defendant, according to whichever side calls him, without any real objective reference to the truth or to the accuracy of the medical diagnosis in the matter.

OSTEONECROSIS AS IT CONCERNS THE DIVING CONTRACTOR

LAD R. HANDELMAN

Bone necrosis is important to the diving contractor for both economic and social reasons. Two major difficulties associated with the disease are that it was not recognized as a problem in diving until very recently and that so little is known about it. I am the president of a large diving company and know very little about it myself. Neither do our divers know very much about this disease.

I first heard about bone necrosis some two years ago at a meeting in New Orleans, at which Dr. Sealey presented a paper and showed some slides. At that time I associated the disease primarily with tunnel workers. I have recently been told that a major lawsuit is in progress (or is about to be) in which a man claiming to suffer from bone necrosis is suing a diving contractor for $1 million. I have been given to believe that osteonecrosis may be the result of improper decompression. That is really about all I know about it.

Another very important question then arises. What else do I not know about the business I am in? It is alarming to find that something of such significance to the future of our company and the diving industry in general could have existed without our knowing about it.

What immediate effect does the existence or threat of bone necrosis have on diving contractors? So far, it has had no effect on our company, because we have not been confronted with a lawsuit or claim based on bone necrosis. What long-range effects, then, will the disease have? Our first concern is that insurance rates will increase considerably, which might mean that we cannot compete for contracts. The second concern is that perhaps we will not be able to get insurance at all. I am not an insurance expert; but I do know that an insurer must be able to ascertain his risk. If he cannot, he would be foolhardy to write insurance.

The third concern is that we may eventually be involved in an assigned-risk program. Under such a plan, the state insists that an insurance company underwrite a contractor for the benefit of his employees, but the sums of money provided under this kind of plan are rather limited. I do not have the exact figures, but I think that maximum coverage is about $25,000, which is certainly not sufficient to help anyone over a long period of time. In any case, it is not pleasant to think that someday soon we may be unable to buy insurance, or enough insurance. Without insurance, we cannot be in the diving business. It is as simple as that.

Other questions are not so simple. We have to protect ourselves from lawsuits, of course, and the results of litigation depend largely upon whether negligence was involved. How can we prove that we were not negligent? My company has divers working around the world today, using various types of decompression schedules. For air diving, we use U.S. Navy schedules. For helium diving we use our own, which we believe are more conservative. Should we ignore conscience to some degree and follow schedules that we do not feel are as safe as our own, simply because they afford us more legal protection?

Even if no negligence is involved, consider the employee who has been disabled or injured and is therefore entitled only to the benefits provided under workmen's compensation laws. He will no doubt sue us for more than that, bringing the company's liability coverage into the case. We carry $2.5 million coverage, which we consider enough for the business that we are in. But what is the upper limit? How long does a person remain disabled? What treatment must he undergo? How many operations?

Finally, we are in the diving-school business. We encourage and teach people to become divers. It is important to be able to look a man in the eye and tell him that he should devote his life to diving. It is important, as well, to be able to say to our employees that we believe they are in a good business. That about sums up our concern.

OSTEONECROSIS AS IT CONCERNS THE INSURANCE UNDERWRITER

WARD JOHNSON

On November 6, 1968, a 39-year-old man worked under 22-psi pressure for 3½ hours, decompressed for 15 to 20 minutes, and went to lunch. He then went back to work for another 3½ hours, this time decompressing for 26 minutes. He went home and began feeling extremely ill and confused. When he was brought to Milwaukee County General Hospital, Edward End, M.D., indicated that the man was suffering from the most severe attack of decompression sickness that he had seen since beginning practice in 1936.

The patient survived, but is permanently and totally disabled because of osteonecrosis of both shoulders and hips, together with frontal brain damage. Under the workmen's compensation statutes of Wisconsin, he will be paid $73 a week for the rest of his life by the insurance carrier, Employers Insurance of Wausau. Based on disabled-lives tables, he will receive $93,000 in direct compensation benefits alone during the remainder of his life. His medical expenses growing out of this occurrence, coverage for which is unlimited under Wisconsin law, will also be paid. Wausau's attempts to rehabilitate this patient vocationally were unsuccessful owing to his brain damage.

Osteonecrosis from compressed-air caisson work was almost unheard of in the Milwaukee area until 18 months ago. There were a few cases, such as the one just described, but they were scattered among various insurance underwriters. They were assigned the wrong class code, so that the problem was not immediately recognized. *Class code* refers to a type of work exposure. Insurance rates for workmen's compensation are much higher for a tunnel worker than a clerical worker because, obviously, the risk of injury is much greater.

The problem of osteonecrosis came to light in Milwaukee when the number of decompression-sickness cases increased and Eric P. Kindwall, M.D., of St. Luke's Hospital started to check into the cause. The fault lay with the inadequate decompression tables then in use and a most inadequate safety code in general. At some pressures, the old Wisconsin decompression schedule was only one-fourth the length of current codes, such as the Washington schedule. The safety code was changed to meet currently recognized standards, but even with the new safety code, attacks of bends still occur.

As Dr. Kindwall has mentioned, one of Wausau's insured companies has reported 28 claims related to pressure exposures in the last four months. This company, incidentally, is in the assigned-risk pool. Employees are relegated to assigned-risk pools when no insurance company will underwrite them directly. Of the 28, 26 were cases of bends. In those 26 cases, Wausau has paid approximately $10,000 in medical expenses involved in treating the men in the hyperbaric chamber of St. Luke's Hospital. Fortunately, no time was lost from work.

These employees received fast and adequate treatment at St. Luke's Hospital, and it is to be hoped that they will not develop osteonecrosis. In Dr. Kindwall's opinion, these cases were caused by a combination of a high concentration of CO_2 in the tunnel where they were working, a lack of rest before reporting to work, and intake of large amounts of alcohol.

One has to remember that sewer contractors are generally small businessmen. They do not always have the funds to buy all-electric equipment or extra compressors; neither do they have the facilities and engineers to develop special safeguards. To accept the insurance risk in air-pressure exposures, therefore, Employers Insurance of Wausau requires that the following conditions of employment, developed by its safety department, be met:

All employees exposed to increased atmospheric pressures or compressed air — such as exists in pneumatic tunneling operations — must have preemployment examinations. The physicals must include a chest X-ray, anterior X-rays of both shoulders and hips, anterior and lateral X-rays of both knees, and sickle-cell trait determination. Employees are required to have an-

Preceding page blank

nual physical examinations, including six joint X-rays, and a chest X-ray every two years. Wausau requires that a qualified air master be employed under the direct supervision of the physician in charge. The air master must be present any time that employees are working under compressed air, during compression, and during decompression. It is the responsibility of the physician in charge to see that these requirements are met.

The decompression tables as printed in the U.S. Department of Labor's Safety and Health Regulations for Construction (Sec. 1926.803) must be followed, unless the tables of the state in which the work is being performed are more stringent, in which case the latter must be used. Reports of all examinations and X-rays are sent to Wausau's medical consultant. The company can thereby be assured of the supervising physician's expertise and can establish nationwide medical uniformity as well. After Wausau's medical consultant has reviewed the material, a report is sent to the employer with the Wausau physician's recommendation.

An example of the sort of cases reported to Wausau is that of a man who had not worked in the construction industry for 18 months prior to undergoing the required preemployment X-ray. He was found to have osteonecrosis of both shoulders. He has been idled for over a year and is currently undergoing vocational rehabilitation as a gunsmith. Under Wisconsin compensation laws, payments to him are retroactive to his last day of work under compressed air. He is paid $73 a week for temporary disability; he is additionally allowed $73 a week for a maximum of 40 weeks while undergoing vocational rehabilitation.

These sums paid by the insurance carrier are over and above what this man receives from Social Security or any federal or state agency. Further to these benefits, he is currently rated by an orthopedist as having a 15% impairment of each shoulder for a total of an additional 165 weeks, making a minimum of $12,000 that will be due him in temporary- and permanent-disability compensation payments, plus medical expenses.

When the new compressed-air code was put into effect in Wisconsin, 43 workmen out of 188 examined were determined to have some degree of disability because of osteonecrosis. The reserves established by the insurance industry amount to $1,821,000 in Milwaukee at this time, of which $146,000 has already been paid out. Of these 43 cases, 30 have reserves in excess of $10,000, 6 in excess of $50,000, 5 in excess of $100,000, and 2 in excess of $200,000.

These losses have raised insurance rates from a top premium of $4.25 per $100 payroll to $14 for tunneling without compressed air; $28 in 1- to 15-psi exposures; and $42 in exposures of 16 psi and over.

The cost in these cases will probably exceed the $1.8 million reserve. A review of other insurance carriers' files suggests that losses in cases of osteonecrosis uncovered thus far will probably approach $2.5 million. The 43 men cited above, who have been disqualified from performing further air-pressure work, must be retrained for some occupation within their physical capabilities, once their degree of impairment has been determined. To this end, the State of Wisconsin has assigned a vocational-rehabilitation counselor to work with the disabled employee, his physician, and the insurance carrier to make the man a productive member of society once again.

As to lesions of the long bones, under Wisconsin law there is no insurance liability because there is no disability. The fact that the man may have to change his occupation because of such lesions does not imply insurance liability. As new contracts are let and preemployment physicals are performed, as required under the new OSHA code, the insurance industry can expect many more claims. In Milwaukee, only the top of the iceberg is presently visible. And, unfortunately, the problem will soon be a nationwide one.

The only effective way of preventing osteonecrosis is insistence upon strict enforcement of the new federal codes by the assigned physician and the safety department of the insurance carrier underwriting the risk. An exchange of knowledge in this area, which conferences such as this provide, are likewise important. So also are follow-up studies — *e.g.*, the one that Dr. Kindwall will be able to present a few years hence in the 43 cases cited — on the disabilities caused by osteonecrosis as well as those instances in which no disability results.

DISCUSSION 11

Dr. JONES: I would like to know if Mr. Johnson's company or other insurance companies might be willing to underwrite the funding of a decompression osteonecrosis data bank and possibly of a consultative group, such as we have suggested as a means of providing a collaborative, united front in settling disputes.

Mr. JOHNSON: I am not in a position to answer that question, but I can give you the name of someone much higher up who is.

Mr. FARAH: I agree that the idea behind this data bank is a good one, but I get the impression that it is a pet project. It should be set up by an independent organization, because to solicit funds from an insurance company would just about take all the credibility out of it. That is no way to instill confidence in people, especially labor. Such a data bank should be established by the federal government.

Dr. WALDER: There is always a natural tendency to sweep difficult matters such as disabilities arising from a man's employment under the carpet. No one would disagree that, when a man loses his livelihood because of osteonecrosis or other unfortunate sequelae to decompression sickness, he should be compensated in some way. On the other hand, it is important that malingerers be detected and prevented from getting something for nothing.

To accomplish these ends, we must know exactly what has happened in each case. Not only are the medical findings important but it is also essential to know the exact details of the man's compression and decompression. The only way that this can be done is to have some system for continuously monitoring and recording pressure changes and the times when they occurred. One can then examine the record and not have to rely on memory.

On compressed-air sites, it should be relatively easy to keep such records. In Newcastle we are developing a gadget for this very purpose. Similarly, the Royal Naval Physiological Laboratory in England is considering the manufacture of a monitor which the diver can carry on his person to record the pressure changes of each dive.

I was very interested in the honest admission of Mr. Handelman, the diving contractor, who said that until this conference came along, it had never struck him that bone necrosis was a problem in divers. But I must admit that I am surprised by this statement. In Great Britain it is assumed in the law courts that a contractor is fully aware of the implications, relative to his employees, of what he is doing, and this includes knowledge of the medical risks to which he exposes them.

The threat that insurance rates will necessarily increase until contractors can no longer afford to buy coverage stems from our ignorance concerning the risk of osteonecrosis. It is desperately urgent that we obtain sound data on which to base our analysis of the current risk to divers.

A final word. Earlier it was mentioned that unions in the United States are opposed to preemployment medical examinations. The attitude that their members might be victimized is really very stupid. Recording the results of a thorough medical examination is advantageous to both men and their employers. If a man is examined before he joins a firm and is found to be free of disease, he can then blame the company if he subsequently develops a disability. But if, on the other hand, it is discovered that he already has a bone lesion when he is examined, then at least his new employer cannot be held responsible for it and he can look to earlier em-

ployers for compensation. To regard examinations as though they were some sort of trick to ensnare either the man or the company is naive, and we should do all we can to reeducate people holding such false ideas.

Dr. SEALEY: If I understand correctly, under the new federal Occupational Safety and Health Act, jurisdiction extends to the continental shelf. Mr. Teed, how will that affect the responsibility under the Jones Act and Longshoremen's Act?

Mr. TEED: Generally speaking, I expect that the courts will treat the new OSHA regulations much as they have treated similarly promulgated health and safety regulations in other industries. Dispute exists among appellate courts about whether a regulatory violation is *ipso facto* a negligent act or omission. But, in line with the majority viewpoints, I would expect that plaintiff or defendant will be permitted to place in evidence the standards claimed to be proper and appropriate as having been complied with or violated.

In these matters there still reposes in the tryer of fact, be it judge or jury, the ultimate determination: Did the employer or the diving contractor (or whoever the defendant is) act as a reasonably prudent person would act in the same or similar circumstances? At this time the primary use of these regulations in a litigated claim is to establish some evidence, although not conclusive, of appropriate standards for the tryer of fact.

On the other side of the coin are certain sanctions and penalties that may be imposed by governmental enforcers upon an employer who violates the regulations. This does not necessarily redound to the benefit of the individual claimant, but amounts to something of a two-pronged use. First, the federal enforcer penalizes the violator in some fashion, or at least requires compliance with the regulation. Second, the claimant or company may then use the regulations as an appropriate standard of reasonable conduct in a litigative claim.

Dr. FAIRCHILD: I would like to interject the point here that workers already covered by legislation such as the Coal Mine Health and Safety Act or the Atomic Energy Act would not be covered by the new Occupational Safety and Health Act.

Dr. MILES: As Mr. Teed has pointed out, there are two parts to this matter; one is liability and the other, disability. The physician's role, as I said earlier, is to try to assess impairment of function objectively in terms of degree of limitation of motion or shortening, weakness, loss of sensation, and the like. Such matters as employability, the current status of the labor market, and all the other nonmedical factors associated with disability are quite out of the physician's field, and I do not think that he should be called on to make decisions about them. Unfortunately, however, several states require that he do so. The Colorado compensation commission has heard my protests in this matter and has accepted my desire simply to rate impairment of function rather than degree of disability.

PART X

RECOMMENDATIONS FOR FUTURE RESEARCH

ROLE OF THE NATIONAL INSTITUTE FOR OCCUPATIONAL SAFETY AND HEALTH

EDWARD J. FAIRCHILD

This Symposium has been extremely helpful and informative to those of us who represent the National Institute for Occupational Safety and Health (NIOSH). We have already accumulated enough new information to provide input into the Institute's priority list.

At the moment, the Institute has under consideration a priority list of some 20 subjects. It is oriented primarily toward chemical environmental agents and certain physical agents — for example, arsenic, benzene, beryllium, cadmium and its compounds, carbon monoxide, chromic-acid mist, cotton dust, fibrous glass, heat stress, lead, mercury, noise, pesticides, silica, trichloroethylene, and ultraviolet radiation — for which criteria documents are being developed. Also being documented are dose response; recommendations for medical criteria, analytical procedures, and sampling procedures; and recommendations for labeling and various other protective measures. [Subsequent to this meeting NIOSH established barotrauma as a toxic physical agent and published a call for information relative to barotrauma, including decompression tables and standards for divers and tunnel workers — Eds.]

Under the Occupational Safety and Health Act regulations, criteria documents are submitted by the Institute through an ad hoc advisory committee to the Secretary of Labor. The Department of Labor promulgates the standards, either accepting or rejecting the Institute's recommendations. Since the Institute is the research organization under the Act, providing expertise in occupational medicine and industrial hygiene, its recommendations are in most instances accepted.

Many of this Symposium's participants no doubt already have in mind certain research that the Institute might instigate — *e.g.*, an epidemiological study of dysbarism in the diver versus the tunnel worker. NIOSH's research grants, as well as its in-house and contract research, encompass epidemiology, applied and basic animal studies, and some human experimental studies in ergonomics and behavior.

The matter of a registry immediately poses special difficulties. NIOSH is involved with so many occupational diseases that focusing on one might generate pressure from various quarters to set up registers for other medical or environmental problems as well. We are nevertheless interested in exploring the possibilities of at least some sort of prototype registry based, for example, on the beryllium registry at MIT.

It is doubtful that NIOSH could ever assume the task of studying all U.S. commercial, Navy, and sports divers. But obviously one must begin somewhere. The British have set the example with respect to diving. Quite often in the past we have followed British leadership in setting standards — for instance, in our recommendations regarding asbestos studies.

The question of a possible need for new decompression tables has been intimated in the course of this Symposium. Pressure could indeed be exerted in the near future to develop decompression-table standards under the Occupational Safety and Health Act. The Department of Labor (DOL), for example, could place a priority on the establishment of decompression standards. With respect to many hazardous chemical and physical agents, the DOL has in the past adopted existing consensus standards from various sources and made them into law. Therefore, I would recommend consideration of how the expertise of this group might be directed toward the development of better tables, so that someday those who dive will not be forced to live with standards that are actually not the best possible. Such a deficiency exists in many present industrial hygiene standards; consequently, NIOSH is having to conduct research to develop more appropriate criteria for standards. One reason for the Institute's priority system is to identify deficiencies in specific areas.

NIOSH tries to work harmoniously with the

Preceding page blank

Department of Labor under the Occupational Safety and Health Act, because the DOL has ultimate responsibility for promulgating industrial standards and enforcing them. This responsibility is rather different from that established by the Coal Mine Health and Safety Act, under which NIOSH develops and sets the health standards.

The Department of Labor was unable to send a representative to this Symposium. But I am told that it will be guided by our report of the proceedings.

DISCUSSION 12

Dr. HILLS: I disagree slightly on the point of the adequacy of decompression tables. I have always tended to regard the conventional naval tables more as treatment tables than as decompression schedules, inasmuch as a latent gas phase normally occurs. I think that Dr. Spencer, who speaks about the mass of bubbles that he finds after symptomless decompressions, would confirm this observation.

Dr. BECKMAN: I agree that the commonly accepted tables — let us say, the U.S. Navy tables — are not universally adequate.

Dr. WORKMAN: Whether aseptic necrosis occurs with any frequency without manifestations of decompression sickness may be a moot point. It is certainly my impression from the literature on caisson workers and from my personal familiarity with divers that both groups are most reluctant to reenter a recompression chamber for treatment if it can possibly be avoided. I very much suspect the completeness of reports on decompression sickness among these workers, as they tend not to complain unless the "hit" is very painful and disabling. Therefore, many cases of aseptic necrosis may well be associated with decompression sickness that was never recorded.

Dr. WALDER: The fact is that we are abysmally ignorant about what causes both aseptic osteonecrosis and decompression sickness. While Hills, Paul Jones, and I are arguing about whether decompression sickness is caused by bubbles or not, others of our colleagues assume that it is indeed caused by bubbles. So they are designing new tables, thinking up new ratios, and working out new tissue half-times on an empirical basis.

There is a fair possibility that any decompression table, if it has got the right sort of profile, will work quite well. If one does not like its shape one can change it a bit, and perhaps it will work a little better. There is no doubt that by using very rapid decompression schedules one can produce bubbles in animals. Also, there is good evidence that bubbles sometimes occur in the circulation of a man following symptom-free decompression. But as far as I know, no one has ever seen a bubble, directly or indirectly, at the site of pain in a man who is complaining about his knee or elbow. So are we interested in bubbles or not?

I have recently reappraised the work of Harvey *et al.* (1944). It has been possible to verify some of his interesting statements to the effect that fluids can be greatly supersaturated with gases without spontaneously bubbling. These supersaturated fluids do not spontaneously bubble unless a pre-formed gas phase (gas micronucleus) is present in them. Therefore, if bubble formation occurs in men, there must be preexisting micronuclei somewhere in their bodies.

Yet these bubbles cannot be found at present. The use of ultrasonics has demonstrated that bubbles do indeed appear in man on decompression, very much more often than was previously suspected. As I see it, the position is that, although we cannot explain on physical grounds how bubbles form in men, we know that they do in fact form. We must solve this dilemma before we start calculating any more tables.

The whole question of the drugs used in decompression sickness, such as heparin and vasodilators, was summarized recently in a report by Dr. Bennett (1971). Drugs seem to be of only very limited value.

To answer Dr. Workman: We do not say that men who develop osteonecrosis have not had bends; we do say that some with osteonecrosis had

not earlier reported for treatment of bends, which is a different matter. I know that some men put up with an attack of bends in their own way — they drink a bottle of whiskey, take a half dozen aspirin, and "sweat it out" rather than return for recompression treatment. There are probably, as well, people who have had an attack of bends but failed to recognize it as such. They too may subsequently develop a bone lesion.

Dr. McCallum and I recently had a great argument in a court of law over this matter. I know that he does not agree with me; but now that we know that bubbles often circulate during decompression, perhaps the question becomes one of where they will ultimately lodge. If they enter tissue surrounding a joint and expand in an area of high gas partial pressure, they can cause diffuse pain in that joint, identified as bends. Bubbles entering bone may not give rise to pain, but they may slowly grow larger and obstruct the blood supply to a patch of bone for a period sufficiently long to cause a bone lesion.

Dr. McCALLUM: I think that there are other things to be borne in mind — for example, the possibility that a bone lesion may occur without our being able to detect it at all; it never develops to the extent that it appears on a radiograph. In some of our work there has been evidence that this was, in fact, happening. Decompression may therefore be a precipitating factor in producing bone necrosis that subsequently heals without ever having produced symptoms.

I should like to go further and say that it appears to me, particularly after what has been presented at this Symposium, that we are dealing with a phenomenon in which the bubble theory alone is not an adequate explanation. It may be that in both bends and bone necrosis, at least two — perhaps several — factors are involved, some of which we know nothing about. I do not think that we know the full story yet.

Dr. HARVEY: As I said earlier, I do not think that our tables need immediate revision. Many of them are probably somewhat inadequate in terms of aseptic necrosis, but we do not know enough at the present time to change them intelligently.

REFERENCES

Bennett, P. B. (1971). A Review of Protective Pharmacological Agents in Diving. Royal Naval Physiological Laboratory Report 771.

Harvey, E. N., Barnes, D. K., McElroy, W. D., Whiteley, A. H., Pease, D. C., and Cooper, K. W. (1944). Bubble formation in animals. I. Physical factors. J. Cellular Comp. Physiol. 24, 1-22.

SUMMARY AND RECOMMENDATIONS FOR FUTURE RESEARCH

EDWARD L. BECKMAN

As physicians we tend to lose sight of the fact that symposia such as the present one are conducted not solely to enrich our own understanding of a specific clinical problem, but also for the purpose of providing guidance to the lay community whom we serve. In the instance of this Symposium we have additional obligations — to our sponsors, NIOSH and its representatives, and to those who face the occupational hazard of dysbarism-related osteonecrosis, the divers and tunnelers themselves.

A review of the concepts and theories presented in the course of this Symposium clearly reveals the benefits of multidiscipline participation. The Chairmen are deeply grateful to all participants — clinicians who treat diseases of bone, scientists engaged in osteonecrosis and pressure-physiology research, physicians in industrial practice, scientific administrators concerned with developing research programs in safety and health, lawyers, insurers, tunneling contractors, and representatives of the commercial diving industry. Because of this sharing of knowledge, we come away from the Symposium with a far deeper understanding than before of osteonecrosis as it relates not only to particular medical specialties but to industrial diving and allied fields as well.

By way of summarizing the various aspects of the disease, as presented in the Symposium, I should like to make the following observations about the existing state of knowledge and the course that future investigation should, in my opinion, take.

A significant incidence of dysbaric osteonecrosis has long been recognized among caisson workers and tunnelers in the United States, England, and other countries. The disease occurs in Royal Naval divers, among commercial divers working in U.S. Gulf coastal waters, in Japanese fisher-divers, and even in U.S. Air Force pilots. The Medical Research Council (U.K.) has established a statistically significant correlation between the disease and the number of decompressions undergone by an individual, frequency of exposure, magnitude of pressure to which he was exposed, and number of attacks of dysbarism suffered. By contrast, there is no significant positive correlation between the occurrence of osteonecrosis and an earlier attack of bends, "chokes," or other acute manifestations of decompression sickness (DCS).

Royal Naval researchers have observed that divers involved in experimental exposures are more likely to develop osteonecrosis than those who perform only routine diving. Additionally, the incidence and severity of osteonecrotic lesions among Gulf of Mexico commercial divers have been found to correlate positively with the number of years of work exposure.

Among tunnelers a relationship between incidence of the disease and certain pressure exposures has been established. Prof. Dennis Walder reports that "the occurrence of the disease among tunnelers who work at pressures less than 17 psig (40 FSW) is believed to be practically nil." This depth limit is remarkably similar to the safe no-decompression limit of 33 FSW (14.7 psig) set for unlimited-duration dives by the U.S. Navy.

Clearly there exists a minimal level and duration of hyperbaric exposure and rate of decompression that protect against both DCS and osteonecrosis. Decompression schedules for use with greater pressure–time exposures have not yielded the same protection. Further, the British Admiralty has reported the discovery of severe multijoint osteonecrosis in three of four submariners several years after a single pressure exposure and decompression, which followed the sinking of their vessel and their emergency escape from it. (The fourth seaman could not be traced at the time of investigation.) These seamen had been under increased ambient pressure for some 3½ hours while they flooded their compartment with water to the water depth of 126 FSW; they then escaped to surface with a Davis Submarine Escape Apparatus.

With respect to decompression schedules, we have been told that the present Washington

State tables have apparently been effective in protecting tunnelers against dysbaric osteonecrosis in the Seattle, San Francisco, and Milwaukee tunneling projects. However, the tables have not been effective in protecting workers against bends — surprising, since current decompression computation is designed to prevent bends and the more serious, acute symptoms of decompression sickness.

We have also been told that if the vascular systems of a group of divers were monitored with Doppler ultrasonic bubble detectors after a standard U.S. Navy pressure–time exposure and decompression, inert-gas bubbles would be detected in the mediastinal vessels of some of these divers even if all of them remained symptomless. Thus we are left with these paradoxes relative to DCS and osteonecrosis:

1. A diver may develop bubbles in his vascular system during decompression according to a standard U.S. Navy table, yet remain asymptomatic of DCS.
2. Commercial divers who have used only the standard U.S. Navy diving tables have developed osteonecrosis.
3. The Washington State tables for caisson work appear to provide protection against osteonecrosis, but a high incidence of DCS nevertheless occurs under these schedules.

We next considered the disease process in osteonecrosis. We are indebted to our orthopedic-surgeon participants for detailing the pathophysiology of dysbaric osteonecrosis and for distinguishing it from other forms of bone necrosis.

Descriptions of osteonecrosis resulting from traumatic interruption of the vascular supply to the femoral head following surgical-neck fracture have put the disease into perspective relative to pressure workers. Dr. James Miles succinctly summarized the process in this way:

> Necrosis of bone results in a unique pathologic event — replacement through a process called creeping substitution. The replacement may be quite perfect. However, when the necrotic process involves the articular cortex, the fate of the associated articular cartilage becomes crucial. If the cartilage is necrotic, it will be replaced rather imperfectly and degenerative arthritis will be the result. The replacement process is identical, no matter what the nature of the bone necrosis may be — idiopathic, traumatic, metabolic, or physiologic. Replacement is, however, influenced by many factors, including *1*) site of involvement, whether articular or nonarticular; *2*) age; *3*) presence or absence of fracture; *4*) presence or absence of union, if there is a fracture; *5*) accessibility of the necrotic areas to fibrovascular invasion and the presence or absence of invasion; and *6*) state of the articular cartilage.

Specialists in diving medicine are inclined to think of osteonecrosis in terms of changes in the roentgenographic density of a bone. Although these changes do indeed reflect one aspect of the disease (namely, rate of calcium deposition or absorption), they neither define the process of repair by creeping substitution nor prognosticate its effectiveness. This fact was demonstrated by Prof. Walder in a case in which microscopic tissue examination after autopsy revealed that an extensive amount of repair had occurred in a diver's femoral head. Yet no radiological evidence of damage or repair had been detected. Similarly, Dr. Kent Smith reported that osteonecrosis in his experimental animals could not always be demonstrated roentgenographically, but could be demonstrated by histologic studies of the bone.

Prof. Walder further pointed out that, in studies of experimentally induced osteonecrosis in animals, roentgenographic diagnosis could not be made sooner than three months after blood supply had been surgically interrupted. The subsequent course of events was equally interesting: When the disease process was followed by serial roentgenograms, the osteonecrotic changes that developed during the first three months gradually disappeared. So complete was the repair process that, after 19 months, there was no radiologic evidence to indicate that any disease had existed at all!

Prof. Walder showed serial roentgenograms taken of a caisson worker in which there was similar onset, progression, and then complete repair of the osteonecrosis disease process. "It is tempting to postulate that bones can become damaged in decompression, and then repair themselves without anything abnormal ever being detected by radiological examination," was his comment.

These observations quite naturally bring into focus the significance of etiology in dysbaric osteonecrosis. Identifying the specific causative agent(s) is, of course, crucial to developing specific preventive methods. But from a therapeutic standpoint, knowing that osteonecrosis results from some interruption of blood circulation within bone may be quite sufficient to establish an optimal treatment program.

The experimental evidence presented suggests that the disease may be caused by one or more etiological agents: multiple gas-bubble formations; multiple fat emboli; embolic aggregations of erythrocytes; osmotic fluid shifts resulting from gas-tension changes in the tissues; or a combination of any or all these factors. All these condi-

tions are known to develop in both divers and caisson workers so that, despite the apparent differences in the type of labor performed, the causative factors appear to be similar.

The case history submitted by Prof. A. A. Bühlmann is particularly relevant to a study of the etiology of osteonecrosis. It concerns a diver who had experienced bends pain in both knees during planned decompression following a deep experimental dive, pains which disappeared as decompression progressed. But postdecompression fat embolization developed, which proved fatal five days later. On postmortem examination, the emboli were traced to marrow damage in the distal end of the left femur, where a large intramedullary hemorrhage was found.

In view of the five-day survival in this case, it is not surprising that gas emboli had not been suspected as causing hemorrhage. Furthermore, if the patient's lesion had healed, calcium deposits would have developed in the necrotic fatty tissue, which would have been radiographically indistinguishable from medullary dysbaric osteonecrosis. Nevertheless, ample data exist to implicate bubble formation and growth, followed by disruption of fatty tissue cells and their vascular supply, with resultant fat embolization, as the mechanism involved in such incidents.

Progress toward preventing the disease of work-related osteonecrosis is presently thwarted by limited research funding. To increase safety by lengthening decompression time or decreasing work time under pressure only escalates operational costs — not the most ideal solution. In responsible industrial-medicine practice, reducing operational cost at the expense of compromising the safety and health of workers is, of course, never justifiable. Therefore, if the interests of both compressed-air worker (or diver) and employer are to be served, much incisive laboratory and field research must be done to define the interrelationships among decompression procedures, acute decompression sickness, and dysbarism-related osteonecrosis.

With respect to diagnostic techniques, roentgenography does not sound the alarm until long after osteonecrotic damage has occurred, nor does it provide prognostic information about the reparative process. Isotopic bone scans and xeroradiography, although new and promising, appear at the moment to offer little that the standardized roentgenographic surveys introduced by the British MRC do not. Regardless of technique, the importance of avoiding radiation overexposure of subjects in the cause of clinical precision must always be borne in mind. Except for the purpose of diagnosing or evaluating juxta-articular lesions, there should be good reason to conduct extensive roentgenographic studies or isotopic bone scans.

Although early diagnosis is vital in those cases that might result in necrosis of the articular cartilage or collapse of the articular surface, apparently no practical prognostic test exists. So we must continue to monitor roentgenographic images of susceptible bones in the hope of detecting early changes. Once evidence indicative of osteonecrosis is observed, the medical consultant must offer information along two major lines of consideration, as discussed by Prof. Walder: What prognosis can be anticipated, and what treatment should be offered?

Prognosis is obviously dependent upon the location of the lesion. Is it at a site *1*) where it is unlikely ever to cause symptoms — *i.e.*, shaft, head, or metaphysis; or 2) where symptoms have already arisen, or may do so? Lesions in the shaft or head of a bone, well away from the articular surface, do not cause symptoms or structural collapse, and hence do not require treatment. A worker with these lesions may even be allowed to continue pressure work, although he should be excluded from unusual or hazardous exposures.

If osteonecrosis is found in a juxta-articular site, but the patient is asymptomatic, then a period of "watchful expectancy" (in medical parlance) must begin. Avoidance of further potentially dangerous hyperbaric exposure makes good sense. A diver, for his own health, should discontinue diving; in any event, he is now virtually unemployable as a diver because of the occupational risk he represents insofar as compensation insurance is concerned.

By way of treatment, a therapeutic regime of complete bed rest may be quite effective clinically, but it is impractical in the industrial world. The average pressure worker would prefer to take his chances, and then if he is luckless, to rely upon surgical repair. When pain occurs, surgical intervention may be indicated. As the orthopedic participants have shown, modern techniques of total hip replacement produce quite satisfactory results. The procedure can be offered as a solution to the pressure worker who is suffering from severe juxta-articular osteonecrosis with collapse of the articular surface of the joint.

Lastly, it was hoped that the Symposium would provide some guidance to NIOSH with

respect to future research efforts. It is apparent that much remains to be learned about pressure-related osteonecrosis. A technique of diagnosing the disease in its early stages is badly needed. So also is a better treatment regimen whereby early lesions can be arrested before they become debilitating ones.

Prevention of a disease is, of course, the ultimate goal in any medical research program. But research into osteonecrosis would reap double benefits, in that a better understanding of and solution to this menace in the compressed-air worker's life would shed light on another major one — namely, acute decompression sickness.

In my opinion, the problems explored in this Symposium suggest that research attention and funding should be expended primarily in seeking answers in the following areas:

1. The epidemiological factors in osteonecrosis among both caisson workers and commercial divers. Such research would be greatly simplified by the establishment of a central registry for storing data on osteonecrosis and decompression sickness.

2. Development of an animal model for studying dysbaric osteonecrosis, the results of which can be used to evaluate:

   a. The relationship between clinical signs of dysbarism and the occurrence of osteonecrosis.

   b. The value of the Doppler ultrasonic bubble detector (or comparable device) in predicting that a particular decompression schedule is potentially productive of dysbarism and/or osteonecrosis.

   c. Development of decompression-schedule criteria to prevent dysbaric osteonecrosis and acute decompression sickness.

   d. Identification of pharmacological agents that are effective in preventing and treating osteonecrosis — *e.g.*, oxygen at high pressures and low-molecular-weight dextran and heparin.

3. Evaluation of fluorine-18 and technetium isotopes for use in early detection and follow-up studies of the disease process, and relating isotopic bone-scan findings to roentgenographic findings.

DISCUSSION 13

Mr. GALLETTI: Will the diving industry be forced to do what is done in the tunnel industry — that is, eliminate workers found to have bone necrosis associated with their jobs? Speaking as a contractor (and for several others here as well), I can say that if we are put in such a position, we would wipe out about 50% of our experienced divers and would have to bring in many inexperienced people to maintain our present services.

Dr. FAIRCHILD: I'm afraid that I cannot really answer that question. Under the Coal Mine Health and Safety Act, it is recommended that the employer find a new job for persons discovered to have a certain category of pulmonary impairment. But I cannot say what our recommendation would be for the diving industry.

Ordinarily we recommend that some compensation be given an individual who has suffered a health compromise. It is left up to our expert review committees, who act as consultants, to determine the amount. We do not wish to put anyone out of work but, obviously, we wish to protect health. Through the Small Business Administration, the Department of Labor has programs to build up business expertise, establish training programs, and even provide moneys. But I do not know where the line is drawn between what is and what is not a small business.

Dr. PURDY: A coal miner who is found to have some category of pneumoconiosis is still free to choose whether he wants to work or not, and his employer has a free choice about continuing to employ him. We do not tell workers that they cannot work. We tell them that if they are sick, they are compensable. Then they have to choose whether they want compensation or to continue to work. I would think that a regulation similar to this might be made to apply to divers.

APPENDIX

AN ANNOTATED BIBLIOGRAPHY

prepared by

Margaret F. Werts

and

Charles W. Shilling

Preceding page blank

ADAMS, G.M., G.P. Vose and S.J. Norton.
Bone density changes and decompression sickness.
In: Abstracts of the Fifth symposium on underwater physiology, Freeport, Bahamas, August 1972, p.26. Published by the Symposium.

Abstract only. Entire item quoted: A system has been devised to investigate decompression sickness without subjecting the model animal to an extremely rapid or explosive decompression rate. Moderate and/or minor signs of decompression sickness were induced in male rats stage decompressed in either 52 minutes or 79 minutes from a 600 FSW simulated dive with 60 minute bottom time. A quantitative, X-ray, micro-densitometric technique was employed to study bone density changes in the tibia epiphysis and diaphysis as a function of the above dive profiles. The decompression schedules produced significant decreases in bone density measured immediately after the dive. Post dive mineral accretion rates appeared significantly decreased or stopped in about 5% of the tested animals while the remaining 95% returned to normal mineral accretion rates. Exogenously administered calcitonin reversed the observed bone density decreases and afforded the treated animals a significant reduction in the incidence of decompression sickness. A measured bone density decrease reflects a loss in bone mineral content, and suggests a possible injury that may result in the eventual occurrence of aseptic bone necrosis. The apparent effectiveness of exogenous calcitonin administration suggests that calcium homeostasis and/or metabolism may be playing a significant role in both the immediate occurrence of decompression sickness and the potential occurrence of aseptic bone necrosis.

ANONYMOUS
Bones problem.
Skin Diver 22:56; June 1973

Entire item quoted: Divers who spend a lot of time underwater for long periods tend to develop bone disorders says Dr. Hiroshi Hayashi (chief of high pressure medical treatment research division of Kyushu Labor Accident Hospital). According to Ocean Science News, 135 divers were studied; 72 had abnormalities with 25 suffering osteonecrosis, 47 others unknowingly had calcification of thigh bones and upper arms. Hayashi found the abnormalities to be related to depths. Those working less than 10 meters down didn't suffer, 12% at 20 to 30 meters were affected, 14% were affected below 30 meters and 43% were affected at depths of more than 51 meters. The osteonecrosis was thought to occur due to too-rapid ascents (not necessarily causing bends, but nitrogen bubbles all the same).

ANONYMOUS
Bone-wasting dives.
Medical World News 14:17-18; July 13, 1973.

The general discussion of osteonecrosis resulting from diving or compressed air work starts with an account of the very inadequate decompression methods employed in the sewer tunnels of Milwaukee. Dr. Eric Kindwall discovered, by means of X-ray, that these workers had a 41% incidence of osteonecrosis as a result of too-rapid decompression. The most generally accepted theory of the etiology of osteonecrosis–lack of blood supply to the bone caused by bubbles, is presented. Case histories are cited which indicate the disease can follow brief exposure, minimal repetitions and moderate pressure and need not be related to a history of decompression sickness. Recent surveys in the U.S. Navy, following similar surveys in the British Navy, have revealed a surprisingly high incidence of osteonecrosis. Although the study has just begun, 76 cases have been discovered, in the majority of which joints were affected. The insurance aspects of the problem are discussed, and the high cost to the diving industry is noted. It is most essential that divers and compressed air workers should be X-rayed before being taken on a job, and the X-rays should be read by a radiologist trained in the detection of early signs of osteonecrosis. (MFW/UMS)

ANONYMOUS
Bone necrosis in divers.
Lancet 2(7875):263-264; August 3, 1974.

The author refers to the high incidence of osteonecrosis in German divers of ten years experience, and in civilian divers in England. The incidence in naval divers is much lower. It is claimed that orthopedic treatment of collapsed joints is unsatisfactory. The problems of radiological diagnosis, and the possible usefulness of bone scanning is noted. Although osteonecrosis occurs in individuals who have never had decompression sickness, it is still believed that inadequate decompression is a cause. It is considered essential that all medical examination reports should be submitted to the Medical Research Council's Decompression Sickness Panel. (MFW/UMS)

Preceding page blank

ANTOPOL, W. and C.P. Chryssanthou.
Experimental production of aseptic bone necrosis in mice.
In: Aerospace Medical Association. 1972 annual scientific meeting, Bal Harbour, Florida, May 1972. Preprints, p.255-256. Published by the Association.

The findings of this preliminary investigation reveal that exposure to compression-decompression produces aseptic bone necrosis in thin mice and increases the incidence of this lesion in the obese animals. The former observation suggests that development of aseptic bone necrosis after exposure to compression-decompression is independent of decompression sickness since thin mice are not "susceptible" to this disease. Supporting this hypothesis is the fact that PPCH and bradykinin, which were previously reported to influence the incidence and severity of decompression sickness in obese mice did not alter the frequency of aseptic bone necrosis in the present investigation. The occurrence of necrotic bone alterations in control obese mice may indicate that this species is subject to the lesion *ab initio* and exposure to compression-decompression precipitates aseptic bone necrosis in these predisposed animals. This study also indicates that the bone lesion is manifest after a latent period of at least five months following the initial treatment, and that with multiple exposures to compression-decompression the incidence is greater than with single exposure. (From author's discussion).

BECKMAN, E.L.
Diving standards.
In: United States-Japan conference on natural resources development. Proceedings of the first joint meeting of the U.S.-Japan panel on diving and technology, Tokyo, 1972, p.104-115. Japan, Ministry of Agriculture and Forestry, 1972.

The author discusses the economic and safety problems of the diving industry in the United States, and emphasizes the difficulties of agreeing on regulations for decompression tables, for medical certification of divers, and for standards regarding equipment and procedure. The necessity of developing new decompression tables for industrial diving is noted. The U.S. Navy decompression tables are so conservative as to be prohibitive in cost, due to the extremely high wages received by divers. In spite of the conservatism of the Navy tables, there is a large incidence of osteonecrosis in former Navy divers who are now working in the industry. The author has been assigned the task of developing commercial decompression tables, and requests the cooperation of Japan in the testing of three tables. (MFW/UMS)

BECKMAN, E.L.
Development of criteria for improved safe work practices in the U.S. diving industry.
In: Trapp, W.G., E.W. Bannister, A.J. Davison and P.A. Trapp, eds. O_2. Fifth international hyperbaric congress proceedings, p.912-917. Burnaby, Canada, Simon Fraser University, 1974.

Present conditions indicate that almost every high pressure worker will be entitled to a compensation claim before he reaches retirement age. Thus, it is essential that legislation be adopted to protect both employer and employee. A committee of the National Institute for Occupational Safety and Health has made recommendations as follows: Specifications must be made as to safe limits of oxygen partial pressure and exposure, as to inert gas partial pressures, and as to medical qualifications for divers. The recommended treatment for decompression sickness consists of U.S. Navy treatment tables plus British Royal Navy Table 7, supplemented by heparin, dextran, and steroids. Regarding osteonecrosis, preemployment and annual roentgenographic bone surveys should be made; juxta-articular lesions prohibit employment, and the disease is to be considered an occupational hazard unrelated to negligence. As to diagnosis, ultrasonic bubble detectors and measurement of platelet function and blood coagulability are suggested. Supervisory personnel must be trained by the government in recognition and treatment of decompression sickness. Diving contractors should be responsible for reasonable care in prevention of decompression sickness, and for administration of proper treatment should it occur. Regarding equipment, the ANSI Z135 Committee recommendations were followed. As to prevention of decompression sickness, the Washington State Tables should continue to be considered standard until further research to improve them has been completed. Divers must remain within easy access of a chamber for a specified period of time after diving, and should wear identification indicating recent diving activity. They should not fly within two hours of a no-decompression dive, within 12 hours of a decompression dive, and within 24 hours of a saturation dive. These recommendations do not apply to altitudes below 800 feet, so that presumably transportation by helicopter would be safe. (MFW/UMS)

BENNETT, P.B.
Physiological problems of deep diving.
Meerestechnik 3:177-185; October 1972.

The major physiological hazards of diving are listed, and a diagram is presented which indicates at which depth each type of trauma or disorder, including osteonecrosis, is likely to occur. The dangers of ascent, including osteonecrosis, are discussed. It is pointed out that entirely successful decompression tables have not yet been worked out, and that decompression sickness is an ever-present danger. Research into osteonecrosis which may or may not be related to decompression sickness has been greatly intensified recently. (MFW/UMS)

BERGMANN, E.W.
Aseptic bone necrosis of known and unknown origin.
Proceedings of the Rudolph Virchow Medical Society, New York 28:46-49; 1970-1971.

(Hard copy not obtained).

CATTO, M.E.
Pathology of caisson disease of bone.
In: The Association of Clinical Pathologists: 89th general meeting. Symposium II. Decompression sickness. Journal of Clinical Pathology. 25:1006; November 1972.

Abstract only. Entire item quoted. While histological examination is of little help in elucidating the pathogenesis of aseptic bone necrosis in compressed air workers, it throws some light on the sequence of events and radiological changes following bone death. Revascularization of both medullary and juxtaarticular lesions may begin but halt short of completion, the revascularization front becoming collagenous. Bone trabeculae adjacent to this fibrous tissue are often greatly thickened and may give rise to a sclerotic line on clinical radiographs. When such a radio-dense line is seen traversing a bone end it is highly probable that the tissue between it and the joint surface is still dead. The necrotic bone trabeculae may later fracture, with collapse of the articular surface associated with pain. Incongruity of the joint surface is often followed by formation of osteophytes at the living joint margins. At first the joint space remains normal and the articular cartilage covering dead bone is relatively well preserved but later it and the underlying dead bone may be ground away, the end result sometimes being difficult to distinguish from primary osteoarthritis. A similar pattern of events and morphological changes may be seen following juxtaarticular bone necrosis due to other causes.

CHEN, S.C.
Caisson disease.
British Journal of Clinical Practice. 26:385-386; August 1972.

This is a case history of a 60-year old man with a lifetime history of tunnel work, who suffered more or less chronic pain in his right hip. Examination revealed a dense, flattened femoral head resulting from avascular necrosis. Four years later he was operated on, and the femoral head was replaced with a Thompson's prosthesis. Three months later, the pain returned, and the hip movement was considerably more limited. X-ray revealed involvement of the roof of the acetabulum. Another operation was performed, replacing the Thompson's arthroplasty with a McKee-Farrar total hip arthroplasty. The case indicates that not all necrotic bone lesions are detectable by radiography in the early stages, and those that are seen may represent only a small part of the necrotic area. The inadequacy of replacing only one component of the joint is demonstrated. (MFW/UMS)

CIZMIC, M., A. Frankic and R. Skarica.
X-ray bone changes in caisson disease.
Medical Journal 94(9):23-27; 1972.
(Translation of Lijecnicki Vjesnik 94(9):449-452; 1972.)

The authors report here on data gathered from examination of 54 sponge and coral divers. After discussing the pathogenesis of decompression sickness, he describes the radiological changes observed in men of long diving experience. The bone changes were of two main types: rarefaction, which is not specific to decompression sickness, and condensation, which is. The condensation is of two types: (1) compact foci, usually located on the head of the humerus or femur, and (2) the less common trabecular type, which appears as small, stringy and dense shadows. Infarctions of the diaphysis are fairly common, sequestrations, usually on the humeral head, are less so. The disease does not appear to be age-connected, but rather to be related to length of diving experience. (MRW/UMS)

COLTMAN, D.B. and D.N. Walder.
A study of avascular bone necrosis in sheep.
In: Abstracts of the Fifth symposium on underwater physiology, Freeport, Bahamas, August 1972, p.27. Published by the Symposium.

Abstract only. Entire item quoted: This investigation was an attempt to reproduce the radiological and histological appearances associated with caisson disease of bone by the interruption of specific vascular pathways to the femoral head in sheep. The superior epiphyseal vessels to one femoral head of 18 sheep in which the epiphyses had fused were divided by means of a cut almost completely through the neck of the femur. The animals were then put out to grass. Serial radiological investigations were carried out. Definite changes were seen in the femoral head of 8 animals, these being progressive over a period of up to 256 days. In 4 animals no changes were visible. The first definite changes occurred at about 110 days, though possible changes could be detected at about 60 days. The animals were killed 300-582 days after the operation and the circulation of the hind limbs injected with a radio-opaque medium (Micropaque). Radiographs and histological studies were then performed. Surprisingly these showed only minimal disturbance of the circulation and bone structure. From the few previous reports of the histological changes seen in men suffering from caisson disease of bone it is clear that the area of bone affected is always considerably larger than that seen on radiographs. Our results indicate the extraordinary ability of bone to repair itself after severe trauma and show how little in the way of histological change remains as evidence of the damage. Because of this, we have been led to postulate that even greater areas of bone then hitherto suspected may be involved in the initial process of caisson disease of bone. Further, the paucity of changes in these animals in spite of the severity of the vascular interference may explain the difficulty experienced in producing bone lesions in animals by exposing them to hyperbaric episodes.

CONTI, V. and R. Sciarli.
Lesions osseuses chez le plongeur autonome
[Bone lesions in the autonomous diver].
In: Hesser, D.M. and D. Linnarsson eds. Proceedings of the first annual scientific meeting of the European Undersea Biomedical Society, Stockholm 13-15 June 1973. Forsvarsmedicin 9:525-527; July 1973.

Medical examinations of divers before hiring revealed clinically latent bone lesions in cases where there was no record of decompression accident. The pictures resembled benign bone islands or lacunae. The authors were struck by their frequent occurrence in compressed-air scuba divers. One case is described in which a diver had pain and difficulty of movement in his shoulder several months after having suffered a decompression accident affecting that area. Bone anomalies were not discovered in divers who performed deep dives with helium-oxygen. It is concluded that nitrogen is the principal cause, by disturbing the circulation in the spherical and hemispherical bone extremities. It is suggested that a diver who should not work with compressed air might be able to dive safely with helium-oxygen. Because of an apparent relationship between hyperlipidemia and osteonecrosis, no applicant with such a tendency should be permitted to dive at all, at least temporarily. Medico-legal questions are brought up here, in relation to occupational disease and damage suits. Radiological records are most important in this connection. (MFW/UMS)

COX, P.T. and D. Walder.
Strontium scanning in caisson disease of bone.
In: Abstracts of the Fifth symposium on underwater physiology, Freeport, Bahamas, August 1972, p.28. Published by the Symposium.

Abstract only. Entire item quoted: One of the present difficulties in treating caisson disease of bone is that the diagnosis depends upon detecting subtle changes in the radiological appearance of the bone and these only become apparent some months after the start of the pathological process when it is probably too late to reverse the course of the disease. The possibility that the abnormality in the bone might be demonstrated by determining the way in which Strontium^{85} is deposited and subsequently cleared from the bone has been investigated. An intravenous injection of Strontium^{85} was given and differential colour scans were thereafter made. We have studied three situations: 1) That in which there is indisputable radiological evidence of an avascular bone lesion. 2) That in which the radiological appearances are normal but the man has been exposed to copmressed air and therefore could have a radiologically undetected lesion. 3) That in which the subject has never been in compressed air and has normal radiographic appearances. It appears that aseptic necrosis of bone lesions can be detected by Strontium scanning because in such cases the Strontium is preferentially held at or around the site of the bone lesion. The use of this type of investigation to detect the early lesion of caisson disease of bone is discussed.

COX, P.T.
Simulated caisson disease of bone.
In: Hesser, D.M. and D. Linnarsson eds. Proceedings of the first annual scientific meeting of the European Undersea Biomedical Society, Stockholm 13-15 June 1973. Forsvarsmedicin 9:520-524; July 1973.

It would appear that the injection of embolic particles into the artery supplying the lower limb of the rabbit indicates that the arterial supply of the femoral head and to a lesser degree the shaft, is poor in that it may be relatively easily obstructed. It also produces avascular necrotic bone lesions of the femur in sites that correspond to those that occur in caisson disease of bone and implies that the aetiological agent in caisson disease of bone may be the embolic occlusion of osseous vessels. (Author's conclusion)

COX, P.T.
Caisson disease of bone.
Journal of the Royal College of Surgeons. 18:290-293; September. 1973.

Diagnosis of dysbaric osteonecrosis is performed by radiology, which reveals the existence of a lesion within three months of its inception, at the very least, and usually much longer. Also, radiology fails to predict joint involvement in the case of a juxta-articular lesion. The use of radioisotope scanning revealed that in some cases a positive radiograph coincided with a negative scan, and vice versa. It is explained that strontium is taken up in the area of the lesion during the period of increased activity and bone turnover, thus revealing the formation of a lesion in its early stages, as well as the cessation of activity which occurs when a lesion becomes static. Experiments were made with rabbits. It was concluded that a positive scan with a negative radiograph indicates that the lesion has not progressed enough to be radiologically visible. In the opposite situation, it is probable that the repair process has ceased, and the lesion is unlikely to progress. (MFW/UMS)

D'AMBROSIA, R.D.
Experience with ^{18}F scintigraphy in avascular necrosis of bone.
Journal of Bone and Joint Surgery 56A:205-206; January 1974.

Abstract only. Entire item quoted: Dr. Robert D. D'Ambrosia noted that F scintigraphy is a simple method of evaluating the blood supply to bone and reported on a study of seven dogs with surgically devascularized femoral heads and seventy-five patients with assorted avascular lesions of bone. The findings by scintigraphy were correlated with those by roentgenography, tetracycline labeling, and histological examinations. Excellent correlation was shown in the femoral neck fractures and it was concluded that this is a promising technique.

DAVIDSON, J.K. and P.D. Griffiths
Caisson disease of bone.
Nursing Times 67:1049-1052; August 26, 1971.

The author states that decompression sickness in general has become well controlled through widespread understanding of recompression therapy. What he terms "caisson disease of bone" is not so easily controlled, and is now considered the greatest danger of the hyperbaric environment. It is noted that in a group of 54 experienced compressed-air workers, 50% showed radiological evidence of bone damage; in a group of 200, 9.5% had juxta-articular bone lesions. A brief review of the literature is given, citing specific cases. In the case of the shoulder joint, pain usually appears suddenly, while in the hip it is more gradual. There are great individual differences in the progress of the lesions–some become disabling within 18 months of the first exposure to compressed air and others, radiographically similar, will remain static for many years. The most satisfactory treatment in seriously disabled cases is excision of the deformed head and insertion of a metal prosthesis. Arthrodesis will relieve pain and can be used satisfactorily if the opposite joint is normal. (MFW/BSCP)

DAVIDSON, J.K.
The earliest radiographic evidence of dysbaric osteonecrosis following exposure at high pressure.
In: Abstracts of the Fifth symposium on underwater physiology, Freeport, Bahamas, August 1972, p.25. Published by the Symposium.

Abstract only. Excerpts quoted: The experience of the early diagnosis of bone necrosis by the radiologists associated with the Medical Research Council Decompression Sickness Panel is discussed. The earliest lesions appear as small dense areas adjacent to the articular surface of the head of the humerus or femur, varying in

diameter between 3 and 20mm. The margins are indistinct and thickened trabeculae may be seen running through the lesions. Tomography may improve definition especially in the femur. Pathological correlation in the early lesion shows that the increased density results from thickened trabeculae following revascularisation of the necrotic segment. Thirty men with bone lesions have been continuously studied over three to eight years at yearly intervals or less. In some the initial lesion has developed from the earliest evidence of bone necrosis through a structural failure with associated 'symptoms' to later develop osteo-arthritis. In some the initial lesion has remained static. Differentiation of caisson disease of bone from bone islands or variation in the normal trabecular pattern can be difficult. Bone islands are more compact, ovoid or obling in shape with well defined margins and usually remain unchanged in size. In the femoral or tibial shaft, the earliest abnormalities are similar dense areas and follow up in five men show progress to calcified areas.

DAVIDSON, J.K.
Radiology of dysbaric osteonecrosis.
In: The Association of Clinical Pathologists: 89th general meeting. Symposium II. Decompression sickness. Journal of Clinical Pathology. 25:1005-1006; November 1972.

Abstract only: The author refers to the first attempt to make a study of the incidence of osteonecrosis in compressed air workers, when the entire work force of the Clyde tunnel in Glasgow was examined radiologically. Findings were 19% incidence, and 10% juxta-articular (potentially disabling). The Medical Research Council Decompression Sickness Registry has kept radiographic records of compressed air workers since that time which give substantially the same figures. The head of the humerus is the most frequent site, followed by the distal shaft of the femur. The earliest radiographic lesions, which develop eight months to a year after exposure, are areas of increased density adjacent to the articular surface. In the medulla, the earliest features are small areas of increased density and small foci of calcification. In diagnosing dysbaric osteonecrosis, other causes of osteonecrosis, such as fracture of the femoral neck, dislocation of the hip, and the idiopathic form sometimes associated with steroid dosage, hemoglobinopathies, Gaucher's disease and Schandler's disease, must be kept in mind. Necropsy radiography following diving fatalities is considered very vaulable in demonstrating intravascular bubbles or air embolisms, pneumothorax, mediastinal emphysema, or surgical emphysema. A radiograph of both groins may show gas or air in the iliofemoral artery and vein segments. Radiographs of the head of the humerus and of the femur should be coned to show trabecular detail. The author emphasizes that "correlation of the radiographic and pathological findings is of considerable value and importance in identifying the earliest radiographic features of osteonecrosis with confidence and differentiating this from variation in normal trabecular structure." (MFW/UMS)

DECOMPRESSION SICKNESS PANEL, MEDICAL RESEARCH COUNCIL
A medical code of practice for work in compressed air.
London, U.K., Construction Industry Research and Information Association. Report CIRIA 44, 90p. February 1973.

The code sets out recommendations for the medical treatment and supervision of compressed air workers. Among the many recommendations is one dealing with radiographic examination of joints which we quote in its entirety: Aseptic necrosis of bone must still be considered one of the major hazards of working in compressed air and the incidence of bone necrosis, rather than the incidence of bends, could be accepted as a guide when assessing the efficacy of a decompression procedure. For this reason it is essential that any man working at gauge pressures 1 bar and above (or above 14 lbf/in^2), who has not been radiologically examined for evidence of bone necrosis within the previous 6 months, should have a radiographic examination of his shoulder, hip and knee joints within 4 weeks of his engagement (Appendix 12). This examination should be repeated at minimum intervals of 6 months during his employment in compressed air and, when possible, at intervals of 12 and 24 months after his last exposure to compressed air. (CWS/UMS)

EGURO, H., B.A. Hills and J.L. Goldner.
Unsuccessful attempts to produce avascular necrosis of bone by compression/decompression stress and alcohol ingestion in guinea pigs.
Clinical Orthopaedics and Related Research 98:294-301; Jan./Feb. 1974.

Heavy weight adult guinea pigs were fed alcohol-containing water, and exposed to multiple compression/gradual decompression stresses for 5 months. Roentgenological and histological studies demonstrated no evidence of necrosis of bone trabeculae or bone marrow. (Authors' summary)

ELLIOTT, D.H.
The role of decompression inadequacy in aseptic bone necrosis of naval divers.
Proceedings of the Royal Society of Medicine. 64:1278-1280; December 1971.

As a result of analyzing the statistics revealed in a radiological survey of 305 naval divers, it is concluded that there is a positive relationship between the presence of radiological lesion and a history of decompression, also between positive lesion and experience of experimental diving with compressed air, and experimental deep diving with helium. ("Experimental" in this case refers to dives in which the decompression schedules used were not of proven adequacy). (MFW/UMS)

ELLIOTT, D.H.
Clinical problems of decompression sickness relevant to the surface activity of intravascular bubbles.
In: Ackles, K.N. ed. Blood-bubble interaction in decompression sickness. Proceedings of an international symposium held at Defence and Civil Institute of Environmental Medicine, Downsview, Ontario, Canada, p.140-161. Published by the Institute, December 1973. (DCIEM Conference Proceedings 73-CP-960).

The surface activity of the intravascular bubble should be considered in relation to each of these problems: individual susceptibility and adaptation to decompression sickness; the role of pulmonary micro-barotrauma in (1) platelet response to normal diving, and (2) decompression sickness; prolonged latent period of onset; prognostic value of doppler-detected bubbles: dose-response and possible correlation with some haematological index; the relation of both to overt manifestations of acute decompression sickness, as well as to the later development of aseptic bone necrosis; cause of cutaneous vascular stasis–(ideal site for investigation); relative preponderance of spinal cord lesions in divers; significance of migraine-like episodes in divers and aviators; the nature of staggers, and the particular problem of vestibular system disturbance; the consequences of increased capillary permeability ranging from the presence of some haemoconcentration in the mild bends of compressed air workers to the serious shock of aviators' post-descent collapse; paradoxical response to recompression; ineffectiveness of recompression, particularly in cases of spinal cord involvement after a prolonged delay in contrast to other cases in whom headache or vertigo have responded after a delay of several days; and finally, perhaps a limiting factor to commercial diving and a subject on which we touch later, aseptic necrosis of bone, its cause and prevention. (Author's summary)

FAGAN, C.J. and E.L. Beckman
Survey of Gulf Coast commercial divers for dysbaric osteonecrosis.
In: United States-Japan conference on natural resources development. Proceedings of the first joint meeting of the U.S.-Japan panel on diving and technology, Tokyo, 1972, p.145-160. Japan, Ministry of Agriculture and Forestry, 1972.

Dysbaric osteonecrosis of bone is not an uncommon disease among Gulf Coast divers. A sample survey consisting of a small number of commercial divers had yielded a high incidence (27%) of roentgenographic findings. As a result of this initial work, we are attempting to expand our survey. A comparison of plain film imaging with xeroradiographic imaging in an admittedly limited number of divers, has not helped us sufficiently to accept the additional radiation exposure inherent in the xeroradiographic technique. Fluorine-18 bone scanning probably represents a reasonable and practical modality in an osteonecrosis survey. We suspect that the bone scan probably relates to the osteogenic activity of the disease process and therefore may be helpful in detecting early or active areas of osteonecrosis. (Authors' summary)

FAGAN, C.J. and E.L. Beckman.
Gulf coast commercial dysbaric osteonecrosis study.
In: Abstracts of the Fifth symposium on underwater physiology, Freeport, Bahamas, August 1972, p.29. Published by the Symposium.

Abstract only. Entire item quoted: Gulf Coast commercial divers are being surveyed for the presence of dysbaric osteonecrosis. A sample survey already completed indicated a 22% incidence of osteonecrosis in those studied. The survey utilizes good quality, well positioned plain films of the shoulders, hips, and knees. Diagnostic parameters are based on the classification and terminology of radiological findings formulated by the British Medical Research Counsel Decompression Sickness Panel. Suspect or questionable lesions are further examined using tomography and xeroradiography. In some cases, Fluorine-18 radioisotope studies have been performed and correlated with the findings from preliminary film studies.

FICAT, P., J. Arlet, R. Vidal, A. Ricci and J.C. Fournial.
Resultats therapeutiques du forage-biopsie dans les osteonecroses femoro-capitales primitives. [Therapeutic results of drill biopsy in 100 cases of primary osteonecrosis of the femoral head]. Revue du Rhumatisme et des Maladies Osteo-Articulaires 38:269-276; April 1971.

An analysis was made of the results of drill biopsy of the head and neck of the femur in 100 cases of primary osteonecrosis which had been verified histologically and followed up for 1-6 years. The following results were shown: suppression or alleviation of pain in 83% of cases; improved mobility of the joint in 43% of cases; and radiological stabilization in 77% of cases. Remarkable results were obtained in stage 1, the pre-radiological phase (42 cases) in which drill biopsy (confirming the diagnosis) was followed by absence of radiological changes in 37 of the 42 cases. Thus, it appears the development of the disease can be arrested by this simple procedure prior to rupture of the femoral head. However, an earlier diagnosis may be possible with the aid of the haemodynamic and phlebographic methods developed by the authors. In addition, the pain destroying and often stabilizing effect of drill biopsy on complicated cases makes it one of the procedures to be considered in all stages of the disease. [Although the origin of the bone necrosis in the cases reveiwed is not specified, the findings would seem to apply to dysbaric bone necrosis as well as to that from other causes]. (English summary)

GILLEN, H.W.
Undersea medicine: osteogenic necrosis.
Aerospace Medicine 43:466-467; April 1972.

This is a plea for a centralized national registry of data collection on the subject of osteogenic necrosis (or aseptic bone necrosis). This should include data on "diving experience, radiographic studies, life habits and health characteristics of a large number of exposed persons over many years." Interview and questionnaire techniques must be developed. The collection of data must be on an involuntary basis as a requirement of employment. It is emphasized that the cause of bone necrosis is not known, and there is no therapy in existence at present by which lesions may be reversed. A national registry of data on bone necrosis would reveal collateral significance of data now isolated and dispersed, and might lead to the identification of other safety and health problems. It is estimated that 5,000 persons are regularly employed in commercial diving and caisson work and many others are irregularly so employed. Because a large number of these workers are peripatetic, reliable data are not available under any program now in existence. A national registry must be developed under the Occupational Safety and Health Act of 1970, with the help of the Occupational Safety and Health Administration of the Department of Labor. (MFW/UMS)

GOLDBERG, M.E. and M.K. Loken.
The varied usefulness of bone scanning.
Geriatrics 29:65-72; March 1974.

Recent improvements in techniques have increased the importance of the role of bone scanning in the detection of underlying bone destruction. Bone scanning detects the increased uptake of radioactive material at the site of the reparative process which will follow any destructive process. There are many areas in which bone scanning is useful, provided the findings are interpreted in the proper context, and in conjunction with radiographic findings. Early detection of avascular necrosis is one of the ways in which this technique proves valuable. (MFW/UMS)

GRIFFITHS, P.D.
An exposure to risk registry for compressed air workers.
Transactions of the Society for Occupational Medicine. 21:123-125; October 71.

A central Registry of compressed air workers was established in Newcastle-upon-Tyne in 1964. Data collected from the Tyne Tunnel project in 1948 and subsequent compressed-air operations were stored and assessed. The data included etiology, sequelae, osteonecrosis, and more recently, diving hazards. In assessing exposure to risk the intensity of the hazard and the duration of exposure are the chief considerations. Data on approximately 10,000 individuals are held. Radiological data are collected on a voluntary basis, and therefore are incomplete. Of the 1660 men who have been radiologically examined, 330 show positive signs of osteonecrosis. Data show that the longer the exposures and the higher the pressure the more likely is the occurrence of osteonecrosis, although cases have been known to occur after a single exposure. Since divers seem to suffer much less frequently from osteonecrosis than do compressed air workers, it is thought that probably the duration of exposure is more important than the degree of pressure. It may be necessary to shorten the work shift, but at present the line of experimentation is in the lengthening of the decompression period. (MFW/UMS)

HILLS, B.A.
Clinical implications of gas-induced osmosis.
Archives of Internal Medicine 129:356-362; February 1972.

A review of the evidence for believing that gas concentration gradients can induce water movement in vivo shows that this could be a significant physiological parameter in many tissues, depending upon the magnitude of the gas-osmotic pressures. Estimation of these has suggested two experiments whose results show (1) that reflexion coefficients for gases may be appreciably higher than determined previously, (2) that water flow rates are high, and (3) that the list of semipermeable tissues should include articular cartilage. The clinical implications of gas-induced osmosis are then discussed with particular reference to gaseous anesthesia, hyperbaric arthralgia, gouty arthritis, aseptic bone necrosis, hyperbaric urticaria, pulmonary edema, and the edematous separation of tissue boundaries in general. (Authors' abstract)

HILLS, B.A. and R.S. Straley
Aseptic osteonecrosis: a study of tibial blood flow under various environmental conditions.
Aerospace Medicine 43:724-728; July 1972.

The direction of change of blood flow in the tibiae of five large rabbits and nine mongrel dogs has been monitored at various stages of exposure to compressed air and to various breathing mixtures at normal atmospheric pressure. The results show a definite increase in flow 4-7 mins after compression to 4 ATA in air and upon exposure to normoxic nitrous oxide. These effects are essentially reversed upon return to air at normal atmospheric pressure or upon exposure to pure oxygen, while I.V. alcohol can cause appreciable variations in either direction. The duration and extent of ischemia observed were not considered sufficient to initiate the aseptic necrosis of bone commonly found in compressed-air workers and alcoholics. Discussion of this disease indicates that it may not be a symptom of decompression sickness, as generally assumed, and may even be induced by the compression phase of an exposure to compressed air. (Authors' abstract)

HORVATH, F. and T. Vizkelety.
Experimentelle Untersuchungen der osteoartikularen Manifestation fer Caisson-Krankheit.
[Experimental studies on osteoarticular manifestations of caisson disease.]
Archiv fur Orthopaedische und Unfall-Chirurgie 75:28-42; 1973.

Based on their experimental investigations the authors are of the opinion that in cases of identical decompression time the bone and joint changes of caisson disease develop according to the degree of pressure and according to the number of repetitions. As the epiphyseal circulation is quickly damaged, necrotoic areas develop in the articular cartilage, in the growth plate and in the metaphysis. In cases of severe lesions large necrotic areas form also in the region of the main nutrient artery. The marrow cavity has the appearance of a cellular reaction following ischaemic necrosis. The necrosis and the reparative processes are balanced in cases of slight circulatory disturbances. No signs of regeneration in the diaphysis and insignificant regeneration in the epiphysis are characteristic of severe defects of the blood supply. Radiological bone changes were especially typical of groups in which the decompression treatment was performed with the critical 2-2.5 atm pressure. Authors found a subchondral and a solitary circumscribed cystic lesion, both of them situated in the distal femoral epiphysis. A further case was observed with a radiological picture of the femur resembling myeloma multiplex. The distal femoral metaphysis of rabbits of the group treated with one atm pressure presented very slight, partly sclerotic, partly porotic structural changes. (English summary)

HORVATH, F. and I. Rozsahegyi.
Chronische caisson-osteoarthropathie in der Gelenkpfanne des Schulterblattes.
[Chronic caisson osteoarthropathy in the glenoid cavity of the clavicle.]
Fortschrifte auf dem Gebiete der Roentgenstrahlen und der Nuklear medizin Ergaenzungsbande 117:733-734; December 1972.

A case of chronic osteoarthropathy of the right shoulder blade in a 48-year old diver and caisson worker is reported. X-ray photographs of the shoulder show a widespread uneven subchondral and cranial sclerosis which extends to a lesser degree to the upper joint surface of the humerus. The joint itself was not compromised, and the patient, although complaining of pain in the right hand, arm and shoulder, had good mobility in the joint. The authors have noted only four cases of shoulder blade arthropathy among the 150 cases of caisson arthropathies which they have examined. (MEMH/UMS)

HORVATH, F. and I. Rozsahegyi
Bedeutung der Tomographie fur die Diagnose der chronischen Caisson-Osteoarthropathie.
[Importance of tomography for the diagnosis of chronic caisson osteoarthropathy.]
Fortschritte aud dem Gebiete der Reontgenstrahlen und der Nuklear medizin Ergaenzunsbande 119(5):610-618; November 1973.

Radiographic symptoms of bone manifestations of caisson sickness in 123 caisson workers are reviewed. Most common localizations were the proximal humeral epiphysis and metaphysis and the femoral head and neck; bone changes were also noted in the scapula, acetabulum, and in the ends of the tibia and femur forming the knee. Radiographic symptoms include osteosclerosis, isolated or multiple geode formations, and isolated or multiple cystic formations of various sizes. These symptoms are discussed in detail and illustrated by a series of photographs. The author recommends the routine use of tomography in the diagnosis and ongoing evaluation of caisson osteoarthropathy. (MEMH/UMS)

JAFFRES, R. and P. Merer.
Contribution a l'etude de la pathogenie de l'ilot solitaire benin et de la lacune benigne du col femoral.
[A contribution to the pathogenesis of the benignant solitary islet and of the benignant lacuna of the femoral neck.]
Revue du Rhumatisme et des Maladies Osteo-Articulaires 29:272-280; May 1962.

After describing the benignant solitary islet and the benignant lacuna of the femoral neck, in two groups of subjects affected or unaffected with barotraumatic osteonecrosis, the authors come to the conclusion that there is no difference between the radiological aspect of these pictures in the two groups. Considering that these pictures are three to ten times more frequent in osteonecrosis, that both aspects may coexist in the same patient, and that they saw the appearance of a benignant lacuna of the neck in a case of osteonecrosis, they logically came to suspect the vascular origin of these images. (English summary)

JAFFRES, R. and P. Merer.
Les localisations extra-epiphysaires de l'osteonecrose barotraumatique.
[The extra-epiphyseal localizations of barometric osteonecrosis.]
L'Ouest Medical 18:263-268; March 10, 1965.

The authors describe the extra-epiphyseal localizations of barotraumatic osteonecrosis of the scapula, the humerus, the pelvis, the femur, and the tibia. They establish the percentage of frequency of the various localizations in a group of 53 patients totaling 148 localizations. (Authors' summary translated by MFW/UMS)

JONES, J.P., Jr. and A.R. Behnke.
Prevention of osseous avascular necrosis in compressed air workers employed in soft-ground tunneling operations by the bay area rapid transit district (BART), a preliminary report.
In: Abstracts of the Fifth symposium on underwater physiology, Freeport, Bahamas, August 1972, p.29. Published by the Symposium.

Abstract only. Entire item quoted: From November, 1967 through May, 1969, 64,567 feet of soft-ground tunneling was driven on the 75-mile BART Project, of which 15,026 feet of tunnel were machine-shield driven using compressed air under hazardous obstacle and soil conditions. Despite 80,360 man-decompressions, at pressures from nine to 36 psi and a total of 135 instances of decompression sickness (128 Type I, and seven Type II), involving 85 men in a group of approximately 400 compressed air workers, there has been no reported clinical or roentgenologic evidence of dysbaric osteonecrosis to date. Over 17,000 skeletal roentgenograms were taken on more than 2,000 workers. Thirty-three lesions of osteonecrosis, of varying maturity, were discovered during pre-employment examinations of 15 compressed air workers who were rejected for pressure tunneling work. Eleven of these individuals had potentially disabling juxta-articular lesions, which principally affected the humeral heads. Two of these rejected workers had previously been exposed to maximum pressures of 16 and 18 psi, respectively, without decompression sickness, but both showed evidence of alcoholism. All other rejected workers had been exposed to pressure in excess of 30 psi. Preliminary follow-up studies indicate that avascular necrosis can be substantially prevented by employing a program of unique engineering principles, designed to avoid use of compressed air altogether, or to minimize exposure to pressure in conjunction with comprehensive medical supervision, including thorough pre-employment examinations, utilization of the Washington State Decompression Tables, as incorporated in the California Code, and use of oxygen decompression in a closed system.

KAWASHIMA, M., T. Torisu, K. Hayashi and Y. Kamo.
Avascular bone necrosis in Japanese diving fishermen.
In: Trapp, W.G., E.W. Bannister, A.J. Davison and P.A. Trapp, eds. O_2. Fifth international hyperbaric congress proceedings, p.855-862. Burnaby, Canada, Simon Fraser University, 1974.

Four hundred and fifty Japanese shell divers were monitored for osteonecrosis form 1966 to 1972. Lesions were found in 268 men. The upper femur and the upper humerus were the most common sites. Juxta-articular lesions occurred most frequently in the upper humerus. Divers with over ten years of experience, and older divers, were more frequently affected than young and/or inexperienced divers. Of the men with lesions, 73.1% had had bends, while in those without lesions the figure was 57.1%. There appeared to be no connection with type II decompression sickness. There was a relationship between osteonecrosis and diving depth. A table is given showing the classification of various types of lesions as modified by Ohta and Matsunga: e.g., juxta-articular lesions are type A; within this group are subclassifications giving more specific identification (A1 – A6). Head, neck and shaft lesions are type B, and have three subclassifications. Lesions resembling bone islands are type C. (MFW/UMS)

KINDWALL, E.P.
Divers' asceptic bone necrosis.
In: Professional diving symposium, New Orleans, Nov. 1972. Marine Technology Society Journal 7:36-38; March/April 1973

Aseptic or avascular necrosis is a disease which can affect anyone working under increased ambient pressures, in excess of 38 feet of sea water, who does not follow sound decompression procedures. It is too early to say with certainty what the incidence of this desease will be in those people using present saturation diving techniques, but it has appeared on the Gulf Coast in saturation divers. The shoulders and hips are most often affected. It is difficult to correlate the incidence of bone necrosis with the number of times a man has decompression sickness. Treatment consists of placing the joint at rest in the early stages or performing surgery if actual destruction of the joint has taken place. Pre-employment and yearly x-rays are becoming prevalent among diving companies to prevent liability and minimize the destruction caused by the disease should it occur. (Author's abstract)

KINDWALL, E.P.
Aseptic necrosis due to occupational exposure to compressed air: experience with 62 cases.
In: Trapp, W.G., E.W. Bannister, A.J. Davison and P.A. Trapp, eds. O_2. Fifth international hyperbaric congress proceedings, p.863-866. Burnaby, Canada, Simon Fraser University, 1974.

It was found that of the compressed air workers digging a sewer system in Milwaukee, 35% had osteonecrosis, and of these, 71% had juxta-articular lesions. The author attributes this situation to inadequate decompression procedures of the New York Code of 1922, which called for a split shift of three hours in the morning, a one hour surface break, and three hours in the afternoon. The second decompression was identical to the first, with no allowance made for residual nitrogen. In August, 1970 the Washington State Tables were adopted. These are now in use throughout the United States. They are similar to the Navy tables, and permit only one decompression a day. Asymptomatic and harmless shaft lesions are important in that they may assist in diagnosis of questionable lesions elsewhere in the individual. The U.S. Navy has found 76 cases of osteonecrosis among its diving personnel, only 15.8% of whom had reported decompression accidents. Most of these resulted from deep helium diving, saturation diving, or experimental diving of some sort. (MFW/UMS)

KOCH, G.H. and R.Y. Nishi.
Decompression procedures for caisson work – a review of various techniques.
Downsview, Ontario. Defence and Civil Institute of Environmental Medicine, Defense Research Board, Report DCIEM 905, 24p. November 1972.

Many different procedures are in effect for decompression after exposure to pressure in caisson work although they differ little in their basic concepts. The main principle is to prevent decompression sickness and aseptic bone necrosis in workers while affording rapid (and therefore economical) decompressions. In order to determine which of the new and highly favoured procedures is the most safe and economical, an analysis was carried out comparing the Ontario, Washington State, and British "Blackpool" caisson decompression procedures, and the U.S. Navy and Royal Navy diving decompression precedures with the DCIEM Kidd-Stubbs decompression model. The conclusions reached are that the Ontario procedure is safe provided the second shift is eliminated for exposure to pressures greater than 14 psig, and that the Washington State and British "Blackpool" procedures become increasingly unsafe as the exposures become longer over all the pressure ranges up to 50 psig. It is noted that these "unsafe" exposures have not generally been used in practice. Recommendations for caisson decompression are suggested. (Author's abstract)

McCALLUM, R.I.
Tunnelling in compressed air and bone necrosis.
Transactions of the Society for Occupational Medicine 22:2-6; January 1972.

(Hard copy not obtained).

McCALLUM, R.I.
Pneumoconiosis and caisson disease of bone.
Transactions of the Society for Occupational Medicine 22:63-68; July 1972.

These two occupational diseases are treated together because of their common dependence upon radiology for detection and management. The problems connected with radiology are discussed, and the work of The Decompression Sickness Panel in England, in the preparation of an album of illustrative lesions (Radiographic appearance of bone lesions in compressed air workers, 1968) is commended. As to radiation dose, it has been established that three routine joint examinations per year are acceptable, provided adequate protective measures are taken. Because of the fact that a lesion does not become radiographically visible until necrosis is too far advanced, other methods of detection, such as bone scans with strontium 85 or fluorine 18 are being studied. (MFW/UMS)

McCALLUM, R.I.
Aetiology of decompression sickness.
In: The Association of Clinical Pathologists: 89th general meeting. Symposium II. Decompression sickness. Journal of Clinical Pathology 25:1004; November 1972.

Abstract only. The author briefly describes type I and type II decompression sickness, and mentions chronic sequelae (osteonecrosis, neurologic complications and vestibular disturbances). No decompression procedures in current use are infallible. The bubble theory of the etiology of decompression sickness is at present being questioned, but no completely satisfactory explanation has been formulated. The author believes that bubbles always occur but that other body changes may be important contributors. It is stated that osteonecrosis occurs in 20% of compressed air workers and divers, and it is noted that it may result from several factors present during compression, decompression, or both. Further observations of human bone tissue are essential to the understanding of this disease. (MFW/UMS)

MIRRA, J.M., P.G. Bullough, R.C. Marcove, B. Jacobs and A.G. Huvos.
Malignant fibrous histiocytoma and osteosarcoma in association with bone infarcts.
Journal of Bone and Joint Surgery 56A:932-940; July 1974.

It is stated that sarcoma at the site of previous bone infarction has been reported only rarely. (See Dorfman et al., J. Bone Joint Surg. 48A:528-532; Apr. 1966, for an earlier case involving a compressed air worker). This report presents four cases, two of which had been caisson workers. Both former caisson workers had malignant fibrous histiocytomas. In one case a pin and plate was used, because of the advanced age and poor general condition of the patient. In the other case, amputation was performed. Neither patient survived. (MFW/UMS)

MURAKHOVSKII, K.I. and L.Z. Golod.
Mineralizatsiya kostnoi tkani cheloveka v uslovihakh vodnoi immersii. (Rentgenofotometricheskoe issledovanie).
[Mineralization of human bone tissue during water immersion. (Roentgenophotometric study)].
Kosmicheskaya Biologiya i Meditsina 6:72-75; November/December 1973

Two experimental series including ten experiments were carried out to assess the effect of a 5-day water immersion on the mineral content of bones of men having a kind of BASS [a special experimental suit] on and without it. The suit consisted of a system of capstans providing an additional load on the musculo-skeletal system. The bone mineral content was measured roentgenophotometrically in milligrams of Ca per 1 mm^3 before and on the second day of immersion. The areas studied were: the scaphoid bone, talus, oscalcis, distal metadiaphysis of the femoral bone and proximal metadiaphysis of the tibial bone. In experiments without the suit the level of bone density in the areas studied decreased by 4.8%. Statistical treatment showed that the decrease was significant at $P = 0.95$. In experiments with the suit the level of bone density increased in most cases; however the data turned out to be statistically insignificant. A comparison of the significance of the differences between bone density changes in experiments with and without BASS has demonstrated that they are statistically significant for the scaphoid bone, talus and oscalcis and insignificant for tubular bones. (English summary)

OHRESSER, P., J. Tassy and J.-F. Amoros.
Le traitement de la maladie de decompression. Bilan de quatre annees d'activite du service d'hyperbaria de l'hospital Salvator a Marseille.
[The treatment of decompression sickness. Summing up of four years of activity at the hyperbaric facility of the Salvator Hospital at Marseille].
In: L'Huillier, J.-R., ed. Medecine de plongee. Gazette des Hopitaux de Paris 35:1045-1046, 1049; December 20, 1971.

At this multiplace chamber facility, approximately 20 cases of decompression sickness were treated per year, usually by the A and B tables of GERS; in three cases table C was used, and in some cases the Workman Tables were used. There were three cases of articular accidents, decalcification was demonstrated radiographically. It is thought that "chronic arthropathies" represent instances where bends have not been treated, or have been poorly treated. (MFW/UMS)

OHTA, Y. and H. Matsunaga.
Bone lesions in divers.
In: United States-Japan conference on natural resources development. Proceedings of the first joint meeting of the U.S.-Japan panel on diving and technology, Tokyo, 1972, p.136-141. Japan, Ministry of Agriculture and Forestry, 1972.

Radiological data collected from 301 divers over a period of three years revealed evidence of osteonecrosis in 50.5%. Of these, 14.6% were juxta-articular, most of which were in the humeral head. Most of the head, neck and shaft lesions were found in the lower extremities. Length of diving experience was related positively to incidence of osteonecrosis. The sites of bone lesions were in the following order: upper humerus 92 cases; lower femur 72 cases; upper femur 58 cases; upper tibia 9 cases. Of the 152 men afflicted, 60 had solitary lesions and 92 had multiple lesions. There was greater incidence among divers with a history of decompression sickness, but there was no relationship between the location of bends pain and the site of the lesions, and no relation between spinal paraplegia and bone lesions. There was a relation between depth of diving and incidence of lesions. (MFW/UMS)

OHTA, Y. and H. Matsunaga.
Bone lesions in divers.
Journal of Bone and Joint Surgery 56B:3-16; February 1974.

A three-year survey of avascular necrosis of bone has been carried out in a community of some 400 professional divers for shell-fish who had used no modern technique of decompression. Of 301 divers radiographed, 152 (50.5 per cent) had bone lesions. The incidence of bone necrosis increased in proportion to the length of diving experience, being highest in men with over ten years' experience. The incidence was also higher in men who usually dived deeper than thirty metres. There was a high incidence in men with a history of the bends but no significant relationship between the sites of the bends and those of the lesions. Bone lesions were more frequently multiple than solitary. The upper end of the humerus was significantly more affected than the upper end of the femur or tibia, but not significantly more than the lower end of the femur. At the upper ends of the humerus and femur the lesions were more frequently unilateral than bilateral. (Authors' summary)

PUELO, L.E. and H.H. Sobel.
Oxygen-modified collagen and its possible pathological significance.
Aerospace Medicine 43:429-431; April 1972.

Acid soluble collagen isolated from the skin of mice was exposed to 150 psi of oxygen at 37°C for four weeks in pH 8.0 buffer. The product was considerably modified from its native state, becoming insoluble in dilute acetic acid, exhibiting reduced ability to form gels in hot water and reduced digestibility by bacterial collagenase. The action of the latter on oxygen-modified collagen results in a soluble fraction which exhibits marked fluorescence at 425 nm after activation at 350 nm. Approximately 10% of a brown collagenase-insoluble product results. The collagenase-soluble fraction yields a fluorescent peptide which contains most or all of the tyrosine in this fraction. Oxygen-modified collagen might be formed in vivo during exposure to high oxygen tension and results in certain pathological changes, such as aseptic necrosis of bone which is observed in diving personnel. (Authors' abstract)

RYCKEWAERT, A. and D. Kuntz.
Les osteonecroses aseptiques de la tete femorale chez l'adulte.
[Aseptic osteonecrosis of the femoral head in adults].
Acquisitions Medicales Recentes, p.167-177; 1970.

A brief general discussion of aseptic osteonecrosis of the femoral head in the human adult is presented. Lesions of the bone and their development, radiological appearance, and clinical symptoms are detailed. The etiology of the disorder is traced to ischemia of the head resulting from injury or compression of the capillary arteries supplying its circulation. Secondary and primary forms of osteonecrosis, correlated mechanical and metabolic-biochemical factors, and their possible pathogenic mechanisms are described. Treatment possibilities are briefly mentioned. The author's discussion of barotraumatic osteonecrosis is limited to the following remarks: Secondary forms are less frequent. They include: (1) Osteonecroses due to microparticular vascular obturation; the particles in question may be intravascular or peri-vascular, causing obturation by compression. Within this group we may include: (a) barotraumatic osteonecroses, observed in subjects who work in compressed air after a too-rapid decompression. They result from the liberation within the bone marrow of bubbles of nitrogen which obstruct or compress the small vessels of the femoral head. (MEH/UMS)

SCHAEFER, K.E.
Involvement of CO_2 and calcium stores in decompression sickness.
In: Abstracts of the Fifth symposium on underwater physiology, Freeport, Bahamas, August 1972, p.28. Published by the Symposium.

Abstract only. Entire item quoted: In a previous communication Schaefer et al. (Aerosp. Med. 41:857; 1970) reported that symptoms of decompression sickness manifested in poorly localized muscle aches and stiffness which did not respond to recompressions and O_2 treatment appeared to be associated with fluid and electrolytes shifts and a large CO_2 excretion in the urine. Further analysis of urine electrolyte data showed that in these cases the carbon dioxide tide was preceeded or followed by a calcium tide in the urine. These observations point to the bone with its CO_2 and calcium sink as a target organ in decompression sickness. Recent findings of Bursaux, demonstrating that over 40% of the bone CO_2 store consists of rapidly exchangeable bicarbonate, provide a better understanding of the interaction of bone CO_2 and calcium stores. Individual data on respiratory gas exchange, CO_2 and calcium excretion obtained in 4 subjects during saturation-excursion dives to 800 and 1000 feet depths showing rapid changes in CO_2 and calcium pools are compared with the slow changes in CO_2 and calcium pools during adaptation to 1.5% CO_2 (Schaefer et al., J. Appl. Physiol. 18:1079; 1963) in an attempt to elucidate the underlying mechanism.

SCHAEFER, K.E.
Involvement of CO_2 and calcium stores in decompression sickness.
United States Naval Submarine Medical Research Laboratory, Report NSMRL 738, 9p. February 12, 1973.

Analysis of urine electrolytes obtained during saturation excursion dives of four divers to depths equivalent to 800 to 1000 feet of sea water showed in all cases during decompression an increase in urinary CO_2 excretion and calcium excretion. In two subjects who developed symptoms of decompression sickness manifested in poorly localized muscle aches and stiffness of joints which did not respond to recompression and oxygen treatment, the carbon dioxide excretion in the urine was more pronounced and was preceded or followed by a calcium tide. These observations point to the bone with its large CO_2 and calcium store as a target organ in decompression sickness. The hypothesis is presented that during compression a greater influx of calcium and carbon dioxide occurs, into the fast exchanging bone carbon dioxide and calcium stores related to an increase in bone-blood flow. During decompression a greater outflow of calcium and carbon dioxide seems to develop corresponding with a decreased bone-blood flow. Recent advances in bone physiology appear to provide a fitting framework for this hypothesis. The hypothesis appears to offer new avenues of approach to the study of decompression sickness and aseptic bone necrosis. (Author's abstract and application)

SCHAEFER, K.E.
Present status of underwater medicine. Review of some challenging problems.
Experientia 30:217-221; 1974.

In this review of the medical problems of diving, there is a short section on osteonecrosis. The author refers to several surveys of the incidence of this disease in compressed air workers and divers. In Germany and Japan, commercial divers showed an incidence of 55% and 50% respectively. By contrast, divers of the Royal Navy in England showed only 6%. In a recent survey of commercial divers on the Gulf Coast of the United States, a 22% incidence was discovered. Because of the comparative prevalence of the disease, and because of the large cost of compensation claims, there will probably be a strong effort made to replace the diver wherever possible. (MFW/UMS)

SMITH, K.H., P.J. Stegall, L.A. Harker and S.J. Slichter.
Possible effects of bubble-induced coagulation following decompression.
In: Ackles, K.N., ed. Blood-bubble interaction in decompression sickness. Proceedings of an international symposium held at Defence and Civil Institute of Environmental Medicine, Downsview, Ontario, Canada, p.260-271. Published by the Institute, December 1973. (DCIEM Conference Proceedings 73-CP-960)

The authors discuss the hemostatic abnormalities which occur following hyperbaric exposure. These changes include increased platelet and fibrinogen utilization. Effective therapy depends upon the combination of heparin and platelet function inhibitors, rather than on anticoagulation alone, thus indicating that more than a single mechanism is at work. Fibrinogen survival returns to normal some time before platelet survival. This fact may indicate that tissue injury of the vascular endothelium results in the release of tissue thromboplastin into circulation, producing a minor component of intravascular consumption. Or, bubble-induced flow changes may affect the microcirculation sufficiently to produce stasis and fibrin formation in low flow areas. It remains to be determined whether these hemostatic changes can produce thrombotic occlusion leading to dysbaric osteonecrosis, and whether this can be prevented by anti-thrombotic treatment. (MFW/UMS)

SMITH, K.H., P.J. Stegall, L.A. Harker and T.W. Huang.
Hemostatic function changes in the pathogenesis of decompression sickness.
In: Abstracts of papers presented at Undersea Medical Society Annual Scientific Meeting, May 10-11, Washington, D.C. Undersea Biomedical Research. 1:A21; March 1974.

Abstract only. Entire item quoted: Hematologic studies done in this laboratory have demonstrated that abnormalities occur following asymptomatic decompressions and that they may be causative factors in symptomatic decompression. These abnormalities can be monitored by following kinetic measurements of the survival of hemostatic factors. These changes could not be prevented by anticoagulation alone, thereby indicating that more than a single mechanism was operating to produce the increased platelet and fibrinogen consumption. This was supported by the finding that fibrinogen survivals returned to normal by the end of the first post-dive week, after which only platelet consumption was involved. The persisting shortened platelet survival was thought to be the result of the platelet response to vessel damage, and reflected the time required for healing of the damaged vascular endothelium. Since the combination of platelet function inhibitors and anticoagulants could prevent the hemostatic changes, these substances could be used to prevent aseptic bone necrosis, if caused by a thrombotic infarct. In those animals in which anticoagulants and platelet inhibitors were used, bony aseptic necrotic infarcts were produced in a shorter period of time and with fewer compression/decompression episodes. The pathologic event explaining this situation includes a hemorrhagic infarct as a result of endothelial damage.

STEGALL, P.J., K.H. Smith and J. Hildebrandt.
Aseptic bone necrosis and hematologic changes in miniature pigs as the result of compression/decompression exposures.
Federation Proceedings 31:653; March/April 1972.

Abstract only. Entire item quoted: Aseptic bone necrosis was produced in one of five miniature pigs exposed to a combination of decompression profiles varying in rate from fast (65.5 fpm) to slow (5-1.3 fpm). A suspicious area in one of the femoral metaphyses found three months after the pig's initial dive became more radiolucent in the following three months, and additonal radiolucencies were noted in the other femur and bilaterally in the humeri. A diagnosis of aseptic bone necrosis was confirmed by biopsy. "Bends" thresholds fell in each pig with successive stress; one possible explanation for this induced sensitivity may be the presence of gas nuclei persisting from one exposure to the next, initiating bubble formation at lower degrees of supersaturation. After each exposure, significant decreases in fibrinogen concentration and thrombin times were noted. Platelet adhesiveness was elevated 25% immediately post-dive, but platelet counts were maximally decreased (>50%) 24-48 hours later. Reticulocyte counts fell significantly as well. CPK levels increased markedly in samples drawn after both fast and slow decompression rates, while LDH values fell by >30% in the same samples. Serum lipid levels rose >30%, with the greatest changes being in triglycerides and phospholipids. Hematologic and chemical changes were not always accompanied by observable symptoms, suggesting that disseminated intravascular coagulation (consistent with this picture) may occur without clinical evidence of decompression sickness.

STEGALL, P.J. and K.H. Smith.
The etiology and pathogenesis of decompression sickness: radiologic, hematologic and histologic studies in miniature swine.
In: Abstracts of the Fifth symposium on underwater physiology, Freeport, Bahamas, August 1972, p.26. Published by the Symposium.

Abstract only. Entire item quoted: The production of aseptic bone necrosis was attempted in seven miniature swine exposed to a combination of decompression profiles varying in rate from fast (65.5 fpm) to slow (5-1.3

fpm). Suspicious sclerotic and radiolucent areas in both femoral and humeral metaphyses were observed radiographically two months after repeated exposure in one pig, three months in two others. A diagnosis of aseptic bone necrosis was confirmed by biopsy in one of these. "Bends" thresholds fell in each pig with successive stress; one possible explanation for this induced sensitivity may be the presence of gas nuclei persisting from one exposure to the next, initiating bubble formation at lower degrees of supersaturation. Significant decreases in fibrinogen concentration and thrombin times were noted in all pigs after exposure. Platelet adhesiveness was elevated 25% immediately post-dive, but platelet counts were maximally decreased (50%) 48 hours later. CPK levels increased markedly in samples drawn after both fast and slow decompression rates, while LDH values fell by 30% in the same samples. Intravascular coagulation was suggested by the presence of pooled plasma and aggregated platelets found in necropsy specimens taken from a pig who died of acute decompression sickness. Histologic preparations demonstrated striking arterial inflammation, excessive fibrin strands in pooled serum, dilated arterioles, progressive fat necrosis and interstitial extravasation. Hematological and chemical changes, however, were not always accompanied by observable symptoms, suggesting that disseminated intravascular coagulation may occur without clinical evidence of decompression sickness.

STEGALL, P., K. Smith and J. Hildebrandt.
Selective platelet destruction and dysbaric osteonecrosis in miniature pigs after decompression.
Federation Proceedings 32(3, pt.1):835; March 1973.

Abstract only. Entire item quoted: Of 11 pigs chronically exposed to hyperbaric pressure (60 fsw for 6 hrs.) with fast decompression (30 fpm), 3 died of decompression sickness or "the bends". The remaining developed dysbaric osteonecrosis within 6 weeks to 1 year, seen by biopsy or radiographically. Osteonecrosis here is due to occlusion of bone blood flow as seen histologically. To better explain the observed thrombocytopenia and bone infarcts, a kinetic study of platelet and fibrinogen survival and turnover times was done. While fibrinogen values remained essentially unchanged, platelet survivals shortened from a normal 5 days (± .5 days) to 1 day (± .2 days) following single exposures with fast decompression. These values remained shortened up to 6 weeks at which time a progressive return to normal baseline was documented. Platelet plugs, bubbles and probable endothelial damage were seen histologically. Either abnormal surfaces (e.g., bubbles) or endothelial injury may be responsible for this predominant platelet destruction; because [the shortening of the survival time] persists, however, we interpret the data as disseminated vessel damage. Present studies will determine if platelet function inhibitors are able to interrupt the increased rate of consumption, and in turn lead to prevention of osteonecrosis.

STETSULA, V.I., I.I. Tal'ko and V.M. Krivenko.
E sperimental'noe obosnovanie primeneniya khimotripsina pri lechenii ascepticheskogo nekroza kostei.
[Experimental study of chymotrypsin in the treatment of aseptic necrosis of bone].
Ortopediia, Travmatologiia i Protezirovanie 34:72-74; January 1973.

The authors studied the action of chymotrypsin on experimental aseptic necrosis in dogs, employing radiographic and histological methods. In the chymotrypsin-treated animals regenerative processes in the bone tissue and bone marrow were observed. Chymotrypsin enhanced blood circulation by speeding up revascularization in the necrotic tissues. Fresh erythrocytes, macrophages and neutrophilic leukocytes were detected in the necrotized zone, proving that chymotrypsin stimulated the hematopoietic activity in the regenerating bone marrow. The dogs were observed for three to four months following the initial induction of thrombosis. Chymotrypsin was administered in repeated ten-day courses. On the 180th day the bone structure was found to be completely regenerated, regardless of the extent of the necrosis. The authors theorize that parenterally administered chymotrypsin stimulates local blood circulation by depolymerizing proteins in the necrotic inflammation zone. Blood circulation enhances bone regeneration as well as the hematopoietic activity of bone marrow. Based on experimental results, the authors recommend repeated doses of chymotrypsin in the treatment of aseptic necrosis in man. (OLC/UMS)

STREDA, A.
Participation of osteonecrosis in the development of severe coxarthrosis.
Acta Universitatis Carolinae Medica Monograph 46:9-166; 1971.

This extensive monograph is divided into two sections: (1) Detailed analysis of the X-ray picture of osteonecrosis of the hip joint; (2) Participation of osteonecrosis in the development of severe coxarthrosis. There is a short discussion devoted to hyperbaric osteonecrosis, in which it is stated that "extensive necrotic change in the hip joint were first described in caisson workers." It is attributed to gas embolism. The differences between necrosis from caisson disease and that caused by infarction are discussed, both as to developmental characteristics and location. (MFW/UMS)

STUTZER, H.
Bone necrosis in tunnel workers. (Letter to the editor)
Lancet 2(7879):530; August 31, 1974

In this brief communication the author refers to recent cases of decompression sickness during the building of the second Elbe tunnel and two new Undergrounds in Germany. He challenges a statement made in a recent editorial (see Anonymous; Lancet 2(7875):263-264; Aug. 3, 1974) that orthopedic treatment of necrosis of the femoral or humeral head is unsatisfactory. He refers to a case in which a St. George hip-joint prosthesis was successfully implanted in a 28-year old man. (See Stutzer and Buchholz, Monats. Unfallheilk. 76:525-527; Nov. 1973). (MFW/UMS)

STUTZER, H. and H.W. Buchholz.
Operative behandlung der Socarthrose bei Caissonkrankheit.
[Surgical treatment of coxarthrosis in caisson disease].
Monatsschrift fur Unfallheilkunde und Versicherungsmedizin 76:525-527; November 1973.

A total hip prosthesis in a case of coxarthrosis following decompression sickness is described. The importance of this method is discussed. (From English summary).

WALDER, D.N.
Bone lesions in divers.
Journal of Bone and Joint Surgery 56B:1-2; February 1974.

In this brief editorial, the author makes some general observations on the incidence of osteonecrosis in compressed air workers and in divers, as discovered in surveys made during the past few years. Although the disease has occurred in divers and workers who have observed the currently accepted decompression tables, it is still generally believed that it is decompression-connected. Japanese divers, who observe no decompression control at all, have an overwhelming incidence of osteonecrosis (more than 70% in all with more than ten years of diving experience). This would appear to refute the theory that compression rate is involved, since the Japanese divers were not subjected to rapid compression. New decompression tables have been computed by the Construction Industry Research and Information Service, and it is hoped that their observance will reduce the incidence of osteonecrosis. (MFW/UMS)

WELFLING, J. and S. De Seze.
Necrose de la tete humerale.
[Necrosis of the humeral head].
Nouvelle Presse Medicale 2:2311-2312; October 6, 1973.

The diagnosis and etiology of humeral head osteonecrosis are discussed. Humeral head osteonecrosis is diagnosed radiologically. X-ray photographs show lesions similar to those of femoral head necrosis. The first radiological signs generally precede clinical symptoms, and the disease may have an evolution of several years. Like femoral head necrosis, humeral head necrosis is usually associated with some other disorder, such as disseminated lupus erythematosus, decompression sickness, hemoglobinopathies, hyperlipidemic obesity, and long-term corticotherapy. The microembolisms occurring during these conditions are thought to be responsible for the bone ischemia which is the cause of the disease. (MEMH/UMS)

WISE, R.A.
A review of health and safety of deep divers.
Industrial Medicine 39:21-27; December 1970.

In this survey of the health hazards confronting divers, osteonecrosis is touched upon. It is noted that the disease is much less frequent with divers than with tunnel workers, presumably because the former, although they go much deeper, do not do nearly so much physical labor. A theory has been proposed that maintenance of proper body chemistry and gas exchange will prevent osteonecrosis, but this is unproven. (MFW/UMS)

WORKMAN, R.D.
Experience with modified U.S. Navy helium-oxygen decompression schedules, saturation decompression and evaluation of divers for aseptic bone necrosis.
In: The working diver – 1974. Symposium proceedings, March 1974, Columbus, Ohio, p.377-385. Washington, D.C., Marine Technology Society, 1974.

Modified U.S. Navy helium-oxygen decompression schedules have been employed for 768 dives to depths from 180 to 350 feet with an incidence of 0.5% bends resulting. Bottom times were 80 minutes at 180 feet to 40 minutes at 350 feet with hard work performed. Thirty-nine saturation operations have been conducted in 1973 with 234 men under pressure for a total of 2409 days. Four bends occurred in 234 men decompressed for an incidence of 1.7%. Over a period of three years, 400 bone surveys have been done for diver applicants with only six men determined to have lesions of aseptic necrosis of bone, all of which occurred in shoulder joints. None of the affected divers had participated in saturation diving. (Author's abstract)

WUNSCHE, O. and G. Scheele.
Knochencysten bei Albinoratten nach Dekompression aus Uberdruck.
[Bone cysts in albino rats following decompression from high pressure].
Archiv fur Orthopaedische und Unfall-Chirurgie 77:7-16; 1973.

In a series of experiments albino rats were subjected to repeated decompressions from high pressure. After 274 days cysts were demonstrated in bone segments close to the joints. These findings are the unequivocal consequence of the experimentally induced decompression sickness. Hence a model follows for skeletal alterations after high pressure exposure. (English abstract)

INDEX

Alcohol, Alcoholism
  in bends etiology, 233
  in differential diagnosis, 155
  as fat solvent, 143
  as osmotic agent, 137, 141
  in osteonecrosis etiology, 29, 87-90, 91-93, 94, 102
Animal studies. *See* Experimentation
Ariake Bay divers, 105
Arteriosclerosis, 99, 102, 155
Arthralgia, hyperbaric, 139
Arthritis, degenerative, 9, 76-77, 79, 81, 152, 196
  complicating osteonecrosis treatment, 206, 208
Arthrodesis, 205, 206, 207, 208
Arthroplasty, 205, 206, 210
Arthrotomy, 77
Atmospheres absolute (atm abs), definitions of, 83
Aviators. *See* Surveys, U.S. Air Force

Bay Area Rapid Transit (BART) project, 25-40, 56
Bends (Limb-bends; musculoskeletal decompression sickness)
  acclimatization, 31, 33
  etiology, 55-56
  incidence. *See* Incidence
  onset of symptoms, 30-31, 190
  and osteonecrosis, 3, 17-18, 33, 42 (Fig. 1), 43, 105 *ff.*, 184 (Fig.), 190, 241-242
  prevention of, 44, 55-56
  threshold, diver vs. caisson worker, 168
  treatment. *See* Oxygen; Recompression; Tables, U.S. Navy
  ultrasonic changes during, 51. *See also* Ultrasonics
  vertigo, 83
  See also Dysbarism
Beryllium workers (U.S.), disease registry, 215, 239
Blood
  -cell aggregation, 31, 33, 35, 39, 89, 109
  -chemistry studies, 105 *ff.*, 128, 133-136, 144, 145, 146, 148
  coagulation
    abnormalities, 87 *ff.*, 111
    in fat embolism, 129, 143
    studies, 135 (Tables I, II)
  erythrocytes. *See* Erythrocytes
  flow
    in bone, 114, 127, 139, 141, 144, 147, 190, 244
    following compression–decompression, 34, 55, 133-136
  perfusion, 35, 133
    impaired, 83, 129
    rate, 47 *ff.*
  platelets. *See* Platelet
  viscosity, in pressure change, 134, 144, 145, 146
Bone
  appositional new, formation of, 70 *ff.*, 110, 111 (Fig. 10), 123 *ff.*, 162, 192, 211
  biosynthesis, 61 *ff.*
  cartilage. *See* Cartilage
  collagen, 61-65, 126, 137
  cortical thickening in, 109, 154
  crystal, structure of, 171, 190
  disuse atrophy of, 70 (Fig. 4), 73, 76, 80 (Fig. 24)
  dysplasia vs. necrosis of, 151
  endosteal thickening of, 109, 160, 167 (Fig. 7)
  fiber bundles, 126
  fracture of, pathologic, 163, 164 (Fig.)
  gas formation in, 52-53
  grafts, to revascularize, 76, 202-203, 210
    Phemister technique, 210
  islands, 11 (Fig. 2), 19, 41, 169, 198
  marrow. *See* Marrow
  metabolism, 61 *ff.*, 190-191
    demonstrated by ^{18}F, 172
  mineralization, 61, 137, 141
  necrosis. *See* Lesions; Osteonecrosis
  repair of necrotic. *See* Lesions, repair of
  resorption, 61-65, 70 *ff.*, 211
  revascularization of necrotic. *See* Lesions, revascularization of
  scans. *See* Isotopes
  surveys. *See* Surveys
  survival, following ischemia, 148
  vascular supply of, 125
    blockage of, 90, 111, 114, 115-116, 120 (Fig. 3), 143, 242
  viability, 148
  See also specific bones
Bromsulphalein retention, abnormal, 91, 93, 95, 183
Bubbles, inert-gas, 32, 34, 35, 37, 39, 44, 51 *ff.*, 56-57, 109-111, 143, 145, 241-242, 244-245
  in bone, 127, 143, 242
  osteonecrosis, relevance in, 39, 241-242
  photomicrographs of, 133, 134
  "silent," 31, 51 *ff.*, 53, 140
  ultrasonic detection of. *See* Ultrasonics
  in vascular system, 56-57, 114, 127, 134, 145, 244

Caisson workers. *See* Compressed-air workers
Carbon dioxide
  in bends etiology, 44, 55-56, 233
  transport of, tissues to lungs, 37
Cartilage, articular
  as controlling factor in osteonecrosis, 77-79, 80-81, 165, 202, 245
  fracture in, 77, 203-204
  osmosis across, 137 *ff.*
Chambers, compression, 29-30, 34, 39
"Chokes," 33, 243

Coal Mine Safety and Health Act, 222, 223, 224, 236, 247
Collagen, 61-65, 126, 137
Compressed-air workers, 31, 56
  diseased, rehabilitation of, 46, 201, 233, 234
  disqualifying conditions in, 19, 28-29, 39, 43 (Fig. 2), 45-46, 209
  dysbarism in, 3, 30 *ff.*, 48, 140
  federal (U.S.) standards *re*, 41, 55
  minimizing work hazards of, 25, 28, 39, 44-45, 55
  osteonecrosis in, 3-4, 43-46, 48, 113, 140, 191 (Fig.), 195-196
  See also Pressure exposures; Registry; Surveys; Tunnel construction
Compression
  –decompression, repeated, 39, 52, 53, 127-128
  effect of, on blood viscosity, 134, 144
  rapid, implications in osteonecrosis, 140-141, 147
  rates of, 55, 141
  therapy. *See* Recompression
Computer analysis of bubble formation. *See* Ultrasonics
Contaminants
  in tunnel construction, 44, 215-216, 233
  undersea vs. tunnel, 55
Contractor
  diving, problems and liabilities of, 221, 225, 229-230, 231, 235, 236
  tunneling, U.K., Registry requirements of, 217
Cortical thickening, 109, 154
Corticosteroid(s)
  experimentation, 117
  therapy. *See* Steroid therapy
Creeping substitution, 72, 73, 74, 148, 192, 244
  age relationship in, 79-80, 81
  definition of, 70-72 (Fig. 7, 9)
  pathologic fracture in area of, 75, 77

Data banks, 223-226. *See also* Registry
Decompression
  chambers. *See* Chambers
  –compression, repeated, 39, 52, 53, 127-128
  isobaric. *See* Oxygen, "window" concept
  length of, vs. protocol, 34, 35, 39, 44
  physiological effects of, adverse, 34-35
  protocols
    differences, diver vs. tunneler, 33
    and dysbarism/osteonecrosis, 31-35
    inadequate, 41, 44, 47, 57, 105 *ff.*, 109, 111, 142
    See also Tables
  rapid, implications of, 39, 128, 140, 141, 143, 147, 241
  sickness. *See* Bends; Dysbarism
  sleep's effect on, 48, 51
  stage, 33, 37, 51
  straight-line, 44, 55
Decompression (*continued*)
  surface, 37
  tables. *See* Tables
  theory, 36-37, 47 *ff.*, 241
Decompression Sickness Panel (U.K.), 3-5, 9, 31, 35, 224
Diagnosis and measurement techniques
  biochemical, 143, 148
  biopsy, 157 (Fig. 5), 187-188, 196
  densitometric, 119 *ff.*
  differential, 146, 155
  intramedullary pressure, 140-141, 144, 145, 186, 210
  isotopes. *See* Isotopes
  osmometer, 138
  oximetry, 186
  phlebography (venography), 145, 186-187, 196, 201-202
  radioautography, 119 *ff.*
  radiology, a general criterion, 152. *See also* Roentgenography
  radionuclides. *See* Isotopes
  scintillation detector probe, 185-186, 192, 209-210
  tomography. *See* Roentgenography, tomography
  ultrasonics. *See* Ultrasonics
  viscometer, 145
  xeroradiography, 177-181, 191, 195, 245
Divers
  amateur scuba, 223, 224
  dysbarism in, 7-8, 25, 190
  ———— registry for. *See* Registry
  legislation *re*, protective, 221-222, 224, 225, 229-230
  osteonecrosis in, 7-8, 19-20, 113, 167 (Fig. 7), 195-196
    commercial, 9-15, 209, 243, 244
    experimental, 8, 209, 243
    Royal Naval, 7-8, 140, 155 *ff.*, 209, 243
    U.S. Navy, 8
  reducing risks to, 223-224
  vocational rehabilitation and pensioning of, 224
Diving
  contractor. *See* Contractor
  excursions, repetitive, 39, 51
  experimental, 140, 190
  federal (U.S.) standards for, 222, 234, 239-240
  helium, 37, 209, 231
  repetitive, 49, 50, 51, 53, 105 *ff.*
  saturation, 37, 39, 48, 51, 57
    scanning survey following, 190
  See also Pressure exposures
Doppler ultrasonic detector. *See* Ultrasonics
Drugs
  addiction to, 92-93
  in dysbarism treatment, 129, 241
"Dry joints," 139

Dysbarism (Decompression sickness)
acclimatization and resistance to, 30, 31, 33, 34, 52
asymptomatic, 106, 241
bends. *See* Bends
"chokes," 33, 243
CNS manifestations, 23, 33, 233
cutaneous manifestations, 34, 52
effects of pressure-change rate, 140
etiology, 44, 55-56, 127, 128, 135-136, 241
and fat embolism, 127-130
fatal, 17, 31, 106, 109, 115, 215, 245
clinical findings (one case), 83-84
and gas embolism, 56-57
incidence. *See* Incidence
and osteonecrosis, correlation between. *See* Osteonecrosis, and dysbarism
registry. *See* Registry
"staggers," 33
time interval, after decompression, 30-31
treatment
drug, 129, 241
hypothermia, 129
See also Oxygen; Recompression; Tables
Types I and II, definitions of, 30
See also Blood; Bubbles; Compressed-air workers; Divers

"Elastic modulus," 52, 126

Emboli, Embolism
air, 36, 56, 127
artificial
glass spheres, 115, 116 (Fig. 5)
Lipiodol, 117-125
fat
experimentally induced, 117-130, 143
fatal, 83-84, 245
intraosseous, 126 (Fig. 13), 127, 129
laboratory tests for, 183
relative to dysbarism, 31, 91, 128, 245
relative to osteonecrosis, 91 *ff.*, 117-130, 143, 244
gas-bubble. *See* Bubbles

Enchondroma, 155, 157 (Fig. 5), 187

Endosteal thickening, 109, 160, 167 (Fig. 7)

Erysipelas, 145

Erythrocytes, Erythroid
aggregation of, 133-136, 244
after decompression, 134, 145-146
disintegration of, 121, 125
hyperplasia, 97, 98 (Fig. 7)
sickled, 97

Excursion saturation diving, 51

Exercise, relative to decompression, 31, 38

Experimentation in pressure exposures
animal
dogs, 127, 128, 129, 140-141, 146
——, rheological changes in, 133-136
hamster, 145
rabbits, 127-128
———, dysbaric osteonecrosis in, 117 *ff.*
sheep, 114-115
swine, miniature, 105-111, 113-114, 145-146
human, 32-33, 190

Fat, Fatty
body, and dysbarism, 36
embolism. *See* Embolism, fat
lipid studies, 105 *ff.*, 128-129
marrow. *See* Marrow, fatty
tissues, and gas transport, 36

Femur, Femoral, 67 *ff.*, 87 *ff.*
atrophy, 69 *ff.* *See also* Wolff's law
embolization in marrow of, 83
head
blood supply to, 68, 186
————, in rabbit, 119
————, in sheep, 114
fat embolism in, 129
————, in animals, 117 *ff.*
fracture of, 70-71, 74-75, 98
idiopathic necrosis of, 98, 187, 188 (Fig. 5)
lesions in, 74, 92 *ff.*, 125, 148, 160, 163-165, 173, 174 (Fig.), 184 (Fig.), 191 (Fig), 202 (Fig.)
————, in nondecompression cases, 87 *ff.*
————, postmortem findings, 115, 244
————, significance of, 4
ligamentum teres, 68, 74, 114, 119
neck
blood supply to, 67-68
fracture of, 74, 98, 147, 148, 165
————, fatigue, 98-99
lesions in, 168 (Fig.), 173, 175 (Fig.)
necrosis, in animal experimentation, 120 *ff.*
revascularization, 185, 210
————, surgical, 198, 202, 210
shaft, lesions in, 44, 113, 153 (Fig.), 156 (Fig.), 230
trauma to, 98-99
age and healing process, 74, 79-80, 81
sequelae of, 69 *ff.*
vascular supply to, 67-69, 74, 144-145
interruption of, 114-116, 125, 244
See also Bone; Hip; Lesions

Fibula, osteonecrosis in, 155, 157 (Fig. 5)

Fluid shifts, in tissue. *See* Osmosis

Fluorine-18 bone scans, 171 *ff.*, 185, 190

Gas, inert
bubbles. *See* Bubbles
diffusion, 37, 51
embolism, 56-57, 127, 134, 143, 245
formation, in bone, 52-53
solubility, 47, 138, 141
in solution, 31, 37, 47 *ff.*
supersaturation, 47 *ff.*, 241
in blood, 36
in bone, 47, 53
in tissue, 146-147
transport
impairment of, 34-35
theoretical models, 47-48
tissue to lung, 36-37
ultrasonic detection. *See* Ultrasonics
uptake and elimination, 51-53
See also Tissues; specific gases
Gaucher's disease, 88, 91, 102, 155
Gout, 88, 90, 93, 155
Government regulations, occupational hazards, 223-226. *See also* Beryllium; Coal Mine; Divers; Diving, federal standards; Jones Act; Longshoremen's Act; Occupational Safety; Registry

Habitats, compressed-air
excursions from, 39, 51
residence in, 40
Hageman factor, 90, 143
Haldane's theory, 36, 47, 51, 52
Half-saturation times. *See* Tissues
Haversian systems, 108, 121, 124, 126, 144
Helium
diving, 7-8, 51, 209
exposure, 52
transport, 37
Hemoglobinopathies, 29, 91, 95-98
necrosis involvement, in children, 97
Heparin therapy, 129, 241
Heroin addiction, 92-93
Hip, Hip joint
lesions in, 43, 45 (Fig.), 46 (Fig. 6)
incidence of, 9, 157 (Fig. 6), 158 (Fig. 7)
osteonecrotic degeneration of: a case history, 10-14
radiologic technique *re*, 154
revascularization of, 198
surgical repair of, 198, 199, 205-207, 210. *See also* Management and treatment
treatment of, following trauma, 75-76
See also Bone; Femur; Lesions
Howship's lacunae, 70, 72 (Fig. 10), 73 (Fig. 12)
Humerus, Humeral
in animal experimentation, 106, 109, 110 (Fig. 9)
head, 113
collapse of, 46 (Fig. 7), 96 (Fig. 4), 185
embolism of, 129
lesions in, 114-115, 154, 160, 173, 174 (Fig.), 175 (Fig.), 196-199
radiologic techniques *re*, 154, 155, 185
lesions in, 11 (Fig. 2), 13 (Fig. 4), 152 (Fig. 2), 161 (Fig. 1), 164 (Fig. 4), 180 (Fig. 6), 181 (Fig.)
revascularization of, spontaneous, 185. *See also* Lesions, revascularization
See also Bone; Lesions; Shoulder
Hyperbaric workers, U.S., population at risk, 221
Hypercorticism, 155
Hypercortisonism, 91, 94-95, 117
Hyperlipemia, 88, 90, 92, 94, 117, 128, 143, 183
Hyperuricemia, 88, 89, 90, 93, 94
Hypobaric exposures, 8, 17-18
Hypovolemia, in fatal dysbarism, 83

Incidence
bends, in tunnelers, 23, 44, 140, 233
dysbarism, in tunnelers, 30 *ff.*, 244
———, reduction of, 39-40
osteonecrosis
in aviators, 17-18
in divers, 7-8, 9-14, 19-20, 105, 160
in tunnelers, 3-4, 33, 35, 41, 140, 234
———, reduction of, 39-40
Insurance, and hyperbaric exposure, 221, 223-224, 231, 233-234, 235
population at risk, U.S., 221
Ischemia, 126, 137, 144, 148
after compression–decompression, 127, 146
damage to cells, 135
delayed, after pressure exposure, 137, 141
etiology of, 91
and sickle-cell disorders, 97
vasculitis relative to, 95
Isotopes, radioactive, in scanning, 196, 210
in animal experimentation, 119 *ff.*
calcium, 171, 185
comparison of, 172 (Table I)
cost of, 190
as diagnostic technique, 145, 171-176
fluorine, 171-176, 185, 190, 210
phosphorus, 119 *ff.*, 185-186, 192, 210
pre- and postdive findings, experimental, 190
vs. radiological findings, 173-176, 190, 245, 246
strontium, 171-173, 190, 191-192, 210
technetium, 185, 246
time lapse, from insult to positive findings, 190-191

Jones Act, 223, 229, 230, 236

Knee
incidence of bends in, 201
lesions in, 9, 44
radiographic technique *re*, 154, 155
surgical treatment of, 77-78

Labor unions, and hyperbaric workers, 225, 226, 235
Legal aspects of diving and tunneling, 222, 223-224, 225, 229-230, 233-234, 235-236
Legg-Calvé-Perthes disease, 79, 80 (Fig. 24), 81, 91
Leriche syndrome, 99
Lesions, osteonecrotic
asymptomatic, 3, 4, 29, 33, 35, 43, 44 (Fig. 4), 87, 140, 151, 154, 195, 201, 241-242
classification of (MRC), 3, 9, 151-152, 160
figures illustrating, 161-168
cortical thickening, 109, 154
disabling vs. nondisabling, 160, 168
distribution of, 4, 7, 9-10, 29, 92, 157, 158, 201
in divers vs. caisson workers, 113, 152, 166-167, 209, 244
and dysbarism. *See* Osteonecrosis, and dysbarism
endosteal thickening, 109, 160, 167 (Fig. 7)
epiphyseal, 19, 94, 98, 162, 163-165, 201
etiology of. *See* Osteonecrosis, etiology
incidence of. *See* Incidence
interpretation of, 161-166
intramedullary, 17-18. *See also* Marrow
juxta-articular, 29, 34, 41, 113 (Fig. 1), 151, 183, 195
classification of, 9
collapse in, 152, 154
and further pressure exposure, 99, 209, 245
progression of, 152 (Fig. 2)
significance of, 9, 15, 45
as therapeutic problem, 196
medullary, 10 (Fig. 1), 113, 153 (Fig.)
classification of, 9, 151
metadiaphyseal, 93, 99, 201
metaphyseal, 19, 162
progression of, 114-115, 152 (Fig. 2), 154, 157 (Table I), 190, 191, 196 *ff.*, 209
repair of, 114, 115, 123, 129, 147, 148, 190, 192, 196, 202, 210, 244. *See also* Creeping substitution
revascularization of, 186, 211
spontaneous, 81, 126-127, 185, 210
surgical procedures for, 198, 201-203, 210
shaft, significance of, 209, 230, 234
sites typically affected, 4, 7, 48
snowcap, 12 (Fig. 3), 43, 161, 162 (Fig. 2), 163, 185
Stages I, II, and III, definitions of, 201-205, 206
unsalvageable, 204
See also Bone; Osteonecrosis; Surveys; specific bones

Lipids. *See* Emboli, fat; Fat
Lipiodol embolism, experimentation, 117-130
Liver
disease, 88, 89-90, 91-93, 102
———, and heroin dependency, 92-93
as fat depot, 91, 94
in osteonecrosis etiology, 128-129
fat embolism in, 117, 120
Longshoremen's Act, 229, 236
Lung
disease, 102, 222, 247
fat embolization in, 83, 84 (Fig. 2), 117, 120, 127, 128, 130, 143
gas transport, tissue to, 37
"vascular waterfall" theory *re*, 141

M-values, 47 *ff.*
Management and treatment of osteonecrosis, 44-46
bed rest, 46, 196, 202, 245
continued work in compressed air, 195, 201, 209, 225, 245, 247
in divers and caisson workers, general, 195-199
drugs, 246
prostheses, 198, 199, 210
advisability of, 46, 198
arthroplasty, 205, 206, 208, 210
restricted activity, 195, 201
revascularization procedures, 198, 201-203, 207, 210
surgical repair, 76, 77-78, 197-199, 245
arthrodesis, 205, 206, 207, 208
arthrotomy, 77
osteotomy, 205-206, 207
Marrow
erythroid hyperplasia, 97, 98 (Fig. 7)
fatty, 52, 70, 98
necrosis of, 69 *ff.*, 93-94, 97, 109 (Fig. 6), 122 *ff.*
regeneration of, 70 *ff.*, 123, 124, 126, 127, 130
role in dysbarism, 47, 48, 51
role in osteonecrosis, 47, 48, 52, 121 *ff.*
sensitivity to O_2 toxicity, 52
gas formation in, 47, 51-53, 127-128
hemorrhage in, 83
intramedullary pressure in, 141, 144, 145
experimentation in, hyperbaric, 140-141
and sickle-cell disorders, 97-98
supersaturation in, 47 *ff.*
Measurement, techniques of. *See* Diagnosis and measurement
Medical Research Council, U.K., 3-5, 19-20, 45, 155, 166, 215, 225, 245
osteonecrosis classification of, 9, 151-152, 160
Metabolism
of bone, 61 *ff.*, 190-191, 210
disorders of, osteonecrosis-related, 87 *ff.*, 91 *ff.*

Milwaukee tunnel project, 41-46
decompression tables used in. *See* Tables, Washington State
workmen's compensation aspects of, 233-234

National Institute for Occupational Safety and Health (NIOSH), 239-240, 245-246
Nitrogen
in dysbarism etiology, 127, 128
exchange, in tissues, 48
osmosis, 137
in osteonecrosis etiology, 129
oxides, adverse effects of, 55
tissue tension, in repetitive pressure exposures, 49, 50
transport, 34, 35, 36
uptake and elimination from tissues, 38, 40, 51-53, 55
Nitrous oxide, as osmotic agent, 137-138

Occupational Safety and Health Act (OSHA), 41, 221, 234, 236, 239-240
Osmometer, 138 (Fig. 1)
Osmosis
gas-induced, 137 *ff.*, 144, 244
hypothesis *re*, in delayed ischemia, 137
Osteoarthritis, 13 (Fig. 4), 165 (Fig. 5), 166, 173
Osteochondritis dissecans, 77-78, 79 (Fig. 21, 22, 23), 165
Osteonecrosis
acclimatization factors in, 4
age relationship to, 7, 87, 93
associated conditions in avascular, 87 *ff.*, 102
asymptomatic. *See* Lesions, asymptomatic
case histories of, 10-14, 17, 233
clinical characteristics of, 87 *ff.*
correlatives between, and hyperbaric exposure, 4, 243
detection of, via urinalysis, 65
and dysbarism, correlation between, 3, 7-8, 17-18, 29, 31, 47-48, 65, 67, 105 *ff.*, 113, 127-130, 184 (Fig.), 190, 198 (Fig. 4), 233, 241-242, 243
physiological aspects of, 137-142
etiological considerations in, 3-4, 31, 39, 44, 47 *ff.*, 87-90, 115-116, 125, 126 (Fig. 13), 127-130, 143, 221, 241, 242, 243-245
experimentally induced, in animals, 117-130
dysbarism-related, 105-111, 113-115
in hyperbaric exposures, specific. *See* Pressure exposures
in hypobaric exposures, 8, 17-18
idiopathic, 79, 88 (Fig. 1), 91 *ff.*, 141

Osteoneocrosis (*continued*)
incidence of. *See* Incidence
management and treatment of. *See* Management and treatment
metabolic implications in, 61 *ff.*, 87 *ff.*, 91 *ff.*
nondecompression-related, 87-90
pathophysiology of, 53, 67 *ff.*, 129, 160
prevention of, 25, 35, 56, 130, 235, 244, 246
prognosis in, 78, 79, 245
repair process in. *See* Lesions, repair
replacement process in, 70 *ff.*, 81, 162, 163, 165, 192, 210-211
age relationship to, 74, 81
See also Creeping substitution
surveys. *See* Surveys
time lapse, between insult and, 56, 143, 146-148, 217, 244
trauma-induced, 98-99
treatment of. *See* Management and treatment
See also Bone; Compressed-air workers; Divers; Lesions; Roentgenography; specific bones
Osteotomy, 205-206, 207
Oximetry, differential, 186
Oxygen
in decompression practice, 25, 37-38, 40
diffusion in tissues, 37
as fire hazard, 29, 37
high-pressure, effects of, 53
hypoxia, 135
inhalation regulator, 39
therapy
in dysbarism, 18, 23, 29, 34, 38
in other conditions, 39, 137
toxicity, 52
"window" concept, 34, 37, 38, 51, 53

Pancreatitis, 93-94, 102, 155
Phosphorus, radioactive, 119 *ff.*, 185-186, 192, 210
Physical examinations, pre- and postemployment, 19, 25, 28-29, 39, 41, 91, 99, 217, 221, 224
as employee–employer protection, 235-236
insurance requirements, Wisconsin, 233-234
labor-union attitude toward, 225, 226
Platelet
aggregation, 31, 39, 109, 129, 130
counts, abnormal, 88-90, 105-106, 143
———, in experimental pressure studies, 105 *ff.*
———, in osteonecrosis, 88 *ff.*
Poseidon, H. M. Submarine, 147
Pressure changes, rapid, dangers of, 140
Pressure exposures
acclimatization to, 4, 36
experimental. *See* Experimentation
monitoring of, 235
pneumatic analogue computation of, 51

Pressure exposures (*continued*)
repeated, and osteonecrosis, 3, 4, 19, 137
repetitive, 17, 49, 50, 51, 105
specific
leading to dysbarism fatality, 83-84
leading to total disability, 233
maximum safe, 41, 195, 209, 243

Professional divers
International Association for, 225
labor unions and, 225, 226, 235

Prostheses. *See* Management and treatment

Pseudoarthrosis, 75, 210

Radiation exposure in diagnostic techniques, 3, 42, 102, 171 *ff*., 178-179, 185, 191
pelvic shielding against, 42, 154

Radioautography, 119 *ff*.

Radionuclides. *See* Isotopes

Recompression, therapeutic, 7, 17, 23, 29, 31, 128, 129, 130
chamber, 29
U.K. registry *re*, 215
worker reluctance *re*, 31, 241, 242

Registry, central, decompression-sickness, 154, 246
U.K. (MRC), 3-5, 140, 155, 195, 215-219, 224
U.S. proposals for, 53, 221-222, 223-224, 235

Regulations, federal, *re* occupational hazards. *See* Government regulations

Renal transplantation, 94-95, 96 (Fig. 4, 5)

Research, future goals for, 57, 246

Revascularization. *See* Lesions; Management and treatment; specific bones

Reynaud's disease, 88

Roentgenography, Roentgenographic
A-P/frogleg, comparisons of, 14 (Fig. 6), 19, 42, 79-80, 154, 155
criteria, in necrosis diagnosis, 151-158
Grashey position, *re* shoulder, 42
interpretation, 74, 75, 106-111, 114-115, 160, 161-166
in animal experimentation, 120 *ff*.
manifestations
lacking, in osteonecrosis, 14 (Fig. 6), 97, 115
time lapse, after insult, 56, 114-115, 146-148, 217, 244
preemployment. *See* Physical examinations
routine and serial, 154, 155, 157-158
in commercial-diving practice, 19
in men at risk, 160
Royal Navy practice, 160
in suspected osteonecrosis, 74, 196, 201
and scanning techniques, compared, 173-176, 190, 192, 245

Roentgenography, Roentgenographic (*continued*)
sites, clinically important, 3
surveys. *See* Surveys
techniques, 9, 42
standardized, 74, 154, 245
tomography, 12 (Fig.), 14, 19, 147, 155, 164 (Fig.), 183-185, 195, 201
and xeroradiography, compared, 179-181, 191, 245

Royal Navy
divers, protection of, 209
osteonecrosis surveys of, 7-8, 155-158

Scanning, radionuclide. *See* Isotopes; Roentgenography

Shoulder, Shoulder joint
lesions in, 7, 13 (Fig.), 43, 44, 46 (Fig.), 151 (Fig. 1), 173, 175 (Fig.), 180 (Fig. 5)
detection of, 42, 152
radiologic techniques *re*, 154. *See also* Management and treatment
surgical repair of, 205, 210
See also Bone; Humerus; Lesions

Sickle-cell abnormalities, 29, 233
incidence in population, 97, 98
relative to osteonecrosis, 91, 95-98, 102

Squalus, Submarine, 37

"Staggers," 33

Steroid therapy
corticosteroids, 94-95, 96 (Fig. 4, 5), 147
in necrosis etiology, 88, 90, 102

Strontium, radioactive, bone scans, 171 *ff*.

Submarine escape, 140, 147, 243

Supersaturation. *See* Gas

Surveys, osteonecrosis
BART, preliminary results, 31, 39-40
compressed-air workers, 3-5, 33
divers
Ariake Bay, 105
civilian, general, 19-20, 158
Gulf of Mexico, 9-14, 19, 171 *ff*.
results of, compared, 7, 10
Royal Navy, 7-8, 155-158
U. S. Navy, 8
German experience, 19, 20
Polish experience, 20
U.S. Air Force, 17-18
See also Roentgenography

Tables, decompression, 47 *ff*., 243-244
Blackpool (1966; 1968), 4, 5, 49, 102
British (1951), 49, 50-51
calculation of, 36-37, 38-39
comparisons of, 4-5, 31-35, 44, 49, 102

Tables, decompression (*continued*)
inadequate, 44, 111, 233, 239, 241, 242, 244
modifying current, 53
MRC (U.K.), 34-35
New York, 31-34, 39, 41, 49
nonwork experimentation, 32-33
Royal Navy, 8
treatment, 18, 23, 38, 241
U.S. Department of Labor regulations, 234
U.S. Navy, 10, 12, 23, 31, 34, 38, 41, 48, 49, 231, 241, 244
Washington, D.C. (1966), 5 (Table III)
Washington State, 5, 25, 31, 34-35, 36, 39, 55, 102, 209, 233, 243-244
in Seattle tunneling experience, 23
in Wisconsin tunneling experience, 41, 44
Work in Compressed Air Special Regulations, 3, 31

Technetium, 185, 246

Tibia
fracture of, 74 (Fig. 13), 75
lesions in, 113, 153 *ff.*, 167 (Fig. 7)
incidence, 201

Tissue(s)
–blood tensions, 139 (Fig. 3)
damage, 133-134
death, 125, 148
"elastic modulus" of, 52, 126
fat embolism in, 143
half-saturation times, 34, 36, 38, 47 *ff.*
inert-gas exchange in, 36-37, 47-48, 51 *ff.*, 244
supersaturation. *See* Gas
See also Decompression, theory

Treatment
in dysbarism. *See* Oxygen; Recompression
in osteonecrosis. *See* Management and treatment

Tunnel construction
BART, 25-40, 56, 223
Blackpool, 3
Clyde, 3, 215-216
contamination problem in, 55-56
Dartford, 3
Dungeness, 4
Lincoln Tunnel, 33-34, 223
Milwaukee, 41-42, 223
Seattle, 23, 34
Tyne, 4, 35, 215-216
See also Compressed-air workers

Tunnelers. *See* Compressed-air workers

Ultrasonics, in bubble detection, 35, 51, 53, 56-57, 128, 143, 241, 244, 246

Vascular supply to bone. *See* Bone, vascular supply of; specific bones

Viscometer, 133, 145

Weight-bearing, in osteonecrosis
avoidance of, 196, 197, 201, 202
following surgical repair, 199

Wolff's law, 73, 76

Work shifts
single, 31, 48, 49, 102
split, 31, 33, 39, 41, 43, 48, 49, 105
tabulation of
MRC and Washington State, 34 (Table IV)
Seattle tunnel, 23

Workmen's compensation, 31, 33, 209, 223-224, 229-230, 231, 247
under Wisconsin statutes, 233-234, 235-236

X-ray. *See* Roentgenography

Xeroradiography. *See* Diagnosis; Roentgenography

☆U.S. GOVERNMENT PRINTING OFFICE: 1975-657-603/5544

HEW Publication (NIOSH) 75-153

U.S. DEPARTMENT OF HEALTH, EDUCATION, AND WELFARE
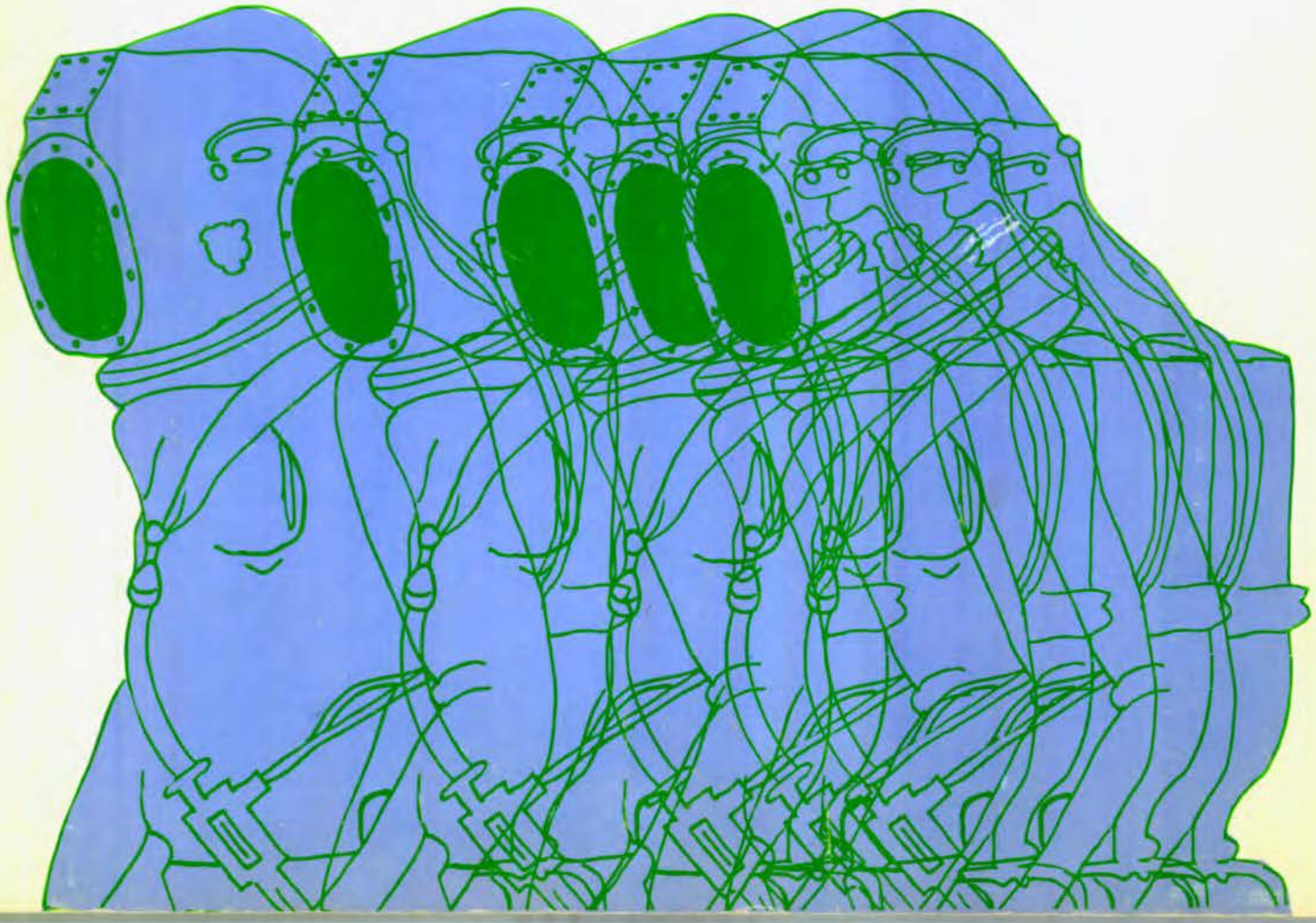
Public Health Service
Center for Disease Control
National Institute for Occupational
Safety and Health