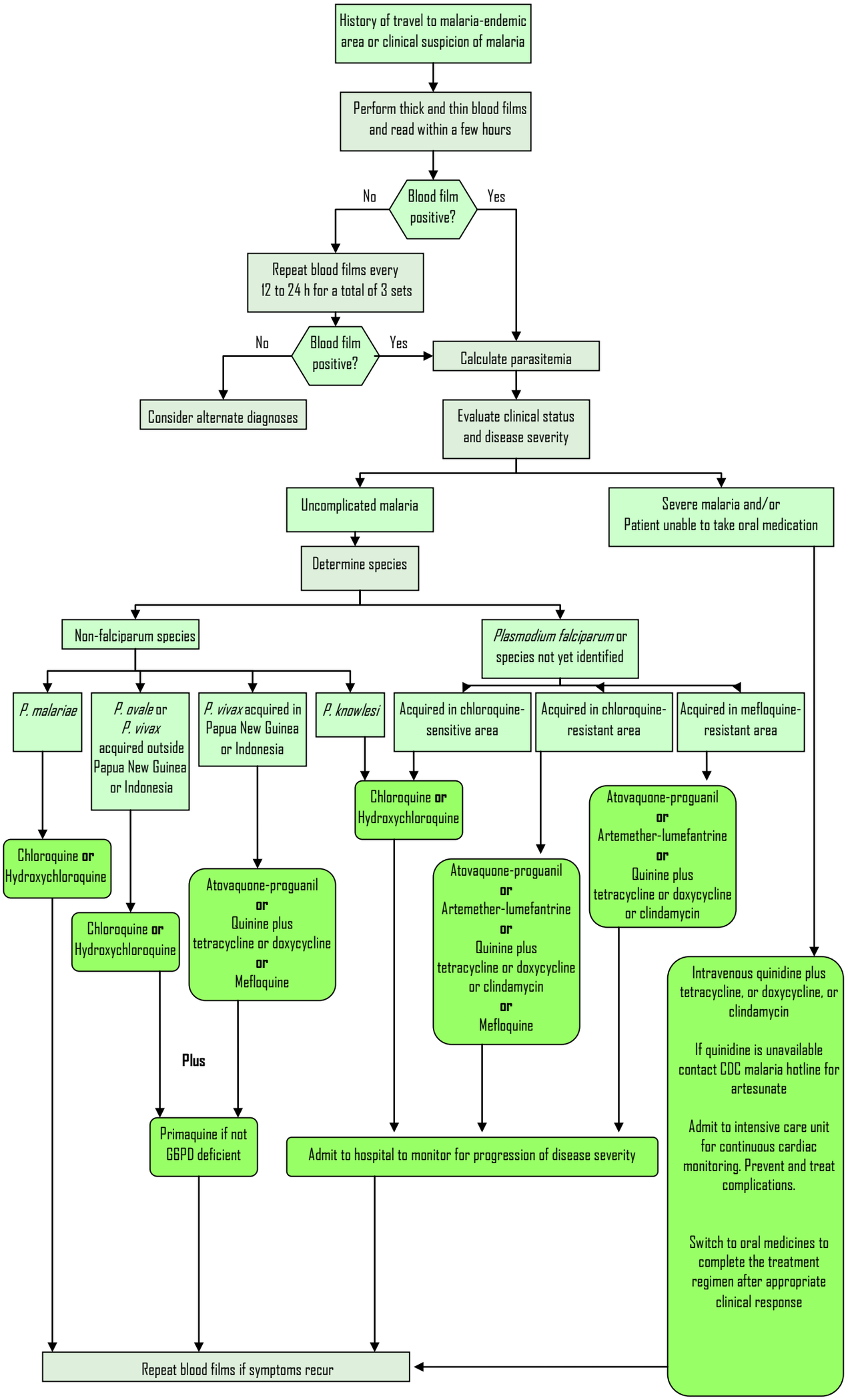
History of travel to malaria-endemic area or clinical suspicion of malaria
Perform thick and thin blood films and read within a few hours
Blood film positive?
No
Yes
Repeat blood films every 12 to 24 h for a total of 3 sets
Blood film positive?
No
Yes
Consider alternate diagnoses
Calculate parasitemia
Evaluate clinical status and disease severity
Uncomplicated malaria
Severe malaria and/or Patient unable to take oral medication
Determine species
Non-falciparum species
Plasmodium falciparum or species not yet identified
P. malariae
P. ovale or P. vivax acquired outside Papua New Guinea or Indonesia
P. vivax acquired in Papua New Guinea or Indonesia
P. knowlesi
Acquired in chloroquine-sensitive area
Acquired in chloroquine-resistant area
Acquired in mefloquine-resistant area
Chloroquine or Hydroxychloroquine
Chloroquine or Hydroxychloroquine
Atovaquone-proguanil or Quinine plus tetracycline or doxycycline or Mefloquine
Chloroquine or Hydroxychloroquine
Atovaquone-proguanil or Artemether-lumefantrine or Quinine plus tetracycline or doxycycline or clindamycin or Mefloquine
Atovaquone-proguanil or Artemether-lumefantrine or Quinine plus tetracycline or doxycycline or clindamycin
Intravenous quinidine plus tetracycline, or doxycycline, or clindamycin
If quinidine is unavailable contact CDC malaria hotline for artesunate
Admit to intensive care unit for continuous cardiac monitoring. Prevent and treat complications.
Switch to oral medicines to complete the treatment regimen after appropriate clinical response
Plus
Primaquine if not G6PD deficient
Admit to hospital to monitor for progression of disease severity
Repeat blood films if symptoms recur