

Three Cases of Tickborne *Francisella tularensis* Infection, Austria, 2022

Florian Heger, Stefanie Schindler, Sonja Pleininger, Astrid Fueszl, Marion Blaschitz, Kathrin Lippert, Patrick Hyden, Peter Hufnagl, David Mutschlechner, Thomas Gremmel, Erwin Hofer, Mateusz Markowicz,¹ Alexander Indra¹

Tularemia is increasing in Austria. We report *Francisella tularensis* subspecies *holarctica* isolated from 3 patients who had been bitten by arthropods. Next-generation sequencing showed substantial isolate similarity. Clinicians should consider bloodstream *F. tularensis* infections for patients with signs/symptoms of ulceroglandular tularemia, and surveillance of potential vectors should be intensified.

Tularemia is a zoonotic disease of the Northern Hemisphere, caused by the highly virulent bacterium *Francisella tularensis*. Although *F. tularensis* subspecies *tularensis* (type A, found only in North America) is associated with severe infections, *F. tularensis* subsp. *holarctica* (type B, found throughout the Northern Hemisphere) causes less severe illness (1,2). Infection occurs after contact with infected animals, transmission via arthropod vectors, or contact with contaminated water or soil (3). Only sporadic infections, detected primarily by serologic testing, have been reported in Austria; therefore, genomic data are scarce (3,4). Recently, cases of tularemia have increased in Austria (Figure 1). We report 3 tularemia cases that developed after arthropod bites in Austria. Ethics approval was not necessary because routine data were processed in the study and personal data were anonymized. The patients gave written consent for publication of the case reports.

Author affiliation: Austrian Agency for Health and Food Safety, Vienna, Austria (F. Heger, S. Schindler, S. Pleininger, A. Fueszl, M. Blaschitz, K. Lippert, P. Hyden, P. Hufnagl, E. Hofer, M. Markowicz, A. Indra); Cardiology and Intensive Care Medicine, Mistelbach, Austria (D. Mutschlechner, T. Gremmel); Institute of Cardiovascular Pharmacotherapy and Interventional Cardiology, St. Pölten, Austria (T. Gremmel); Paracelsus Medical University of Salzburg, Salzburg, Austria (A. Indra)

The Cases

Patient 1 was a 64-year-old woman who had received a tick bite in the right inframammary region. After experiencing fever, chills, and a general feeling of discomfort, along with nausea and vomiting, she sought emergency care when symptoms persisted. Clinical examination detected a 20-mm skin lesion surrounded by a reddish hem and central necrotic ulcer. Results of serologic testing for Lyme borreliosis were negative. Stab incision of the skin lesion was performed, and no bacteria grew in culture of the sampled pus. Blood cultures grew *F. tularensis*. Antimicrobial treatment with oral ciprofloxacin (500 mg 2×/d) led to sign/symptom resolution.

Patient 2 was a 5-year-old girl seen at a pediatric outpatient clinic for retroauricular pain after a tick bite 9 days earlier. Clinical examination showed a swollen and reddened pinna, a pus-covered 5-mm retroauricular skin lesion with a central ulcer (Appendix Figure, <https://wwwnc.cdc.gov/EID/article/29/11/23-0460-App1.pdf>), and swollen cervical lymph nodes. After 2 days, fever, increased lymph node swelling, and tonsillitis developed, and the retroauricular wound deteriorated. Therapy was switched from oral amoxicillin/clavulanic acid (250 mg 4×/d) and fucidin ointment to intravenous ceftriaxone (520 mg 1×/d), followed by oral cefixim (64 mg 2×/d), which alleviated signs and symptoms. A wound swab sample culture yielded *F. tularensis*. Antimicrobial treatment, changed to oral ciprofloxacin (250 mg 2×/d), led to substantial signs/symptom improvement.

Patient 3 was a 76-year-old man who was hospitalized after reporting fever, generalized discomfort, nausea, and vertigo. A red, painless skin lesion with central

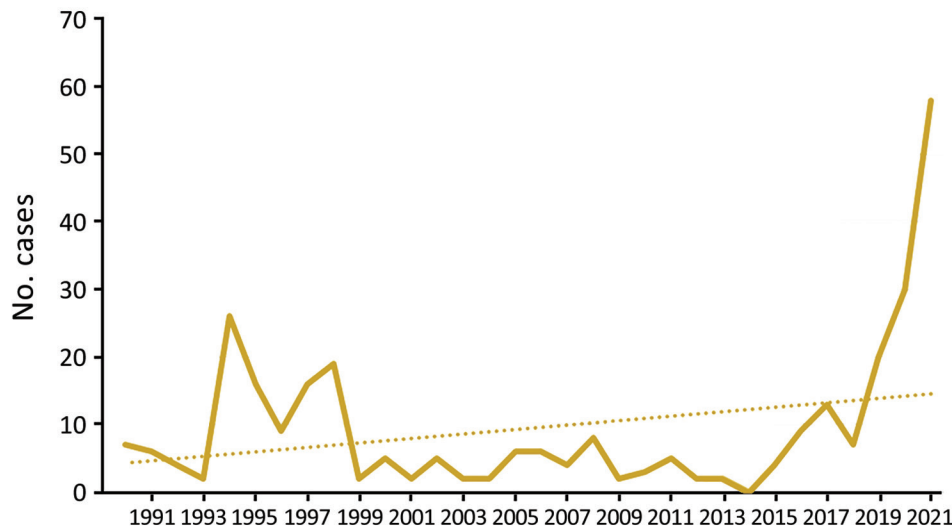


Figure 1. Reported cases (solid line) and trends (dotted line) of tularaemia in Austria, 1990–2021. Data from the Austrian Epidemiologic Reporting System (<https://oecd-opsi.org>).

crust on the left thigh, which probably developed after an arthropod bite, and inguinal lymphadenopathy were noted. Antimicrobial treatment with ampicillin/sulbactam was started because of suspected pneumonia. Eight days after hospitalization, *F. tularensis* grew on anaerobic blood culture. Therapy with ciprofloxacin was initiated and later switched to oral doxycycline (100 mg 2×/d) because of potential allergic reaction to ciprofloxacin, followed by substantial sign/symptom improvement. The findings suggest local transmission of *F. tularensis* after an insect or tick bite.

We used multiplex PCR (Analyticon Instruments GmbH, <https://www.analyticon.eu/de>) to test samples, and all were positive for *F. tularensis*. Real-time PCR (TIB MolBiol, <https://www.tib-molbiol.de>), performed for subspecies determination according to manufacturer instructions, yielded *F. tularensis* subsp. *holarctica* (5). We determined MICs for 6 antimicrobials by Etest (bioMérieux, <https://www.biomerieux.fr>) and interpreted results according to Clinical and Laboratory Standards Institute guidelines (6) (Table). Because of high-level erythromycin resistance, we assigned the isolates to *F. tularensis* subsp. *holarctica* biovar II (genotype B.12), which was later confirmed by whole-genome sequencing (WGS) to be subclade B.34/B.35.

For all *F. tularensis* samples, we performed WGS on a NextSeq 2000 instrument (Illumina, Inc., www.illumina.com), 150-bp paired-end, by using a QIAGEN MagAttract HMW DNA Kit (<https://www.qiagen.com>) for DNA isolation and a Nextera XT DNA Library Prep Kit (Illumina, Inc.) for library preparation.

We assembled whole-genome sequences de novo by using SPAdes (7) version 3.15.2, analyzed them by using JSpecies webserver (8), and corroborated real-time PCR species results by using the TCS (Templeton, Crandall and Sing) calculation method. In a pairwise comparison, the 3 isolates differed in 5 genes: 410015–22 vs. 410016–22 (FTL_0160, FTL_0920, FTL_1212, and FTL_1567); 410015–22 vs. 410041–22 (FTL_0414 and FTL_0920), and 410016–22 vs. 410041–22 (FTL_0160, FTL_0414, FTL_1212, and FTL_1567). Average allelic distance is 3.3 alleles, which is above cluster threshold for this species (1 allele difference). We applied core-genome multilocus sequence typing analysis by using Seqshpere+ version 8.5.1 (Ridom GmbH, <https://www.ridom.de>) with the published core-genome multilocus sequence typing scheme (9) to compare our isolate genomes against genomes from Germany (Bavaria) and Austria from a previous study (PRJEB40963 [10]). We identified clades/subclades by using CanSNPer2 (11). We submitted the following *F. tularensis* subsp. *holarctica* WGS assemblies to the National Center for Biotechnology Information (BioProject PRJNA900077): biosample SAMN31677967 (410015–22, patient 1), accession no. JAPKFK000000000; biosample SAMN31677968 (410016–22, patient 2), accession no. JAPKFJ000000000; and biosample SAMN32382778 (410041–22, patient 3), accession no. JAPZIK000000000 (Figure 2, Appendix).

Table. Antimicrobial MICs for *Francisella tularensis* isolates recovered from 3 patients with tickborne tularemia, Austria*

Patient	MIC, mg/L					
	Gentamicin	Erythromycin	Ciprofloxacin	Tetracycline	Doxycycline	Streptomycin
1	0.25	>256	0.008	0.047	0.094	1.5
2	0.5	>256	0.012	0.032	0.19	3
3	0.19	>256	0.008	0.125	0.125	0.75

*Boldface indicates antimicrobial resistance according to Clinical and Laboratory Standards Institute standards (6).

Conclusions

Outbreaks of *F. tularensis* subsp. *holarctica* in Europe are linked mainly to infected rodents and hares; mosquitoes and ticks serve as arthropod vectors (3). Over the past 30 years (1990–2021), a total of 302 human infections have been reported in Austria, with 2 peaks after outbreaks in hares during 1994–1995 and 1997–1998 (12–14). So far, national reported cases show an upward trend; in 2021 alone, a total of 58 cases were reported (Figure 1).

Biovar I (genotype B.6) is found mainly in western Europe and biovar II (genotype B.12) in northern and eastern Europe (11). Most tularemia cases in Austria are associated with hunting hares and skinning carcasses and are caused by *F. tularensis* subsp. *holarctica* biovar II. Recently, ticks have been identified as

vectors, and *F. tularensis* subsp. *holarctica* biovar I was detected in Austria in 2016 (1,15). Under debate is whether pathogenic potential of biovar I may be higher than that of biovar II (15).

Of the 3 patients, 2 reported removing a tick after spending time in rural areas; the third did not observe a tick or insect bite but had local skin alterations that were highly comparable to those seen on other patients with tickborne tularemia. Isolate sequences were closely related to isolates from Austrian and German hares (10).

Bloodstream infections with *F. tularensis* after arthropod bites are rarely reported in Europe. One reason might be that in Europe only *F. tularensis* subsp. *holarctica* is found, and it is known to cause milder disease than *F. tularensis* subsp. *tularensis* in the United

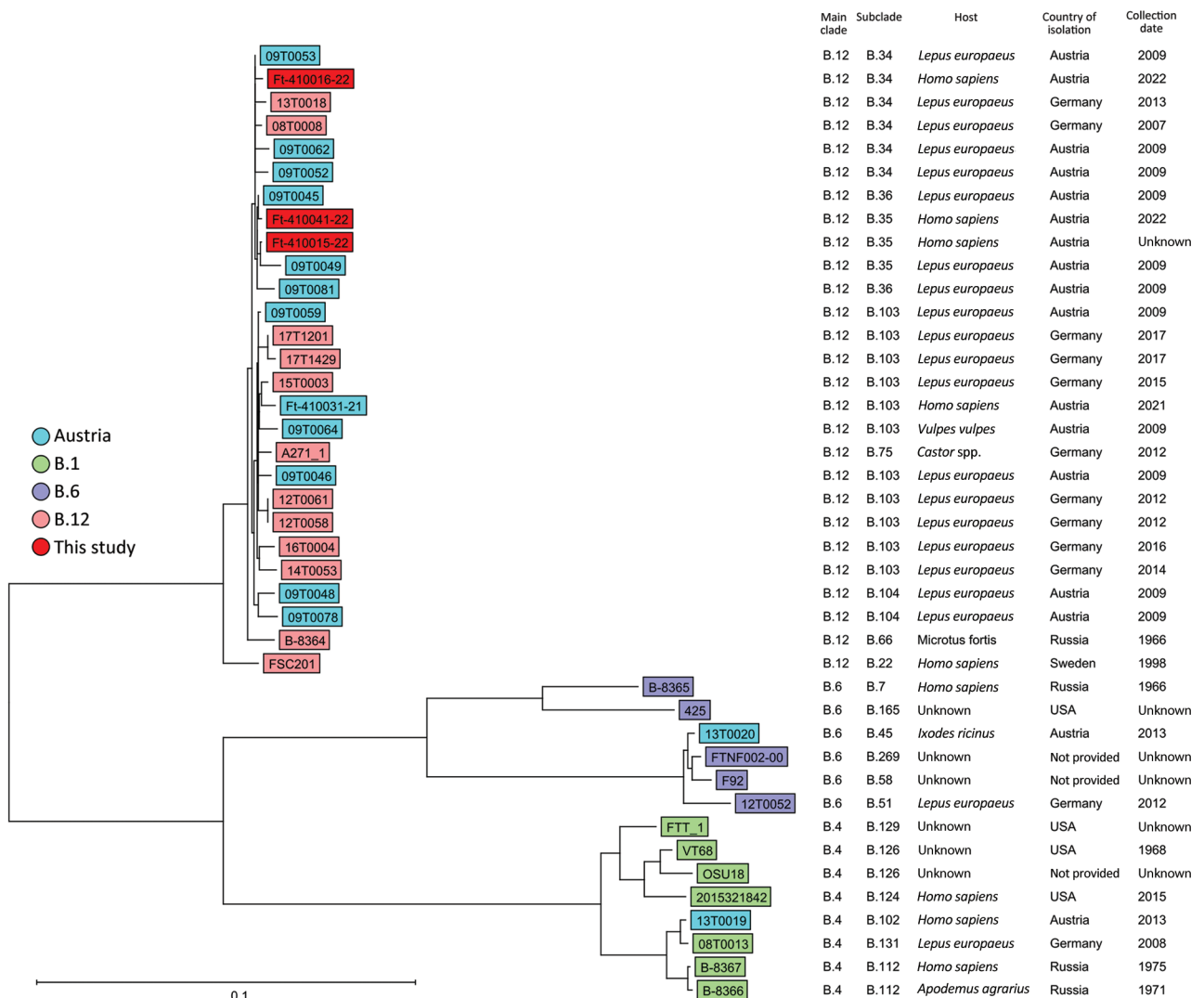


Figure 2. Ridom SeqSphere+ NJ tree (Ridom GmbH, <https://www.ridom.de>) for 41 *Francisella tularensis* samples isolated from 3 patients in Austria, based on 1,147 columns from *F. tularensis* core-genome multilocus sequence typing. Scale bar indicates nucleotide substitutions per site. Metadata are provided in the Appendix Table (<https://wwwnc.cdc.gov/EID/article/29/11/23-0460-App1.pdf>).

States. Thus, we find it remarkable that bacteremia developed in 2 patients in Austria. WGS showed a close relationship between isolates from the patients and isolates found mostly in Germany and Austria, as shown in the neighbor-joining tree for 41 *F. tularensis* complete genomes (Figure 2; Appendix Table), which indicates the wild animal population as a host for *F. tularensis* subsp. *holarctica* biovar II (B.12) and ticks as vectors for tularemia in Austria.

Our findings show that ticks represent underestimated vectors for *F. tularensis* transmission in Austria. Aside from other tickborne diseases endemic to Austria, clinicians should consider tularemia as a cause of signs/symptoms that follow tick bites, especially when combined with fever, enlarged and painful lymph nodes, and skin ulcers. Diagnosis can be achieved by molecular testing. Genomic data are essential for understanding dissemination and invasion of certain genotypes that may cause systemic infections. To confidently declare that certain genetic subpopulations are associated with systemic infections, a larger number of isolates and further research are needed. For that reason, Austria established large-scale monitoring of arthropod vectors for the presence of vectorborne pathogens, including *F. tularensis*, to provide public health authorities with knowledge about infection risk for the exposed population.

Acknowledgments

We thank all persons involved in laboratory work at the Austrian Agency of Health and Food Safety and treating clinicians Gian Farid Monfared, Anna Thell for their cooperation and sharing of the patients' clinical data.

M.M. is an unpaid member of the Executive Committee of ESGBOR, the ESCMID Study Group for Lyme Borreliosis and received honoraria from Pfizer and DiaSorin for obligations unrelated to this study.

F.H. and S.S. undertook the microbiological testing. S.S., M.M., D.M., and T.G. collected the data. M.B., K.L., and P.H. performed molecular testing and analyzed the data. S.P. and A.I. provided laboratory services and supervised the study. F.H. and M.M. wrote the manuscript. All authors reviewed and approved the final version of the manuscript.

About the Author

Mr. Heger is head of the department of Medical Microbiology and Hygiene at the Austrian Agency for Health and Food Safety. His main fields of work are highly pathogenic bacteria, antibiotic resistance, and infectious diseases.

References

- Seiwald S, Simeon A, Hofer E, Weiss G, Bellmann-Weiler R. Tularemia goes west: epidemiology of an emerging infection in Austria. *Microorganisms*. 2020;8:1597. <https://doi.org/10.3390/microorganisms8101597>
- Farlow J, Wagner DM, Dukerich M, Stanley M, Chu M, Kubota K, et al. *Francisella tularensis* in the United States. *Emerg Infect Dis*. 2005;11:1835–41. <https://doi.org/10.3201/eid1112.050728>
- Hestvik G, Warns-Petit E, Smith LA, Fox NJ, Uhlhorn H, Artois M, et al. The status of tularemia in Europe in a one-health context: a review. *Epidemiol Infect*. 2015; 143:2137–60. <https://doi.org/10.1017/S0950268814002398>
- Markowicz M, Schötta AM, Penatzer F, Matscheko C, Stanek G, Stockinger H, et al. Isolation of *Francisella tularensis* from skin ulcer after a tick bite, Austria, 2020. *Microorganisms*. 2021; 9:1407. <https://doi.org/10.3390/microorganisms9071407>
- Kugeler KJ, Pappert R, Zhou Y, Petersen JM. Real-time PCR for *Francisella tularensis* types A and B. *Emerg Infect Dis*. 2006;12:1799–801. <https://doi.org/10.3201/eid1211.060629>
- Clinical and Laboratory Standards Institute. Methods for antimicrobial dilution and disk susceptibility testing of infrequently isolated or fastidious bacteria (M45). 3rd ed. Wayne (PA): The Institute; 2015.
- Bankevich A, Nurk S, Antipov D, Gurevich AA, Dvorkin M, Kulikov AS, et al. SPAdes: a new genome assembly algorithm and its applications to single-cell sequencing. *J Comput Biol*. 2012;19:455–77. <https://doi.org/10.1089/cmb.2012.0021>
- Richter M, Rosselló-Móra R, Glöckner FO, Peplies J. JSpeciesWS: a web server for prokaryotic species circumscription based on pairwise genome comparison. *Bioinformatics*. 2016;32:929–31.
- Antwerpen MH, Prior K, Mellmann A, Höppner S, Spletstoeser WD, Harmsen D. Rapid high resolution genotyping of *Francisella tularensis* by whole genome sequence comparison of annotated genes ("MLST+"). *PLoS One*. 2015; 10:e0123298. <https://doi.org/10.1371/journal.pone.0123298>
- Linde J, Homeier-Bachmann T, Dangel A, Riehm JM, Sundell D, Öhrman C, et al. Genotyping of *Francisella tularensis* subsp. *holarctica* from hares in Germany. *Microorganisms*. 2020;8:1932. <https://doi.org/10.3390/microorganisms8121932>
- Lärkeryd A, Myrtenäs K, Karlsson E, Dwibedi CK, Forsman M, Larsson P, et al. CanSNPer: a hierarchical genotype classifier of clonal pathogens. *Bioinformatics*. 2014; 30:1762–4. <https://doi.org/10.1093/bioinformatics/btu113>
- Federal Ministry of Health. Leaflet on tularemia [in German]. https://www.verbrauchergesundheits.at/tiere/zoonosen/BMG-74600_0201_2012_17_Merkblatt_Tularaemie_Aug2012.pdf
- Federal Ministry for Social Affairs. Epidemiology of communicable diseases in Austria [in German]. <https://www.sozialministerium.at/Themen/Gesundheit/Uebertragbare-Krankheiten/Statistiken-und-Fallzahlen.html>
- Tomaso H, Al Dahouk S, Hofer E, Spletstoeser WD, Treu TM, Dierich MP, et al. Antimicrobial susceptibilities of Austrian *Francisella tularensis holarctica* biovar II strains. *Int J Antimicrob Agents*. 2005;26:279–84. <https://doi.org/10.1016/j.ijantimicag.2005.07.003>
- Faber M, Heuner K, Jacob D, Grunow R. Tularemia in Germany—a re-emerging zoonosis. *Front Cell Infect Microbiol*. 2018;8:40. <https://doi.org/10.3389/fcimb.2018.00040>

Address for correspondence: Florian Heger, Austrian Agency for Health and Food Safety, Medical Microbiology and Hygiene, Waehringer Strasse 25A, Wien, Vienna 1100, Austria; email: florian.heger@ages.at

EID cannot ensure accessibility for supplementary materials supplied by authors. Readers who have difficulty accessing supplementary content should contact the authors for assistance.

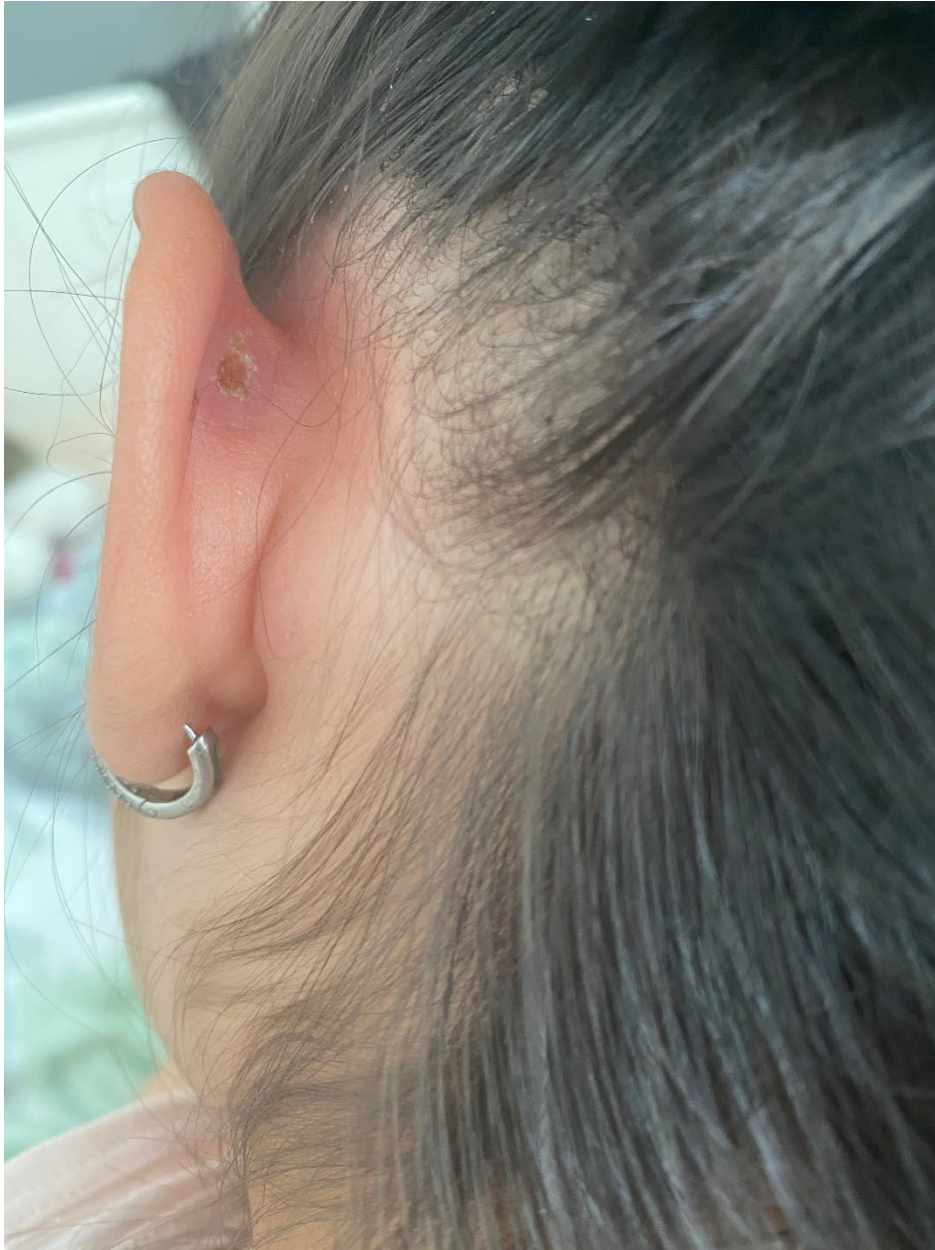Three Cases of Tickborne Tularemia, Austria, 2022

Appendix

Appendix Table. Overview of metadata of 41 *F. tularensis* subsp. *holarctica* complete genomes imported from NCBI to Ridom SeqSphere+.

Strain	Source Type	Host	Isolation Source	Country of Isolation	Collection Date	Main Clade	Sub-Clade	PubMed ID(s)	Nucleotide Accession(s)	Perc. Good Targets	Contig Count (Assembled)	Approximated Genome Size (Mbases)	Avg. Coverage (Assembled)
FSC201	clinical/host-associated	Homo sapiens		Sweden	1998	B.12	B.22		NZ_CP089549.1	99.9	1	1.9	1
2015321842	clinical/host-associated	Homo sapiens	pleural	USA	2015	B.4	B.124		NZ_CP073125.1	95.8	1	1.9	200
08T0013	clinical/host-associated	Lepus europaeus		Germany	2008	B.4	B.131		NZ_CP058301.1	98.7	1	1.9	150
12T0052	clinical/host-associated	Lepus europaeus		Germany	2012	B.6	B.51		NZ_CP058275.1	97.6	1	1.9	150
A271_1	clinical/host-associated	Castor sp.		Germany	2012	B.12	B.75	27356883	NZ_CP048229.1	99.8	1	1.9	100
B-8364	clinical/host-associated	Microtus fortis		Russia	1966	B.12	B.66		NZ_CP0444005.1	99.7	1	1.9	196
B-8365	clinical/host-associated	Homo sapiens		Russia	1966	B.6	B.7		NZ_CP0444004.1	98.5	1	1.9	205
B-8366	clinical/host-associated	Apodemus agrarius		Russia	1971	B.4	B.112		NZ_CP0444003.1	98.8	1	1.9	248
B-8367	clinical/host-associated	Homo sapiens		Russia	1975	B.4	B.112		NZ_CP0444002.1	98.8	1	1.9	212
425			Water	USA		B.6	B.165	25931589	NZ_CP010289.1	98.3	1	1.9	
VT68			Muskrat spleen	USA	1968	B.4	B.126	25931589	NZ_CP010288.1	98.6	1	1.9	
FTT_1				USA		B.4	B.129	25931589	NZ_CP009693.1	98.7	1	1.9	767
F92						B.6	B.58	23405342	NC_019537.1	95.1	1	1.9	
OSU18						B.4	B.126	18927608	NC_017463.1	98.1	1	1.9	
FTNF002-00						B.6	B.269	19756146	NC_009749.1	98.7	1	1.9	
08T0008	clinical/host-associated	Lepus europaeus		Germany	2013	B.12	B.34	32991594	GCA_010378045.1	99.4	103	1.8	
09T0045	clinical/host-associated	Lepus europaeus		Austria	2013	B.12	B.36		GCA_010377935.1	99.6	97	1.8	
09T0048	clinical/host-associated	Lepus europaeus		Austria	2009	B.12	B.104		GCA_010377875.1	99.7	98	1.8	

Strain	Source Type	Host	Isolation Source	Country of Isolation	Collection Date	Main Clade	Sub-Clade	PubMed ID(s)	Nucleotide Accession(s)	Perc. Good Targets	Contig Count (Assembled)	Approximated Genome Size (Mbases)	Avg. Coverage (Assembled)
09T0049	clinical/host-associated	Lepus europaeus		Austria	2009	B.12	B.35		GCA_010377865.1	99.5	98	1.8	
09T0046	clinical/host-associated	Lepus europaeus		Austria	2009	B.12	B.103		GCA_010377845.1	99.4	99	1.8	
09T0052	clinical/host-associated	Lepus europaeus		Austria	2009	B.12	B.34		GCA_010377815.1	99.6	98	1.8	
09T0053	clinical/host-associated	Lepus europaeus		Austria	2009	B.12	B.34		GCA_010377805.1	99.6	98	1.8	
09T0062	clinical/host-associated	Lepus europaeus		Austria	2009	B.12	B.34		GCA_010377765.1	99.0	110	1.8	
09T0064	clinical/host-associated	Vulpes vulpes		Austria	2009	B.12	B.103		GCA_010377745.1	99.6	98	1.8	
09T0059	clinical/host-associated	Lepus europaeus		Austria	2009	B.12	B.103		GCA_010377725.1	99.6	99	1.8	
09T0078	clinical/host-associated	Lepus europaeus		Austria	2009	B.12	B.104		GCA_010377675.1	99.6	99	1.8	
09T0081	clinical/host-associated	Lepus europaeus		Austria	2009	B.12	B.36		GCA_010377605.1	99.6	97	1.8	
12T0058	clinical/host-associated	Lepus europaeus		Germany	2009	B.12	B.103	32991594	GCA_010376485.1	99.7	100	1.8	
12T0061	clinical/host-associated	Lepus europaeus		Germany		B.12	B.103	32991594	GCA_010376435.1	99.7	99	1.8	
13T0018	clinical/host-associated	Lepus europaeus		Germany	2022	B.12	B.34	32991594	GCA_010376365.1	98.1	113	1.8	
13T0019	clinical/host-associated	Homo sapiens		Austria	2022	B.4	B.102		GCA_010376335.1	98.4	99	1.8	
13T0020	clinical/host-associated	Ixodes ricinus		Austria	2017	B.6	B.45		GCA_010376315.1	96.3	153	1.8	
14T0053	clinical/host-associated	Lepus europaeus		Germany	2017	B.12	B.103	32991594	GCA_010375985.1	95.9	148	1.8	
15T0003	clinical/host-associated	Lepus europaeus		Germany	2016	B.12	B.103	32991594	GCA_010375455.1	99.6	100	1.8	
16T0004	clinical/host-associated	Lepus europaeus		Germany	2015	B.12	B.103	32991594	GCA_010375285.1	98.5	97	1.8	
17T1201	clinical/host-associated	Lepus europaeus		Germany	2014	B.12	B.103	32991594	GCA_010375095.1	99.7	98	1.8	
17T1429	clinical/host-associated	Lepus europaeus		Germany	2013	B.12	B.103	32991594	GCA_010375055.1	98.2	123	1.8	
Ft-410015-22	clinical/host-associated	Homo sapiens		Austria	2022	B.12	B.35		Submitted	96.0	230	1.8	
Ft-410016-22	clinical/host-associated	Homo sapiens		Austria	2022	B.12	B.34		Submitted	97.6	220	1.8	
Ft-410041-22	clinical/host-associated	Homo sapiens		Austria	2022	B.12	B.35		Submitted	97.6	176	1.8	
Ft-410031-21	clinical/host-associated	Homo sapiens		Austria	2021	B.12	B.103			94.0	228	1.8	



Appendix Figure. Swollen and reddened pinna, with pus-covered 5-mm retroauricular skin lesion with a central ulcer in 5-year-old girl with tick-borne tularemia, Austria.