

Her current research investigates the impact of Social Determinants of Health needs and interventions on severe maternal morbidity and maternal mortality in an attempt to improve parity in maternal/neonatal health outcomes.

References

1. Emeruwa UN, Ona S, Shaman JL, Turitz A, Wright JD, Gyamfi-Bannerman C, et al. Associations between built environment, neighborhood socioeconomic status, and SARS-CoV-2 infection among pregnant women in New York City. *JAMA*. 2020;324:390–392 <https://doi.org/10.1001/jama.2020.11370>
2. United States Census Bureau. American community survey, 2012–2016. [cited 2020 May 23]. <https://www.census.gov/programs-surveys/acs/>
3. Moore JT, Ricaldi JN, Rose CE, Fuld J, Parise M, Kanget GJ et al. Disparities in incidence of COVID-19 among underrepresented racial/ethnic groups in counties identified as hotspots during June 5–18, 2020 – 22 states, February–June 2020. *MMWR Morb Mortal Wkly Rep*. <https://www.cdc.gov/mmwr/volumes/69/wr/mm6933e1.htm>
4. Georgia Department of Public Health. COVID-19 daily status report. 2020 [cited 2020 May 23]. <https://dph.georgia.gov/covid-19-daily-status-report>
5. Jamieson DJ, Haddad LB. What obstetrician-gynecologists should know about population health. *Obstet Gynecol*. 2018;131:1145–52. <https://doi.org/10.1097/AOG.0000000000002638>
6. Wilson R, Din A. Understanding and enhancing the U.S. Department of Housing and Urban Development's ZIP code crosswalk files. *Cityscape: J Policy Dev Res*. 2018;20:277–94 [cited 2020 Sep 23]. <https://www.huduser.gov/portal/periodicals/cityscape/vol20num2/ch16.pdf>
7. Ellington S, Strid P, Tong VT, Woodworth K, Galang RR, Zambrano LD, et al. Characteristics of women of reproductive age with laboratory-confirmed SARS-CoV-2 infection by pregnancy status – United States, January 22–June 7, 2020. *MMWR Morb Mortal Wkly Rep*. 2020;69:769–75. <https://doi.org/10.15585/mmwr.mm6925a1>

Address for correspondence: Naima T. Joseph, Department of Gynecology and Obstetrics, Emory University School of Medicine, 69 Jesse Hill Jr. Dr SE, 4th Fl, Glenn Building, Atlanta, GA 30303, USA; email: ntjose2@emory.edu

COMMENT LETTERS

Nocardia ignorata Infection in Heart Transplant Patient

Victoria A. Muggia, Yoram A. Puius

Author affiliations: Albert Einstein College of Medicine, Bronx, NY, USA; Montefiore Medical Center, Bronx

DOI: <https://doi.org/10.3201/eid2611.202756>

To the Editor: We read with interest the recent description of pulmonary *Nocardia ignorata* infection (1). We report a similar infection in an orthotopic heart transplant recipient, which likely began as a pulmonary infection with dissemination to soft tissue, without known exposure. Risk factors included tacrolimus, steroids, older age, and posttransplant intensive care unit admission (2).

The patient was a 66-year-old African American man with a history of ischemic cardiomyopathy. After implantation of a left ventricular assist device, infectious complications included *Enterococcus faecalis* device infection and extended spectrum β -lactamase-producing (ESBL) *Klebsiella* urosepsis. The course after left ventricular assist device explantation and orthotopic heart transplant was complicated by tamponade requiring a pericardial window and an ESBL *Klebsiella* urinary tract infection treated

with meropenem. Because of leukopenia, *Pneumocystis* prophylaxis was changed from trimethoprim/sulfamethoxazole to atovaquone 2 weeks posttransplant. ESBL *Klebsiella* bacteremia recurred 6 weeks later, again treated with meropenem.

The patient returned 6 months posttransplant with 10 days of cough and dyspnea. Chest computed tomography demonstrated bilateral nodules with cavitation, bronchiectasis, and spiculation. We initially treated the patient with meropenem and doxycycline. Results from severe acute respiratory syndrome coronavirus 2 swab test, respiratory pathogen panel, fungal studies, and sputum culture were nondiagnostic. We obtained no additional pulmonary samples.

Due to severe left calf pain, venous duplex was performed, revealing a nonvascular mass. The patient reported no trauma, soil contact, or recent travel. The abscess was aspirated, demonstrating branching gram-positive beaded rods. The isolate was identified by a reference laboratory (Mycobacteria and *Nocardia* Laboratory, University of Texas Health Center at Tyler, Tyler, TX, USA) by partial 16S rRNA sequencing as a 99.51% match with *Nocardia ignorata*, with susceptibilities identical to the isolate in Rahdar et al. (1). Brain magnetic resonance imaging results were unremarkable. The patient's respiratory status and leg pain quickly

improved and he was discharged on long-term trimethoprim/sulfamethoxazole and doxycycline. Because of renal insufficiency, trimethoprim/sulfamethoxazole was switched to moxifloxacin after 2 weeks. Chest radiograph results were improving 3 months later.

References

1. Rahdar HA, Gharabaghi MA, Bahador A, Shahraki-Zahedani S, Karami-Zarandi M, Mahmoudi S, et al. Pulmonary *Nocardia ignorata* infection in gardener, Iran,

2017. *Emerg Infect Dis.* 2020;26:610–1. <https://doi.org/10.3201/eid2603.180725>

2. Coussement J, Lebeaux D, van Delden C, Guillot H, Freund R, Marbus S, et al.; European Study Group for Nocardia in Solid Organ Transplantation. *Nocardia* infection in solid organ transplant recipients: a multicenter European case-control study. *Clin Infect Dis.* 2016;63:338–45. <https://doi.org/10.1093/cid/ciw241>

Address for correspondence: Yoram A. Puius, Division of Infectious Diseases, Montefiore Medical Center, 111 East 210th Street, Bronx, NY 10467, USA; e-mail: ypuius@montefiore.org

etymologia

Nocardia [no-kahr' e-əm]

Christoffel J. Opperman

The genus *Nocardia* is named in honor of Edmond Isidore Etienne Nocard (1850–1903), a French veterinarian and microbiologist who discovered the bacteria in 1888 from a bovine farcy case. He named this filamentous, branching bacteria *Streptothrix farcinica* (Greek *streptós-* “twisted” and *thrix* “hair”). Farcy (old French *farcin*), is a form of cutaneous glanders, characterized by superficial lymph node swelling and ulcerating nodule formation under the skin (Late Latin *farciminum* “glanders,” from Latin *farcimen* “a sausage,” from *farcire* “to stuff”).

One year later, Trevisan characterized and termed the bacteria *Nocardia farcinica*, creating the genus *Nocardia*. In 1890, Eppinger isolated a similar organism from a brain abscess and called it *Cladothrix asteroides* (Greek *kládos-* “branch” and *-thrix* “hair”) because of its star-shaped colonies (Greek *asteroieidēs* “starlike”). Blanchard renamed the organism *Nocardia asteroides* in 1896. Additional taxonomic work in 1962 resulted in *Nocardia asteroides* replacing *Nocardia farcinica* as the type species for the genus *Nocardia*.

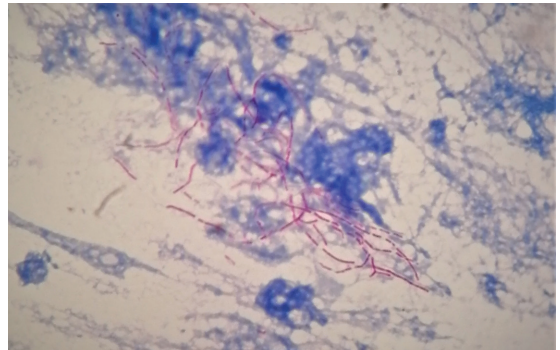


Figure. Twisted hair bacteria (*Nocardia* spp.) described by Edmond Nocard, from a bronchial alveolar lavage sample. Nocardiosis is an opportunistic infection, commonly associated with pulmonary disease. *Nocardia* are partially acid-fast, filamentous, branching bacilli (modified Kinyoun acid-fast stain using weak acid [0.5% sulfuric acid] for decolorization and methylene blue counterstain, original magnification x1,000.) Photograph courtesy of the author.

Sources

1. Blanchard R. 1896. Plant pests excluding bacteria [in French]. In: Bouchard C, editor. *Treatise of general pathology*. Volume II. Paris: Mason. p. 811–926.
2. Gordon RE, Mihm JM. The type species of the genus *Nocardia*. *J Gen Microbiol.* 1962;27:1–10. <https://doi.org/10.1099/00221287-27-1-1>
3. Nocard E. Note on the disease of oxen from Guadeloupe known as farcin [in French]. *Ann Inst Pasteur (Paris)*. 1888;2:293–302.
4. Saubolle MA, Sussland D. Nocardiosis: review of clinical and laboratory experience. *J Clin Microbiol.* 2003;41:4497–501. <https://doi.org/10.1128/JCM.41.10.4497-4501.2003>
5. Trevisan V. 1889. Genera and species of the batteries [in Italian]. Milan: Zanaboni and Gabuzzi; 1889.

Address for correspondence: Christoffel J. Opperman, National Health Laboratory Service, Department of Medical Microbiology, University of Cape Town and Groote Schuur Hospital, Cape Town, South Africa.; email: stefanopperman1@gmail.com

Author affiliation: Groote Schuur Hospital, Cape Town, South Africa

DOI: <https://doi.org/10.3201/eid2611.ET2611>