

Europe. Emerg Infect Dis. 2014;20:1544–7. <http://dx.doi.org/10.3201/eid2009.140554>

Address for correspondence: Alexander Malogolovkin, Federal Research Center for Virology and Microbiology, 601125, Vladimirskaia Oblast', Pokrov, Russia; email: malogolovkin@inbox.ru

## Classical Swine Fever Outbreak after Modified Live LOM Strain Vaccination in Naive Pigs, South Korea

Sang H. Je,<sup>1</sup> Taeyong Kwon,<sup>1</sup> Sung J. Yoo, Dong-Uk Lee, SeungYoon Lee, Juergen A. Richt, Young S. Lyoo

Author affiliations: Konkuk University, Seoul, South Korea (S.H. Je, T. Kwon, S.J. Yoo, D.-U. Lee, Y.S. Lyoo); HanByol Farm Tech, Namyangju, South Korea (S. Lee); Kansas State University, Manhattan, Kansas, USA (J.A. Richt)

DOI: <https://doi.org/10.3201/eid2404.171319>

We report classical swine fever outbreaks occurring in naive pig herds on Jeju Island, South Korea, after the introduction of the LOM vaccine strain. Two isolates from sick pigs had >99% identity with the vaccine strain. LOM strain does not appear safe; its use in the vaccine should be reconsidered.

Classical swine fever is a highly contagious disease of pigs that tremendously affects the swine industry. Although several countries have become free from classical swine fever after eradication programs, sporadic outbreaks continue to occur in most major pig-producing countries, and classical swine fever is endemic to some countries in Asia. Vaccination is regarded as one of the most effective tools to prevent and control classical swine fever. Modified live vaccines (MLVs) mainly containing C-strain have been used widely because of their safety and provide complete protection against virus challenge (1,2).

Since 1974, the LOM strain has been the MLV strain for classical swine fever in South Korea. As a result of the government's classical swine fever eradication program, Jeju Island, South Korea, became a classical swine fever virus (CSFV)-free area, and vaccination efforts ceased there in 1999 (3). Strong prohibition of live pig trade has

also contributed to the maintenance of CSFV-naive herds on Jeju Island for over a decade, although sporadic classical swine fever outbreaks have occurred in mainland South Korea, despite mandatory vaccination with the LOM strain (4). This study describes classical swine fever outbreaks in naive pig herds on Jeju Island caused by the MLV.

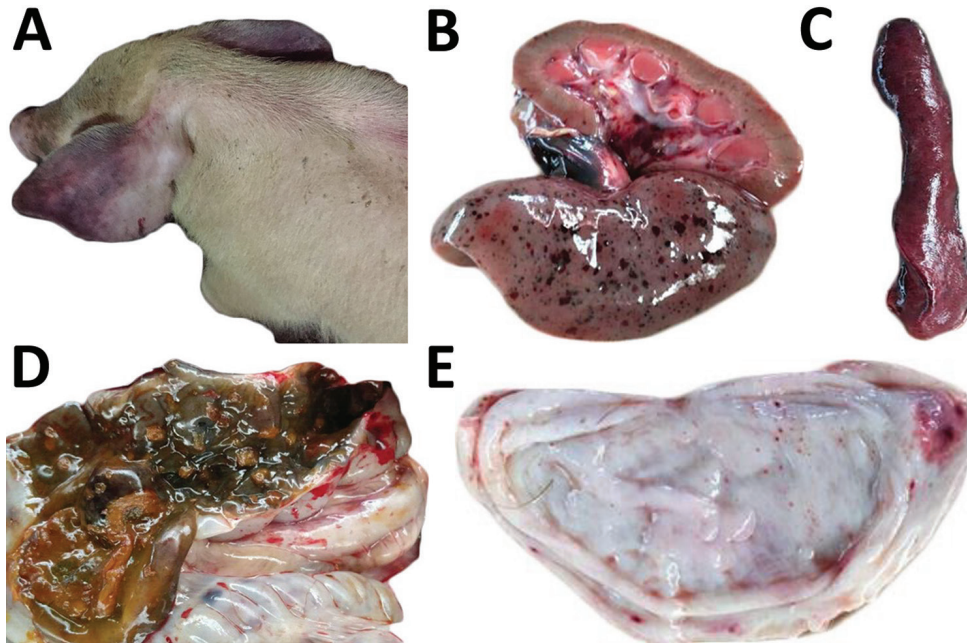
Since 2014, multiple classical swine fever outbreaks have occurred on Jeju Island (online Technical Appendix Figure 1, <https://wwwnc.cdc.gov/EID/article/24/4/17-1319-Techapp1.pdf>). Clinical manifestation is characterized by reproductive problems (including stillbirth and fetus mummification), lethargy, cutaneous hyperemia, and cyanosis of the ear in young pigs. Pathologic examination showed typical classical swine fever lesions (Figure). Clinical samples from 2 nonvaccinated herds in 2016 were submitted for laboratory analysis.

PCR showed that these samples were positive for CSFV. Other viral pathogens involved in abortions (e.g., porcine reproductive and respiratory syndrome virus, Aujeszky disease virus, porcine parvovirus, Japanese encephalitis virus, and encephalomyocarditis virus) were not detected in any samples; however, lymph node, tonsil, lung, and brain fetal specimens and placenta specimens from farm A and lung specimens from farm B were weakly positive for porcine circovirus type 2, which is ubiquitous in South Korea (5). At farm B, serum samples from 20% of suckling piglets and 30% of weaned pigs were positive for CSFV. Although blood samples from growing and finishing pigs were not positive for CSFV, fecal samples were positive, indicating possible horizontal transmission in the field.

LOM isolates JJ-1601 (identified in a placenta sample from farm A) and JJ-1602 (in a spleen sample from farm B) shared 99.0% nucleotide identity with each other; and JJ-1601 shared 99.1% and JJ-1602 shared 99.5% nucleotide identity with the LOM strain. However, they shared low nucleotide identity (84%) with PC11WB, a virus isolated from a wild boar in South Korea (6). Phylogenetic analysis indicated that both viruses were classified within subgroup 1.1 (online Technical Appendix Figure 2). Compared with LOM, JJ-1601 contained 5 aa and JJ-1602 10 aa substitutions in the N<sup>pro</sup>-E2 region; these substitutions are not critical for acquisition of pathogenicity (online Technical Appendix Table 2) (7).

In this study, we observed residual virulence of the LOM strain in naive herds. Since CSFV vaccine was accidentally introduced onto Jeju Island in 2014, continuous LOM outbreaks have occurred (online Technical Appendix Table 3), resulting in tremendous damage to pig farms on the island. In addition, the virus has persistently circulated and caused repeated problems within the infected herds. Given that accidental vaccination was limited in 2014, the

<sup>1</sup>These authors contributed equally to this article.



**Figure.** Clinical signs and pathologic lesions in naive pig infected with classical swine fever virus LOM vaccine strain, Jeju Island, South Korea. A) Cyanosis of ear. B) Hemorrhages in kidney. C) Marginal infarction of spleen. D) Button ulcers in large intestine. E) Hemorrhages in bladder.

continuous classical swine fever outbreaks, including those occurring on farms A and B, resulted from farm-to-farm transmission of the vaccine virus strain.

CSFV live vaccination should guarantee safety to host animals: safety in young pigs, safety in pregnant sows, non-transmissibility, and no reversion to virulence (8). The first problem with the LOM vaccine was that the virus spread beyond initially introduced herds. Our results indirectly support horizontal transmissibility of the LOM vaccine within the infected herd. Another factor is the capacity of LOM to cause clinical signs in both young pigs and pregnant sows. Although we could not make observations in 2014 when the vaccine strain was first introduced, viruses with 99% nucleotide identity with LOM were found in CSFV-infected pigs that exhibited clinical signs and typical pathologic lesions of classical swine fever. This virulence could have occurred because of insufficient attenuation or reversion to virulence (7,9). In a previous study, vaccination of naive pregnant sows with LOM induced stillbirth and fetus mummification (10). These results suggested that transplacental transmission and fetal death might be inherent features of the vaccine, which indicates insufficient attenuation during virus adaptation in vitro. Further study is needed to determine the basis for the virulence of the LOM strain in young pigs.

In conclusion, we must reconsider the use of LOM in the classical swine fever MLV and use a strain with experimental results satisfying safety requirements. Furthermore, control methods, including a marker vaccine for differentiating infected from vaccinated animals, are needed to stop the continuous damage and spread of LOM on Jeju Island.

#### Acknowledgments

We thank Hyeckyoung Yoo and Kyungsu Yang for providing data and critical information about the current status of classical swine fever on Jeju Island, South Korea.

This work was partially supported by a grant from the Department of Homeland Security Center of Excellence for Emerging and Zoonotic Animal Diseases at Kansas State University (Manhattan, Kansas, USA).

#### About the Author

Mr. Je is a pig veterinarian who previously completed his master's degree at Konkuk University, Seoul, South Korea. His primary research interests include highly contagious diseases of pigs. Mr. Kwon is a graduate student at Konkuk University. His research interests are viral and contagious diseases of pigs.

#### References

- van Oirschot JT. Vaccinology of classical swine fever: from lab to field. *Vet Microbiol.* 2003;96:367–84. <http://dx.doi.org/10.1016/j.vetmic.2003.09.008>
- Graham SP, Everett HE, Haines FJ, Johns HL, Sosan OA, Salguero FJ, et al. Challenge of pigs with classical swine fever viruses after C-strain vaccination reveals remarkably rapid protection and insights into early immunity. *PLoS One.* 2012;7:e29310. <http://dx.doi.org/10.1371/journal.pone.0029310>
- Song JY, Lim SI, Jeoung HY, Choi EJ, Hyun BH, Kim B, et al. Prevalence of classical swine fever virus in domestic pigs in South Korea: 1999–2011. *Transbound Emerg Dis.* 2013;60:546–51. <http://dx.doi.org/10.1111/j.1865-1682.2012.01371.x>
- Yoo SJ, Kwon T, Kang K, Kim H, Kang SC, Richt JA, et al. Genetic evolution of classical swine fever virus under immune environments conditioned by genotype 1-based modified live virus vaccine. *Transbound Emerg Dis.* 2018 Jan 10; [Epub ahead of print]. <http://dx.doi.org/10.1111/tbed.12798>

5. Kwon T, Lee D-U, Yoo SJ, Je SH, Shin JY, Lyoo YS. Genotypic diversity of porcine circovirus type 2 (PCV2) and genotype shift to PCV2d in Korean pig population. *Virus Res.* 2017;228:24–9. <http://dx.doi.org/10.1016/j.virusres.2016.11.015>
6. Jeoung HY, Lim JA, Lim SI, Kim JJ, Song JY, Hyun BH, et al. Complete genome sequences of classical swine fever virus strains isolated from wild boars in South Korea. *Genome Announc.* 2013;1:e0014713. <http://dx.doi.org/10.1128/genomeA.00147-13>
7. Tamura T, Sakoda Y, Yoshino F, Nomura T, Yamamoto N, Sato Y, et al. Selection of classical swine fever virus with enhanced pathogenicity reveals synergistic virulence determinants in E2 and NS4B. *J Virol.* 2012;86:8602–13. <http://dx.doi.org/10.1128/JVI.00551-12>
8. World Organisation for Animal Health. Classical swine fever (hog cholera). In: *OIE terrestrial manual*. Paris: The Organisation; 2014. p. 1–26.
9. Terpstra C. Epizootiology of swine fever. *Vet Q.* 1987;9(sup1):50–60. <http://dx.doi.org/10.1080/01652176.1987.9694138>
10. Lim SI, Song JY, Kim J, Hyun BH, Kim HY, Cho IS, et al. Safety of classical swine fever virus vaccine strain LOM in pregnant sows and their offspring. *Vaccine.* 2016;34:2021–6. <http://dx.doi.org/10.1016/j.vaccine.2016.02.062>

Address for correspondence: Young S. Lyoo, Konkuk University, College of Veterinary Medicine, 120 Neungdong-ro Gwangjin-gu, Seoul 05029, South Korea; email: lyoo@konkuk.ac.kr

## Imported Congenital Rubella Syndrome, United States, 2017

Roukaya Al Hammoud, James R. Murphy, Norma Pérez<sup>1</sup>

Author affiliation: The University of Texas Health Science Center, Houston, Texas, USA

DOI: <https://doi.org/10.3201/eid2404.171540>

Although transmission of rubella virus within the United States is rare, the risk for imported cases persists. We describe a rubella case in a newborn, conceived in Saudi Arabia, in Texas during 2017, highlighting the importance of active surveillance and early diagnosis of this disease.

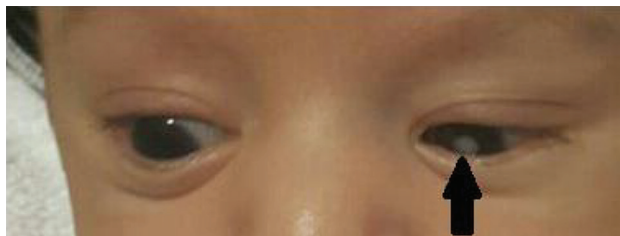
A full-term male infant was born in Houston, Texas, USA, in early 2017 to a 29-year-old woman from Pakistan; this pregnancy was her first. Delivery was by emergent cesarean section because of fetal cardiac decelerations. The mother had lived in Saudi Arabia for 3 years before traveling to the United States in her third trimester of pregnancy.

<sup>1</sup>All authors contributed equally to this article.

Early in pregnancy, while in Saudi Arabia, she had acute onset of fever and rash, then arthralgia. Symptoms resolved within a week without medical treatment. She reported prenatal care in Saudi Arabia but had no records with her; she knew of no ill contacts during pregnancy. At delivery, she had negative results for HIV and negative rapid plasma reagin but positive rubella IgG titers (>500 IU/ML; reference, positive >10 IU/mL).

The infant was transferred to The University of Texas Health Science Center (Houston, Texas, USA). Birthweight and head circumference were below the third percentile. Symptoms were respiratory distress, left leukocoria (Figure), systolic heart murmur, and depressed neonatal reflexes. Laboratory evaluation showed normal peripheral leukocyte count, hemoglobin, and liver enzymes and platelet count of 93,000/mm<sup>3</sup>. Because of suspected congenital rubella infection, we placed the patient on contact isolation. Tests for cytomegalovirus and toxoplasma were negative. We considered congenital Zika syndrome, but no testing was done. An ophthalmologic exam confirmed left cataract without retinal involvement. Chest radiograph showed clear lungs; echocardiogram showed supravulvar pulmonary stenosis and patent ductus arteriosus. Cerebrospinal spinal fluid (CSF) analysis showed normal leukocyte, glucose, and protein levels. Blood and CSF cultures were negative. On the fourth day of life, blood rubella IgG was >500 IU/mL (reference, immune ≥10 IU/mL), and blood rubella IgM was >400 AU/mL (reference range 20–24.9 AU/mL). Ultrasound examination of the brain was unremarkable. Radiographic evaluation of long bones showed diffuse coarse trabecular pattern, striated appearance of the metaphysis, and lucent linear areas. Audiometry brainstem response testing failed in the left ear. Thrombocytopenia self-resolved.

We reported the case to the local health department. We sent no clinical specimens for rubella virus detection. The patient was discharged on his tenth day of life and had uncomplicated pulmonary valvuloplasty and cataract removal surgery by 6 weeks of age. The infectious disease team last saw the patient at 2 months of age; at that time, he was developing well, but his growth was borderline. The patient and his family traveled to Pakistan 3 months after birth.



**Figure.** Left eye cataract (arrow) in case-patient with congenital rubella syndrome, Texas, USA, 2017. Patient was 4 weeks of age.