

**Ana Paula Moreira Franco-Luiz,
Alexandre Fagundes-Pereira,
Galileu Barbosa Costa,
Pedro Augusto Alves,
Danilo Bretas Oliveira,
Cláudio Antônio Bonjardim,
Paulo César Peregrino Ferreira,
Giliane de Souza Trindade,
Carlos Javier Panei,
Cecilia Mónica Galosi,
Jônatas Santos Abrahão,
and Erna Geessien Kroon**

Author affiliations: Universidade Federal de Minas Gerais, Belo Horizonte, Brazil (A.P.M. Franco-Luiz, A. Fagundes-Pereira, G.B. Costa, P.A. Alves, D.B. Oliveira, C.A. Bonjardim, P.C.P. Ferreira, G.S. Trindade, J.S. Abrahão, E.G. Kroon); Universidad Nacional de la Plata, Buenos Aires, Argentina (C.J. Panei, C.M. Galosi); Consejo Nacional Investigaciones Científicas y Técnicas, Buenos Aires (C.J. Panei); and Comisión de Investigaciones Científicas Provincia de Buenos Aires, Buenos Aires (C.M. Galosi)

DOI: <http://dx.doi.org/10.3201/eid2009.140154>

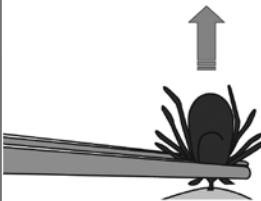
References

- Trindade GS, Lobato ZIP, Drumond BP, Leite JA, Trigueiro RC, Guedes MIMC, et al. Isolation of two vaccinia virus strains from a single bovine vaccinia outbreak in rural area from Brazil: implications on the emergence of zoonotic orthopoxviruses. *Am J Trop Med Hyg.* 2006;75:486–90.
- Campos RK, Brum MC, Nogueira CE, Drumond BP, Alves PA, Siqueira-Lima L, et al. Assessing the variability of Brazilian vaccinia virus isolates from a horse exanthematic lesion: coinfection with distinct viruses. *Arch Virol.* 2011;156:275–83. <http://dx.doi.org/10.1007/s00705-010-0857-z>
- Mota BEF, Trindade GS, Diniz TC, da Silva-Nunes M, Braga EM, Urbano-Ferreira M, et al. Seroprevalence of orthopoxvirus in an Amazonian rural village, Acre, Brazil. *Arch Virol.* 2010;155:1139–44. <http://dx.doi.org/10.1007/s00705-010-0675-3>
- Abrahão JS, Silva-Fernandes AT, Lima LS, Campos RK, Guedes MI, Cota MM, et al. Vaccinia virus infection in monkeys, Brazilian Amazon. *Emerg Infect Dis.* 2010;16:976–9. <http://dx.doi.org/10.3201/eid1606.091187>
- Cohen JI, Hohman P, Preuss JC, Li L, Fischer SH, Fedorko DP, et al. Detection of vaccinia virus DNA, but not infectious virus, in the blood of smallpox vaccine recipients. *Vaccine.* 2007;25:4571–4. <http://dx.doi.org/10.1016/j.vaccine.2007.03.044>
- Savona MR, Dela Cruz WP, Jones MS, Thornton JA, Xia D, Hadfield TL, et al. Detection of vaccinia DNA in the blood following smallpox vaccination. *JAMA.* 2006;295:1895–900. <http://dx.doi.org/10.1001/jama.295.16.1898>
- de Souza Trindade G, Li Y, Olson VA, Emerson G, Regnery RL, da Fonseca FG, et al. Real-time PCR assay to identify variants of vaccinia virus: implications for the diagnosis of bovine vaccinia in Brazil. *J Virol Methods.* 2008;152:63–71. <http://dx.doi.org/10.1016/j.jviromet.2008.05.028>
- Damon IK. Poxviruses. In: Knipe DM, Howley PM, Griffin DE, Lamb RA, Martin MA, Roizman B, et al., editors. *Fields virology.* Vol II. 5th ed. Philadelphia: Lippincott Williams and Wilkins; 2007. p. 2947–75.
- Trindade GS, Emerson GL, Carroll DS, Kroon EG, Damon IK. Brazilian vaccinia viruses and their origins. *Emerg Infect Dis.* 2007;13:965–72. <http://dx.doi.org/10.3201/eid1307.061404>
- Abrahão JS, Guedes MI, Trindade GS, Fonseca FG, Campos RK, Mota BF, et al. One more piece in the VACV ecological puzzle: could peridomestic rodents be the link between wildlife and bovine vaccinia outbreaks in Brazil? *PLoS ONE.* 2009;4:e7428. <http://dx.doi.org/10.1371/journal.pone.0007428>

Address for correspondence: Erna G. Kroon, Laboratório de Vírus, Departamento de Microbiologia, Instituto de Ciências Biológicas, Universidade Federal de Minas Gerais, Av. Antônio Carlos, 6627, Caixa Postal 486, CEP 31270-901, Belo Horizonte, Minas Gerais, Brazil; email: ernagkroon@gmail.com

How to Correctly Remove a Tick

Grasp the tick firmly and as closely to the skin as possible. With a steady motion, pull the tick's body away from the skin. Do not be alarmed if the tick's mouthparts remain in the skin. Cleanse the area with an antiseptic.



For more information please contact:
Centers for Disease Control and Prevention
1600 Clifton Road NE, Atlanta, GA 30333
Telephone: 1-800-CDC-INFO (232-4636)
TTY: 1-888-232-63548
Web: www.cdc.gov/Lyme

Cerebellitis Associated with Influenza A(H1N1)pdm09, United States, 2013

To the Editor: Central nervous system (CNS) manifestations of influenza are uncommon, especially in adults (1,2), and influenza-associated cerebellitis is exceedingly rare: 8 cases have been reported (3–7; online Technical Appendix). We describe a case of cerebellitis caused by influenza A(H1N1)pdm09 in an adult woman.

The 37-year-old female patient who sought medical care in Florida, United States, on January 5, 2013, described a 4-day history of intermittent fever of 38.5°C, generalized fatigue, diffuse headache, mild nonproductive cough, 3 episodes of vomiting, and decreased oral intake. On January 4, she experienced acute onset of ataxia and dysarthric speech with slurred pronunciation. She reported no contact with sick persons, recent travel, or exposure to pets or birds. She had a medical history of asthma since childhood, controlled by using montelukast tablets and inhaled steroids. The patient denied having ever received an influenza vaccination.

The patient appeared ill; her oral temperature was elevated at 38.3°C, but other vital signs were within normal limits (blood pressure 109/70 mm Hg; pulse rate 88 beats/minute; respiratory rate 15 breaths per minute; and oxygen saturation 98% at room air). Mucosal membranes appeared normal. No neck stiffness or palpable lymph nodes were noted. Results of heart examination were normal. Lungs were clear to auscultation, and the abdomen was soft, indicating no hepatosplenomegaly or palpable masses. No rash was seen. The neurologic examination revealed normal mental status but moderate ataxic dysarthria. Her cranial nerves were intact, and motor strength was 5/5 throughout. Results of a sensory

examination were normal, and patient's reflexes were largely intact; Babinski sign was absent. However, her coordination was bilaterally impaired in finger-to-nose testing, and her gait was notably broad-based and ataxic.

Laboratory test results showed a leukocyte count of 13.72×10^3 cells/mm³; percentages of neutrophils and lymphocytes were within reference limits at 59% and 25%, respectively. Levels of electrolytes, liver enzymes, and creatine phosphokinase were within reference ranges. C-reactive protein level was below the limit of detection. A nonenhanced brain computed tomographic scan revealed no pertinent findings. Brain magnetic resonance imaging (MRI) revealed enlarged bilateral cerebellar hemispheres with evidence of hypointensity of the affected thoracic vertebral segment on T1 image and hyperintensity on the T2 image (Figure). A lumbar puncture drained clear and colorless cerebrospinal fluid (CSF) with an opening pressure of 15 cm of H₂O. CSF analysis was pertinent, showing presence of erythrocytes (7.5/mm³) and elevated number of leukocytes (330/mm³ [13% neutrophils and 62% lymphocytes]). Glucose and protein levels in CSF were 61 mg/dL and 41 mg/dL, respectively. Blood and urine cultures were

negative for pathogens. A chest radiograph did not show infiltrates. Bacterial culture, acid-fast smear, and culture of CSF were all negative. Blood and CSF tests for HIV syphilis, respectively, were nonreactive. However, reverse transcription PCR (RT-PCR) for influenza A(H1N1)pdm09 virus RNA was positive in the nasopharyngeal swab sample and CSF specimens, at a titer of 4.5×10^5 and 671 RNA copies/mL, respectively. RT-PCR of CSF was negative for viruses, including herpes simplex, Epstein-Barr, cytomegalovirus, West Nile, and herpes zoster.

The patient was given oseltamivir, 75 mg orally twice daily for 5 days. She experienced a progressive improvement of ataxia and dysarthria during her hospital stay and was discharged after 1 week. At a follow-up visit 2 months later, the patient had remained healthy and neurologically stable.

Cerebellitis, or acute cerebellar ataxia, is an inflammatory process of the cerebellar white matter that occasionally is manifested after systemic viral or bacterial infections (8). The following pathogens are known to cause acute cerebellitis: viruses varicella-zoster, herpes simplex, Epstein-Barr, rotavirus, echovirus, coxsackie, mumps, measles, and rubella; and bacteria *Borrelia burgdorferi*, *Coxiella*

burnetii, *Salmonella typhi*, and *Bordetella pertussis* (8). Although the condition is presumed to be more common in children, adult cases of cerebellitis have been well described (8).

Before this case, influenza cerebellitis had been diagnosed in 8 cases as of 2011 (3–7) (online Technical Appendix Table, <http://wwwnc.cdc.gov/EID/article/20/9/14-0160-Techapp1.pdf>). Two cases were reported in adult women and the remaining were in children. Four had a probable diagnosis of influenza cerebellitis, although positive viral culture or RT-PCR was lacking (4). Seven case-patients had influenza-like illness preceding the neurologic symptoms (3–6). One case-patient showed evidence of pneumonia, and described the interval from respiratory illness onset to developing of cerebellar signs (6). Clinical sequelae, displayed in most case-patients affected by influenza cerebellitis (3,4,6,7), varied from complete recovery to development of serious complications such as hydrocephalus (5).

The pathogenic mechanism of influenza virus infection on the CNS can be either a direct invasion of the virus that causes acute illness or, more typically, a delayed autoimmune demyelinating postviral encephalopathy (9,10). Amplification of viral DNA in CSF is rare in most influenza-related CNS infections (10). In this case, the positive RT-PCR results for influenza A and the pertinent brain MRI findings, as well as the concurrent influenza prodromal symptoms, suggest that acute influenza cerebellitis, rather than a postinfluenza encephalopathy, caused the associated neurologic findings.

The limitation of this report includes the lack of sequence data comparing the patient's viral RNA from the CSF and the nasopharynx and the absence of sequential sampling during the course of her illness. In conclusion, influenza virus, though rare, should remain a consideration in patients who have acute cerebellitis during influenza season.

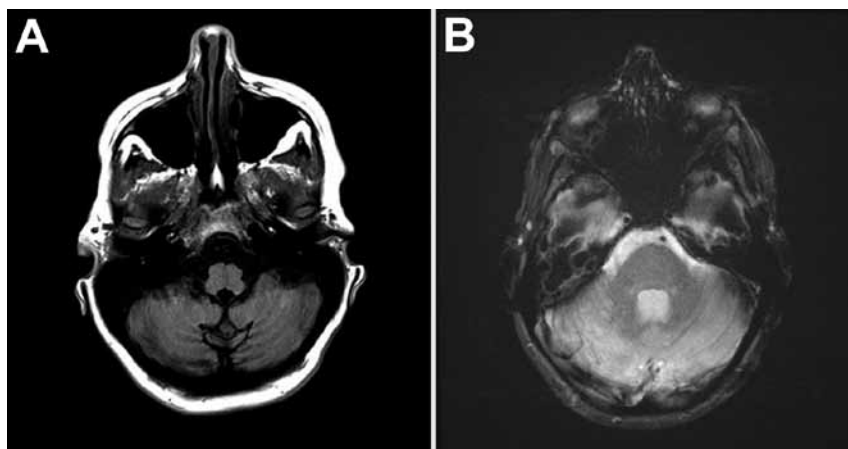


Figure. A) Magnetic resonance images of the brain of a woman with cerebellitis associated with influenza A(H1N1)pdm09, United States, 2013. T1-weighted axial MRI brain sequence showing hypo-intensity of bilateral cerebellar hemispheres. B) T2-weighted axial MRI brain sequence showing hyperintensity of bilateral cerebellar hemispheres.

Acknowledgments

We thank Lesley K. of the University of Miami Writing Center staff for the help in crafting the revised manuscript.

Maroun M. Sfeir and Catherine E. Najem

Author affiliations: University of Miami Miller School of Medicine/Jackson Memorial Hospital, Miami, Florida, USA (M.F. Sfeir); and Roger Williams Medical Center, Providence, Rhode Island, USA (C.E. Najem)

DOI: <http://dx.doi.org/10.3201/eid2009.140160>

References

1. Tan K, Prerna A, Leo YS. Surveillance of H1N1-related neurological complications. *Lancet Neurol*. 2010;9:142–3. [http://dx.doi.org/10.1016/S1474-4422\(10\)70015-6](http://dx.doi.org/10.1016/S1474-4422(10)70015-6)
2. Glaser CA, Winter K, DuBray K, Harriman K, Uyeki TM, Sejvar J, et al. A population-based study of neurologic manifestations of severe influenza A(H1N1)pdm09 in California. *Clin Infect Dis*. 2012;55:514–20. <http://dx.doi.org/10.1093/cid/cis454>
3. Hayase Y, Tobita K. Probable post-influenza cerebellitis. *Intern Med*. 1997;36:747. <http://dx.doi.org/10.2169/internalmedicine.36.747>
4. Tili-Graess K, Mhiri Souei M, Mlaiki B, Arifa N, Moulahi H, Jamni Gharbi H, et al. Imaging of acute cerebellitis in children. Report of 4 cases. [in French] *J Neuroradiol*. 2006;33:38–44 [http://dx.doi.org/10.1016/S0150-9861\(06\)77226-1](http://dx.doi.org/10.1016/S0150-9861(06)77226-1)
5. Apok V, Alamri A, Qureshi A, Donaldson-Hugh B. Fulminant cerebellitis related to H1N1: a first case report. P0102. *J Neurol Neurosurg Psychiatry*. 2010;81:e53. <http://dx.doi.org/10.1136/jnnp.2010.226340.143>
6. Hackett I, O'Sullivan R, Zaid AA, Rea D, Walsh S. Acute cerebellitis associated with dual influenza A (H1N1) and B infection. *Ir Med J*. 2013;106:87–8.
7. Ishikawa T, Fujio Y, Morita M, Takiyama Y, Nakano I. An adult case of acute cerebellitis after influenza A infection with a cerebellar cortical lesion on MRI. [in Japanese]. *Rinsho Shinkeigaku*. 2006;46:491–5.
8. Sawaiishi Y, Takada G. Acute cerebellitis. *Cerebellum*. 2002;1:223–8. <http://dx.doi.org/10.1080/14734220260418457>
9. Mizuguchi M. Influenza encephalopathy and related neuropsychiatric syndromes. *Influenza Other Respir Viruses*. 2013;7:67–71. <http://dx.doi.org/10.1111/irv.12177>
10. Goenka A, Michael BD, Ledger E, Hart IJ, Absoud M, Chow G, et al. Neurological manifestations of influenza infection in children and adults: results of a national British surveillance study. *Clin Infect Dis*. 2014;58:775–84. <http://dx.doi.org/10.1093/cid/cit922>

Address for correspondence: Maroun M. Sfeir, Department of Medicine, University of Miami Miller School of Medicine/Jackson Memorial Hospital, 1611 NW 12th Ave, Miami, FL 33136, USA; email: msfeir@med.miami.edu

Potential Human Adaptation Mutation of Influenza A(H5N1) Virus, Canada

To the Editor: In December 2013, influenza associated with pandemic influenza A H5N1 was reported in Canada in a patient who had traveled to China; the patient died in January 2014. This case leaves unanswered questions.

In the absence of direct poultry contact by the patient, the possible route of transmission and infection, often influenced by receptor-binding properties of the virus, requires special attention. The full genome and phylogenetic analysis by Pabbaraju et al. (1) provides a summary of what can typically be deduced from the sequence. The authors also mention 2 novel mutations, R189K and G221R, in the hemagglutinin (HA) protein (R193K and G225R in H3 numbering, used hereafter). When mapped to the H5 HA protein structure by using FluSurver in GISAID (<http://www.gisaid.org>, <http://flusurver.bii.a-star.edu.sg>), both mutations are found in the immediate receptor-binding pocket, and G225R has been known to change specificity of an H3N2 virus toward human erythrocytes (2). The same position is also

known for receptor recognition changes in the 2009 pandemic H1N1 virus (mutations D222G, D225G, or D239G in different numberings). Besides A/Alberta/01/2014 (clade 2.3.2.1c), the mutation G225R has been found in 3 other H5N1 sequences: A/duck/Human/15/2004 (clade 2.3.3), A/chicken/Xinjiang/53/2005, and A/chicken/Xinjiang/27/2006 (both clade 7, all lineage assignments made with LABEL, <http://label.phiresearchlab.org/>). Although few G225R mutations were found, they were all found in avian hosts, indicating that the mutation can occur sporadically and avian-like receptor-binding properties may not be fully abolished by G225R.

In the absence of glycan-binding data or crystal structures, which take longer to deduce, computational structural modeling is an efficient and safe alternative for fast preliminary assessment of these mutations in their natural structural context of H5N1 binding pockets. We have shown (3) that a method using the classical AMBER03 molecular mechanics force field (4) with an implicit solvation model in combination with short molecular dynamics simulations in YASARA (5) can reproduce relative preference for human-like α 2,6-linked versus avian-like α 2,3-linked sialic acid receptors. The interaction energies of all atoms in a system are described and combined with distance-dependent functions for different interaction types, including bonds, various angles, van der Waals, electrostatics, and solvent, which leads to consideration of the concerted effects of all residues in the binding pocket. By using this energy function, short molecular dynamics simulations enable all atoms to move for specified intervals within the constraints of their interactions. These simulations are used to minimize and finally predict the energies of the wild-type and mutant HA proteins for their ligand-bound and unbound states considering their respective ligands (see Methods section of [3] for details).

Cerebellitis Associated with Influenza A(H1N1)pdm09, United States, 2013

Technical Appendix Table. Characteristics of 8 reported cases of influenza cerebellitis in 5 published articles before this study. Six of the cases were described in children. Five patients had possible diagnosis of influenza cerebellitis. One patient had a complicated course.

Published case, year of publication, (Language of publication)	Characteristics, signs, symptoms	Brain imaging	CSF analysis	Confirmed (C) or probable (P) influenza cerebellitis	Lower respiratory tract symptoms and chest radiography findings	Treatment	Resolution of symptoms
<i>Hayase Y et al, Internal Medicine 1997</i> (English)	Woman, 31 y; fever and ataxia	Normal brain CT and MRI	Normal cell count, glucose and protein	(C) High serum hemagglutination inhibition titer to influenza B, and positive CSF RT-PCR for influenza B nucleoprotein gene	NA	NA	NA
<i>Tilli-Graies K et al, J Neuroradiol. 2006</i> (French)	4 children, 2-7 y; headache, fever, and vomiting; ataxia was present in 2 cases	Initial MRI (2 cases) demonstrated increased intensity on T2W and Flair sequences of the cerebellar gray matter	High lymphocytes and proteins in samples from 3 children; normal values for 1 child	(P) Viral serologic tests were negative for 3 cases; serum sample from 1 child was positive for Epstein-Barr virus	No respiratory symptoms noted. No chest radiograph	Prednisone ×5 d for 3 cases and ×10 d for 1 case.	Complete resolution of symptoms in 3 cases; persistent mild right upper limb paresis in 1
<i>Apok V et al, J Neurol Neurosurg Psychiatry Poster 0102,2010</i> (English)	Teenaged girl with acute fulminant cerebellitis following a course of antiviral for H1N1 virus	Hydrocephalus	NA	(P) Influenza RT-PCR in CSF was negative	Patient had cough and fever and was started on antiviral therapy; no chest radiograph	NA	Residual left-sided ataxia after 3 months.
<i>Hackett I et al, Ir Med J. 2013</i> (English)	Child, 6 y; headache, worsening dysarthria and ataxia; coordination revealed significant bilateral dysdiadochokinesia	MRI brain revealed findings consistent with a diagnosis of cerebellitis, no enhancement was noted post contrast	Lumbar puncture parameters were normal	(C) CSF samples RT-PCR–positive for influenza A and influenza B and nasopharyngeal aspirate RT-PCR–positive for influenza A(H1N1) and B.	2 weeks before treatment sought, patient had rhinitis, cough, and fever; chest radiography showed mild bilateral bronchial prominence	Oseltamivir ×5 d	All symptoms fully resolved after 1 week
<i>Ishikawa T et al, Rinsho Shinkeigaku. 2006</i> (Japanese)	Woman, 25 y; fever and headache	T2-weighted brain MRI demonstrated a high signal lesion in the cerebellar cortex.123l-	Pleocytosis	(C) Nasal swab sample positive in the influenza assay and a ≥4× change in the antibody titer to influenza virus A	Not available	Oseltamivir	Truncal ataxia normalized after 3 mo.†

Published case, year of publication, (Language of publication)	Characteristics, signs, symptoms	Brain imaging	CSF analysis	Confirmed (C) or probable (P) influenza cerebellitis	Lower respiratory tract symptoms and chest radiography findings	Treatment	Resolution of symptoms
		IMP-SPECT showed hypoperfusion in the cerebellum		(H3N2) detected by hemagglutination inhibition			

*NA: not available.

†Followup imaging showed cerebellar cortical lesion observed on MRI had resolved 80 days after hospitalization; laboratory data indicated that cerebrospinal fluid pleocytosis had normalized ≈3 months later.