

Bejel was known to be endemic to the Middle East and was prevalent in Iraq and in the Bedouin population in Saudi Arabia until the 1980s (5,6). In 1995, it was diagnosed in 3 children and their father in southeastern Turkey, an area where no cases of bejel had been reported for >30 years (7). In 1954, 1 epidemiologic study of bejel in Iran reported a prevalence of 23%–34% in 4 remote villages of Khouzistan (8), near the home of the case-patient in the current study. Since 1954, no cases in Iran have been reported to WHO.

This case report shows that bejel continues to be transmitted among isolated, poor rural communities in Iran. Our patient was living in a remote, rural district of low socioeconomic status, and his community had almost no access to medical facilities. WHO recently convened a meeting to discuss a new initiative for the eradication of yaws, after it was demonstrated that a single oral dose of azithromycin was as effective as injected penicillin in the treatment of this disease (9,10). Bejel should be equally susceptible to eradication, but only if health services are made available to poor rural communities in areas where the disease is endemic. We recommend that countries in which this disease was formerly declared endemic initiate surveillance programs with the goal of eradication if new cases are found.

**Alireza Abdolrasouli,  
Adam Croucher,  
Yahya Hemmati,  
and David Mabey**

Author affiliations: Imperial College Healthcare National Health Service Trust, London, UK (A. Abdolrasouli, A. Croucher); Imperial College London, London (A. Abdolrasouli); Marie-Curie Medical Institute, Tehran, Iran (A. Abdolrasouli, Y. Hemmati); and London School of Hygiene and Tropical Medicine, London (D. Mabey)

DOI: <http://doi.org/10.3201/eid1901.120756>

## References

1. Antal GM, Lukehart SA, Meheus AZ. The endemic treponematoses. *Microbes Infect.* 2002;4:83–94. [http://dx.doi.org/10.1016/S1286-4579\(01\)01513-1](http://dx.doi.org/10.1016/S1286-4579(01)01513-1)
2. World Health Organization. Informal consultation on endemic treponematoses, 6–7 July 1995. Geneva; The Organization; 1995 (WHO/EMC/95.3) [cited 2012 May 22] <http://apps.who.int/iris/handle/10665/69816>
3. World Health Organization. The World Health Report 1998—Life in the 21st century; a vision for all. Geneva: The Organization; 1998 [cited 2012 May 22] <http://www.who.int/whr/1998/en/index.html>
4. Meheus A. Non-venereal treponematoses. *Medicine (Baltimore)*. 2005;33:82–4. PubMed <http://dx.doi.org/10.1383/medc.2005.33.10.82>
5. Csonka G, Pace J. Endemic nonvenereal treponematoses (bejel) in Saudi Arabia. *Clin Infect Dis.* 1985;7:S260–5. PubMed [http://dx.doi.org/10.1093/clinids/7-Supplement\\_2.S260](http://dx.doi.org/10.1093/clinids/7-Supplement_2.S260)
6. Pace JL, Csonaka GW. Late endemic syphilis: case report of bejel with gummatous laryngitis. *Genitourin Med.* 1988;64:202–4. PubMed
7. Yakinci C, Özcan A, Aslan T, Demirhan B. Bejel in Malatya, Turkey. *J Trop Pediatr.* 1995;14:117–20. PubMed
8. Ansari N, Faghih MA, Hajian A, Bijan H. Contribution à l'étude de "bejel" en Iran, report préliminaire. *Acta Med Iran.* 1954;1:327–41.
9. Mitjà O, Hays R, Ipai A, Penias M, Paru R, Fagaho D, et al. Single-dose azithromycin versus benzathine benzylpenicillin for treatment of yaws in children in Papua New Guinea: an open-label, non-inferiority, randomised trial. *Lancet.* 2012;379:342–7. PubMed [http://dx.doi.org/10.1016/S0140-6736\(11\)61624-3](http://dx.doi.org/10.1016/S0140-6736(11)61624-3)
10. Maurice J. WHO plans new yaws eradication campaign. *Lancet.* 2012;379:1377–8. PubMed [http://dx.doi.org/10.1016/S0140-6736\(12\)60581-9](http://dx.doi.org/10.1016/S0140-6736(12)60581-9)

Address for correspondence: Alireza Abdolrasouli, Department of Medical Microbiology, 4th Floor, East Wing, Charing Cross Hospital, Imperial College Healthcare NHS Trust, Fulham Palace Rd, London W6 8RP, UK; email: [alireza.abdolrasouli@imperial.nhs.uk](mailto:alireza.abdolrasouli@imperial.nhs.uk)

All material published in *Emerging Infectious Diseases* is in the public domain and may be used and reprinted without special permission; proper citation, however, is required.

## Antiretroviral Therapy-associated Coccidioidal Meningitis

**To the Editor:** Coccidioidomycosis, a reemerging fungal infection in the United States, comprises ≈150,000 cases annually (1,2). We report a case of postmortem examination-proven antiretroviral therapy (ART)-associated coccidioidomycosis manifesting as atypical lymphocytic meningitis, which we believe represents a rare presentation of immune reconstitution inflammatory syndrome (IRIS).

In September 2011, a 59-year-old man sought care in Atlanta, Georgia, USA, with new-onset headache, photophobia, and neck stiffness. He also reported fevers, chills, weight loss, dyspnea, and cough with scant hemoptysis. Two months earlier, he had sought care for epididymitis; HIV infection was diagnosed at that time (CD4+ T-cell count of 45 cells/μL [7%] and plasma HIV RNA level of 420,720 copies/mL [reference not detectable]). He was started on an ART regimen, and 1 week before his September 2011 illness, HIV RNA level had decreased to 790 copies/mL and CD4+ count had risen to 163 cells/μL (13%).

The patient was a thin African-American man who reported marked discomfort, with nuchal rigidity. Laboratory results were unremarkable except for serum sodium of 128 mEq/L (reference 132–144 mEq/L) and creatinine of 1.7 mg/dL (reference 0.7–1.2 mg/dL). Chest imaging showed a diffuse infiltrate in a miliary pattern. Noncontrast computed tomography scan of the head was normal. Cerebrospinal fluid (CSF) examination revealed an opening pressure of 31 cm H<sub>2</sub>O, 365 leukocytes/μL (reference <11/mL), (93% lymphocytes, 80% described as atypical), glucose 13 mg/dL (reference 40–70 mg/dL), and protein 171 mg/dL (reference 15–45 mg/dL).

Closer examination of the atypical CSF lymphocytes showed mostly CD3+ T cells, markedly variable in size and morphology, containing substantially irregular nuclear membranes, coarsened chromatin with multilobulated flower-shaped nuclei, and increased cytoplasm (Figure, panel A). India ink stain, acid-fast bacillus stain, and Gram stain were all negative. CSF Venereal Disease Research Laboratory and cryptococcal antigen test results also were negative. Flow cytometry on the CSF was not performed. No abnormal-appearing lymphocytes were noted in the blood.

Empirically, the patient was placed on 4-drug therapy plus dexamethasone for tuberculous meningitis, along with bacterial and viral meningitis coverage. Results of CSF cultures and viral PCR studies were negative. Magnetic resonance imaging of the brain showed 2 areas consistent with cavernous malformations but no abnormal meningeal enhancement. On day 5 of admission, blurred vision and confusion developed and rapidly progressed to obtundation. A repeat head computed tomography scan showed marked edema and transtentorial herniation, and a ventricular drain was placed. Full-strength voriconazole

was added empirically for coverage of common fungal organisms. However, the patient's clinical status worsened, and he died 2 days later.

On postmortem examination, brain pathology showed areas of necrosis, along with massive hemorrhage. Special staining of the necrotic tissue revealed marked inflammation surrounding multiple characteristic *Coccidioides* spp. spherules, 1 of which had ruptured and was spilling endospores (Figure, panel B). Examination of the lungs showed multiple granulomas that also contained coccidioidal spherules.

Pathogenic *Coccidioides* spp. is not indigenous to the Atlanta area; however, the patient was homeless and could have traveled to *Coccidioides* spp.–endemic areas. The need for increased suspicion for coccidioidomycosis in areas to which it is not endemic was highlighted further by a recent report identifying a case in Rome, Italy (3).

Coccidioidal meningitis is the most severe complication of coccidioidomycosis and results from lymphohematogenous spread from the lung, manifesting as fever, headache, changes in sensorium, malaise, and meningismus. CSF studies typically

show 100–500 leukocytes/ $\mu$ L (predominantly lymphocytes), low glucose, and protein >150 mg/dL. Culture of *Coccidioides* spp. from the CSF is diagnostic but is much less sensitive than detection of anticoccidioidal antibodies in the CSF (4).

The most intriguing aspect of this case is the atypical pleocytosis, which initially suggested lymphomatous or tuberculous meningitis and obscured the true diagnosis of coccidioidal disease. Atypical reactive CSF lymphocytes were described in a lymphoma patient in whom coexistent cryptococcal meningitis was diagnosed (5). Those cells were initially confused for CNS lymphoma and caused a similar diagnostic and therapeutic dilemma.

Haddow et al. recently proposed case definitions for such clinical phenomena involving cryptococcosis, offering that newly defined cryptococcal disease identified after ART initiation be termed ART-associated cryptococcosis, with a more virulent subset of disease attributed to the unmasking of cryptococcal IRIS (6). We propose that the case described here parallels that described by Haddow et al. and illustrates ART-associated coccidioidomycosis. Furthermore, because of the significant inflammatory process, granulomatous pathology, and exaggerated clinical deterioration in the setting of rapid ART-induced CD4+ T-cell recovery, we suggest that this case meets the proposed criteria for the unmasking form of IRIS (6,7).

The high percentage of atypical lymphocytes described here is unusual for an IRIS response and might reflect an unusual variation of the diverse immune mechanisms used during an IRIS phenomenon (8). Another unusual case of coccidioidal IRIS manifested as superior vena cava syndrome (9). Additionally, the use of high-dose corticosteroids in the absence of antifungal therapy might have contributed to more aggressive disease progression. We suggest that the discovery of atypical lymphocytic meningitis in

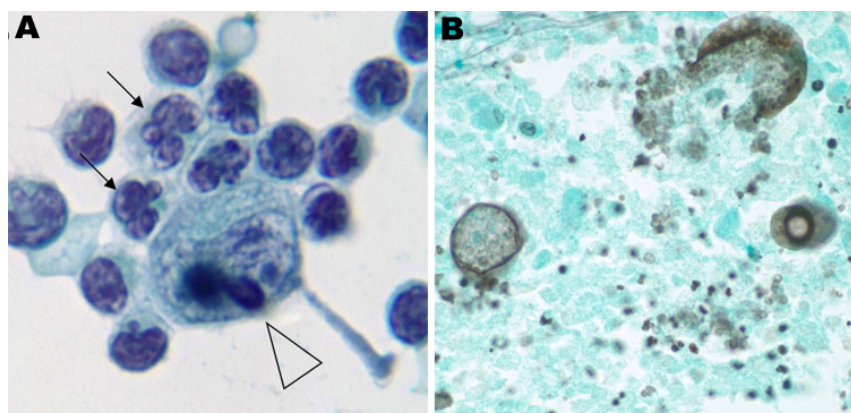


Figure. Test results of cerebrospinal fluid and brain tissue in HIV-positive man with signs and symptoms of meningitis, Atlanta, Georgia, USA, 2011. A) Atypical lymphocytes containing flower-shaped nuclei (arrows) and coarse chromocenters (arrowhead). Cerebrospinal fluid processed by Cytospin centrifuge (Thermo Electron Corp., Waltham, MA, USA) and prepared by Papanicolaou staining. Original magnification  $\times$ 100. B) Gomori methenamine silver stain of sampled brain tissue showing multiple spherules and endospores of *Coccidioides* spp. Original magnification  $\times$ 40.

a patient shortly after ART-associated immune recovery should alert the clinician to the possibility of coccidioidal meningitis.

**Ronald Tribble, Neil Edgerton,  
Salim Hayek, Daniel Winkel,  
and Albert M. Anderson**

Author affiliation: Emory University School of Medicine, Atlanta, GA, USA

DOI: <http://dx.doi.org/10.3201/eid1901.120889>

## References

- Benedict K, Park BJ. The re-emergence and changing epidemiology of coccidioidomycosis, United States, 1998–2010 [abstract]. International Conference on Emerging Infectious Diseases 2012: poster and oral presentation abstracts. Emerg Infect Dis [Internet]. 2012 Mar [2012 Mar 13]. <http://www.cdc.gov/EID/pdfs/ICEID2012.pdf>
- Galgiani JN, Ampel NM, Blair JE, Catanzaro A, Johnson RH, Stevens DA, et al. Coccidioidomycosis. Clin Infect Dis. 2005;41:1217–23. <http://dx.doi.org/10.1086/496991>
- D'Avino A, Di Giambenedetto S, Fabbiani M, Farina S. Coccidioidomycosis of cervical lymph nodes in an HIV-infected patient with immunologic reconstitution on potent HAART: a rare observation in a nonendemic area. Diagn Microbiol Infect Dis. 2012;72:185–7. <http://dx.doi.org/10.1016/j.diagmicrobio.2011.10.002>
- Blair JE. Coccidioidal meningitis: update on epidemiology, clinical features, diagnosis, and management. Curr Infect Dis Rep. 2009;11:289–95. <http://dx.doi.org/10.1007/s11908-009-0043-1>
- Davies SF, Gormus BJ, Yarchoan R, Kaplan ME. Cryptococcal meningitis with false-positive cytology in the CSF: use of T-cell resetting to exclude meningeal lymphoma. JAMA. 1978;239:2369–70. <http://dx.doi.org/10.1001/jama.1978.03280490053025>
- Haddow LJ, Colebunders R, Meintjes G, Lawn SD, Elliott JH, Manabe YC, et al. The International Network for the Study of HIV-associated IRIS (INSHI). Cryptococcal immune reconstitution inflammatory syndrome in HIV-1-infected individuals: proposed clinical case definition. Lancet Infect Dis. 2010;10:791–802. [http://dx.doi.org/10.1016/S1473-3099\(10\)70170-5](http://dx.doi.org/10.1016/S1473-3099(10)70170-5)
- Lawn SD, Bekker L-G, Miller RF. Immune reconstitution disease associated with mycobacterial infections in HIV-infected individuals receiving antiretrovirals. Lancet Infect Dis. 2005;5:361–73. [http://dx.doi.org/10.1016/S1473-3099\(05\)70140-7](http://dx.doi.org/10.1016/S1473-3099(05)70140-7)
- Price P, Murdoch DM, Agarwal U, Lewin SR, Elliott JH, French MA. Immune restoration diseases reflect diverse immunopathological mechanisms. Clin Microbiol Rev. 2009;22:651–63. <http://dx.doi.org/10.1128/CMR.00015-09>
- Mortimer RB, Libke R, Eghbalieh B, Bilello JF. Immune reconstitution inflammatory syndrome presenting as superior vena cava syndrome secondary to *Coccidioides* lymphadenopathy in an HIV-infected patient. J Int Assoc Physicians AIDS Care (Chic). 2008;7:283–5. <http://dx.doi.org/10.1177/1545109708326090>

Address for correspondence: Ronald Tribble, Emory University School of Medicine, Division of Infectious Diseases, 208 Woodruff Research Extension Bldg, 49 Jesse Hill Jr Dr, Atlanta, GA 30303, USA; email: [rtribble@emory.edu](mailto:rtribble@emory.edu)

## Concurrent Tuberculosis and Influenza, South Korea

**To the Editor:** The concurrence of active pulmonary tuberculosis (TB) and influenza in immunocompetent hosts is rarely reported. Such concurrence could distract clinicians from diagnosing TB during an influenza epidemic. We describe 7 cases of concurrent active pulmonary TB and influenza A(H1N1)pdm09 virus infection in South Korea.

At 2 teaching hospitals in Seoul, medical records were reviewed retrospectively. Among the 12,196 patients for whom A(H1N1)pdm09 infection was confirmed by real-time reverse transcription PCR from May 2009 through May 2011, a total of 7 (0.06%) were co-infected with newly diagnosed active pulmonary TB (Table). Patients who had a history of TB diagnosis were excluded.

Among the 7 co-infected patients, 6 (85.7%) were <30 years of

age. All but 1 patient, who had colon cancer, had been previously healthy. No patients had diabetes mellitus or HIV infection. One patient was a current smoker. For 5 patients, pulmonary TB was diagnosed within 1 week from the date of influenza diagnosis; initial chest radiographic findings were suggestive of active TB or pneumonia. Another 2 patients, for whom radiographic examination was not performed at the first visit, experienced worsening cough and blood-tinged sputum after improvement of influenza; laboratory tests for TB were performed, and pulmonary TB was diagnosed 17 days after the date of influenza diagnosis. For 4 patients, computed tomography of the chest was performed, and multiple nodular lesions, cavities, and tree-in-bud appearance were found. Lymphopenia at initial visit was detected in 2 patients. All *Mycobacterium tuberculosis* isolates were sensitive to anti-TB drugs, and clinical outcomes were good for all patients.

For persons infected with *M. tuberculosis*, lifetime risk for development of active TB is 5%–10%; this risk increases for those with immunocompromising conditions (1). One study reported that pulmonary TB was a risk factor for A(H1N1)pdm09 infection (2). However, the concurrence of influenza and pulmonary TB has been reported only a few times, and the findings have been mostly descriptive and somewhat contradictory. An old report, from 1919, describes TB diagnoses for patients who were not recovered completely from influenza pneumonia (3). During 1957–1958, Löfgren and Callans (4) observed 46 patients with newly detected TB that had been diagnosed shortly after Asian influenza; among them, 4 had a history of typical influenza.

In South Africa, among 72 patients who died of A(H1N1)pdm09 infection, 7 also had active TB (5).