

tected from a single fecal sample examined on microscopy (1), infection most likely resulted from consumption of infective eggs in the feces of a carnivore-definitive host. This host could have been a translocated domestic dog, thought to be the mechanism of recent introduction of *E. multilocularis* parasites into Sweden (7). It is also possible that a European strain of the parasite was introduced into North America in the last century, when red fox from France and Scandinavia were introduced (8).

The possible establishment of a European strain in North American wildlife, with spillover into domestic dogs, may have implications for public health and require increased vigilance by medical and veterinary personnel in the newly endemic region. Compared with native North American strains, European strains of *E. multilocularis* appear to have greater potential to cause alveolar hydatid disease (AHD) in humans. These strains are emerging worldwide (increasing in both prevalence and distribution) as a result of changes in landscape, climate, and wildlife-human interfaces (2,9,10). In Europe, human AHD can be fatal (definite or probable cause of death in 23.5% of 119 recent cases) and has low cure rates (5% of 408 recent cases) (2). As of 2000, in Europe and Asia, the estimated cost per case of AHD was US \$100,000–\$300,000 (9). Therefore, better understanding of the distribution, genetic diversity, and pathogenicity of strains of *E. multilocularis* is needed to assess risks and mitigate costs for public and veterinary health, as well as to provide evidence for the regulation and screening of imported domestic animals and translocated wildlife.

**Emily J. Jenkins,
Andrew S. Peregrine,
Janet E. Hill, Christopher Somers,
Karen Gesy, Brian Barnes,
Bruno Gottstein,
and Lydden Polley**

Author affiliations: University of Saskatchewan, Saskatoon, Saskatchewan, Canada (E. Jenkins, J.E. Hill, K. Gesy, L. Polley); University of Guelph, Guelph, Ontario, Canada (A. Peregrine); University of Regina, Regina, Saskatchewan, Canada (C. Somers); Westview Veterinary Hospital, Powell River, British Columbia, Canada (B. Barnes); and Universitat Bern, Bern, Switzerland (B. Gottstein)

DOI: <http://dx.doi.org/10.3201/eid1806.111420>

References

1. Peregrine AS, Jenkins EJ, Barnes B, Johnson S, Polley L, Barker IK, et al. Alveolar hydatid disease (*Echinococcus multilocularis*) in the liver of a Canadian dog in British Columbia, a newly endemic region. *Can Vet J*. In press.
2. Kern P, Bardonnnet K, Renner E, Auer H, Pawlowski Z, Ammann RW, et al. European echinococcosis registry: human alveolar echinococcosis, Europe, 1982–2000. *Emerg Infect Dis*. 2003;9:343–9.
3. Bowles J, McManus DP. NADH dehydrogenase I gene sequences compared for species and strains of the genus *Echinococcus*. *Int J Parasitol*. 1993;23:969–72. [http://dx.doi.org/10.1016/0020-7519\(93\)90065-7](http://dx.doi.org/10.1016/0020-7519(93)90065-7)
4. Nakao M, Xiao N, Okamoto M, Yanagida T, Sako Y, Ito A. Geographic pattern of genetic variation in the fox tapeworm *Echinococcus multilocularis*. *Parasitol Int*. 2009;58:384–9. <http://dx.doi.org/10.1016/j.parint.2009.07.010>
5. Knapp J, Bart JM, Glowatzki ML, Ito A, Gerard S, Maillard S, et al. Assessment of use of microsatellite polymorphism analysis for improving spatial distribution tracking of *Echinococcus multilocularis*. *J Clin Microbiol*. 2007;45:2943–50. <http://dx.doi.org/10.1128/JCM.02107-06>
6. Nakao M, Sako Y, Ito A. Isolation of polymorphic microsatellite loci from the tapeworm *Echinococcus multilocularis*. *Infect Genet Evol*. 2003;3:159–63. [http://dx.doi.org/10.1016/S1567-1348\(03\)00070-4](http://dx.doi.org/10.1016/S1567-1348(03)00070-4)
7. Osterman Lind E, Juremalm M, Christenson D, Widgren S, Hallgren G, Agren EO, et al. First detection of *Echinococcus multilocularis* in Sweden, February to March 2011. *Euro Surveill*. 2011;16:pii=19836.
8. Kamler JF, Ballard WB. A review of native and nonnative red foxes in North America. *Wildl Soc Bull*. 2002;30:370–9.
9. Eckert J, Conraths FJ, Tackmann K. Echinococcosis: an emerging or re-emerging zoonosis? *Int J Parasitol*. 2000;30:1283–94. [http://dx.doi.org/10.1016/S0020-7519\(00\)00130-2](http://dx.doi.org/10.1016/S0020-7519(00)00130-2)
10. Jenkins EJ, Schurer JM, Gesy KM. Old problems on a new playing field: helminth zoonoses transmitted among dogs, wildlife, and people in a changing northern climate. *Vet Parasitol*. 2011;182:54–69. <http://dx.doi.org/10.1016/j.vetpar.2011.07.015>

Address for correspondence: Emily J. Jenkins, Department of Veterinary Microbiology, University of Saskatchewan, 52 Campus Dr, Saskatoon, Saskatchewan S7N 5B4, Canada; email: emily.jenkins@usask.ca

Recognition and Diagnosis of *Cryptococcus gattii* Infections in the United States

To the Editor: An outbreak of *Cryptococcus gattii* cryptococcosis has been ongoing in the US Pacific Northwest (PNW) since 1999 (1–3). In contrast to *C. neoformans* infections, which typically cause meningitis in HIV-infected persons, outbreak-associated *C. gattii* infections occur primarily in persons without HIV and often cause pneumonia (1–3). Sporadic, nonoutbreak-associated *C. gattii* infections often cause meningitis and have been reported outside the PNW (1–4). The prevalence of both types of *C. gattii* infection in the United States is unknown because diagnostic practices and awareness vary among physicians.

Some reports indicate that patients with *C. gattii* infections may respond to treatment more slowly and relapse more frequently than patients with *C. neoformans* infections and, thus, may require more aggressive clinical management (5–8). Therefore, differentiation of *C. gattii* from *C. neoformans* infections may be necessary for optimal patient

management. However, cryptococcal infections are often diagnosed by antigen testing, which cannot distinguish between *C. gattii* and *C. neoformans*, and differential agar necessary to distinguish species in culture (9) is not uniformly used in clinical laboratories. In addition to possible missed diagnoses caused by the atypical manifestation of outbreak-associated *C. gattii*, outbreak-associated and sporadic *C. gattii* infections in the United States are likely being misdiagnosed as *C. neoformans* infections.

We conducted a survey of US infectious disease physicians to better understand the clinical approach to diagnosing cryptococcal infections, the relative regional frequency

of *C. gattii*, and the capacity of clinical laboratories to differentiate cryptococcal species. To survey physicians, we used the Emerging Infections Network (EIN), a sentinel public health surveillance system of infectious disease clinicians that is supported by the Centers for Disease Control and Prevention and sponsored by the Infectious Diseases Society of America (10). During February–March 2011, web-based surveys were distributed by email or fax to the 1,342 EIN members, of whom 792 (59%) responded.

Analysis was restricted to 286 (36%) respondents (representing 43 states) who treated a cryptococcosis patient during the past year. We compared answers from respondents

in the 4 US census regions (Table; online Appendix Figure, wwwnc.cdc.gov/EID/article/18/1/11-1228-FA1.htm). Results were analyzed by using SAS version 9.2 (SAS Institute Inc., Cary, NC).

The approximate number of reported physician consults for cryptococcosis was similar among respondents from all regions (Table). More respondents from the West (40%), compared with the South (21%), Midwest (22%), and Northeast (19%), reported that >25% of their cryptococcosis patients had pneumonia; this finding may reflect the higher prevalence of outbreak-associated *C. gattii* infections in the West (1–3). The percentage of respondents who treated

Table. Physician responses, by US region, to a survey about cryptococcosis, February–March 2011*

Question and responses	No. (%) responding physicians†				
	Overall, n = 286	Northeast, n = 48	Midwest, n = 63	South, n = 113	West, n = 62
No. patients with cryptococcosis seen during the past year					
1–4	218 (76)	41 (85)	55 (87)	71 (63)	51 (82)
5–8	49 (17)	6 (13)	7 (11)	29 (26)	7 (11)
9–12	12 (4)	1 (2)	1 (2)	8 (7)	3 (5)
>12	7 (2)	0	0	5 (4)	1 (2)
Percentage of patients with cryptococcal pneumonia, with or without meningitis					
0–25	213 (75)	39 (81)	49 (78)	89 (79)	36 (59)
26–50	33 (12)	1 (2)	6 (10)	13 (12)	13 (21)
51–75	8 (3)	1 (2)	1 (2)	4 (4)	2 (3)
76–100	31 (11)	7 (15)	7 (11)	7 (6)	10 (16)
Method used to obtain a diagnosis of cryptococcosis (all that apply)					
Cryptococcal antigen test	272 (95)	48 (100)	58 (92)	110 (97)	56 (90)
Microscopy	95 (33)	16 (33)	13 (21)	42 (37)	24 (39)
Culture	210 (73)	33 (69)	50 (79)	82 (73)	45 (73)
Histopathology	75 (26)	10 (21)	10 (16)	31 (27)	24 (39)
Any combination of tests that does not include culture	76 (27)	15 (31)	13 (21)	31 (27)	17 (27)
Clinical laboratory routinely or on request can differentiate <i>Cryptococcus neoformans</i> from <i>C. gattii</i> ‡	131 (66)	20 (67)	28 (68)	48 (64)	35 (66)
Percentage of cryptococcal infection cases in HIV-uninfected patients					
0–25	154 (54)	32 (68)	26 (41)	70 (62)	26 (44)
26–50	48 (17)	5 (11)	15 (24)	16 (14)	12 (20)
51–75	32 (11)	3 (6)	9 (14)	11 (10)	9 (15)
76–100	51 (18)	7 (15)	13 (21)	16 (14)	12 (20)
Diagnosed cryptococcal infections in HIV-uninfected patients with no known risk factors for infection during past 5 y	78 (27)	6 (13)	13 (21)	26 (23)	33 (53)
Considers species of <i>Cryptococcus</i> as a factor of interest in diagnosis or when treating a patient	179 (63)	22 (46)	36 (57)	71 (63)	50 (81)
Considered <i>C. gattii</i> infection as a differential diagnosis for pneumonia in a person from the US Pacific Northwest	153 (54)	19 (40)	29 (46)	63 (56)	42 (68)
Ever treated or consulted on a patient known to have <i>C. gattii</i> infection	38 (13)	5 (10)	3 (5)	3 (3)	27 (44)

*The survey was conducted by the Emerging Infections Network among physician members; responses are from providers who had seen any patients with cryptococcosis during the preceding year. Region is defined by the 4 census regions: Northeast (Connecticut, Maine, Massachusetts, New Hampshire, New Jersey, New York, Pennsylvania, Rhode Island, Vermont), Midwest (Indiana, Illinois, Iowa, Kansas, Michigan, Minnesota, Missouri, Nebraska, North Dakota, Ohio, South Dakota, Wisconsin), South (Alabama, Arkansas, Delaware, District of Columbia, Florida, Georgia, Kentucky, Louisiana, Maryland, Mississippi, North Carolina, Oklahoma, South Carolina, Tennessee, Texas, Virginia, West Virginia), West (Alaska, Arizona, California, Colorado, Hawaii, Idaho, Montana, New Mexico, Nevada, Oregon, Washington, Wyoming).

†Not all respondents answered all questions.

‡Excludes “don’t know” responses.

cryptococcosis patients without known risk factors for infection (including HIV) during the past 5 years was also higher in the West (53%) compared with other regions (Table).

Most (93%) respondents reported that they were aware of the *C. gattii* outbreak. However, only 63% of respondents consider *Cryptococcus* species a factor of interest during diagnosis or treatment, and 54% would consider *C. gattii* as a differential diagnosis for pneumonia in a patient from the PNW. Although awareness of *C. gattii* appears high, recognition of infection may be delayed when diagnostic plans do not include species identification.

Of the respondents, 94% reported that they most often use the cryptococcal antigen test for diagnosis, although 73% of respondents report that they commonly request a culture. Furthermore, 76 (27%) of respondents report using a combination of tests (cryptococcal antigen, microscopy, histopathology) that does not include culture. Tests that do not differentiate between cryptococcal species represent missed opportunities for diagnosis of *C. gattii* infections. When respondents were asked if their clinical laboratory could differentiate *C. neoformans* from *C. gattii* isolates, 131 (46%) responded "yes, either routinely or when requested"; 68 (24%) responded "no"; 87 (30%) did not know. When we excluded respondents who did not know, only 66% of respondents from the West indicated that their laboratory could differentiate species. This finding is concerning because outbreak-associated *C. gattii* is clearly endemic to the region. A better understanding of which laboratories perform this service and which send specimens to a reference laboratory will help identify where additional capacity is needed.

A lower percentage of respondents from the Northeast (10%), Midwest (5%), and South

(3%), compared with those from the West (44%), reported having ever consulted on a case of *C. gattii* infection. This may reflect a low incidence of *C. gattii* infections in these regions, or it may be a result of decreased clinical suspicion for *C. gattii* infections outside the PNW.

Results from this study suggest that although most EIN members are aware of *C. gattii* and the ongoing outbreak in the PNW, missed opportunities for diagnosis still exist. To understand the true incidence of *C. gattii* inside and outside the PNW, vigilance among physicians nationwide is necessary. Clinicians and laboratorians should be aware of the need to obtain specimens for culture and of the need to develop methods to differentiate cryptococcal species. An accurate diagnosis of cryptococcosis cases in the United States will lead to a better understanding of the epidemiology and incidence of *C. gattii* in this country and may result in improved treatment.

Acknowledgments

We thank Kevin Winthrop and James Hughes for their suggestions and feedback with regard to the survey creation and design.

This work was supported by grant/cooperative agreement number U50 CCU112346 from the Centers for Disease Control and Prevention.

**Sally Ann Iverson, Tom Chiller,
Susan Beekmann,
Philip M. Polgreen,
and Julie Harris**

Author affiliations: Johns Hopkins Bloomberg School of Public Health, Baltimore, Maryland, USA (S.A. Iverson); Centers for Disease Control and Prevention, Atlanta, Georgia, USA (T. Chiller, J. Harris); and University of Iowa Carver College of Medicine, Iowa City, Iowa, USA (S. Beekmann, P.M. Polgreen)

DOI: <http://dx.doi.org/10.3201/eid1806.111228>

References

- Centers for Disease Control and Prevention. Emergence of *Cryptococcus gattii*—Pacific Northwest, 2004–2010. *MMWR Morb Mortal Wkly Rep*. 2010;59:865–8.
- Harris JR, Lockhart SR, Debesse E, Marsden-Haug N, Goldoft M, Wohrle R, et al. *Cryptococcus gattii* in the United States: clinical aspects of infection with an emerging pathogen. *Clin Infect Dis*. 2011;53:1188–95. <http://dx.doi.org/10.1093/cid/cir723>
- MacDougall L, Kidd SE, Galanis E, Mak S, Leslie MJ, Cieslak PR, et al. Spread of *Cryptococcus gattii* in British Columbia, Canada, and detection in the Pacific Northwest, USA. *Emerg Infect Dis*. 2007;13:42–50. <http://dx.doi.org/10.3201/eid1301.060827>
- Galanis E, MacDougall L. Epidemiology of *Cryptococcus gattii*, British Columbia, Canada, 1999–2007. *Emerg Infect Dis*. 2010;16:251–7.
- Speed B, Dunt D. Clinical and host differences between infections with the two varieties of *Cryptococcus neoformans*. *Clin Infect Dis*. 1995;21:28–34, discussion 5–6. <http://dx.doi.org/10.1093/clinids/21.1.28>
- Chen S, Sorrell T, Nimmo G, Speed B, Currie B, Ellis D, et al. Epidemiology and host- and variety-dependent characteristics of infection due to *Cryptococcus neoformans* in Australia and New Zealand. Australasian Cryptococcal Study Group. *Clin Infect Dis*. 2000;31:499–508. <http://dx.doi.org/10.1086/313992>
- Perfect JR, Dismukes WE, Dromer F, Goldman DL, Graybill JR, Hamill RJ, et al. Clinical Practice guidelines for the management of cryptococcal disease: 2010 update by the Infectious Diseases Society of America. *Clin Infect Dis*. 2010;50:291–322. <http://dx.doi.org/10.1086/649858>
- Galanis E, Hoang L, Kibsey P, Morshed M, Phillips P. Clinical presentation, diagnosis and management of *Cryptococcus gattii* cases: Lessons learned from British Columbia. *Can J Infect Dis Med Microbiol*. 2009;20:23–8.
- Klein KR, Hall L, Deml SM, Rysavy JM, Wohlfiel SL, Wengenack NL. Identification of *Cryptococcus gattii* by use of L-canavanine glycine bromothymol blue medium and DNA sequencing. *J Clin Microbiol*. 2009;47:3669–72. <http://dx.doi.org/10.1128/JCM.01072-09>
- Executive committee of the Infectious Diseases Society of America Emerging Infections Network. The emerging infections network: a new venture for the Infectious Diseases Society of America. Executive Committee of the Infectious Diseases Society of America Emerging Infections Network. *Clin Infect Dis*. 1997;25:34–6.

Address for correspondence: Sally Ann Iverson, Johns Hopkins Bloomberg School of Public Health, 615 N. Wolfe St, Baltimore, MD 21205, USA; email: siverson@jhsph.edu

Coccidioidal Endophthalmitis in Immunocompetent Person, California, USA

To the Editor: In the United States, dimorphic fungi of the species *Coccidioides* are endemic to California (particularly the Central Valley), southern Arizona, southern New Mexico, and western Texas. Although there are a relatively large number of coccidioidomycosis cases in the United States ($\approx 150,000$ /year), intraocular coccidioidomycosis is uncommon (1,2). We report a case of coccidioidal endophthalmitis in an immunocompetent person.

In October 2010, a 55-year-old white man in Santa Clarita, California, had severe pneumonia, drenching sweats, and an associated 25-pound weight loss. Three weeks later, when his symptoms had nearly resolved, the man reported having scratched his left eye with his eyeglasses and subsequent development of increasing redness, pain, and progressive vision loss (from 20/10 to 20/60 without correction).

In November 2010, the man sought the care of an ophthalmologist, who noted panuveitis of the left eye. Laboratory testing was performed: the erythrocyte sedimentation rate was 49 mm/h (reference 0–22 mm/h), and test results were negative for human leukocyte antigen B27, angiotensin-converting enzyme, rapid plasma reagin, and antinuclear antibody.

The patient was started on topical corticosteroids and escalated to high-dose prednisone soon thereafter without improvement. Pain continued to increase in his left eye, and visual acuity declined to hand motion only.

Thus, in February 2011, the patient was referred to our institution, where an ocular ultrasound showed vitreous opacities (Figure). He underwent vitrectomy with intravitreal injection of empiric antimicrobial drugs, including voriconazole. Aqueous fluid obtained intraoperatively grew mold, and the patient was admitted to the hospital for systemic antifungal therapy.

The patient's history was unremarkable except for avid mountain biking in the Central Valley of California. His physical examination was notable for left visual acuity limited to hand motion only, limited extraocular movement, conjunctival injection, and hypopyon. His HIV test result was negative. Computed tomography (CT) scanning of the chest showed micronodules in the right upper lobe, suggesting previous pulmonary coccidioidal infection. Intravenous voriconazole (4 mg/kg every 12 hours) was administered along with daily intravitreal

injections of voriconazole while the patient was hospitalized. Results for coccidioidal antibody testing were positive by enzyme immunoassay and immunodiffusion but negative by serum complement fixation. Nucleic acid hybridization testing of aqueous fluid cultures identified *Coccidioides* spp. Results of a CT brain scan, lumbar puncture, and bone scan were normal.

After 1 week of hospitalization, the patient was discharged on oral voriconazole (4 mg/kg 2 \times /day). Because of transaminitis, the patient was transitioned to fluconazole (800 mg/day) 4 weeks later. He underwent 13 subsequent intravitreal injections of amphotericin and voriconazole. Eleven months after discharge, the patient's best-corrected visual acuity was 20/25, and his ocular media were clear and without any lesions.

Coccidioidomycosis often goes undetected because up to 60% of affected patients are asymptomatic (3). When signs and symptoms are present, they vary from subclinical infection to acute pneumonia to disseminated disease (3). The rate of extrapulmonary complications is estimated at 0.5% of infections in white persons, but such complications may occur in


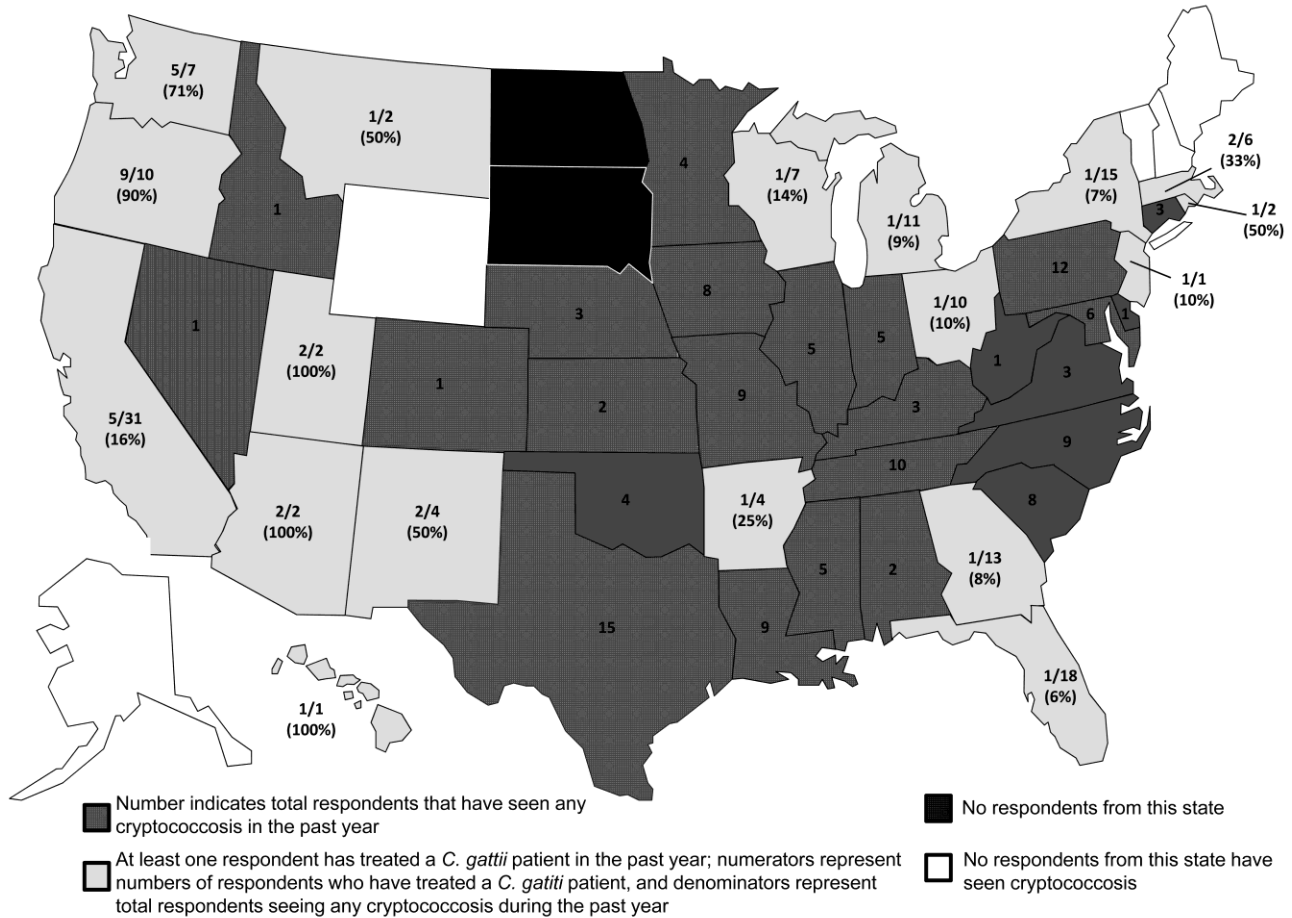


Figure. Ocular ultrasound demonstrating hyperechoic, punctate opacities (arrows) within the vitreous chamber (X) of a patient with coccidioidomycosis, California, USA.

Recognition and Diagnosis of *Cryptococcus gattii* Infections in the United States

Technical Appendix



Technical Appendix Figure. Distribution of survey respondents who have seen any patient(s) with cryptococcosis during the past year and who have ever treated a patient with *Cryptococcus gattii* infection, Emerging Infections Network survey, March–February 2011.