

***Mycobacterium obuense* Bacteremia in a Patient with Pneumonia**

**Bruno Ali López Luis, Paulette Díaz-Lomelí,
Livier Patricia Gómez-Albarrán,
Areli Martínez-Gamboa, Alfredo Ponce-de-León**

Author affiliation: Instituto Nacional de Ciencias Médicas
y Nutrición Salvador Zubirán, Mexico City, Mexico

DOI: <https://doi.org/10.3201/eid2505.180208>

Mycobacterium obuense is a pigmented, rapidly growing mycobacterium. Because it has been considered nonpathogenic, *M. obuense* is being investigated in clinical trials of cancer immunotherapy and bioremediation. We report a case of bacteremia caused by *M. obuense* in a patient with pneumonia, showing its potential pathogenicity.

Approximately 75 species of rapidly growing mycobacteria (RGM) have been isolated from soil, animals, and water (1). The RGM *Mycobacterium obuense*, an environmental pigmented mycobacterium, is mobile and easily adaptable to the environment and possesses oxygenases that enable it to degrade organic compounds and dechlorinate methoxychlor-based insecticides (2). Until recently, *M. obuense* has been considered nonpathogenic. We report a case of bacteremia caused by *M. obuense*.

A 29-year-old man from a rural community in Puebla, Mexico, arrived at an emergency department in Mexico City reporting a 2-day history of chest pain, dyspnea, and fever. On physical examination, his heart rate was 94 bpm, blood pressure 175/88 mm Hg, temperature 38.5°C, and peripheral oxygen saturation 70%. Chest auscultation revealed bibasilar fine crackles and signs of pleural effusion.

The patient was a farmer; had been in close contact with pigs, sheep, and cows; and reported consuming unpasteurized dairy products. He had a history of diabetes mellitus with chronic kidney disease categorized as stage G4 A3 (glomerular filtration rate 16.7 mL/min/1.73 m²; proteinuria >2.8 g/d) of the KDIGO classification (Kidney Disease: Improving Global Outcomes, <https://kdigo.org>) without replacement therapy. He reported taking metformin, amlodipine, furosemide, and iron sulfate.

At admission, laboratory test results included leukocyte count, 11,900 cells/μL with 88.2% neutrophils; C-reactive protein, 250 mg/L; procalcitonin, 17 ng/mL; creatinine, 4.0 mg/dL; and arterial blood gases, pH 7.24, pO₂ 40.8 mm Hg, pCO₂ 34.8 mm Hg, lactate 2.9 mmol/L, HCO₃ 14.6 mmol/L, and sO₂ 71% on ambient air. Findings of a

computed tomography scan of the chest suggested that the patient had a lung infection (Figure).

The patient began empirical treatment for community-acquired pneumonia with ceftriaxone and clarithromycin. No respiratory samples were obtained because the patient was unable to produce sputum. We performed blood cultures in Aerobic/F medium (Becton Dickinson, <https://www.bd.com>). After a 7-day incubation period, we detected growth and observed gram-positive bacilli in the gram stain (Appendix Figure, panel A, <http://wwwnc.cdc.gov/EID/article/25/5/18-0208-App1.pdf>). We made subcultures on sheep blood, chocolate, and Sabouraud agar and performed Kinyoun and Ziehl-Neelsen stains, in which we observed partially acidic alcohol-resistant coccobacilli (Appendix Figure, panels B,C). After 2 weeks of incubation at 35°–37°C, we observed rough, mucoid colonies (Appendix Figure, panels D,E).

We attempted to identify the bacilli by using GenoType Mycobacterium (Hain Lifescience, <https://www.hain-lifescience.de>) but were unsuccessful because no species-specific probe is available. We performed amplification and sequencing of the 16S rRNA gene (498 bp) and *hsp65* gene (400 bp). Pairwise sequence aligned 100% with 16S rRNA and 99.6% with *hsp65* to the sequences of *M. obuense* strain CIP 106803 (GenBank accession no. AF547954.1).

The patient was started on intravenous amikacin, clarithromycin, and moxifloxacin as soon as we notified clinicians of RGM isolated from his blood cultures. We conducted susceptibility testing by broth microdilution, which showed susceptibility to all antimicrobial drugs tested except tobramycin (intermediate susceptibility) (Appendix) (3).

The patient completed 2 weeks of intravenous moxifloxacin, amikacin, and clarithromycin and was discharged. He received 4 additional weeks of oral azithromycin and moxifloxacin and experienced complete resolution.

M. obuense, first described as a scotochromogenic RGM species isolated primarily from soil >40 years ago in Obu, Japan, is a catalase-positive, peroxidase-negative bacillus that can degrade salicylates, forming a black product (4,5). In culture, *M. obuense* has 2 morphotypes, smooth and rough variants. In the smooth variants, its cell wall contains long-chain saturated fatty acids that enable it to colonize the environment and are responsible for the pleomorphism observed on the surface of solid agars (6). Although this species was later isolated from sputum samples from patients with apparent pulmonary disease, no additional clinical data were reported, and thus, no evidence of pathogenicity was established (4,7).

Phylogenetic analysis of *M. obuense* shows close association with *M. chubuense* (81.3% identity) and *M. rufum* (92.2% identity) (7). Its genome consists of 5,576,960 bp

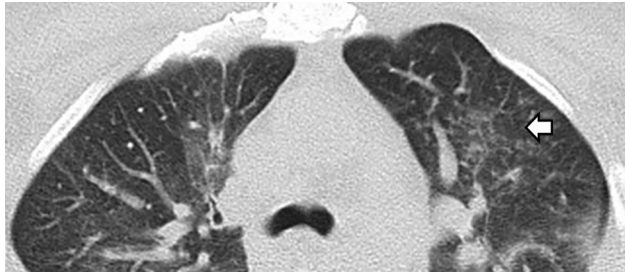


Figure. Computed tomography scan of the chest in a patient with *Mycobacterium obuense* pneumonia, Mexico, showing air space infiltration in the left parahilar and a tree bud pattern in the left upper lobe (arrow), as well as bilateral interstitial thickening and ground glass opacities.

(of which 133,713 bp are of plasmid origin with 68% GC content) and 800 unique genes, more than related species, such as *M. chubuense*. Although these mycobacteria are considered nonpathogenic, they have homologous genes to mammalian cell entry that encode proteins involved in virulence and cell invasion. In addition, *M. obuense* contains genes involved in antimicrobial resistance, such as *marA*, aminoglycoside-resistance protein kinase, β -lactamases, and monooxygenases, which confer *M. obuense* with intrinsic rifampin resistance (2,7).

Establishing etiology in this case was challenging because current nucleic acid probe assays cannot identify *M. obuense* correctly. Clinicians should avoid discarding RGM or misclassifying these isolates as colonizers until definitive species identification confirms etiology.

M. obuense has been evaluated as an adjuvant immunotherapy in phase I and II trials on patients with melanoma, pancreatic cancer, and colorectal cancer, with promising results. This treatment consists of an intradermal application of a suspension of heat-killed whole cell *M. obuense* (8–10).

The isolation of *M. obuense* from blood cultures of a patient with community-acquired pneumonia suggests its capacity for virulence and invasiveness in humans. Because *M. obuense* might become an adjuvant in cancer therapy, researchers should ensure implementation of proper, standardized inactivation protocols.

About the Author

Dr. Luis is a fellow in infectious diseases and Dr. Ponce-de-Leon is a senior researcher at the National Institute of Medical Science and Nutrition Salvador Zubiran, Mexico City. Their research fields are mycobacterial diseases and clinical microbiology.

References

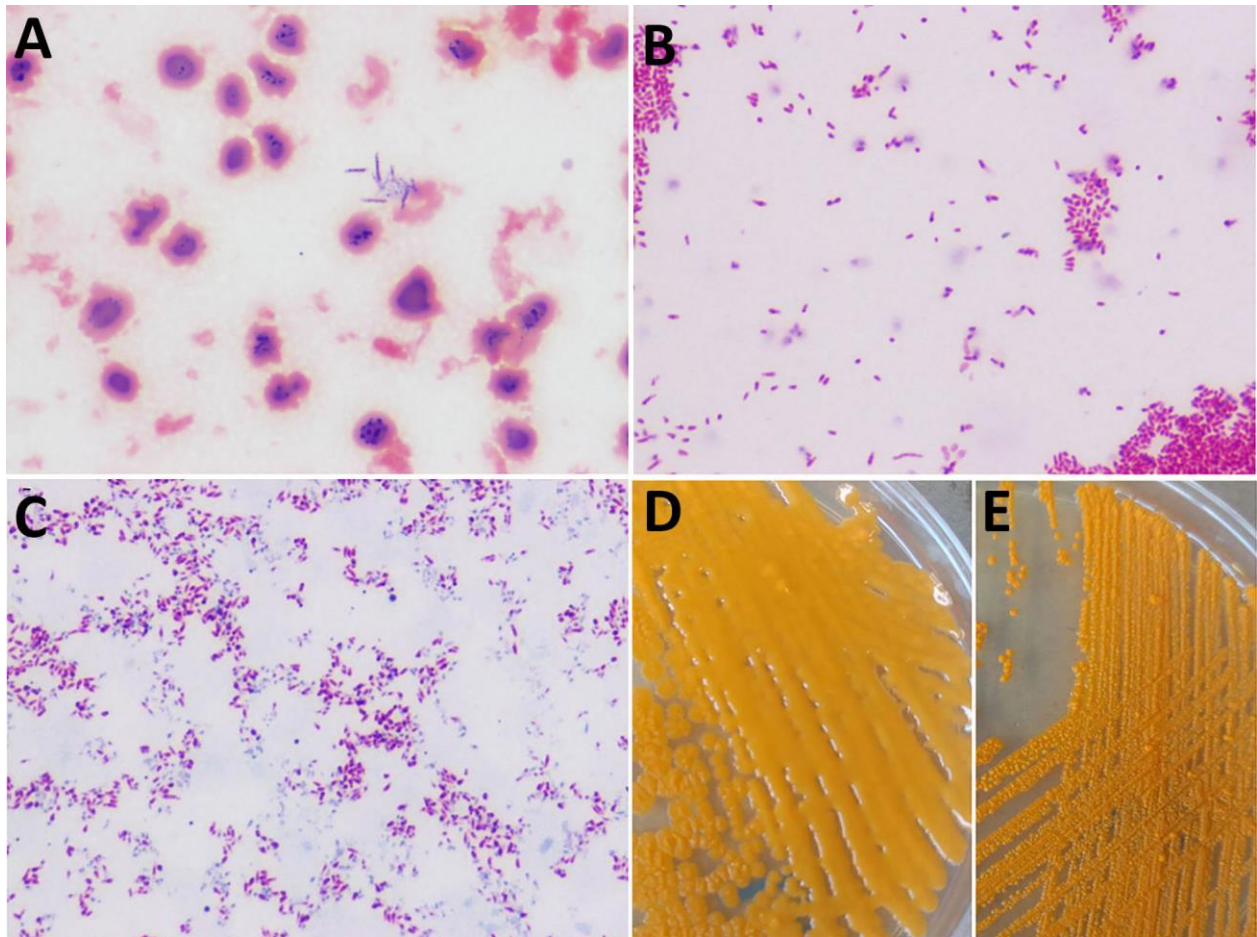
1. Brown-Elliott BA, Philley JV. Rapidly growing mycobacteria. *Microbiol Spectr*. 2017;5. <http://dx.doi.org/10.1128/microbiolspec.TNMI7-0027-2016>
2. Das S, Pettersson BM, Behra PR, Ramesh M, Dasgupta S, Bhattacharya A, et al. Characterization of three *Mycobacterium* spp. with potential use in bioremediation by genome sequencing and comparative genomics. *Genome Biol Evol*. 2015;7:1871–86. <http://dx.doi.org/10.1093/gbe/evv111>
3. Clinical and Laboratory Standards Institute. Susceptibility testing of *Mycobacteria*, *Nocardiae*, and other aerobic actinomycetes. Approved standard. 2nd edition. Document M24–A2. Wayne (PA): The Institute; 2011.
4. Tsukamura M, Mizuno S. *Mycobacterium obuense*, a rapidly growing scotochromogenic mycobacterium capable of forming a black product from *p*-aminosalicylate and salicylate. *J Gen Microbiol*. 1971;68:129–34. <http://dx.doi.org/10.1099/00221287-68-2-129>
5. Tsukamura M, Mizuno S, Tsukamura S. Numerical analysis of rapidly growing scotochromogenic mycobacteria, including *Mycobacterium obuense* sp. nov., nom. rev., *Mycobacterium rhodesiae* sp. nov., nom. rev., *Mycobacterium aichiense* sp. nov., nom. rev., *Mycobacterium chubuense* sp. nov., nom. rev., and *Mycobacterium tokaiense* sp. nov., nom. rev. *Int J Syst Bacteriol*. 1981;31:263–75. <http://dx.doi.org/10.1099/00207713-31-3-263>
6. Agustí G, Astola O, Rodríguez-Güell E, Julián E, Luquin M. Surface spreading motility shown by a group of phylogenetically related, rapidly growing pigmented mycobacteria suggests that motility is a common property of mycobacterial species but is restricted to smooth colonies. *J Bacteriol*. 2008;190:6894–902. <http://dx.doi.org/10.1128/JB.00572-08>
7. Greninger AL, Cunningham G, Hsu ED, Yu JM, Chiu CY, Miller S. Draft genome sequence of *Mycobacterium obuense* strain UC1, isolated from patient sputum. *Genome Announc*. 2015;3:e00612-15. <http://dx.doi.org/10.1128/genomeA.00612-15>
8. Fowler D, Dalgleish A, Liu W. A heat-killed preparation of *Mycobacterium obuense* can reduce metastatic burden in vivo. *J Immunother Cancer*. 2014;2(Suppl 3):P54. <http://dx.doi.org/10.1186/2051-1426-2-S3-P54>
9. Stebbing J, Dalgleish A, Gifford-Moore A, Martin A, Gleeson C, Wilson G, et al. An intra-patient placebo-controlled phase I trial to evaluate the safety and tolerability of intradermal IMM-101 in melanoma. *Ann Oncol*. 2012;23:1314–9. <http://dx.doi.org/10.1093/annonc/mdr363>
10. Costa Neves M, Giakoustidis A, Stamp G, Gaya A, Mudan S. Extended survival after complete pathological response in metastatic pancreatic ductal adenocarcinoma following induction chemotherapy, chemoradiotherapy, and a novel immunotherapy agent, IMM-101. *Cureus*. 2015;7:e435.

Address for correspondence: Alfredo Ponce-de-León, Laboratory of Clinical Microbiology, Department of Infectious Diseases, Instituto Nacional de Ciencias Médicas y Nutrición Salvador Zubirán, Avenida Vasco de Quiroga No.15, Colonia Belisario Domínguez Sección XVI, Delegación Tlalpan, 14080, Mexico City, Mexico; email: alf.poncedeleon@gmail.com

Mycobacterium obuense Bacteremia in a Patient with Pneumonia

Appendix

We conducted susceptibility testing on the bacilli by broth microdilution, which showed MICs to amikacin, 0.25 µg/mL; clarithromycin, ≤0.03 µg/mL; ciprofloxacin, 0.03 µg/mL; doxycycline, 0.5 µg/mL; imipenem, 2 µg/mL; linezolid, 0.5 µg/mL; moxifloxacin, ≤0.015 µg/mL; tobramycin, 4 µg/mL; and trimethoprim/sulfamethoxazole, 0.25/4.8 µg/mL. According to Clinical Laboratory Standards Institute guidelines (3), all antimicrobial drugs tested were susceptible except tobramycin, which was intermediate.



Appendix Figure. A) Gram stain from positive blood culture showing gram-positive bacilli. Original magnification $\times 100$. B) Kinyoun stain from sheep blood agar with red coccobacilli, some in clusters. Original magnification $\times 100$. C) Ziehl Neelsen stain from sheep blood agar showing partially acid-fast stained coccobacilli. Original magnification $\times 100$. D) *Mycobacterium obuense* on Sabouraud agar showing mucoid and smooth colonies with yellow pigmentation. E) *M. obuense* after several passages showing smaller, dry and rough colonies.