

About the Author

Mr. Loyola is a researcher in the Genomics & Pathogen Discovery Unit at the US Naval Medical Research Unit No. 6, in Lima, Peru. His primary research interest is the characterization of new and emerging pathogens.

References

- Jiang J, Maina AN, Knobel DL, Cleaveland S, Laudisoit A, Wamburu K, et al. Molecular detection of *Rickettsia felis* and *Candidatus Rickettsia asemboensis* in fleas from human habitats, Asembo, Kenya. *Vector Borne Zoonotic Dis.* 2013;13:550–8. <http://dx.doi.org/10.1089/vbz.2012.1123>
- Maina AN, Luce-Fedrow A, Omulo S, Hang J, Chan TC, Ade F, et al. Isolation and characterization of a novel *Rickettsia* species (*Rickettsia asembonensis* sp. nov.) obtained from cat fleas (*Ctenocephalides felis*). *Int J Syst Evol Microbiol.* 2016;66:4512–7. <http://dx.doi.org/10.1099/ijsem.0.001382>
- Pérez-Osorio CE, Zavala-Velázquez JE, Arias-León JJ, Zavala-Castro JE. *Rickettsia felis* as emergent global threat for humans. *Emerg Infect Dis.* 2008;14:1019–23. <http://dx.doi.org/10.3201/eid1407.071656>
- Maina AN, Fogarty C, Krueger L, Macaluso KR, Odhiambo A, Nguyen K, et al. Rickettsial infections among *Ctenocephalides felis* and host animals during a flea-borne rickettsioses outbreak in Orange County, California. *PLoS One.* 2016;11:e0160604. <http://dx.doi.org/10.1371/journal.pone.0160604>
- Troyo A, Moreira-Soto RD, Calderon-Arguedas Ó, Mata-Somarrivas C, Ortiz-Tello J, Barbieri AR, et al. Detection of rickettsiae in fleas and ticks from areas of Costa Rica with history of spotted fever group rickettsioses. *Ticks Tick Borne Dis.* 2016;7:1128–34. <http://dx.doi.org/10.1016/j.ttbdis.2016.08.009>
- Kolo AO, Sibeko-Matjila KP, Maina AN, Richards AL, Knobel DL, Matjila PT. Molecular detection of zoonotic *Rickettsiae* and *Anaplasma* spp. in domestic dogs and their ectoparasites in Bushbuckridge, South Africa. *Vector Borne Zoonotic Dis.* 2016;16:245–52. <http://dx.doi.org/10.1089/vbz.2015.1849>
- Oteo JA, Portillo A, Portero F, Zavala-Castro J, Venzal JM, Labruna MB. ‘*Candidatus Rickettsia asemboensis*’ and *Wolbachia* spp. in *Ctenocephalides felis* and *Pulex irritans* fleas removed from dogs in Ecuador. *Parasit Vectors.* 2014;7:455.
- Forshey BM, Stewart A, Morrison AC, Gálvez H, Rocha C, Astete H, et al. Epidemiology of spotted fever group and typhus group rickettsial infection in the Amazon basin of Peru. *Am J Trop Med Hyg.* 2010;82:683–90. <http://dx.doi.org/10.4269/ajtmh.2010.09-0355>
- Kocher C, Morrison AC, Leguia M, Loyola S, Castillo RM, Galvez HA, et al. Rickettsial disease in the Peruvian Amazon basin. *PLoS Negl Trop Dis.* 2016;10:e0004843. <http://dx.doi.org/10.1371/journal.pntd.0004843>
- Jima DD, Luce-Fedrow A, Yang Y, Maina AN, Sniesrud EC, Otiang E, et al. Whole-genome sequence of “*Candidatus Rickettsia asemboensis*” strain NMRCii, isolated from fleas of western Kenya. *Genome Announc.* 2015;3:e00018–15. <http://dx.doi.org/10.1128/genomeA.00018-15>

Address for correspondence: Mariana Leguia, Pontificia Universidad Católica del Perú, Av. Universitaria No. 1801, San Miguel, Lima, Perú; email: mariana.leguia@pucep.edu.pe

Spontaneous Abortion Associated with Zika Virus Infection and Persistent Viremia

Anna Goncé, Miguel J. Martínez, Elena Marbán-Castro, Adela Saco, Anna Soler, María Isabel Alvarez-Mora, Aida Peiro, Verónica Gonzalo, Gillian Hale, Julu Bhatnagar, Marta López, Sherif Zaki, Jaume Ordi, Azucena Bardají

Author affiliations: BCNatal–Barcelona Center of Maternal-Fetal and Neonatal Medicine, Barcelona, Spain (A. Goncé, M. López); ISGlobal, Hospital Clínic–Universitat de Barcelona, Barcelona (M.J. Martínez, E. Marbán-Castro, J. Ordi, A. Bardají); Hospital Clínic, Barcelona (M.J. Martínez, A. Saco, A. Peiro, V. Gonzalo, J. Ordi); Hospital Clínic, IDIBAPS and CIBERER, Barcelona (A. Soler, M.I. Alvarez-Mora); Centers for Disease Control and Prevention, Atlanta, Georgia, USA (G. Hale, J. Bhatnagar, S. Zaki)

DOI: <https://doi.org/10.3201/eid2405.171479>

We report a case of spontaneous abortion associated with Zika virus infection in a pregnant woman who traveled from Spain to the Dominican Republic and developed a rash. Maternal Zika viremia persisted at least 31 days after onset of symptoms and 21 days after uterine evacuation.

Evidence regarding the association of Zika virus infection and pregnancy loss (spontaneous abortions and stillbirths) has been reported recently (1). Zika virus has been detected by reverse transcription PCR (RT-PCR) in brain tissue samples from stillborn infants and from placental tissue obtained from pregnancy losses (2,3). We report a case of early pregnancy loss associated with Zika virus with evidence of persistent maternal viremia after uterine evacuation.

In mid-June 2016, a 22-year-old woman, who was in the seventh week of gestation, traveled from Spain to the Dominican Republic. Fifteen days after her arrival, she developed a mild macular rash and malaise that resolved after 3 days (Figure). One day after her return to Spain (at 10.5 weeks of pregnancy and 9 days after the onset of symptoms), a routine first-trimester prenatal scan showed an embryo without cardiac activity and a crown–rump length of 19 mm, compatible with a pregnancy loss at an estimated gestational age of 8 weeks and 4 days (Figure). On July 5, 2016, a maternal serum sample tested positive for Zika virus by a commercial real-time RT-PCR with a cycle threshold (C_t) value of 33, and a urine sample was

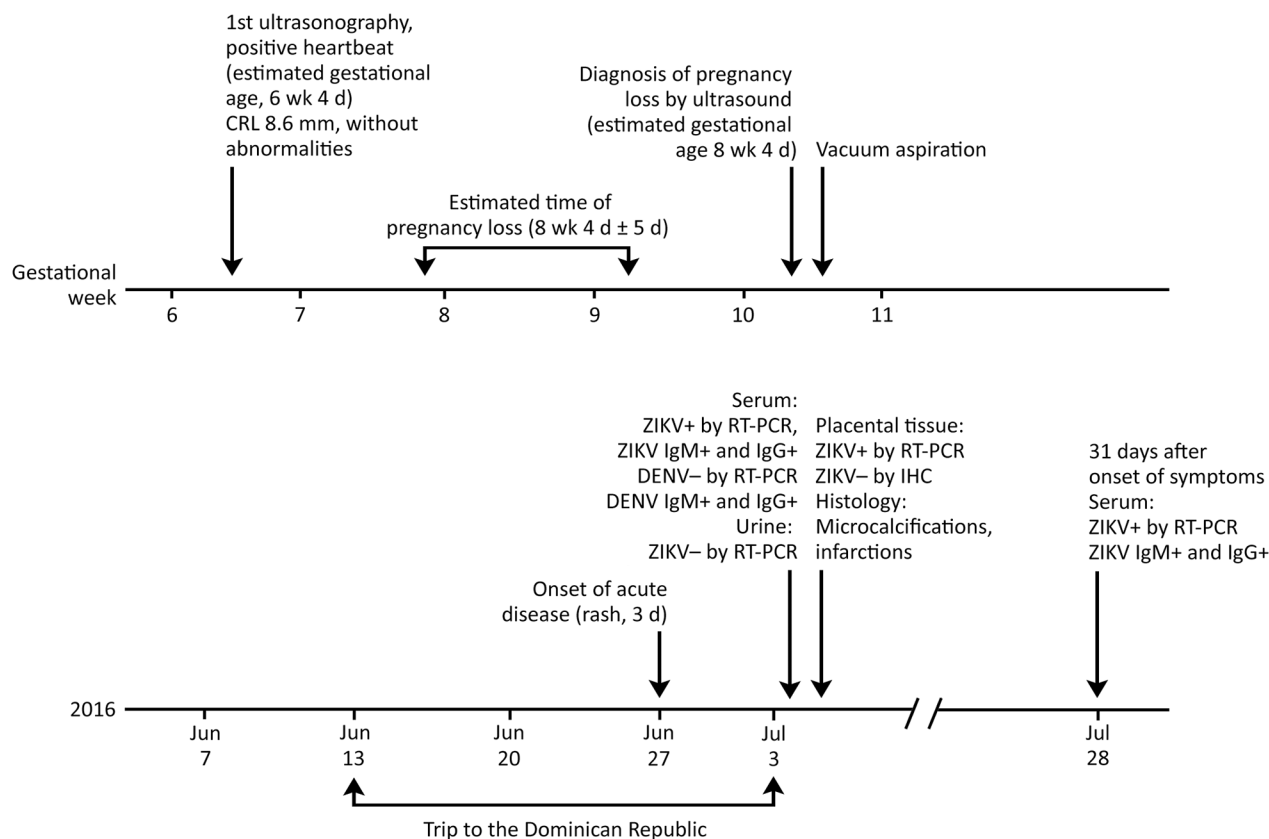


Figure. Clinical timeline for a 22-year-old pregnant woman who had suspected Zika virus infection. The woman was in the seventh week of gestation when she traveled from Spain to the Dominican Republic. CRL, crown-rump length; DENV, dengue virus; Ig, immunoglobulin; IHC, immunohistochemistry; ZIKV, Zika virus; RT-PCR, reverse transcription PCR; +, positive; -, negative.

negative by real time RT-PCR (details on laboratory testing in online Technical Appendix, <https://wwwnc.cdc.gov/EID/article/24/5/17-1479-Techapp1.pdf>). We detected Zika virus IgM and IgG by a commercial immunofluorescence assay (see online Technical Appendix).

The patient was offered a chorionic villi sampling; the genetic analysis was normal. Surgical evacuation of the uterus was performed by vacuum aspiration followed by curettage. We detected Zika virus by real time RT-PCR in both the transport medium in which the chorionic biopsy was stored ($C_t = 36$) and the supernatant of the karyotype cell culture ($C_t = 12$). Differences in real-time PCR C_t values can be explained by active viral replication in the karyotype cell culture. We used the supernatant of the karyotype cell culture to inoculate Vero cells, where we observed a cytopathic effect. We confirmed virus isolation by subsequent infection of new Vero cells, RT-PCR analysis, and sequencing of the Zika virus envelope gene. This analysis suggested active Zika virus replication in embryonic cells. We also detected Zika virus by real time RT-PCR in fresh placental tissue samples from vacuum aspiration (online Technical Appendix).

Formalin-fixed paraffin-embedded placental tissues were also analyzed at the Centers for Disease Control and

Prevention (CDC; Atlanta, GA, USA). Histopathological analyses of these placental tissues revealed perivillous fibrinoid deposition, focal coarse calcifications, and moderate increase of Hofbauer cells. The histological sections of the placental tissue, which were stained with hematoxylin and eosin, showed a focus of villous necrosis associated with calcifications. A small portion of embryonic membranes was visible, showing no noteworthy inflammatory infiltrate. Immunohistochemical testing on placental tissue did not show presence of Zika virus-specific immunostaining. The histological findings were not relevant to the diagnosis. No specific changes were observed, neither associated inflammation was identified, and only nonspecific mild abnormalities were present. Nevertheless, Zika virus RT-PCR assays and sequencing performed on RNA extracted from placental tissues identified the presence of Zika virus in the sample (4). On July 6, 21 days after vacuum aspiration and 31 days after the onset of symptoms, we detected Zika virus in maternal serum samples using RT-PCR ($C_t = 37$).

Our investigation found evidence of Zika virus infection in tissue samples from an early pregnancy loss in a mother infected with Zika virus in the first trimester of pregnancy.

Testing of tissues from vacuum aspiration and from chorionic villi sampling revealed that placenta and chorion contained Zika virus RNA. Isolation of Zika virus from the karyotype cell culture confirmed active viral replication in embryonic cells. All the tests performed suggest that the spontaneous abortion in this woman was likely associated with a symptomatic Zika virus infection occurring early in pregnancy. These findings provide further evidence of the association between Zika virus infection early in pregnancy and transplacental infection, as well as embryonic damage, leading to poor pregnancy outcomes (2). Given that embryo loss had probably occurred days before maternal-related symptoms, we hypothesize that spontaneous abortion happened early during maternal viremia. The prolonged viremia in the mother beyond the first week after symptom onset concurs with other recent reports (1,5). However, persistent viremia 3 weeks after pregnancy outcome has not been described previously and underscores the current lack of knowledge regarding the persistence of Zika virus infection. Because we identified Zika virus RNA in placental tissues, our findings reinforce the evidence for early gestational placental tissue as the preferred target for viral tropism (2,4). Finally, although laboratory tests were performed to dismiss other maternal infections (see online Technical Appendix), the attribution of Zika virus as the cause of the spontaneous abortion must be interpreted with caution, because a non-Zika-related etiology cannot be entirely ruled out. Further studies are warranted to investigate the natural history of Zika virus infection in pregnant women.

This work was funded by grant no. PI16/0123. ISCIII-AES-Proyectos de Investigación en Salud, 2016, Government of Spain.

About the Author

Dr. Gonc  is an associate professor of obstetrics and gynecology at Hospital Cl nic, University of Barcelona, Spain. Her main research focus is perinatal infections, including Zika virus.

References

- van der Eijk AA, van Genderen PJ, Verdijk RM, Reusken CB, M gling R, van Kampen JJ, et al. Miscarriage associated with Zika virus infection. *N Engl J Med*. 2016;375:1002–4. <http://dx.doi.org/10.1056/NEJMc1605898>
- Martines RB, Bhatnagar J, de Oliveira Ramos AM, Davi HP, Iglezias SD, Kanamura CT, et al. Pathology of congenital Zika syndrome in Brazil: a case series. *Lancet*. 2016;388:898–904. [http://dx.doi.org/10.1016/S0140-6736\(16\)30883-2](http://dx.doi.org/10.1016/S0140-6736(16)30883-2)
- Schaub B, Monthieux A, Najioullah F, Harte C, C saire R, Jolivet E, et al. Late miscarriage: another Zika concern? *Eur J Obstet Gynecol Reprod Biol*. 2016;207:240–1. <http://dx.doi.org/10.1016/j.ejogrb.2016.10.041>
- Bhatnagar J, Rabeneck DB, Martines RB, Reagan-Steiner S, Ermias Y, Estetter LB, et al. Zika virus RNA replication and persistence in brain and placental tissue. *Emerg Infect Dis*. 2017;23:405–14. <http://dx.doi.org/10.3201/eid2303.161499>
- Driggers RW, Ho CY, Korhonen EM, Kuivanen S, J askel inen AJ, Smura T, et al. Zika virus infection with prolonged maternal viremia and fetal brain abnormalities. *N Engl J Med*. 2016;374:2142–51. <http://dx.doi.org/10.1056/NEJMoal601824>

Address for correspondence: Azucena Bardaj , ISGlobal, Hospital Cl nic, Universitat de Barcelona, Rossell , 132, 5-1, 08036 Barcelona, Spain; email: azucena.bardaji@isglobal.org

Isolation of Oropouche Virus from Febrile Patient, Ecuador

Emma L. Wise, Steven T. Pullan, Sully M rquez, Ver nica Paz, Juan D. Mosquera, Sonia Zapata, Simon K. Jackson, Gyorgy Fejer, Gabriel Trueba, Christopher H. Logue

Author affiliations: Public Health England, Salisbury, UK (E.L. Wise, S.T. Pullan, C.H. Logue); Plymouth University, Plymouth, UK (E.L. Wise, S.K. Jackson, G. Fejer, C.H. Logue); Microbiology Institute, Universidad San Francisco de Quito, Quito, Ecuador (S. M rquez, J.D. Mosquera, S. Zapata, G. Trueba, C.H. Logue); Hospital Delfina Torres de Concha, Esmeraldas, Ecuador (V. Paz)

DOI: <https://doi.org/10.3201/eid2405.171569>

We report identification of an Oropouche virus strain in a febrile patient from Ecuador by using metagenomic sequencing and real-time reverse transcription PCR. Virus was isolated from patient serum by using Vero cells. Phylogenetic analysis of the whole-genome sequence showed the virus to be similar to a strain from Peru.

Oropouche virus (OROV) is a negative-sense, single-stranded RNA virus (family *Bunyaviridae*, genus *Orthobunyaviridae*) with a tripartite genome consisting of large (L), medium (M), and small (S) segments. OROV causes a self-limiting acute febrile illness, Oropouche fever (1). Since its discovery in Trinidad in 1955 (2), >30 outbreaks of OROV have been reported from Brazil, Panama, and Peru, demonstrating the ability of this midgeborne virus to cause epidemics. Approximately 500,000 cases of Oropouche fever have been reported, making OROV one of the most clinically significant orthobunyaviruses (1). Two previous studies reported unconfirmed infections in Ecuador by using

Spontaneous Abortion Associated with Zika Virus Infection and Persistent Viremia after Uterine Evacuation

Technical Appendix

Details of Laboratory Testing

Molecular Diagnostics and Antibody Testing

We tested serum and urine samples for Zika virus using a commercial real-time RT-PCR kit (Real Star Zika RT-PCR kit, Altona Diagnostics, Hamburg, Germany). We detected antibodies against Zika virus using a commercial immunofluorescence test (Arbovirus Fever Mosaic 2, Euroimmun, AG, Lübeck, Germany). We used a commercial assay (Panbio ELISA, Alere, Brisbane, Australia) to test for antibodies against dengue virus (IgG and IgM).

Zika Virus Culture

We inoculated samples onto subconfluent Vero cells in 25 cm² culture flasks and maintained them in Dulbecco's modified Eagle medium (DMEM) supplemented with 2.5% fetal bovine serum (FBS). We inspected the cells visually every day for the presence of cytopathic effect (CPE). The culture medium of the 25 cm² flask presenting CPE was centrifuged at 1000 rpm for 5 minutes to pellet detached cells and we used the supernatant to inoculate new Vero cells. The supernatant of this cell culture presented a similar CPE and tested positive for Zika virus by real-time RT-PCR.

Immunohistochemical Testing

Immunohistochemical analysis was performed at the US Centers for Disease Control and Prevention. A mouse polyclonal anti-Zika virus antibody and a polymer-based indirect colorimetric immunoalkaline phosphatase detection system with fast red chromogen (Thermo Fisher Scientific, Runcorn, Cheshire, UK) were used. Deparaffinized and rehydrated tissue sections were placed in a LAB Vision autostainer and digested in 0.1 mg/mL proteinase K (Roche Diagnostics, Mannheim, Germany). Tissue sections were incubated with anti-Zika

antibody for 30 minutes, followed by sequential incubations with MACH 4 Universal AP Polymer Kit (Biocare Medical LLC, Concord, CA, USA) and fast red substrate (Dako North America, Carpinteria, CA, USA). Sections were then counterstained in Mayer's modified hematoxylin (Poly Scientific R&D Corp. Bay Shore, NY, USA) using the Sakura Automatic Slide Stainer and mounted with aqueous mounting medium (Polysciences, Warrington, PA, USA) (1).

Placental Pathology

Pathological evaluation was performed after formalin-fixed paraffin-embedded sections of placental tissue were processed. Histopathological analyses of placental samples were performed at CDC and the Pathology Department of the Hospital Clinic of Barcelona. Histopathological analyses of the placental tissues showed normal findings consistent with intrauterine embryonic death. They revealed perivillous fibrinoid deposition, focal coarse calcifications, and moderate increase of Hofbauer cells. A focus of villous necrosis associated with calcifications was also noted. A small portion of embryonic membranes was seen showing no notable inflammatory infiltrate.

Genetics: Microarray Analysis

The patient was offered and received a chorionic villi sampling for evaluation of chromosomal and submicroscopic anomalies. The sample was cleaned under the dissecting microscope and maternal decidua was rejected. Direct chromosome analysis showed a normal 46,XX karyotype, and molecular analysis by quantitative fluorescence PCR did not show the presence of a second cell line of maternal origin. The array-comparative genomic hybridization (aCGH) (qChipCM 8x60K, qGenomics, Barcelona, Spain) revealed a normal genetic analysis with a feminine profile, arr (1–22,X)x2.

We isolated DNA from embryonic tissue automatically with the MagNA Pure Compact Instrument (Roche, Indianapolis, IN, USA) using the MagNA Pure Nucleic Acid isolation kit according to the manufacturer's instructions. We measured DNA concentration with a Qubit fluorometer (ThermoFisher Scientific, Wilmington, DE, USA).

We performed whole-genome array CGH using the qChipCM microarray following the manufacturer's instructions (ChipCM 8x60K, qGenomics, Spain). This microarray has a 350–500 kb resolution along the whole genome, a resolution of 100–125 kb in subtelomeric and

pericentromeric regions, and ≈ 30 kb resolution in constitutional regions associated with pathology. This microarray applies University of California Santa Cruz Genome Browser hg18 (NCBI Build 36, Mar 2006; <http://www.qgenomics.com/es/servicios/asistenciales/servicios-con-microarrays/postnatal-qchip-postr>) as the reference assembly. Briefly, we labeled, purified, precipitated, and hybridized 250 ng of patient DNA and of a sex-matched control according to manufacturer's instructions (qGenomics). We analyzed this array using a scanner (Agilent G2565CA Microarray Scanner System, Agilent Technologies, Santa Clara, CA, USA). We quantified and analyzed the captured images using Cytogenomics software (Agilent Technologies).

Diagnostics to Rule Out Other Maternal Infections

According to protocols for prenatal care, and as routinely performed for all pregnant women in the first trimester, the patient was screened for rubella and toxoplasma (she showed previous immunity to both infections), syphilis, HIV, and hepatitis B (she showed negative results). To rule out other maternal infections, residues from curettage were tested and showed negative results by RT-PCR for herpes simplex virus (HSV) type 1 and type 2. Endocervix samples were collected 31 days after surgical evacuation and tested negative for Zika virus by RT-PCR assay, as well as for *Chlamydia trachomatis*, *Neisseria gonorrhoeae*, and HSV 1 and 2.

Reference

1. Martines RB, Bhatnagar J, de Oliveira Ramos AM, Davi HP, Iglezias SD, Kanamura CT, et al. Pathology of congenital Zika syndrome in Brazil: a case series. *Lancet*. 2016;388:898–904. [http://dx.doi.org/10.1016/S0140-6736\(16\)30883-2](http://dx.doi.org/10.1016/S0140-6736(16)30883-2)