

*H. influenzae* serotypes and NTHi (1; <https://www.cdc.gov/meningitis/lab-manual/full-manual.pdf>; online Technical Appendix Table). In Oman, it is mandatory to report cases of Hib meningitis within 24 hours of laboratory diagnosis, and those caused by other serotypes and NTHi within 1 week, to the Department of Communicable Disease Surveillance and Control, Ministry of Health. Evidence of capsule-deficient variants of Hia that cannot be differentiated from NTHi by conventional methods (7) and recurrent invasive diseases (9,10) and outbreaks caused by Hia (9; online Technical Appendix Table) emphasize the necessity for continued surveillance, strong laboratory support, and local epidemiologic studies on non-b *H. influenzae* disease.

Hia meningitis has been reported mainly in the indigenous peoples of Canada, Alaska (USA), and Australia; in the Navajo and White Mountain Apache tribes in the southwestern United States; and in Utah (USA), Brazil, the Gambia, East Africa, and Papua New Guinea. Sporadic cases have been reported in the rest of the world (1,10; online Technical Appendix Table). The reasons behind the high rates of invasive Hia disease among indigenous children remain unclear (1). In Canada, where invasive non-b *H. influenzae* disease has been included in the list of nationally reportable diseases (<http://diseases.canada.ca/notifiable/diseases-list>) since 2007, a public health-driven initiative has been established to provide a better characterization of the epidemiology of invasive Hia disease and develop a candidate vaccine against Hia (online Technical Appendix Table).

Dr. Sawardekar is a senior consultant in the Department of Pediatrics at Nizwa Hospital, Nizwa, Oman. His primary research interests are pediatric infectious diseases and congenital malformations.

## References

1. Ulanova M, Tsang RS. *Haemophilus influenzae* serotype a as a cause of serious invasive infections. *Lancet Infect Dis*. 2014;14:70–82. [http://dx.doi.org/10.1016/S1473-3099\(13\)70170-1](http://dx.doi.org/10.1016/S1473-3099(13)70170-1)
2. World Health Organization Regional Office for the Eastern Mediterranean. *Haemophilus influenzae* vaccine introduced in all national immunization programmes. Vaccine-preventable diseases and immunization. 2014 Nov 20 [cited 2017 Feb 22] <http://www.emro.who.int/vpi/vpi-news/hib-vaccine.html>
3. Communicable Disease Surveillance and Control, Ministry of Health, Sultanate of Oman. Communicable diseases in Oman: passive surveillance data 2001–2011. [cited 2017 Feb 22] <http://www.cdscoman.org/uploads/cdscoman/Notified%20cases%202001%20-%202011.pdf>
4. Antony S, Kaushik A, Mauriello C, Chatterjee A. Non-type b *Haemophilus influenzae* invasive infections in North Dakota and South Dakota, 2013–2015. *J Pediatric Infect Dis Soc*. 2016; pii053. <http://dx.doi.org/10.1093/jpids/piw053>
5. Adderson EE, Byington CL, Spencer L, Kimball A, Hindiyeh M, Carroll K, et al. Invasive serotype a *Haemophilus influenzae* infections with a virulence genotype resembling *Haemophilus influenzae* type b: emerging pathogen in the vaccine era? *Pediatrics*. 2001;108:E18. <http://dx.doi.org/10.1542/peds.108.1.e18>
6. Lima JB, Ribeiro GS, Cordeiro SM, Gouveia EL, Salgado K, Spratt BG, et al. Poor clinical outcome for meningitis caused by *Haemophilus influenzae* serotype A strains containing the IS1016-bexA deletion. *J Infect Dis*. 2010;202:1577–84. <http://dx.doi.org/10.1086/656778>
7. Ohkusu K, Nash KA, Inderlied CB. Molecular characterisation of *Haemophilus influenzae* type a and untypeable strains isolated simultaneously from cerebrospinal fluid and blood: novel use of quantitative real-time PCR based on the cap copy number to determine virulence. *Clin Microbiol Infect*. 2005;11:637–43. <http://dx.doi.org/10.1111/j.1469-0691.2005.01203.x>
8. Roaa Z, Abdulsalam A, Shahid G, Kamaldeen B, Tariq AF. Pediatric invasive disease due to *Haemophilus influenzae* serogroup a in Riyadh, Saudi Arabia: case series. *J Infect Dev Ctries*. 2016;10:528–32. <http://dx.doi.org/10.3855/jidc.6687>
9. Hammitt LL, Block S, Hennessy TW, Debye C, Peters H, Parkinson A, et al. Outbreak of invasive *Haemophilus influenzae* serotype a disease. *Pediatr Infect Dis J*. 2005;24:453–6. <http://dx.doi.org/10.1097/01.inf.0000160954.90881.29>
10. Whyte K, Levett PN, Horsman GB, Chokani K, Hayden K, Shuel M, et al. Recurrent invasive *Haemophilus influenzae* serotype a infection in an infant. *Microbiology Discov*. 2015;3:4. <http://dx.doi.org/10.7243/2052-6180-3-4>

Address for correspondence: Kiran P. Sawardekar, Department of Pediatrics, Nizwa Hospital, Nizwa, Post Box 1066, Postal Code 611, Sultanate of Oman; email: sawar.kiran@gmail.com

## Importation of Zika Virus from Vietnam to Japan, November 2016

Takehiro Hashimoto, Satoshi Kutsuna, Shigeru Tajima, Eri Nakayama, Takahiro Maeki, Satoshi Taniguchi, Chang-Kweng Lim, Yuichi Katanami, Nozomi Takeshita, Kayoko Hayakawa, Yasuyuki Kato, Norio Ohmagari

Author affiliations: National Center for Global Health and Medicine, Tokyo, Japan (T. Hashimoto, S. Kutsuna, Y. Katanami, N. Takeshita, K. Hayakawa, Y. Kato, N. Ohmagari); National Institute of Infectious Diseases, Tokyo (S. Tajima, E. Nakayama, T. Maeki, S. Taniguchi, C.-K. Lim)

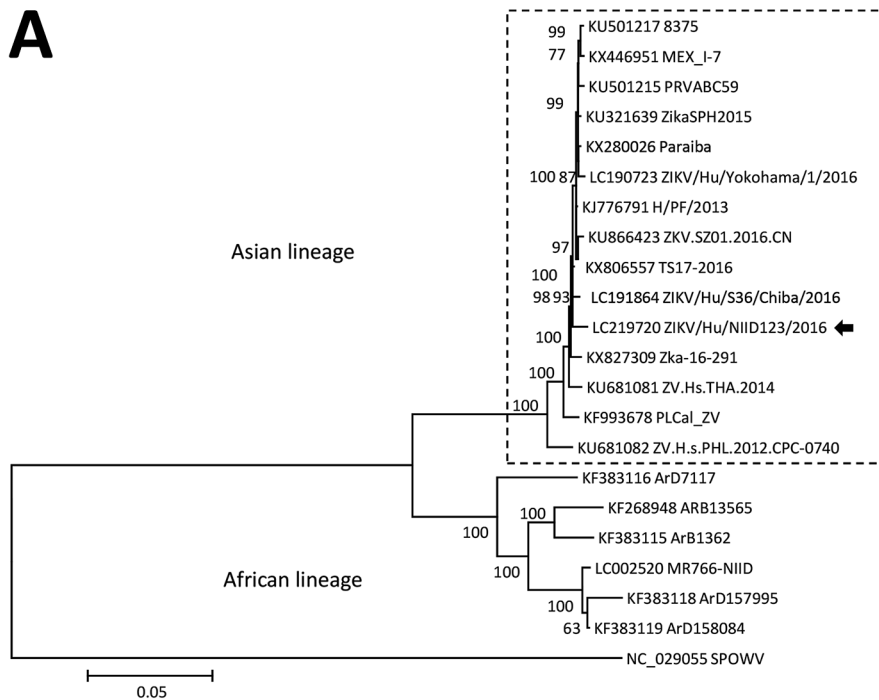
DOI: <https://dx.doi.org/10.3201/eid2307.170519>

We report a case of Zika virus infection that was imported to Japan by a traveler returning from Vietnam. We detected

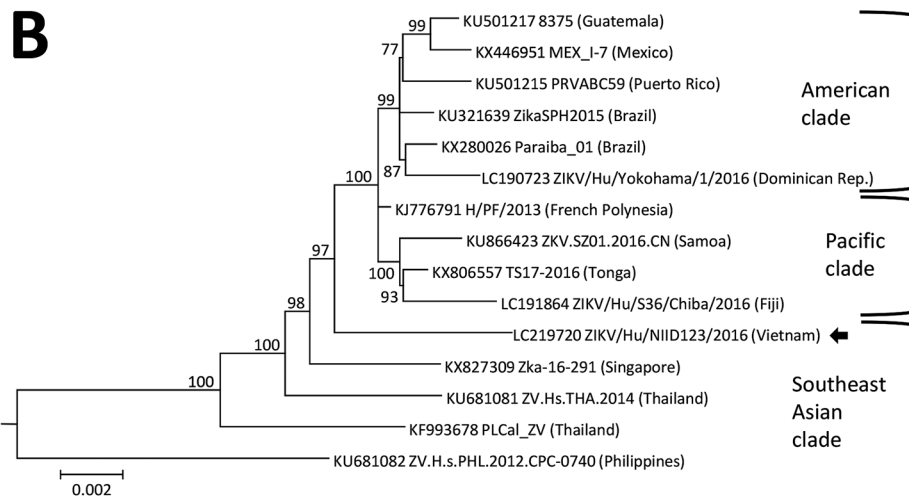
Zika virus RNA in the patient's saliva, urine, and whole blood. In the Zika virus strain isolated from the urine, we found clearly smaller plaques than in previous strains.

Zika virus has been documented in Southeast Asia since the 1940s; however, the prevalence and geographic extent of Zika virus disease in Asia remain unclear (1). In Vietnam, 219 cases of Zika virus infection were reported in 2016 and 13 new cases in 2017 (2). We report a case of Zika virus infection imported from Vietnam to Japan, diagnosed after PCR amplification of Zika virus RNA in the patient's saliva, urine, and whole blood.

A 40-year-old man came to the National Center for Global Health and Medicine in Tokyo, Japan, in the middle of November 2016 with fever and a rash. In early November 2016, he had traveled to Ho Chi Minh City, Vietnam, where he stayed for 10 days. During his return to Japan, he developed fever and a diffuse rash on his face, trunk, arms, and legs. He went to the hospital on the day after his return and reported having been bitten by mosquitoes in Ho Chi Minh City. Upon arrival at the hospital, he had no fever (temperature 36.8°C); physical examination revealed conjunctivitis and a maculopapular rash on his face, trunk, and extremities. Results of laboratory tests showed leukopenia (2,250 cells/ $\mu$ L; reference 3,500–8,500 cells/



**Figure.** Phylogenetic analysis of the Zika virus sequence derived from a patient returning to Japan from Vietnam in November 2016. The phylogenetic tree was based on a nearly complete genome and constructed by using the maximum-likelihood method (MEGA 7.0, <http://www.kumarlab.net/publications>). The sequence derived from the patient is indicated with an arrow. A) The phylogenetic tree based on a nearly full-length region. B) The expanded Asian lineage branch (dotted box in panel A). Scale bars indicate nucleotide substitutions per site.



μL) and a platelet count within reference range. We performed a rapid dengue test (Dengue Duo NS-1 Ag + Ab combo; SD Biotec, Standard Diagnostics Inc., Gyeonggi-do, South Korea); results were negative for nonstructural protein 1, IgM, and IgG. We performed real-time reverse transcription PCR (RT-PCR) amplification using Zika virus primers and probes with urine, saliva, whole blood, serum (obtained 4 days after symptom onset), and semen samples (obtained 6 days after symptom onset). We detected Zika virus RNA in the urine (cycle threshold [ $C_t$ ] 32.0), saliva ( $C_t$  39.1), and whole blood ( $C_t$  38.1) samples. However, we did not detect Zika virus RNA in the serum or semen samples. We diagnosed Zika virus infection in this patient; his symptoms resolved without treatment within 7 days after he initially sought care.

We successfully isolated the infectious Zika virus from the urine specimen. We amplified the nearly complete genome (10,696 bases; GenBank accession no. LC219720) of the Zika virus from the isolate using RT-PCR and subsequently sequenced it. BLAST analysis (<https://blast.ncbi.nlm.nih.gov/Blast.cgi>) showed that the isolate was an Asian lineage virus (3), sharing 99.3% sequence identity with the Zika virus strain isolated in French Polynesia in 2013 (H/PF/2013; GenBank accession no. KJ776791), 98.9% identity with the strain isolated in Fiji in 2016 (ZIKV/Hu/S36/Chiba/2016; GenBank accession no. LC191864), 99.0% identity with the strain isolated in Puerto Rico in 2015 (PRV-ABC59; GenBank accession no. KU501215), and 88.5% identity with the strain isolated in Uganda in 1947 (MR766-NIID; GenBank accession no. LC002520). The phylogenetic tree that we constructed using the complete coding region of the Zika virus genome suggested that the sequence belonged to the Southeast Asian clade of the Asian lineage (Figure). The plaque size of the isolated strain in Vero cells was obviously smaller than that of the Asian strain ZIKV/Hu/S36/Chiba/2016 (Pacific clade) (online Technical Appendix, <https://wwwnc.cdc.gov/EID/article/23/7/17-0519-Techapp1.pdf>).

A previous study showed that Zika virus RNA could be detected more easily in urine than in serum a few days after disease onset (4). Other reports showed that Zika virus RNA could be detected for a longer period in whole blood than that in urine and serum (5) and that Zika virus RNA could be detected more easily in saliva than in plasma and urine during the first week after symptom onset (6). In the case we report, during RT-PCR analysis of the patient's serum, urine, saliva, whole blood, and semen samples, the urine sample showed the lowest  $C_t$ , indicating that the urine sample had the highest concentration of Zika virus RNA. However, we could not detect the Zika virus genome in serum and semen samples.

Our phylogenetic analysis suggested that the Asian lineage can be divided into 3 clades (Southeast Asian,

Pacific, and American), and the strain we isolated belonged to the Southeast Asian clade. A previous study indicated that a strain isolated in Singapore in 2016 (ZKA-16-291; GenBank accession no. KX827309) also belonged to the Southeast Asian branch, and it was distinct from the isolates obtained in the Americas (7). Therefore, it is possible that the isolate from the current case was the strain that is already circulating in Vietnam and was not imported from South America. Our isolate formed smaller plaques in Vero cells than those observed with the other Asian lineage ZIKV/Hu/S36/Chiba/2016 strain (Pacific clade). We also confirmed that the plaque sizes of the PRVABC59 (American clade) and MR766-NIID (African lineage) strains resemble that of ZIKV/Hu/Chiba/S36/2016 (data not shown), suggesting that the Southeast Asian clade Zika virus strains might have a lower cytotoxicity and replicative ability than the American clade and African lineage.

In conclusion, the replicative ability of Zika virus might differ by region and thus influences endemic potential. Further studies are necessary to validate these findings.

This work was supported by a grant from the Japan National Center for Global Health and Medicine (27-6001).

Dr. Hashimoto is a medical doctor at the National Center for Global Health and Medicine, Disease Control and Prevention Center, in Tokyo, Japan. His main research interest is tropical infectious diseases.

## References

- Meltzer E, Lustig Y, Leshem E, Levy R, Gottesman G, Weissmann R, et al. Zika virus disease in traveler returning from Vietnam to Israel. *Emerg Infect Dis*. 2016;22:1521–2. <http://dx.doi.org/10.3201/eid2208.160480>
- Zika virus (02): Americas, Asia, Africa, Pacific, research, observations. *ProMed*. 2017 Feb 17 [cited 2017 Mar 20]. <https://www.promedmail.org/post/4846633>, archive no. 20170217.4846633.
- Haddow AD, Schuh AJ, Yasuda CY, Kasper MR, Heang V, Huy R, et al. Genetic characterization of Zika virus strains: geographic expansion of the Asian lineage. *PLoS Negl Trop Dis*. 2012;6:e1477. <http://dx.doi.org/10.1371/journal.pntd.0001477>
- Bingham AM, Cone M, Mock V, Heberlein-Larson L, Stanek D, Blackmore C, et al. Comparison of test results for Zika virus RNA in urine, serum, and saliva specimens from persons with travel-associated Zika virus disease—Florida, 2016. *MMWR Morb Mortal Wkly Rep*. 2016;65:475–8. <http://dx.doi.org/10.15585/mmwr.mm6518e2>
- Lustig Y, Mendelson E, Paran N, Melamed S, Schwartz E. Detection of Zika virus RNA in whole blood of imported Zika virus disease cases up to 2 months after symptom onset, Israel, December 2015 to April 2016. *Euro Surveill*. 2016;21:30269. <http://dx.doi.org/10.2807/1560-7917.ES.2016.21.26.30269>
- Barzon L, Pacenti M, Berto A, Sinigaglia A, Franchin E, Lavezzo E, et al. Isolation of infectious Zika virus from saliva and prolonged viral RNA shedding in a traveller returning from the Dominican Republic to Italy, January 2016. *Euro Surveill*. 2016;21:30159. <http://dx.doi.org/10.2807/1560-7917.ES.2016.21.10.30159>

7. Maurer-Stroh S, Mak TM, Ng YK, Phuah SP, Huber RG, Marzinek JK, et al. South-east Asian Zika virus strain linked to cluster of cases in Singapore, August 2016. *Euro Surveill.* 2016;21:30347. <http://dx.doi.org/10.2807/1560-7917.ES.2016.21.38.30347>

Address for correspondence: Satoshi Kutsuna, National Center for Global Health and Medicine—Disease Control and Prevention Center, 1-21-1, Toyama Shinjuku, Tokyo 162-8655, Japan; email: [sonare.since1192@gmail.com](mailto:sonare.since1192@gmail.com)

## Case of Nigeria-Acquired Human African Trypanosomiasis in United Kingdom, 2016

Akish Luintel, Patricia Lowe, Anneli Cooper, Annette MacLeod, Philippe Büscher, Tim Brooks, Mike Brown

Author affiliations: University College London Hospital, London, UK (A. Luintel, P. Lowe, M. Brown); University of Glasgow, Glasgow, Scotland, UK (A. Cooper, A. MacLeod); Institute of Tropical Medicine, Antwerp, Belgium (P. Büscher); Public Health England, London (T. Brooks); London School of Hygiene and Tropical Medicine, London (M. Brown)

DOI: <https://dx.doi.org/10.3201/eid2307.170695>

Human African trypanosomiasis has not been reported in Nigeria since 2012. Nevertheless, limitations of current surveillance programs mean that undetected infections may persist. We report a recent case of stage 2 trypanosomiasis caused by *Trypanosoma brucei gambiense* acquired in Nigeria and imported into the United Kingdom.

Human African trypanosomiasis (HAT), known as African sleeping sickness, is a protozoal infection, the West African form of which is caused by *Trypanosoma brucei gambiense*. We report a case of imported *T. brucei gambiense* HAT, acquired in Nigeria, where no cases have been reported since 2012 (1).

The case-patient, a 58-year-old Nigerian woman, lived near Warri, in Delta State, Nigeria. She traveled infrequently to towns within Delta State, across the Niger River into Bayelsa State, and to larger cities in Nigeria, but never outside Nigeria. She reported no history of tsetse fly bites.

In January 2016, the patient experienced leg tremors and lethargy. These symptoms persisted until arrival in the United Kingdom in May 2016. Over the next 2 months, increasing malaise and unsteadiness in walking developed. In August 2016, the patient was admitted to a regional hospital with confusion and drowsiness. She was febrile at admission but had no lymphadenopathy; neurologic examination revealed no neck stiffness or photophobia, but did show poor coordination with slow cognitive processes.

Laboratory investigations revealed microcytic anemia with a C-reactive protein level of 13 mg/L (reference value <5 mg/L) and a total serum IgM of 13.7 g/L (reference range 0.5–2.0 g/L). A blood film was negative for malaria. Confirmatory assays after positive screening assay results for HIV and syphilis antibodies showed the original results to be false positive.

Cerebrospinal fluid (CSF) examination revealed 331 leukocytes/mm<sup>3</sup>, 99% lymphocytes; CSF protein level 0.82 g/L (reference range 0.23–0.38 g/L); and glucose level was >50% plasma glucose. Results of CSF PCR for herpesviruses, enterovirus, and JC virus were negative. Results of GeneXpert (Cepheid, Buckinghamshire, UK) tests of CSF and mycobacterial culture were negative. Magnetic resonance imaging of the brain showed, on T2 weighted and flair images, bilateral diffuse hyperintensities within white matter located in the periventricular regions, basal ganglia, cerebellum, and brainstem.

Treatment with ceftriaxone, acyclovir, antituberculous treatment and prednisolone was stopped at 14 days because of a lack of clinical improvement and drug-induced transaminitis.

The patient's lethargy, intermittent confusion, and periods of somnolence became more severe. Examination in August 2016 revealed intention tremor in all limbs and myoclonic jerks. Her case was discussed with the Imported Fever Service at Public Health England. A serum sample was sent to the Hospital of Tropical Diseases in London, UK for *T. brucei gambiense* indirect fluorescent antibody testing (IFAT), which showed a positive result (titer 1:400). The patient was transferred to this hospital.

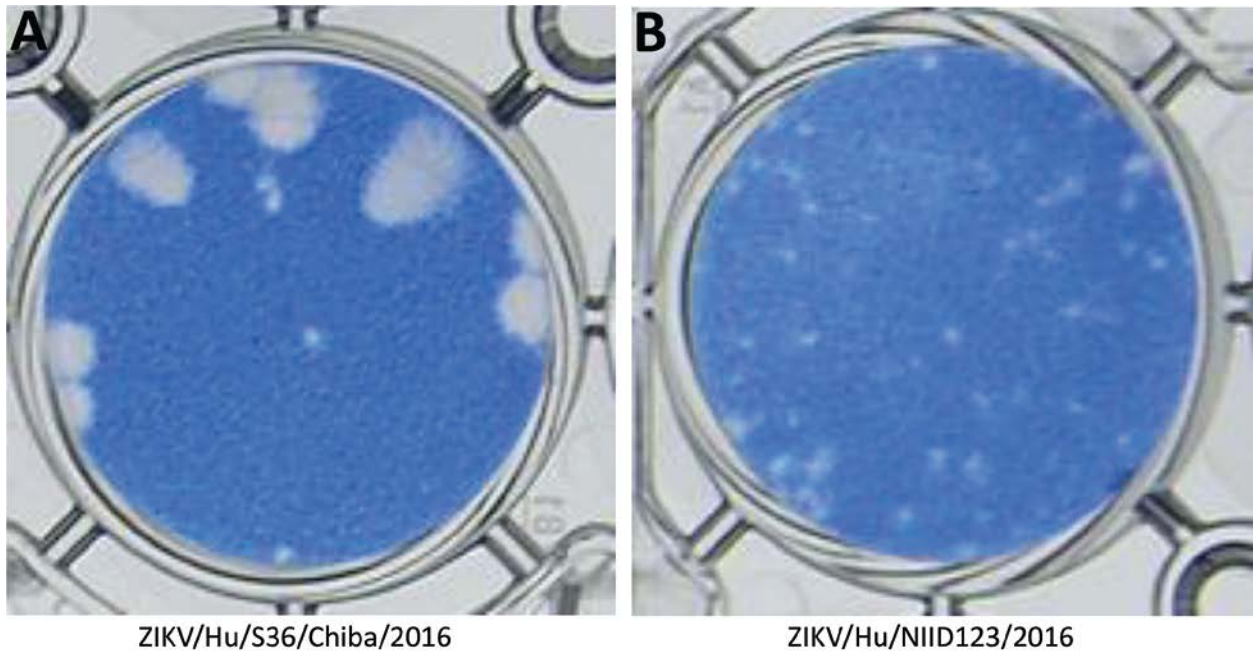
Repeat CSF examination revealed a protein level of 1.14 g/L, CSF glucose level of 2.3 mmol/L (serum 5.5 mmol/L), and 1,140 leukocytes/mm<sup>3</sup> (90% mononuclear). No trypanosomes were seen in the buffy coat of peripheral blood or CSF. CSF total IgM of 1.98 mg/L (reference range 0–0.9 mg/L) and IgG of 306 mg/L (reference range 10–40 mg/L) were markedly raised (2).

*T. brucei gambiense* IFAT results for CSF (titer 1:4) and blood (titer 1:400) were positive. DNA extracted from CSF was positive for trypanosomes of the subgenus *Trypanozoon* by PCR (3) and confirmed as *T. brucei gambiense* group 1 by diagnostic PCR with *TgsGP* primers (4). The result of immune trypanolysis was negative



# Importation of Zika Virus from Vietnam to Japan, November 2016

## Technical Appendix



**Technical Appendix Figure.** Comparison of plaque morphology between 2 Asian lineage strains of Zika virus. A) ZIKV/Hu/S36/Chiba/2016. B) ZIKV/Hu/NIID123/2016.