

Zika Virus–Associated Cognitive Impairment in Adolescent, 2016

Jason Zucker, Natalie Neu, Claudia A. Chiriboga, Veronica J. Hinton, Marc Leonardo, Arif Sheikh, Kiran Thakur

Author affiliations: Columbia University Medical Center, New York, New York, USA (J. Zucker, N. Neu, C.A. Chiriboga, V.J. Hinton, A. Sheikh, K. Thakur); Child, Adolescent, and Adult Psychiatry private practice, New York (M. Leonardo)

DOI: <https://dx.doi.org/10.3201/eid2306.162029>

Incidence of neurologic manifestations associated with Zika virus infection has been increasing. In 2016, neuropsychological and cognitive changes developed in an adolescent after travel to a Zika virus–endemic area. Single-photon emission computed tomography and neuropsychological testing raised the possibility that Zika virus infection may lead to neuropsychiatric and cognitive symptoms.

Although the full clinical spectrum of complications associated with Zika virus disease remains unclear, evidence of an association between Zika virus infection and diseases of the nervous system is growing (1). Increased incidence of neurologic manifestations has been reported, including cerebral birth abnormalities (2), Guillain-Barré Syndrome (3), meningoencephalitis (4), and memory loss (5). We describe a case of probable central nervous system (CNS) infection with Zika virus associated with the onset of neuropsychological and cognitive changes in an adolescent.

In summer 2016, an adolescent traveled to a Zika virus–endemic island in the southern Caribbean, where many insect bites occurred. Before the trip, the patient's medical history included mild depression treated with a selective serotonin reuptake inhibitor. Assessment after return to the United States indicated that mental and physical health were the same as before travel. One week after return, the patient experienced sore throat, headache, diffuse scarlatiniform rash (online Technical Appendix Figure 1, <https://wwwnc.cdc.gov/EID/article/23/6/16-2029-Techapp1.pdf>), joint pain, confusion, and short-term memory loss; no fever or eye inflammation were noted.

Three days after symptom onset, the patient received care from a pediatrician; extensive laboratory testing revealed urine reverse transcription PCR (RT-PCR) results positive for Zika virus. Serologic results were positive for Epstein-Barr virus, consistent with the patient's history of infection 15 months earlier (online Technical Appendix Table 1). Five days after symptom onset, the sore

throat, headache, rash and joint pain resolved; however, 8 days after symptom onset, the neuropsychiatric symptoms worsened and included excessive energy, decreased sleep, rapid and tangential speech, grandiose thinking, impulsivity, decreased inhibition, and behavioral regression suggestive of hypomania. The patient's psychiatrist prescribed an antipsychotic medication. An ambulatory and 24-hour electroencephalogram and magnetic resonance imaging of the brain without contrast showed no abnormalities.

Symptoms failed to improve, and 13 days after symptom onset, the patient was hospitalized for further work-up. Fourteen days after symptom onset, magnetic resonance imaging of the brain with contrast showed no abnormalities. Serum was positive for dengue virus IgG and IgM (online Technical Appendix Table 2). Repeat Zika virus testing was not performed because of the prior positivity of urine RT-PCR. Fifteen days after symptom onset, cerebrospinal fluid (CSF) obtained by lumbar puncture contained 8 leukocytes/ μ L, 1,000 erythrocytes/ μ L, 55 mg/dL glucose, and 30 mg/dL protein. CSF testing for Zika virus, performed at the Wadsworth Laboratory, New York City Department of Mental Health and Hygiene (New York, NY, USA), was positive for IgM but negative by RT-PCR.

After discharge, the patient's symptoms of regression, disinhibition, and cognitive impairment persisted. Seven weeks after symptom onset, single-photon emission computed tomography revealed mildly heterogeneous cerebral cortical perfusion, with focal moderate-to-severe hypoperfusion in the inferior left frontal region (online Technical Appendix Figure 2); neuropsychological testing demonstrated evidence of superior intellectual ability (Wechsler Intelligence Scale for Children—fourth edition, General Ability Index), probably reflecting function before illness (online Technical Appendix Table 3). Processing speed was significantly slowed relative to other skills; the Processing Speed Index score was >2 SDs lower than the General Ability Index score. Performance on most memory tests and tests of executive function was within normal limits yet lower than expected given reported performance before illness. Immediate and delayed visual recall of the Rey complex figure was poor, reflecting primary difficulty encoding new visual information. On a standardized behavioral questionnaire, the patient self-reported psychiatric symptoms including anxiety, racing thoughts, and an inability to turn off thoughts. The patient had not experienced racing thoughts before the Zika virus infection, and the anxiety symptoms had worsened since the infection. In addition, the patient reported significant and functionally limiting fatigue. Nine weeks after onset, symptoms were better but not resolved; because of concerns that these symptoms were triggered by a postinfectious immune-mediated process, a trial of intravenous immunoglobulin was administered. Fifteen

weeks after symptom onset, the patient's symptoms were better but not fully resolved.

Although we cannot entirely rule out Epstein-Barr virus as a possible trigger, the length of time between previous infection and onset of neuropsychological symptoms would be unusual. In addition, although it is impossible to exclude contributions of coinfection from other mosquito-borne viruses (e.g., dengue and chikungunya), given the Zika virus positivity on RT-PCR, the patient's condition met criteria for definitive Zika virus infection and the CSF IgM titer was consistent with CNS involvement of Zika virus. The changes on single-photon emission computed tomographs and neuropsychological test scores raise the possibility that Zika virus infection may trigger neuropsychiatric and cognitive symptoms. Although we cannot prove that the patient's symptoms were related to Zika virus, clinicians should be aware of this potential association and the value of closely monitoring patients with Zika virus infection.

K.T., who helped edit the manuscript, is a World Health Organization consultant on neurologic manifestations in the context of the Zika virus outbreak, receives an honorarium as chief consult editor on Zika virus for Medscape consults, and participates in Zika research through the Neuroviruses Emerging in the Americas Study. K.T. receives funding support from the National Institutes of Health, and J.Z. receives funding support from a National Institutes of Health training grant (T32 AI007531).

Dr. Zucker is a postdoctoral fellow in adult and pediatric infectious diseases at Columbia University Medical Center. His research interests include improving prevention and treatment for adolescents and young adults living with, or at risk for, HIV infection, hepatitis C, and sexually transmitted diseases.

References

1. Araujo AQ, Silva MT, Araujo AP. Zika virus-associated neurological disorders: a review. *Brain*. 2016;139:2122–30. <http://dx.doi.org/10.1093/brain/aww158>
2. Mlakar J, Korva M, Tul N, Popović M, Poljšak-Prijatelj M, Mraz J, et al. Zika virus associated with microcephaly. *N Engl J Med*. 2016;374:951–8. <http://dx.doi.org/10.1056/NEJMoa1600651>
3. dos Santos T, Rodriguez A, Almiron M, Sanhueza A, Ramon P, de Oliveira WK, et al. Zika virus and the Guillain-Barré Syndrome—case series from seven countries. *N Engl J Med*. 2016;375:1598–601. <http://dx.doi.org/10.1056/NEJMc1609015>
4. Carteaux G, Maquart M, Bedet A, Contou D, Brugières P, Fourati S, et al. Zika virus associated with meningoencephalitis. *N Engl J Med*. 2016;374:1595–6. <http://dx.doi.org/10.1056/NEJMc1602964>
5. Nicastri E, Castilletti C, Balestra P, Galgani S, Ippolito G. Zika virus infection in the central nervous system and female genital tract. *Emerg Infect Dis*. 2016;22:2228–30. <http://dx.doi.org/10.3201/eid2212.161280>

Address for correspondence: Jason Zucker, Columbia University Medical Center, 622 West 168th St, PH4 West-474, New York, NY 10032, USA; email: jz2700@cumc.columbia.edu

Highly Pathogenic Avian Influenza Virus (H5N8) Clade 2.3.4.4 Infection in Migratory Birds, Egypt

Abdullah A. Selim, Ahmed M. Erfan, Naglaa Hagag, Ali Zanaty, Abdel-Hafez Samir, Mohamed Samy, Ahmed Abdelhalim, Abdel-Satar A. Arafa, Mohamed A. Soliman, Momtaz Shaheen, Essam M. Ibraheem, Ibrahim Mahrous, Mohamed K. Hassan, Mahmoud M. Naguib

Author affiliations: National Laboratory for Veterinary Quality Control on Poultry Production, Animal Health Research Institute, Giza, Egypt (A.A. Selim, A.M. Erfan, N. Hagag, A. Zanaty, A.-H. Samir, M. Samy, A. Abdelhalim, A.-S.A. Arafa, M.A. Soliman, M. Shaheen, E.M. Ibraheem, M.K. Hassan, M.M. Naguib); General Organization for Veterinary Services, Giza (I. Mahrous); Friedrich-Loeffler-Institut, Federal Research Institute for Animal Health, Insel-Riems, Germany (M.M. Naguib)

DOI: <https://dx.doi.org/10.3201/eid2306.162056>

We isolated highly pathogenic avian influenza virus (H5N8) of clade 2.3.4.4 from the common coot (*Fulica atra*) in Egypt, documenting its introduction into Africa through migratory birds. This virus has a close genetic relationship with subtype H5N8 viruses circulating in Europe. Enhanced surveillance to detect newly emerging viruses is warranted.

Avian influenza is a highly contagious disease of poultry that continues to spread across the globe in bird populations. Occasionally, transmission of a highly pathogenic avian influenza virus (HPAIV) from infected poultry to humans results in a severe public health crisis (1).

In 2010, strains of HPAIV (H5N8) of clade 2.3.4.4 were first detected among wild birds in Asia and later spread to domestic birds across China, South Korea, and Japan (2,3). Most recently, a novel reassortant virus of subtype H5N8 clade 2.3.4.4 was reported in Russia and further spread to many countries in Europe, Asia, and the Middle East (4,5). The spread of HPAIV (H5N8) strains has been linked to the overlapping flyways of migratory wild birds that come from different continents; this mingling of wild birds poses a major concern worldwide (4,6).

Egypt is one of the most notable migration spots for migratory birds crossing Europe, Asia, and Africa. In early winter each year, thousands of migrating waterfowl use Egypt as a resting stop before they continue their journey southward through the African continent through the East Africa/East Asia and Mediterranean/Black Sea migratory

Zika Virus–Associated Cognitive Impairment in Adolescent, 2016

Technical Appendix

Technical Appendix Table 1. Outpatient laboratory evaluation of acute illness and mental status changes in an adolescent returning from a Zika endemic territory

Date	Test (units)	Result	Reference
8/6/16*	EBV EBNA (U/ml)	75.4 (H)	0–21.9
	EBV VCA IgG (U/ml)	100 (H)	0–21.9
	EBV VCA IgM (U/ml)	<10	0–43.9
	EBV IgG (U/ml)	9.3	0–10.9
	Mycoplasma IgG (U/L)	.02	<0.09
	Mycoplasma IgM (U/L)	.21 U/L	<0.76
	Parvovirus IgG (IV)	5.73 (H)	<0.89
	Parvovirus IgM (IV)	.24	<0.89
	Antinuclear antibody	Negative	Negative
	Antistreptolysin O Titer (IU/ml)	63	0–330
	DNase B antibody (U/ml)	169	0–310
	Sedimentation rate (mm/hr)	8	0–24
	Thyroid stimulating hormone (uH/mL)	1.2	.4 – 4.2
	Vitamin B12 (pg/ml)	406	211–911
	Folate (ng/mL)	10.17	4–1000
	Vitamin D 25 Hydroxy (NG/ml)	42.5	30–100
	8/6/16†	Lyme Western Blot IgM	Negative
Lyme Western Blot IgG		Negative	Neg
Serum N methyl D Aspartate Receptor Antibody		<1:10	<1:10
8/6/16‡	Zika Serum RT-PCR	Negative	Negative
	Zika Serology (IgM)	Negative	Negative
	Zika Urine RT-PCR	Positive	Negative

*Labs performed at Mount Sinai Beth Israel Laboratory.

†Labs performed at an outside hospital laboratory.

‡Labs performed at New York Department of Health.

Technical Appendix Table 2. Inpatient laboratory evaluation of acute illness and mental status changes in an adolescent returning from a Zika endemic territory

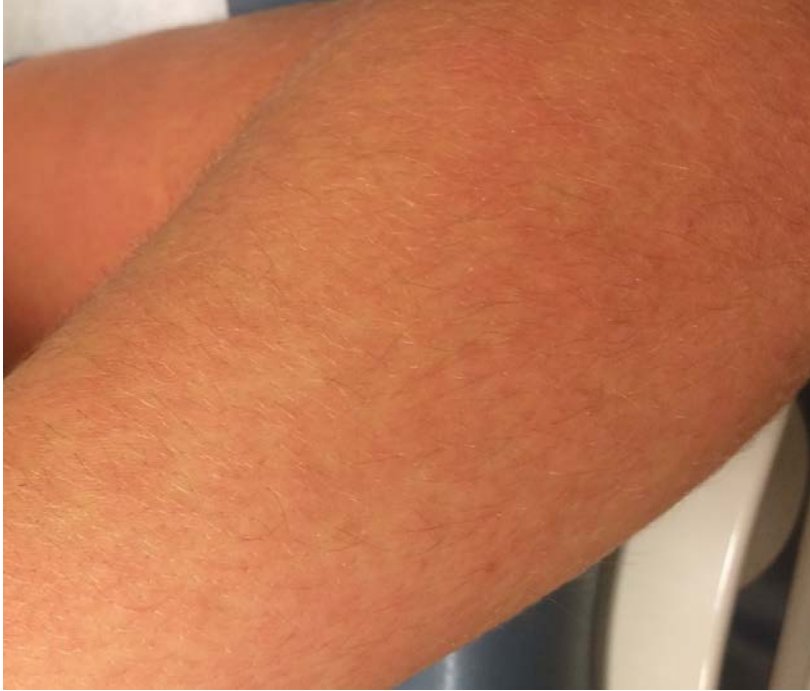Date	Test	Result	Reference
Serum	Urine toxicology	Negative	Negative
	8/16/16*		
	C-Reactive Protein (mg/L)	<0.15	0–10
	Sedimentation rate (mm/hr)	10	0–20
	Dengue Fever Virus Antibody IgM (IV)	2.15 (H)	<1.64
	Dengue Fever Virus Antibody IgG (IV)	14 (H)	<1.64
	Total IgG (mg/dL)	941	714 - 1711
CSF	CSF Cell Count (cells/microliter)	8 WBCs	0 - 5
	8/18/16*	1000 RBCs	0
	CSF Glucose (mg/dL)	55 (L)	60 - 80
	CSF IgG and Total Protein Ratio	6.7	6–13
	BioFire® Meningitis/Encephalitis RT- PCR Panel	Negative	Negative
	Oligoclonal Bands	Negative	Negative
8/18/16*	CSF N methyl D Aspartate Receptor Antibody, IgG	Negative	Negative
8/18/16†	CSF Zika RT-PCR	Negative	Negative
	CSF Zika IgM	Positive	Negative

*Labs performed at New York Presbyterian Columbia.

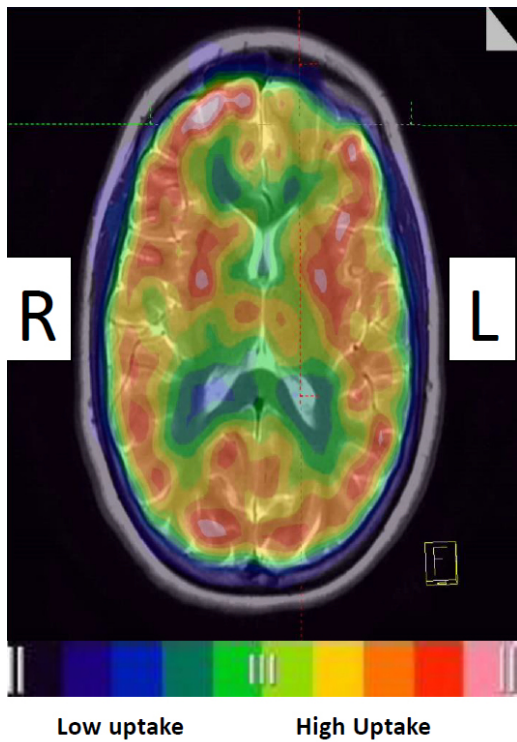
†Labs performed at New York Department of Health.

Technical Appendix Table 3. Neuropsychological test findings

Intellectual Function	Score	Percentile
Wechsler Intelligence Scale for Children - 5	Standard Score	Percentile
Verbal Comprehension	118	88
Visual Spatial	117	87
Fluid Reasoning	118	88
Working Memory	115	84
Processing Speed	83	13
General Ability Index	121	92
Memory and Learning		
California Verbal Learning Test for Children	T/z-score	Percentile
Trials 1-5	45	34
Long Delay Free Recall	0	50
NEPSY - 2	Scaled Score	Percentile
Memory for Designs	12	75
Memory for Designs-Delayed	13	84
Rey Complex Figure Test	T-score	Percentile
Immediate Recall	29	2
Delayed Recall	24	1
Recognition	27	1
Wide Range Assessment of Memory and Learning 2	Scaled Score	Percentile
Story Memory	11	63
Story Memory Delay Recall	12	75
Story Memory Recognition	14	91
Executive Functions		
Delis-Kaplan Executive Function System	Scaled Score	Percentile
Verbal Fluency		
Letter	14	91
Category	12	75
Switching	13	84
Trail Making		
Visual Scanning	7	16
Number Sequencing	10	50
Letter Sequencing	12	75
Number-Letter Switching	8	25
Motor Speed	10	50
Color Word Interference		
Color Naming	9	37
Word Reading	11	63
Inhibition	8	25
Inhibition - Total Errors	8	25
Inhibition/Switching	9	37
Inhibition/Switching - Total Errors	10	50
Tower		
Total Achievement Score	13	84
Mean First Move Time	13	84
Time-Per-Move Ratio	11	63
Move Accuracy Ratio	8	25



Technical Appendix Figure 1. Scarlitiform rash in a patient with urine positive for Zika virus on reverse transcription PCR. Picture taken 4 days after the onset of symptoms.



Technical Appendix Figure 2. This ^{99m}Tc -ethyl cysteinyl dimer (ECD) fusion of brain SPECT and MRI shows the localization of focal left inferofrontal lobe moderate-severely decreased hypoperfusion (crosshairs), along with a non-specific heterogeneous global uptake pattern.