

3. Ambrosioni J, van Delden C, Krause KH, Bouchuiguir-Wafa C, Nagy M, Passweg J, et al. Invasive microsporidiosis in allogeneic haematopoietic SCT recipients. *Bone Marrow Transplant*. 2010;45:1249–51. <https://doi.org/10.1038/bmt.2009.315>
4. Jiménez-González GB, Martínez-Gordillo MN, Caballero-Salazar S, Peralta-Abarca GE, Cárdenas-Cardoz R, Arzate-Barbosa P, et al. [Microsporidia in pediatric patients with leukemia or lymphoma]. *Rev Invest Clin*. 2012;64:25–31. Spanish.
5. Velásquez JN, di Risio C, Etchart C, Chertcoff AV, Astudillo OG, Carnevale S. Multimethodological approach to gastrointestinal microsporidiosis in HIV-infected patients. *Acta Parasitol*. 2019;64:658–69. <https://doi.org/10.2478/s11686-019-00095-z>
6. Valperga SM, de Jogna Prat SA, de Valperga GJ, Lazarte SG, de Trejo AV, Díaz N, et al. [Microsporidian spores in the stool specimens of toddlers, with or without diarrhea, from Tucumán, Argentina]. *Rev Argent Microbiol*. 1999;31:157–64. Spanish.
7. Han B, Weiss LM. Therapeutic targets for the treatment of microsporidiosis in humans. *Expert Opin Ther Targets*. 2018;22:903–15. <https://doi.org/10.1080/14728222.2018.1538360>
8. Buckholt MA, Lee JH, Tzipori S. Prevalence of *Enterocytozoon bieneusi* in swine: an 18-month survey at a slaughterhouse in Massachusetts. *Appl Environ Microbiol*. 2002;68:2595–9. <https://doi.org/10.1128/AEM.68.5.2595-2599.2002>
9. Mena CJ, Barnes A, Castro G, Guasconi L, Burstein VL, Beccacece I, et al. Microscopic and PCR-based detection of microsporidia spores in human stool samples. *Rev Argent Microbiol*. 2021;53:124–8. <https://doi.org/10.1016/j.ram.2020.04.005>
10. Desoubreaux G, Nourrisson C, Moniot M, De Kyvon MA, Bonnin V, De La Bretonnière ME, et al. Genotyping approach for potential common source of *Enterocytozoon bieneusi* infection in Hematology unit. *Emerg Infect Dis*. 2019;25:1625–31. <https://doi.org/10.3201/eid2509.190311>

Address for correspondence: Laura S. Chiapello, Departamento de Bioquímica Clínica (Lab 105), Facultad de Ciencias Químicas, Universidad Nacional de Córdoba, CIBICI, CONICET, Ciudad Universitaria, Haya de la Torre y Medina Allende, X5000HUA Córdoba, Argentina; email: laura.chiapello@unc.edu.ar

## Subdural Empyema from *Streptococcus suis* Infection, South Korea

Sejin Choi, Tae-Hwan Park, Hyun-Jeong Lee, Tae Hyoung Kim, Jin-Deok Joo, Jisoon Huh, You Nam Chung, Sang Taek Heo, Eui Tae Kim, Jong-Kook Rhim

Author affiliations: Seoul National University Hospital, Seoul, South Korea (S. Choi, T.-H. Park); Jeju National University College of Medicine, Jeju, South Korea (H.-J. Lee, T.H. Kim, J.D. Joo, J. Huh, Y.N. Chung, S.T. Heo, E.T. Kim, J.-K. Rhim); Jeju National University Graduate School, Jeju (T.H. Kim); Jeju National University Core Research Institute, Jeju (E.T. Kim)

DOI: <https://doi.org/10.3201/eid3003.231018>

In Jeju Island, South Korea, a patient who consumed raw pig products had subdural empyema, which led to meningitis, sepsis, and status epilepticus. We identified *Streptococcus suis* from blood and the subdural empyema. This case illustrates the importance of considering dietary habits in similar clinical assessments to prevent misdiagnosis.

*Streptococcus suis* is a zoonotic pathogen that affects pigs and humans when they handle pigs or eat undercooked pork products. Globally, an outbreak of infection occurred in China in 2005, and *S. suis* is a common cause of bacterial meningitis in Vietnam and Hong Kong (1,2). High-risk eating habits of ingesting raw or undercooked pork also have been reported in Thailand (2).

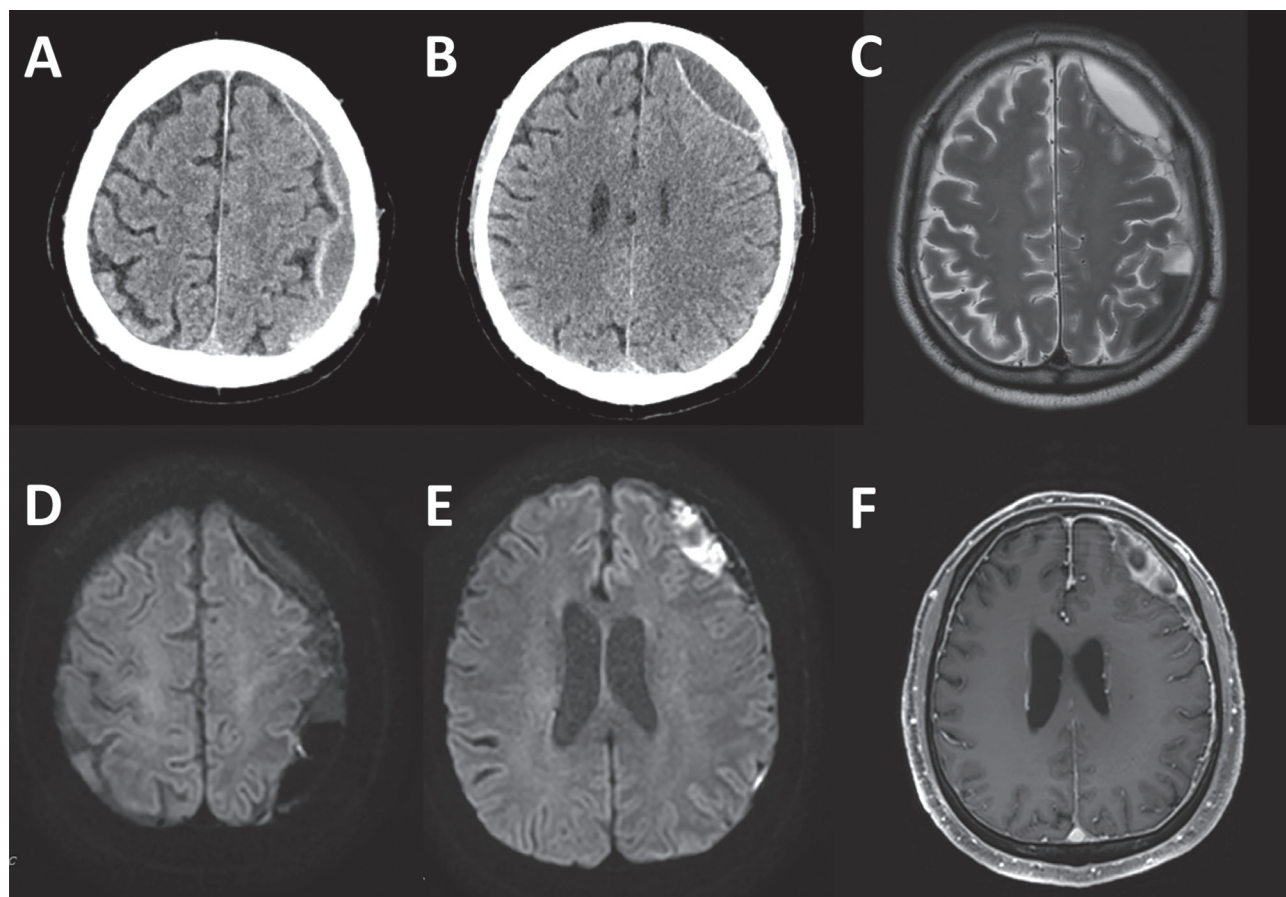
Although *S. suis* infection traditionally is associated with pig contact or consumption of undercooked pork, South Korea reported its first human infection in 2012, with subsequent cases not explicitly linked to pigs (3). Of note, consuming raw pork is rare in South Korea because of cultural taboos. In South Korea, the prevalence of *S. suis* infection was 12.6% among slaughtered pigs and 16.4% among diseased pigs; serotypes 2 and 14 were predominant in the Jeju area compared with other regions (4).

Common manifestations of *S. suis* infection are meningitis, endocarditis, septicemia, and arthritis but not subdural empyema (2). Subdural empyema is a rare but serious infection that causes a collection of pus between the dura and arachnoid layers of the meninges (5). We describe a case of subdural empyema caused by *S. suis* infection after the consumption of raw pig products in Jeju Island, South Korea, where the pork industry has been an economic pillar for over 500 years.

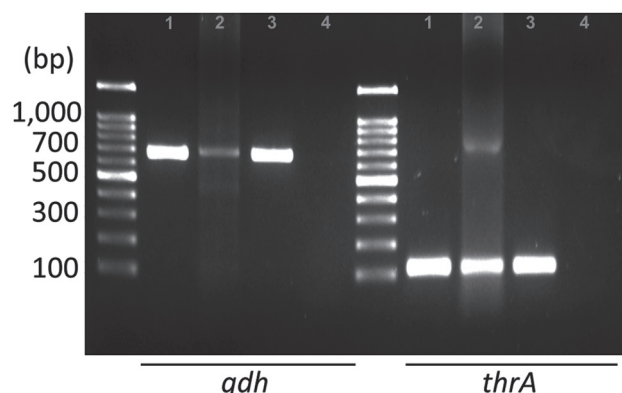
The patient, a 76-year-old man, visited the emergency department exhibiting dysarthria, neck stiffness, and right-sided weakness with motor grade III. He did not have hearing loss, a common symptom of human *S. suis* infection, or signs of increased intracranial pressure such as papilledema. His medical history included a fall 3 months prior and recent headache and dizziness. Initial brain computed tomography and magnetic resonance imaging showed chronic subdural hematoma (cSDH) with recurrent bleeding and an inflamed subdural sac (Figure 1). Concurrently, he exhibited septic symptoms, such as fever, hypotension, marked thrombocytopenia, and elevated inflammatory markers, necessitating immediate administration of antibiotics (vancomycin, ceftazidime, and metronidazole). Further studies showed that he did not have endocarditis, sinusitis, or otitis media (all possible causes of subdural empyema) (5). We drew blood cultures on admission day and on hospital days 4 and 7 and incubated them for >5 days. On hospital day 4, we detected *S. suis* from a blood culture. Subsequent inquiries

into the patient's dietary habits revealed recent consumption of Ae-Jeo-Hoe, a traditional dish from Jeju Island, made by slicing open the belly of a pregnant pig, finely chopping or grinding the fetus, and eating it raw with various seasonings. Consequently, we conducted further microbiologic investigations to rule out other conditions, such as severe fever with thrombocytopenia syndrome and cysticercosis, which all turned out negative.

Upon confirmation of *S. suis* infection, treatment shifted to ceftriaxone. Results of blood cultures from days 4 and 7 were negative, but neurologic deficits persisted. On day 10, we evacuated a subdural empyema through left frontal and parietal burr hole trephinations. Intraoperatively, we identified a multiseptated pus-like tissue and a bloody subdural fluid. Despite the negative swab and fluid culture results, PCR confirmed *S. suis* *gdh* and *thrA* genes in the subdural empyema sample (Figure 2). We extracted total genomic DNA from blood-cultured bacteria and from the patient's subdural hematoma by using the Solg Genomic DNA Prep Kit (SolGent,



**Figure 1.** Initial image findings of subdural empyema in a patient with *Streptococcus suis* infection, Jeju Island, South Korea. A, B) Computed tomography scans. D–F) Magnetic resonance imaging: diffusion weighted (D, E), T2 (C), and enhanced T1 (F).



**Figure 2.** Detection of *Streptococcus suis* in a patient with *Streptococcus suis* infection, Jeju Island, South Korea, performed by using PCR with specific primers for *gdh* and *thrA*. Size marker, 1 kb DNA ladder (LugenSci, <https://www.lugensci.com>). Lane 1, blood culture, DNA from patient's blood culture; lane 2, subdural empyema, DNA from patient's subdural pus; lane 3, positive control, DNA from previously isolated *S. suis* stock; lane 4, negative control, no template PCR condition.

<http://www.solgent.com>) according to the manufacturer's instructions. We detected *S. suis* DNA by using the *gdh*-specific primers GCAGCGTATTCTGTCAAACG (forward) and CCATGGACAGATAAAGATGG (reverse) (6), and the *thrA*-specific primers GAAAATATGAAGAGCCATGTCG (forward) and GACAACGAACATAACAGAACTTC (reverse) (7). In addition, we conducted next-generation whole-genome sequencing (Theragen Bio, <https://www.theragenbio.com>), which identified the isolate as serotype 2, which closely matched the genetic sequence of the ISU2614 strain (GenBank accession no. ASM1348816v1), known for its high virulence (8,9) (Appendix Figure, <https://wwwnc.cdc.gov/EID/article/30/3/23-1018-App1.pdf>).

On day 16, the patient had onset of convulsive status epilepticus potentially attributable to meningitis, which was managed by a continuous infusion of propofol. The patient was subsequently stabilized, and his neurologic symptoms improved.

This case is noteworthy because it represents a neurosurgical condition, specifically subdural empyema, which required surgery, associated with *S. suis* infection. In addition, severe conditions such as sepsis and status epilepticus after the infection underscore the lethality of this zoonotic pathogen.

The role of the patient's cSDH caused by prior trauma warrants further discussion in the pathogenesis of the infection. The vascularized membrane of the cSDH may have served as a seeding bed for the hematogenous spread of the infection and development of the subdural empyema (10), suggesting increased

susceptibility in patients with cSDH or older patients with a trauma history and emphasizing the need for prompt diagnosis and treatment.

This report highlights a unique correlation to consuming a traditional dish prepared from raw pig fetuses and underscores the importance of considering dietary habits in the clinical assessment. It also raises public health concerns about the potential risks associated with consuming raw or undercooked pork products and possible *S. suis* endemic in Jeju Island, where extensive pig rearing and consumption take place. Increasing disease awareness among clinicians and laboratories can prevent undiagnosed or misdiagnosed cases.

E.T.K. was supported by the National Research Foundation of Korea grant, funded by the Ministry of Science and Information and Communication Technology (grant no. 2021R1A2C1010313) and the Ministry of Education (grant no. RS2023-00270936), South Korea.

## About the Author

Dr. Choi is a neurosurgery resident at Seoul National University Hospital. His primary research interests include neurosurgical diseases and public health.

## References

- Wertheim HF, Nghia HD, Taylor W, Schultsz C, Taylor W, Schultsz C. *Streptococcus suis*: an emerging human pathogen. Clin Infect Dis. 2009;48:617–25. <https://doi.org/10.1086/596763>
- Huong VTL, Ha N, Huy NT, Horby P, Nghia HDT, Thiem VD, et al. Epidemiology, clinical manifestations, and outcomes of *Streptococcus suis* infection in humans. Emerg Infect Dis. 2014;20:1105–14. <https://doi.org/10.3201/eid2007.131594>
- Kim J-G, Seong GM, Kim YR, Heo ST, Yoo JR. *Streptococcus suis* causes bacterial meningitis with hearing loss in patients without direct exposure to pigs in a regional pork industry territory. J Med Life Sci. 2023;20:43–7.
- Oh SI, Jeon AB, Jung BY, Byun JW, Gottschalk M, Kim A, et al. Capsular serotypes, virulence-associated genes and antimicrobial susceptibility of *Streptococcus suis* isolates from pigs in Korea. J Vet Med Sci. 2017;79:780–7. <https://doi.org/10.1292/jvms.16-0514>
- Baek SH, Choi SK, Ryu J, Lee SH. Subdural empyema treated by continuous irrigation and drainage catheter insertion in a young adult patient with hemiparesis: a case report. Nerve. 2017;3:85–8.
- Okwumabua O, O'Connor M, Shull E. A polymerase chain reaction (PCR) assay specific for *Streptococcus suis* based on the gene encoding the glutamate dehydrogenase. FEMS Microbiol Lett. 2003;218:79–84. <https://doi.org/10.1111/j.1574-6968.2003.tb11501.x>
- Liu Z, Zheng H, Gottschalk M, Bai X, Lan R, Ji S, et al. Development of multiplex PCR assays for the identification of the 33 serotypes of *Streptococcus suis*. PLoS One. 2013;8:e72070. <https://doi.org/10.1371/journal.pone.0072070>



8. Fan H-j. Advances in pathogenesis of *Streptococcus suis* serotype 2. *Journal of Integrative Agriculture*. 2017;16: 2834–47.
9. Nicholson TL, Waack U, Anderson TK, Bayles DO, Zaia SR, Goertz I, et al. Comparative virulence and genomic analysis of *Streptococcus suis* isolates. *Front Microbiol*. 2021;11:620843. <https://doi.org/10.3389/fmicb.2020.620843>
10. Shapiro M, Walker M, Carroll KT, Levitt MR, Raz E, Nossek E, et al. Neuroanatomy of cranial dural vessels: implications for subdural hematoma embolization. *J Neurointerv Surg*. 2021;13:471–7. <https://doi.org/10.1136/neurintsurg-2020-016798>

Address for correspondence: Eui Tae Kim or Jong-Kook Rhim, Jeju National University College of Medicine, Aran 13gil 15 (Ara-1 Dong) Jeju-si, Jeju Self-Governing Province, 63241, South Korea; email: [tae@jejunu.ac.kr](mailto:tae@jejunu.ac.kr) or [nsrhim@gmail.com](mailto:nsrhim@gmail.com)

## Incursion of Highly Pathogenic Avian Influenza A(H5N1) Clade 2.3.4.4b Virus, Brazil, 2023

Andreina Carvalho de Araújo,<sup>1</sup> Laura Morais Nascimento Silva,<sup>1</sup> Andrew Yong Cho,<sup>1</sup> Márcio Repenning, Deyvid Amgarten, Ana Paula de Moraes, Fernanda Malta, Michael Miller, Erick G. Dorlass, Soledad Palameta, Daniele Bruna L. Oliveira, Jansen de Araújo, Clarice Weis Arns, Edison L. Durigon, João Renato R. Pinho, Dong-Hun Lee, Helena Lage Ferreira

Author affiliations: University of São Paulo, Pirassununga, Brazil (A.C. Araujo, L.M.N. Silva, D.B.L. Oliveira, J. De Araujo, E.L. Durigon, J.R.R. Pinho, H.L. Ferreira); Konkuk University, Gwangjin-gu, South Korea (A.Y. Cho, D.-H. Lee); FURG, Rio Grande, Brazil (M. Repenning); Albert Einstein Israelite Hospital, São Paulo, Brazil (D. Amgarten, F. Malta, E.G. Dorlass, D.B.L. Oliveira, J.R.R. Pinho); UNICAMP, Campinas, Brazil (A.P. de Moraes, M. Miller, S. Palameta, C.W. Arns); Institut Pasteur, São Paulo, Brazil (E.L. Durigon)

DOI: <http://doi.org/10.3201/eid3003.231157>

<sup>1</sup>These authors contributed equally to this article.

We report 4 highly pathogenic avian influenza A(H5N1) clade 2.3.4.4.b viruses in samples collected during June 2023 from Royal terns and Cabot's terns in Brazil. Phylo-dynamic analysis revealed viral movement from Peru to Brazil, indicating a concerning spread of this clade along the Atlantic Americas migratory bird flyway.

Highly pathogenic avian influenza viruses (HPAIVs) have caused substantial economic losses in the poultry industry and potentially threaten public health. Since its first identification in 1996, H5Nx HPAIVs, Gs/GD lineage, have evolved into multiple genotypes through reassortment across decades (1–3).


In late 2020, novel reassortant clade 2.3.4.4b H5N1 HPAIVs emerged and became predominant in Europe (1). The first detection of clade 2.3.4.4 b H5N1 viruses in North America occurred through trans-atlantic spread via wild birds in late 2021 (2). From late 2021 to early 2022, multiple reassortant viruses have been naturally generated by recombination with North American low pathogenicity avian influenza virus (LPAIV) internal genes. In late October 2022, South America countries including Argentina, Bolivia, Brazil, Chile, Colombia, Ecuador, Paraguay, Peru, Uruguay, and Venezuela reported clade 2.3.4.4 b H5N1 HPAIV detection in domestic and wild birds (3,4). Human infections were also reported for the first time in South America (3,5). We report 4 clade 2.3.4.4b H5N1 HPAIVs sequenced from wild bird carcasses collected in Brazil in June 2023.

In June 2023, we collected swab samples from Royal terns (*Thalasseus maximus*) and Cabot's terns (*Thalasseus acuflavidus*) in Brazil, from which we detected and sequenced 4 H5N1 HPAIVs: A/*Thalasseus maximus*/Brazil-ES/23ES1A0008/2023 (TM/BR08/23), A/*Thalasseus acuflavidus*/Brazil-ES/23ES1A0009/2023 (TA/BR09/23), A/*Thalasseus acuflavidus*/Brazil-ES/23ES1A0025/2023 (TA/BR25/23), and A/*Thalasseus maximus*/Brazil-ES/23ES1A0026/2023 (TM/BR26/23) (Appendix 1, <https://wwwnc.cdc.gov/EID/article/30/3/23-1157-App1.pdf>). We obtained complete genome sequences for TM/BR08/23 and TM/BR09/23 and partial sequences for TA/BR25/23 and TM/BR26/23 (GISAID [<https://www.gisaid.org>] accession nos. EPI\_ISL\_18130597, EPI\_ISL\_18130622, EPI\_ISL\_18130627, and EPI\_ISL\_18130628) (Appendix 1 Table 1).

All H5N1 isolates possessed polybasic amino acid sequences at the hemagglutinin (HA) cleavage site (PLREKRKKR/GLF). The isolates shared high sequence identities (99.59%–100%) across all 8 genes. BLAST search (<https://blast.ncbi.nlm.nih.gov>) showed all 8 genes shared high identities (99.59%–

# Subdural Empyema from *Streptococcus suis* Infection, South Korea

## Appendix



**Appendix Figure.** Phylogenomic tree of blood cultured *Streptococcus suis* from the patient and related type strains. Whole-genome phylogenies based on a maximum-likelihood (phylogenomic) tree inferred from 49 genomes. Scalebar indicates 0.0005 substitutions per nucleotide position.