

patient's consent was not obtained. The patient has not had a recurrence of multiple ulcers but remains positive for *H. ailurogastricus*. The limitation of this case report is that, although we succeeded in culturing *H. ailurogastricus* in the stomach of this patient and the drug-susceptibility test has determined the regimen for eradication, we have not yet been able to perform eradication therapy. Therefore, the efficacy of eradication in *H. ailurogastricus* infections has not been confirmed. *H. ailurogastricus* eradication therapy will be administered at the next patient visit to prevent ulcer recurrence.

The clinical importance of NHPH infection in the human stomach has been increasing in the post-*H. pylori* era. Because NHPH species such as *H. suis* and *H. ailurogastricus* cannot be detected by most *H. pylori* diagnostic tests, such as the urea breath test and stool antigen test, NHPH infections should be considered when routine *H. pylori* tests are negative, despite the presence of inflammatory findings in the gastric mucosa.

This work was supported by MEXT/JSPS KAKENHI (grant no. 20H03667, awarded to H.S.), and by AMED (grant no. JP20fk0108148, awarded to E.R. and H.S.).

About the Author

Dr. Sano is an instructor at the Division of Gastroenterology and Hepatology, Tokai University School of Medicine. His primary research interests are endoscopic treatment of gastrointestinal diseases and elucidation of pathological mechanisms.

References

1. Nishizawa T, Suzuki H. Mechanisms of *Helicobacter pylori* antibiotic resistance and molecular testing. *Front Mol Biosci*. 2014;1:19. <https://doi.org/10.3389/fmolb.2014.00019>
2. Rimbara E, Suzuki M, Matsui H, Nakamura M, Morimoto M, Sasakawa C, et al. Isolation and characterization of *Helicobacter suis* from human stomach. *Proc Natl Acad Sci U S A*. 2021;118:e2026337118. <https://doi.org/10.1073/pnas.2026337118>
3. Nakamura M, Øverby A, Michimae H, Matsui H, Takahashi S, Mabe K, et al. PCR analysis and specific immunohistochemistry revealing a high prevalence of non-*Helicobacter pylori* Helicobacters in *Helicobacter pylori*-negative gastric disease patients in Japan: high susceptibility to an Hp eradication regimen. *Helicobacter*. 2020;25:e12700. <https://doi.org/10.1111/hel.12700>
4. Shafaie S, Kaboosi H, Peyravii Ghadikolaii F. Prevalence of non *Helicobacter pylori* gastric Helicobacters in Iranian dyspeptic patients. *BMC Gastroenterol*. 2020;20:190. <https://doi.org/10.1186/s12876-020-01331-x>
5. Joosten M, Lindén S, Rossi M, Tay AC, Skoog E, Padra M, et al. Divergence between the highly virulent zoonotic pathogen *Helicobacter heilmannii* and its closest relative, the low-virulence "*Helicobacter ailurogastricus*" sp. nov. *Infect Immun*. 2015;84:293–306. <https://doi.org/10.1128/IAI.01300-15>

Address for correspondence: Hidekazu Suzuki, Division of Gastroenterology and Hepatology, Department of Internal Medicine, Tokai University School of Medicine, 143 Shimokasuya, Isehara, Kanagawa, 259-1193, Japan; email: hsuzuki@tokai.ac.jp

Harbor Porpoise Deaths Associated with *Erysipelothrix rhusiopathiae*, the Netherlands, 2021

Lonneke L. IJsseldijk, Lineke Begeman, Birgitta Duim, Andrea Gröne, Marja J.L. Kik, Mirjam D. Klijnstra, Jan Lakemeyer, Mardik F. Leopold, Bas B. Oude Munnink, Mariel ten Doeschate, Linde van Schalkwijk, Aldert Zomer, Linda van der Graaf-van Bloois, Els M. Broens

Author affiliations: Utrecht University, Utrecht, the Netherlands (L.L. IJsseldijk, B. Duim, A. Gröne, M.J.L. Kik, J. Lakemeyer, M. ten Doeschate, L. van Schalkwijk, A. Zomer, L. van der Graaf-van Bloois, E.M. Broens); Erasmus University Medical Center, Rotterdam, the Netherlands (L. Begeman, B.B. Oude Munnink); Wageningen Food Safety Research, Wageningen, the Netherlands (M.D. Klijnstra); Wageningen Marine Research, Den Helder, the Netherlands (M.F. Leopold)

DOI: <https://doi.org/10.3201/eid2903.221698>

In August 2021, a large-scale mortality event affected harbor porpoises (*Phocoena phocoena*) in the Netherlands. Pathology and ancillary testing of 22 animals indicated that the most likely cause of death was *Erysipelothrix rhusiopathiae* infection. This zoonotic agent poses a health hazard for cetaceans and possibly for persons handling cetacean carcasses.

Erysipelothrix bacteria cause infections in humans and other species after contact with infected animals or environmental sources (1). Illness ranges from mild to systemic, which can include septicemia and endocarditis. *Erysipelothrix* can survive for long periods in the environment, including marine ecosystems (1) associated with marine fish, mollusks, and crustaceans. *Erysipelothrix* infection affects captive and

free-ranging crustaceans and is linked to fatal sepsis (2). To our knowledge, reports of large-scale mortality events caused by *Erysipelothrix* infection in marine mammals are absent from the literature, and *Erysipelothrix* has not been detected in stranded porpoises along the Netherlands coastline since the start of our harbor porpoise stranding research program in 2008.

At the end of August 2021, a total of 190 dead harbor porpoises (*Phocoena phocoena*) were found on Dutch Wadden islands; the annual average for stranded harbor porpoises on the entire Dutch coastline is 600. No anthropogenic activities in the southern or central North Sea that could explain this mortality event were reported to the government of the Netherlands in the 4–6 weeks before the event.

Most porpoises were found in an advanced state of decomposition. Twenty-two animals were collected for examination at the Faculty of Veterinary Medicine of Utrecht University (Appendix Table 1, <https://wwwnc.cdc.gov/EID/article/29/4/22-1698-App1.pdf>). We immediately necropsied 2, and the rest were temporarily frozen pending postmortem investigation and ancillary testing.

Because of advanced decomposition, we could perform only gross pathologic examinations and sampling for ancillary testing, following a standardized international protocol (3). Adult female porpoises were mostly in good to moderate nutritional condition with mild to moderate parasitic infections of various organs and had been reproductively active

(Appendix Table 1). Of the 21 stomachs examined (1 was not examined because of gross damage caused by scavengers), none contained marine debris; 10 contained the remains of a few prey, reflecting nonrecent food intake, and the remaining stomachs were empty.

Samples from 3 porpoises with gross changes (mammary gland, lung, spinal cord) were cultured on blood agar (bioTrading, <https://biotrading.com>) at 37°C for 48 h. Culture results were positive for *Erysipelothrix rhusiopathiae*. Subsequently, we tested liver samples from 21 animals for *E. rhusiopathiae*; and 16 were positive (Appendix Table 2). To investigate the relatedness of isolates, genomes of 18 isolates were sequenced by using Illumina NextSeq (<https://www.illumina.com>) and assembled by using SPAdes version 3.14.1 (4); we included 11 publicly available reference genomes from different *E. rhusiopathiae* clades (5). A core genome alignment was made with Parsnp version 1.2 (6) and visualized by using iTol version 4 (7).

Genomes from this study were phylogenetically positioned between clade 2 *E. rhusiopathiae* reference genomes and formed 2 distinct clusters showing ≈3,400 single-nucleotide polymorphism (SNP) differences and limited diversity of <6 SNPs within the clusters (Figure). That pattern suggests dissemination of 2 clonal lineages of *E. rhusiopathiae*, either through exposure to a common source or contact between individuals.

Virology tests on 14 fecal, 15 blood, and 17 spleen samples and metagenomic sequencing with VirCapSeq-VERT (8) revealed no virus sequences of

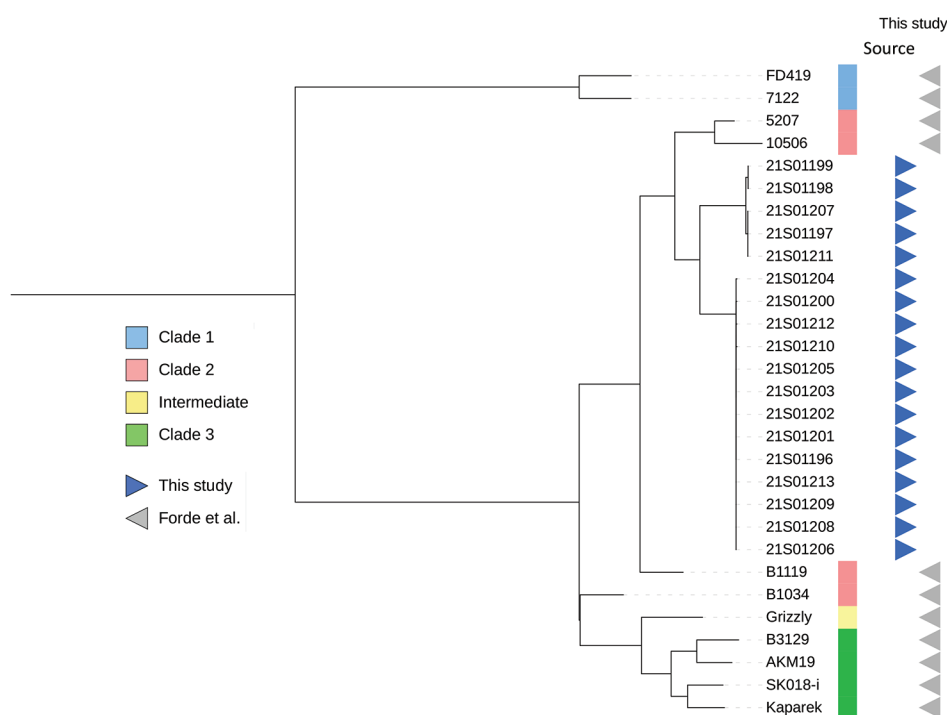


Figure. Phylogenetic tree of *Erysipelothrix rhusiopathiae* from stranded harbor porpoises, the Netherlands, 2021, compared with reference genomes described by Forde et al. (5). Branches are square root transformed. Detailed information for each sample is provided in Appendix Table 3 (<https://wwwnc.cdc.gov/EID/article/29/4/22-1698-App1.pdf>).

interest. In addition, we tested 20 lung and 20 brain samples for influenza A virus, paramyxoviruses (including morbilliviruses), coronaviruses (including SARS-CoV-2), and herpesviruses. Only 2 brain samples tested positive for *P. phocoena* alphaherpesvirus (Appendix Table 1), described as an incidental cause of death in porpoises (9). Our results indicate that viruses were an unlikely factor in this mortality event.

We pooled 20 stomach content samples and 21 liver samples in triplicate and analyzed them with a Liquid Chromatograph Triple Quadrupole Mass Spectrometer (LC-MS/MS) (McCrone Associates, <https://www.mccrone.com>) for domoic acid, saxitoxins, tetrodotoxin, and lipophilic marine toxins. Only saxitoxin was detected; it was in 1 pooled liver sample (estimated concentration 15 µg/kg). Subsequently, we analyzed livers individually, and saxitoxin was not confirmed in any of the individual samples. We therefore conclude that harmful algae were an unlikely factor in this mortality event.

Gross pathologic assessment revealed a moderate to good body condition for most porpoises, but none had recently fed. This finding suggests a subacute cause of death from sudden and excessive disease. No clinically relevant viruses were detected. Phycotoxins were detected in a limited number of porpoises. In contrast, *E. rhusiopathiae* was isolated from most investigated porpoises. Therefore, we consider *E. rhusiopathiae* to be the most likely cause of death. Advanced autolysis of the carcasses made detection of distinctive lesions associated with *Erysipelothrix* infection impossible. The low number of SNPs differing between isolates suggests common exposure, possibly a food source, transmission between porpoises, or both.

Our results draw attention to possibly increased cetacean susceptibility to *E. rhusiopathiae*, to new or emerging sources of *Erysipelothrix* in the marine environment, or both. *Erysipelothrix* remains viable in a carcass up to 12 days in direct sunlight, up to 4 months in putrefied flesh, and up to 9 months in a buried carcass (10). This new emerging source and the long survival time in carcasses demonstrates a need for having only trained personnel handle stranded animals, proper disposal of carcasses, and increased awareness for the potential presence and transmission of this zoonotic bacterium among cetaceans.

Acknowledgments

We thank all volunteers and organizations of the Dutch Stranding Network for their tremendous efforts and work to document stranded porpoises during the event. Necropsies were assisted by Louis van den Boom, Natashja Ennen-Buijs, Olle Juch, Darryl Leydekkers,

Immelle Coenen Morales, Jan Mosterd, Eva Schotanus, and Ruby Wagenveld. We also thank Judith van den Brand for her input in the discussions of the ancillary testing. Virology was conducted at Erasmus MC, with special thanks to Marco van de Bildt, Irina Chestakova, Marjan Boter, Babette Weller, Reina Sikkema, and Marion Koopmans. Bacteriology was conducted at the Veterinary Microbiological Diagnostic Center, for which we thank all staff involved. Stomach investigations were conducted at Wageningen Marine Research with the help of Guido Keijl and Eva Schotanus. Algae toxin research was carried out by Wageningen Food Safety Research with the help of Dominique van der Horst.

The research was financed by the Ministry of Agriculture, Nature and Food Quality (project no. 1400012118), for which we are especially grateful for the help of Anne-Marie Svoboda and Sandra van der Graaf.

About the Author

Dr. IJsseldijk is assistant professor at the Division of Pathology, Department of Biomolecular Health Sciences, Faculty of Veterinary Medicine, Utrecht University. Her primary research interests focus on marine mammal health and conservation.

References

1. Wang Q, Chang BJ, Riley TV. *Erysipelothrix rhusiopathiae*. *Vet Microbiol*. 2010;140:405–17. <https://doi.org/10.1016/j.vetmic.2009.08.012>
2. Ceccolini ME, Wessels M, Macgregor SK, Deaville R, Perkins M, Jepson PD, et al. Systemic *Erysipelothrix rhusiopathiae* in seven free-ranging delphinids stranded in England and Wales. *Dis Aquat Organ*. 2021;145:173–84. <https://doi.org/10.3354/dao03609>
3. IJsseldijk LL, Brownlow AC, Mazzarioli S, editors. Best practice for cetacean post mortem investigation and tissue sampling. Joint ACCOBAMS and ASCOBANS document. Stralsund, Germany: Agreement for the Conservation of Cetaceans of the Baltic Sea, Mediterranean Sea and Contiguous Atlantic Area (ACCOBAMS); Agreement on the Conservation of Small Cetaceans of the Baltic, North East Atlantic, Irish and North Seas (ASCOBANS); 2019 [cited 2022 Nov 7]. https://www.ascobans.org/sites/default/files/document/ascobans_ac25_inf3.2_rev1_best-practice-cetacean-post-mortem-investigation.pdf
4. Bankevich A, Nurk S, Antipov D, Gurevich AA, Dvorkin M, Kulikov AS, et al. SPAdes: a new genome assembly algorithm and its applications to single-cell sequencing. *J Comput Biol*. 2012;19:455–77. <https://doi.org/10.1089/cmb.2012.0021>
5. Forde T, Biek R, Zadoks R, Workentine ML, De Buck J, Kutz S, et al. Genomic analysis of the multi-host pathogen *Erysipelothrix rhusiopathiae* reveals extensive recombination as well as the existence of three generalist clades with wide geographic distribution. *BMC Genomics*. 2016;17:461. <https://doi.org/10.1186/s12864-016-2643-0>
6. Treangen TJ, Ondov BD, Koren S, Phillippy AM. The Harvest suite for rapid core-genome alignment and visualization of

- thousands of intraspecific microbial genomes. *Genome Biol.* 2014;15:524. <https://doi.org/10.1186/s13059-014-0524-x>
7. Letunic I, Bork P. Interactive Tree Of Life (iTOL) v4: recent updates and new developments. *Nucleic Acids Res.* 2019;47(W1):W256-9. <https://doi.org/10.1093/nar/gkz239>
 8. Briese T, Kapoor A, Mishra N, Jain K, Kumar A, Jabado OJ, et al. Virome capture sequencing enables sensitive viral diagnosis and comprehensive virome analysis. *MBio.* 2015;6:e01491-15. <https://doi.org/10.1128/mBio.01491-15>
 9. van Elk C, van de Bildt M, van Run P, de Jong A, Getu S, Verjans G, et al. Central nervous system disease and genital disease in harbor porpoises (*Phocoena phocoena*) are associated with different herpesviruses. *Vet Res (Faisalabad).* 2016;47:28. <https://doi.org/10.1186/s13567-016-0310-8>
 10. Brooke CJ, Riley TV. *Erysipelothrix rhusiopathiae*: bacteriology, epidemiology and clinical manifestations of an occupational pathogen. *J Med Microbiol.* 1999;48:789-99. <https://doi.org/10.1099/00222615-48-9-789>

Address for correspondence: Els M. Broens, Department of Biomolecular Health Sciences, Faculty of Veterinary Medicine, Utrecht University, Yalelaan 1, 3584 TD, Utrecht, the Netherlands; email: e.m.broens@uu.nl

Powassan Virus Infection Detected by Metagenomic Next-Generation Sequencing, Ohio, USA

Marjorie Farrington,¹ Jamie Elenz, Matthew Ginsberg, Charles Y. Chiu, Steve Miller, Scott F. Pangonis

Author affiliations: Children's Hospital Medical Center of Akron, Akron, Ohio, USA (M. Farrington, M. Ginsberg, S.F. Pangonis); Columbiana County Health District, Lisbon, Ohio, USA (J. Elenz); University of California, San Francisco, California, USA (C.Y. Chiu, S. Miller)

DOI: <https://doi.org/10.3201/eid2904.221005>

We describe a 4-year-old male patient in Ohio, USA, who had encephalitis caused by Powassan virus lineage 2. Virus was detected by using metagenomic next-generation sequencing and confirmed with IgM and plaque reduction neutralization assays. Clinicians should recognize changing epidemiology of tickborne viruses to enhance encephalitis diagnosis and management.

¹Current affiliation: St. Louis Children's Hospital, St. Louis, Missouri, USA.

Powassan virus (POWV) is a tickborne flavivirus that causes encephalitis with severe neurologic sequelae (1). In the United States, POWV infections occur primarily in the Northeast and Great Lakes regions (2). We report a case of human POWV infection in Ohio.

A 4-year-old boy was brought to the emergency department because of fever, vomiting, and convulsive status epilepticus. He had no neurologic history or developmental delays. Mosquito and tick exposure history was substantial, although no engorged ticks were recently removed. The patient had not traveled outside of Ohio.

Results of a computed tomography scan of the head were unremarkable. We initiated intravenous vancomycin, ceftriaxone, and acyclovir. Magnetic resonance imaging showed left temporal pulvinar and thalamic T2-weighted fluid attenuated inversion recovery hyperintensity and restricted diffusion; an electroencephalogram showed lateralized periodic discharges. Cerebrospinal fluid (CSF) was collected by lumbar puncture, revealing a leukocyte count of 44 cells/ μ L (reference range <10 cells/ μ L) of which 85% were lymphocytes; glucose and protein levels were normal. The patient's BIO-FIRE FILMARRAY Meningitis/Encephalitis PCR panel (bioMérieux, <https://www.biomerieux-diagnostics.com>) was negative (Table). He was admitted to the pediatric intensive care unit, and seizures were controlled with anticonvulsants. Tests for infectious and noninfectious causes of meningitis and encephalitis were negative (Table). Antimicrobial drugs were discontinued after negative bacterial cultures were observed. Acyclovir was discontinued after PCR of CSF for herpes simplex virus was negative.

On hospitalization day 5, severe neurologic decline developed, and brain magnetic resonance imaging was repeated. New areas of T2 hyperintensity and restricted diffusion and thalamic microhemorrhages in a rhombencephalitis pattern were identified. Lumbar puncture was repeated, revealing considerable lymphocytic pleocytosis and elevated protein (156 mg/dL). Leading diagnoses were autoimmune encephalitis and acute necrotizing encephalopathy of childhood (ANEC). The patient exhibited severe encephalopathy, nystagmus, right hemiparesis, and diffuse hypertonia. He was treated with high dose methylprednisolone, plasmapheresis, and intravenous immunoglobulins.

Genetic testing for familial ANEC type 1 was negative. We sent CSF obtained on hospital day 5 to the University of California San Francisco for metagenomic

EID cannot ensure accessibility for supplementary materials supplied by authors. Readers who have difficulty accessing supplementary content should contact the authors for assistance.

Harbor Porpoise Deaths Associated with *Erysipelothrix rhusiopathiae*, the Netherlands, 2021

Appendix

Appendix Table 1. Overview of biological, pathological and relevant ancillary testing data of investigated harbor porpoises*

Case ID	Stranding date	Stranding location	Age	Sex	DCC	NCC	Mass (kg)	TL (cm)	Repro assessment	Erysipelothrix	Phocoena phocoena alpha herpesvirus	Phycotoxins
UT1877	23-8-2021	Schiermonnikoog	A	M	3	5	27	130	Adult male	positive	NA	Pooled samples stomach and liver negative
UT1878	26-8-2021	Schiermonnikoog	A	F	4	5	35	154	Large CL but no embryo detected, suspect aborted	positive	NA	
UT1880	28-8-2021	Ameland	A	M	4	3	32	138	Adult male	positive	negative	Pooled samples stomach and liver negative
UT1881	28-8-2021	Ameland	J	F	4	2	19	122	Juvenile female	positive	positive (brain)	
UT1882	28-8-2021	Ameland	A	F	4	2	23	136	Scavenged	positive	negative	
UT1883	28-8-2021	Ameland	A	F	4	3	44	157	Scavenged	positive	negative	
UT1884	28-8-2021	Ameland	A	F	4	2	42	153	Lactating and pregnant	positive	negative	
UT1885	28-8-2021	Ameland	A	F	4	1	35	144	Pregnant	negative	negative	Pooled samples stomach and liver negative
UT1886	28-8-2021	Ameland	A	M	4	6	22	141	Adult male	positive	negative	
UT1887	28-8-2021	Ameland	A	F	4	1	41	153	Lactating, extended uterus, no embryo detected	positive	positive (brain)	
UT1888	28-8-2021	Ameland	A	F	4	1	32	153	Cervix extended, further scavenged hampering assessment	positive	negative	
UT1889	28-8-2021	Ameland	A	M	4	5	29	134	Adult male	negative	negative	
UT1890	28-8-2021	Ameland	A	F	4	4	34	152	Lactating, CL left, no embryo detected	positive	negative	
UT1891	28-8-2021	Schiermonnikoog	A	F	4	1	51	165	Pregnant	negative	negative	Pooled sample stomach negative; pooled samples liver positive for
UT1892	27-8-2021	Schiermonnikoog	A	F	4	1	44	154	Resting	negative	negative	
UT1893	28-8-2021	Terschelling	A	F	4	6	44	163	Lactating and pregnant	positive	negative	
UT1894	28-8-2021	Terschelling	A	F	4	2	27	147	Lactating and pregnant	positive	negative	
UT1895	28-8-2021	Terschelling	A	F	4	4	33	152	Pregnant	positive	negative	
UT1896	28-8-2021	Terschelling	A	F	4	4	35	164	Resting	positive	negative	

Case ID	Stranding date	Stranding location	Age	Sex	DCC	NCC	Mass (kg)	TL (cm)	Repro assessment	Erysipelothrix	Phocoena phocoena alphaherpesvirus	Phycotoxins
UT1897	28-8-2021	Terschelling	A	F	4	2	44	162	Lactating and pregnant	positive	negative	SXT (15 µg/kg)
UT1898	28-8-2021	Terschelling	A	F	4	3	37	163	Scavenged	negative	negative	
UT1899	28-8-2021	Terschelling	J	M	4	4	13	114	Juvenile male	NA	negative	NA

*Dates are DD-MM-YYYY. Age: A = adult, J = Juvenile; Sex: M = Male, F = Female; DCC: Decomposition Condition Code, following L.L. IJsseldijk et al., unpub. data, <https://eprints.gla.ac.uk/270811>; NCC: Nutritional Condition Code, following L.L. IJsseldijk et al., unpub. data. NA = Not Available; STX = saxitoxins

Appendix Table 2. Detailed results of bacteriological culture

Bacteriology		
ID	Cultured organs	Culture results
UT1877	Liver	Liver: 1. Mild amount of <i>Proteus mirabilis</i> , 2. Moderate amount of <i>E. rhusiopathiae</i>
UT1878	Liver and lung	Liver: Moderate amount of <i>E. rhusiopathiae</i> . Lung: 1. Severe amount of <i>Clostridium perfringens</i> , 2. Severe amount of <i>E. rhusiopathiae</i> , 3. Mixed culture of 3 bacteria, mild amount
UT1880	Liver	Liver: Moderate amount of <i>E. rhusiopathiae</i>
UT1881	Liver	Liver: 1. Mild amount of <i>E. rhusiopathiae</i> , 2. Mixculture of 2 bacteria, mild amount
UT1882	Liver	Liver: 1. Mild amount of <i>E. rhusiopathiae</i> , 2. Mild amount of anaerob mixed culture
UT1883	Liver	Liver: Moderate amount of <i>E. rhusiopathiae</i>
UT1884	Liver	Liver: 1. Moderate amount of <i>E. rhusiopathiae</i> , 2. Mild amount of mixed culture of 2 bacteria
UT1885	Liver	Liver: Mild amount of anaerob mixed culture
UT1886	Liver	Liver: 1. Moderate amount of <i>E. rhusiopathiae</i> , 2. Mild amount of anaerob mixed culture
UT1887	Liver	Liver: 1. Moderate amount of <i>E. rhusiopathiae</i> , 2. Mild amount of anaerob mixed culture
UT1888	Liver	Liver: 1. Moderate amount of <i>E. rhusiopathiae</i> , 2. Mild amount of anaerob mixed culture
UT1889	Liver	Liver: Mild amount of anaerob mixed culture
UT1890	Liver	Liver: Moderate amount of <i>E. rhusiopathiae</i>
UT1891	Liver	Liver: Mild amount of anaerob mixed culture
UT1892	Liver	Liver: Mild amount of anaerob mixed culture
UT1893	Liver	Liver: 1. Moderate amount of <i>E. rhusiopathiae</i> , 2. Mild amount of anaerob mixed culture
UT1894	Liver and mammary gland	Liver: Mild amount of <i>Paenicostridium sordelli</i> . Mammary gland: 1. Moderate amount of <i>E. rhusiopathiae</i> , 2. Mixed culture of 2 bacteria
UT1895	Liver and spinal cord (swab)	Liver: 1. Mild amount of anaerob mixed culture, 2. Mild amount of <i>E. rhusiopathiae</i> . Swab CNS: 1. Moderate amount of <i>E. rhusiopathia</i> , 2. Mixed culture.
UT1896	Liver	Liver: 1. Moderate amount of <i>E. rhusiopathiae</i> , 2. Mild amount of anaerob mixed culture
UT1897	Liver	Liver: Moderate amount of <i>E. rhusiopathiae</i>
UT1898	Liver	Liver: no bacteria cultured
UT1899	NA	NA

NA, not available

Appendix Table 3. Detailed information for each sample

ASSEMBLY_NAME	VMDC ID	ASSEMBLY_ACC	STUDY_ID	SAMPLE_ID
21S01196	221083103101	GCA_947039675	PRJEB56391	ERS13511510
21S01197	221093006801	GCA_947041805	PRJEB56391	ERS13511511
21S01198	221093006701	GCA_947037435	PRJEB56391	ERS13511512
21S01199	221101910801	GCA_947040135	PRJEB56391	ERS13511513
21S01200	221101911001	GCA_947037175	PRJEB56391	ERS13511514
21S01201	221101911101	GCA_947037165	PRJEB56391	ERS13511515
21S01202	221101911201	GCA_947039825	PRJEB56391	ERS13511516
21S01203	221101911301	GCA_947038085	PRJEB56391	ERS13511517
21S01204	221101911401	GCA_947040235	PRJEB56391	ERS13511518
21S01205	221101911601	GCA_947037575	PRJEB56391	ERS13511519
21S01206	221101911801	GCA_947040195	PRJEB56391	ERS13511520
21S01207	221101911901	GCA_947038325	PRJEB56391	ERS13511521
21S01208	221101912101	GCA_947038715	PRJEB56391	ERS13511522
21S01209	221101912401	GCA_947038205	PRJEB56391	ERS13511523
21S01210	221101912601	GCA_947038705	PRJEB56391	ERS13511524
21S01211	221101912701	GCA_947037675	PRJEB56391	ERS13511525
21S01212	221101912801	GCA_947038755	PRJEB56391	ERS13511526
21S01213	221101910901	GCA_947038735	PRJEB56391	ERS13511527