

This work includes multilocus sequence typing profiles publicly available on BIGSdb-*Listeria* (<https://bigsdbs.pasteur.fr/listeria>).

This work was developed within the framework of agreements between Institut Pasteur and the University of Costa Rica, and between Institut Pasteur and Instituto Tecnológico de Costa Rica (amendment no.1 to the memorandum of understanding dated February 21, 2018), and supported by Institut Pasteur, Inserm, Santé Publique France, the government of France Investissement d'Avenir program Laboratoire d'Excellence Integrative Biology of Emerging Infectious Diseases (no. ANR-10-LABX-62-IBRID), the Vice Rectory of Research of the Instituto Tecnológico de Costa Rica (research project no. 1510160), and the Vice Rectory of Research at the University of Costa Rica (project nos. B2104 and B9026). Travel funds for M.G.Z. were provided by the Instituto Tecnológico de Costa Rica and the Consejo Nacional para Investigaciones Científicas y Tecnológicas (CONICIT). Travel funds for M.R.S. were provided by the Institut Français.

About the Author

Ms. Giralt-Zúñiga is currently a PhD student at the Molecular Microbiology Department of the Institute for Biology, Humboldt-Universität zu Berlin, Germany. Her research interests focus on infectious diseases and enteric pathogens.

References

- Swaminathan B, Gerner-Smidt P. The epidemiology of human listeriosis. *Microbes Infect.* 2007;9:1236–43. <https://doi.org/10.1016/j.micinf.2007.05.011>
- Moura A, Criscuolo A, Pouseele H, Maury MM, Leclercq A, Tarr C, et al. Whole genome-based population biology and epidemiological surveillance of *Listeria monocytogenes*. *Nat Microbiol.* 2016;2:16185. <https://doi.org/10.1038/nmicrobiol.2016.185>
- Chenal-Francisque V, Lopez J, Cantinelli T, Caro V, Tran C, Leclercq A, et al. Worldwide distribution of major clones of *Listeria monocytogenes*. *Emerg Infect Dis.* 2011;17:1110–2. <https://doi.org/10.3201/eid1706.101778>
- Maury MM, Tsai YH, Charlier C, Touchon M, Chenal-Francisque V, Leclercq A, et al. Uncovering *Listeria monocytogenes* hypervirulence by harnessing its biodiversity. *Nat Genet.* 2016;48:308–13. <https://doi.org/10.1038/ng.3501>
- Schmid D, Allerberger F, Huhulescu S, Pietzka A, Amar C, Kleta S, et al. Whole genome sequencing as a tool to investigate a cluster of seven cases of listeriosis in Austria and Germany, 2011–2013. *Clin Microbiol Infect.* 2014;20:431–6. <https://doi.org/10.1111/1469-0691.12638>
- Calvo-Arrieta K, Matamoros-Montoya K, Arias-Echandi ML, Huete-Soto A, Redondo-Solano M. Presence of *Listeria monocytogenes* in ready-to-eat meat products sold at retail stores in Costa Rica and analysis of contributing factors. *J Food Prot.* 2021;84:1729–40. <https://doi.org/10.4315/JFP-21-020>
- Posada-Izquierdo GD, Mazón-Villegas B, Redondo-Solano M, Huete-Soto A, Viquez-Barrantes D, Valero A, et al. Modelling the effect of salt concentration on the fate of *Listeria monocytogenes* isolated from Costa Rican fresh cheeses. *Foods.* 2021;10:1722. <https://doi.org/10.3390/foods10081722>
- Leclercq A, Chenal-Francisque V, Dieye H, Cantinelli T, Drali R, Brisse S, et al. Characterization of the novel *Listeria monocytogenes* PCR serogrouping profile IVb-v1. *Int J Food Microbiol.* 2011;147:74–7. <https://doi.org/10.1016/j.ijfoodmicro.2011.03.010>
- Castro H, Jaakkonen A, Hakkinen M, Korkeala H, Lindström M. Occurrence, persistence, and contamination routes of *Listeria monocytogenes* genotypes on three Finnish dairy cattle farms: a longitudinal study. *Appl Environ Microbiol.* 2018;84:e02000-17. <https://doi.org/10.1128/AEM.02000-17>
- Buchanan RL, Gorris LGM, Hayman MM, Jackson TC, Whiting RC. A review of *Listeria monocytogenes*: an update on outbreaks, virulence, dose-response, ecology, and risk assessments. *Food Control.* 2017;75:1–13. <https://doi.org/10.1016/j.foodcont.2016.12.016>

Address for correspondence. Marc Lecuit or Javier Pizarro-Cerda, 28 Rue du Docteur Roux, 75724 Paris CEDEX 15, France; email: marc.lecuit@pasteur.fr or javier.pizarro-cerda@pasteur.fr

Human *Taenia martis* Neurocysticercosis, Switzerland

Valentin K. Steinsiepe, Marie-Therese Ruf, Marco Rossi, Claudia Fricker-Feer, Danijela Kolenc, Brigitte Suter Buser, Maura Concu, Andreas Neumayr, Ulf C. Schneider

Author affiliations: Cantonal Hospital of Lucerne, Lucerne, Switzerland (V.K. Steinsiepe, M. Rossi, C. Fricker-Feer, D. Kolenc, U.C. Schneider); Swiss Tropical and Public Health Institute, Allschwil, Switzerland (M.-T. Ruf, M. Concu, A. Neumayr); University of Basel, Basel, Switzerland (M.-T. Ruf, M. Concu, A. Neumayr)

DOI: <https://doi.org/10.3201/eid2912.230697>

Neurocysticercosis is almost exclusively caused by *Taenia solium* tapeworms. We describe a case of neurocysticercosis in Switzerland caused by infection with *Taenia martis*, the marten tapeworm, and review all 5 published cases of human infection with the marten tapeworm. In epidemiologically nonplausible cases of neurocysticercosis, zoonotic spillover infections should be suspected.

Neurocysticercosis is a zoonotic, parasitic, central nervous system infection almost exclusively caused by the larvae of *Taenia solium*, the pork tapeworm (1). In a few exceptional cases, neurocysticercosis in humans is not caused by *T. solium* but by other zoonotic *Taenia* species, representing rare spillover infections from distant ecologic niches (Appendix Table, <https://wwwnc.cdc.gov/EID/article/29/12/23-0697-App1.pdf>). In this article, we describe a rare case of *T. martis* neurocysticercosis in a woman in Switzerland.

A woman 55 years of age sought care at the emergency department of the Cantonal Hospital of Lucerne (Lucerne, Switzerland) because of a 3-week history of progressive transient numbness and convulsions of her left hand. Her medical history was unremarkable. Clinical examination revealed disorientation to time, a pronator drift of the left arm, hypoesthesia of the left extremities, and a tactile neglect toward the left side. A comprehensive metabolic panel and a complete blood count showed no major abnormalities. Computed tomography of the brain revealed a 12 × 14 mm mass in the right postcentral gyrus with strong ring-enhancement and perifocal edema (Appendix Figure 1). We started the patient on levetiracetam and admitted her for further investigation.

Results of computed tomography of the thorax and abdomen were unremarkable. Magnetic resonance imaging (MRI) (Appendix Figure 2) showed no restriction on diffusion-weighted imaging. After starting the patient on dexamethasone, we removed the lesion through a right parietal craniotomy. Post-operative MRI confirmed complete resection. We gradually discontinued dexamethasone and discharged the patient 6 days after the operation.

The specimen consisted of a cyst with a thick wall and with no macroscopically discernible content. Histologic analysis revealed a singular membrane, compatible with a helminthic parasite, and an abscessing inflammation at the border (Figure). Results of immunohistochemical tests, eubacterial 16S PCR, and whole-genome sequencing were negative, as was serologic screening for *Echinococcus* spp. However, Western blot for cysticercosis, which uses *T. solium* IgG (LDBIO Diagnostics, <https://www.ldbiodiagnostics.com>), revealed a weak band pattern suggestive of an infection with *T. solium*. We contacted the Swiss Tropical and Public Health Institute, which raised the issue of missing epidemiologic plausibility, given that the patient had never traveled to a *T. solium*-endemic area. The possibility of zoonotic spillover infection was considered and MRI of the whole spine, ocular ultrasound, and stool investigations recommended to exclude additional lesions and taeniasis. We analyzed the resected neurocysticercus by using a pan-helminthic PCR and sequencing of the cestode- and nematode-specific cytochrome c oxidase subunit 1 (*cox1*) gene (2), which revealed 100% sequence identity with *Taenia martis*, the marten tapeworm (GeneBank accession no. OQ536306).

Because of the unclear date of infection, the unknown proliferation rate of the parasite in humans, and the possibility of undetectable lesions, we treated the patient with albendazole and praziquantel, analogous to treatment for *T. solium* neurocysticercosis, assuming similar susceptibility of the parasite (3). Three months after the operation, the patient showed no neurologic deficits and no new focal seizures.

The definitive hosts of *T. martis* tapeworms are martens and other mustelids. *T. martis* tapeworms

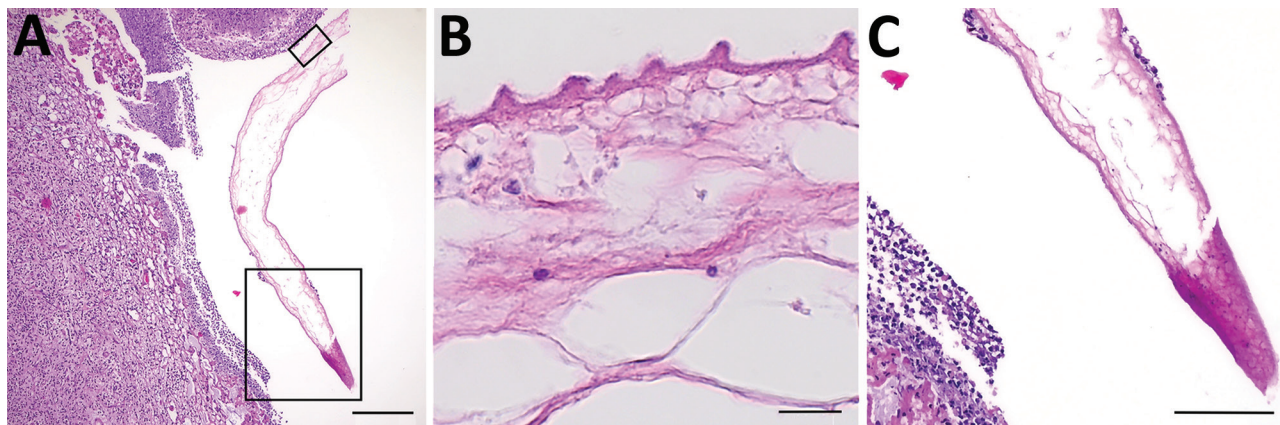


Figure. Histologic sections of resected *Taenia martis* metacestode from a patient in Switzerland. A) Cross-section through the excised tissue revealed strong infiltration surrounding a structure suggestive of parasitic origin. Boxed areas are shown in a higher magnification in panels B and C. B, C) The metacestode's cyst wall, showing the warty appearance (B) characteristic of tapeworm metacestodes' tegument (3,4). Hematoxylin and eosin stain. Scale bars indicate 200 μ m (A), 10 μ m (B), and 100 μ m (C).

Table. Overview of published cases of human *Taenia martis* infections

Authors (year of publication)	Country	Patient age, y/sex	Chief complaint	Location of lesion	False-positive serologic assays	Treatment
Eberwein et al. (2013) (6)	Germany	43/F	Flashing lights and paracentral scotoma	Left eye	No	Albendazole 400 mg 2×/d, dexamethasone 20 mg/d for 8 d, surgical excision
Brunet et al. (2015) (7)	France	44/F	Right hemiparesis and aphasia	Left temporal lobe	<i>T. solium</i>	Surgical excision, praziquantel 50 mg/kg for 15 d, albendazole 15 mg/kg for 1 mo, corticosteroids 1 mg/kg (sic)
Koch et al. (2016) (8)	Germany	70/F	Drop in visual acuity	Left eye	No	Surgical excision, albendazole 400 mg 2×/d for 7 d
Rudelius et al. (2017) (9)	Germany	36/F	Ascites	Pouch of Douglas	<i>Echinococcus granulosus</i>	Surgical excision, albendazole 400 mg 2×/d for 4 weeks
Mueller et al. (2020) (10)	Germany	24/F	Lower abdominal pain and dysmenorrhea	Pouch of Douglas	<i>E. multilocularis</i> , <i>T. solium</i> , <i>Diriofilaria immitis</i> .	Surgical excision; antiparasitic treatment refused by patient
Steinsiepe et al. (2023) (this report)	Switzerland	55/F	Focal epileptic seizures	Right parietal lobe	<i>T. solium</i>	Surgical excision, praziquantel 50 mg/kg/d for 14 d, albendazole 15 mg/kg/d for 28 d, corticosteroids

have been found in the intestines of 36% of stone martens (*Martes foina*) in southwest Germany but also parasitize other mustelids (4,5). Stone martens occur throughout Europe and Central Asia. The natural intermediate hosts of *T. martis* tapeworms are small rodents, which develop cysticerci in the pleural and peritoneal cavities. The infection in this patient suggests an accidental fecal-oral transmission, although it remains unclear when and how she came into contact with marten droppings.

Diagnosed human infections with *T. martis* tapeworms are limited to 5 cases reported from Germany and France (Table; Appendix Figure 3) (6–10). Those cases were 2 peritoneal infections, 2 eye infections, and 1 central nervous system infection, all with single lesions occurring in immunocompetent women. Of note, an increased susceptibility to various *Taenia* spp. tapeworms dependent on sex and hormone status has been described in animals (5). All 6 patients, including ours, lived in rural villages, 5 (including ours) grew their own vegetables, and at least 3 (including ours) had frequent marten sightings around their homes. Similar to what other authors reported, we did find cross-reactivity with a *T. solium*-specific assay.

All but 1 of the patients described in the published cases received antiparasitic treatment; the only untreated case was in a patient who refused medical treatment (10). None of the published cases reported recurrence or emergence of additional lesions.

Neurocysticercosis may be caused by *Taenia* spp. other than *T. solium* tapeworms. Cases in which an infection with *T. solium* is epidemiologically not plausible should be investigated for zoonotic spillover infections (in Central Europe, specifically

infection with *T. martis* should be considered). Such cases are probably underrepresented in the literature, given the high prevalence of stone martens, their high infection rate with *T. martis* tapeworms, and the possibility of false positives of available, cross-reactive *T. solium*- and *Echinococcus* spp.-specific serologic assays. If adequate material is available, a panhelminthic PCR with *cox1* sequencing is highly recommended.

About the Author

Mr. Steinsiepe is a resident at the Department of Neurosurgery at Lucerne Cantonal Hospital, Switzerland. His primary research interest is the interface of general medicine, clinical neurology, and neurosurgery.

References

- Nash TE, Garcia HH. Diagnosis and treatment of neurocysticercosis. *Nat Rev Neurol*. 2011;7:584–94. <https://doi.org/10.1038/nrneurol.2011.135>
- Bowles J, Blair D, McManus DP. Genetic variants within the genus *Echinococcus* identified by mitochondrial DNA sequencing. *Mol Biochem Parasitol*. 1992;54:165–73. [https://doi.org/10.1016/0166-6851\(92\)90109-W](https://doi.org/10.1016/0166-6851(92)90109-W)
- Neumayr A. Antiparasitic treatment recommendations: a practical guide to clinical parasitology. 2018 [cited 2022 Dec 18]. <https://edoc.unibas.ch/69153>
- Loos-Frank B, Zeyhle E. The intestinal helminths of the red fox and some other carnivores in southwest Germany. *Z Parasitenkd*. 1982;67:99–113. <https://doi.org/10.1007/BF00929518>
- Deplazes P, Eichenberger RM, Grimm F. Wildlife-transmitted *Taenia* and *Versteria* cysticercosis and coenurosis in humans and other primates. *Int J Parasitol Parasites Wildl*. 2019;9:342–58. <https://doi.org/10.1016/j.ijppaw.2019.03.013>
- Eberwein P, Haeupler A, Kuepper F, Wagner D, Kern WV, Muntau B, et al. Human infection with marten tapeworm. *Emerg Infect Dis*. 2013;19:1152–4. <https://doi.org/10.3201/eid1907.121114>

7. Brunet J, Benoild A, Kremer S, Dalvit C, Lefebvre N, Hansmann Y, et al. First case of human cerebral *Taenia martis* cysticercosis. *J Clin Microbiol*. 2015;53:2756–9. <https://doi.org/10.1128/JCM.01033-15>
8. Koch T, Schoen C, Muntau B, Addo M, Ostertag H, Wiechens B, et al. Molecular diagnosis of human *Taenia martis* eye infection. *Am J Trop Med Hyg*. 2016;94:1055–7. <https://doi.org/10.4269/ajtmh.15-0881>
9. Rudelius M, Brehm K, Poelcher M, Spinner C, Rosenwald A, da Costa CP. First case of human peritoneal cysticercosis mimicking peritoneal carcinosis: necessity of laparoscopy and histologic assessment for the correct diagnosis. *JMM Case Rep*. 2017;4:e005097. <https://doi.org/10.1099/jmmcr.0.005097>
10. Mueller A, Förch G, Zustin J, Muntau B, Schuldt G, Tappe D. Case report: molecular identification of larval *Taenia martis* infection in the pouch of Douglas. *Am J Trop Med Hyg*. 2020;103:2315–7. <https://doi.org/10.4269/ajtmh.20-0782>

Address for correspondence: Valentin K. Steinsiepe, Department of Neurosurgery, Cantonal Hospital of Lucerne, Spitalstrasse, 6000 Luzern, Switzerland; email: valentinklaus.steinsiepe@luks.ch

Highly Pathogenic Avian Influenza A(H5N1) from Wild Birds, Poultry, and Mammals, Peru

Cristopher D. Cruz, M. Eliana Icochea, Victoria Espejo, Gilda Troncos, Gina R. Castro-Sanguinetti, Megan A. Schilling, Yeny Tinoco

Author affiliations: US Naval Medical Research Unit SOUTH, Lima, Peru (C.D. Cruz, V. Espejo, G. Troncos, M.A. Schilling, Y. Tinoco); Universidad Nacional Mayor de San Marcos, Lima (M.E. Icochea, G.R. Castro-Sanguinetti)

DOI: <https://doi.org/10.3201/eid2912.230505>

We identified highly pathogenic avian influenza A(H5N1) virus clade 2.3.4.4b in wild birds, poultry, and a lion in Peru during November 2022–February 2023 and markers associated with transmission adaptation and antiviral drug resistance. Continuous genomic surveillance is needed to inform public health measures and avoid mass animal deaths.

Highly pathogenic avian influenza (HPAI) H5 viruses of the goose/Guangdong lineage have been categorized into multiple clades (0–9) and subclades. Viruses belonging to H5 clade 2.3.4.4 are differentiated into 8 subclades (a–h) and are of high concern because of spillover events into mammals and direct mammal-to-mammal transmission reported in Spain (1,2). HPAI H5N1 virus subclade 2.3.4.4b has been circulating in Africa, Asia, and Europe since ≈2020 (3,4). Subsequently, this subclade was identified in North America and Canada in late 2021; Colombia, Venezuela, Peru, Ecuador, and Chile during October–December 2022; and in Bolivia, Argentina, and Uruguay during January–February 2023 (1).

By November 2022, ≈300 dead Peruvian pelicans (*Pelecanus thagus*) and 24 dead blue-footed boobies (*Sula nebouxii*) were found on the northern coast of Peru (5). On November 23, 2022, the National Agrarian Health Service of Peru (Servicio Nacional de Sanidad Agraria del Peru) and the US Naval Medical Research Unit SOUTH reported HPAI H5N1 virus was present in Peru (6). Subsequently, we sequenced 18 additional virus samples positive for hemagglutinin (HA) subtype 5 (H5) that were collected from 3 Peruvian pelicans, 12 chickens (*Gallus gallus domesticus*), 2 Neotropic cormorans (*Nannopterum brasilianum*), and 1 lion (*Panthera leo*, from a zoo). We extracted viral RNA from respiratory tissue or environmental fecal samples. We collected samples from birds during November–December 2022 from northern and central coasts of Peru and the sample from the lion in February 2023 from Junin (Andean region) (Appendix Table 1, <https://wwwnc.cdc.gov/EID/article/29/12/23-0505-App1.xlsx>).

We amplified influenza A virus genomes by using a modified protocol (7). We prepared libraries by using the Nextera XT DNA Library Preparation Kit (Illumina, <https://www.illumina.com>) and sequenced them by using the MiSeq Reagent Kit v3 (600-cycle paired-end) on the MiSeq platform (Illumina). We trimmed raw reads, removed host sequences, and then de novo assembled the filtered reads. We identified the resulting contigs as H5N1 by using a BLASTn search (<https://blast.ncbi.nlm.nih.gov>). We deposited all obtained sequences in GenBank (accession nos. OQ547312–451).

We performed phylogenetic analysis to classify subclades by using the maximum-likelihood method. We retrieved H5 sequences from HPAI clade 2.3.4.4 and low pathogenicity avian influenza viruses published in GISAID (<https://www.gisaid.org>) and GenBank during 2014–2023 (until July 20, 2023). The phylogenetic tree of HA sequences placed H5N1

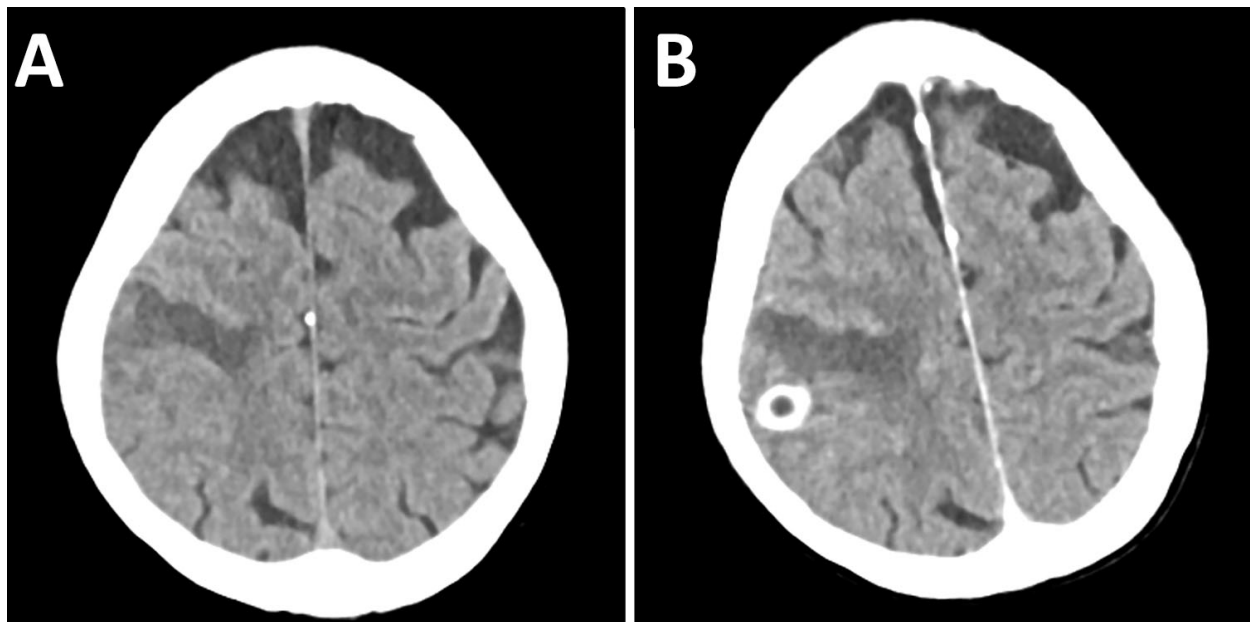
EID cannot ensure accessibility for supplementary materials supplied by authors. Readers who have difficulty accessing supplementary content should contact the authors for assistance.

Human *Taenia martis* Neurocysticercosis, Switzerland

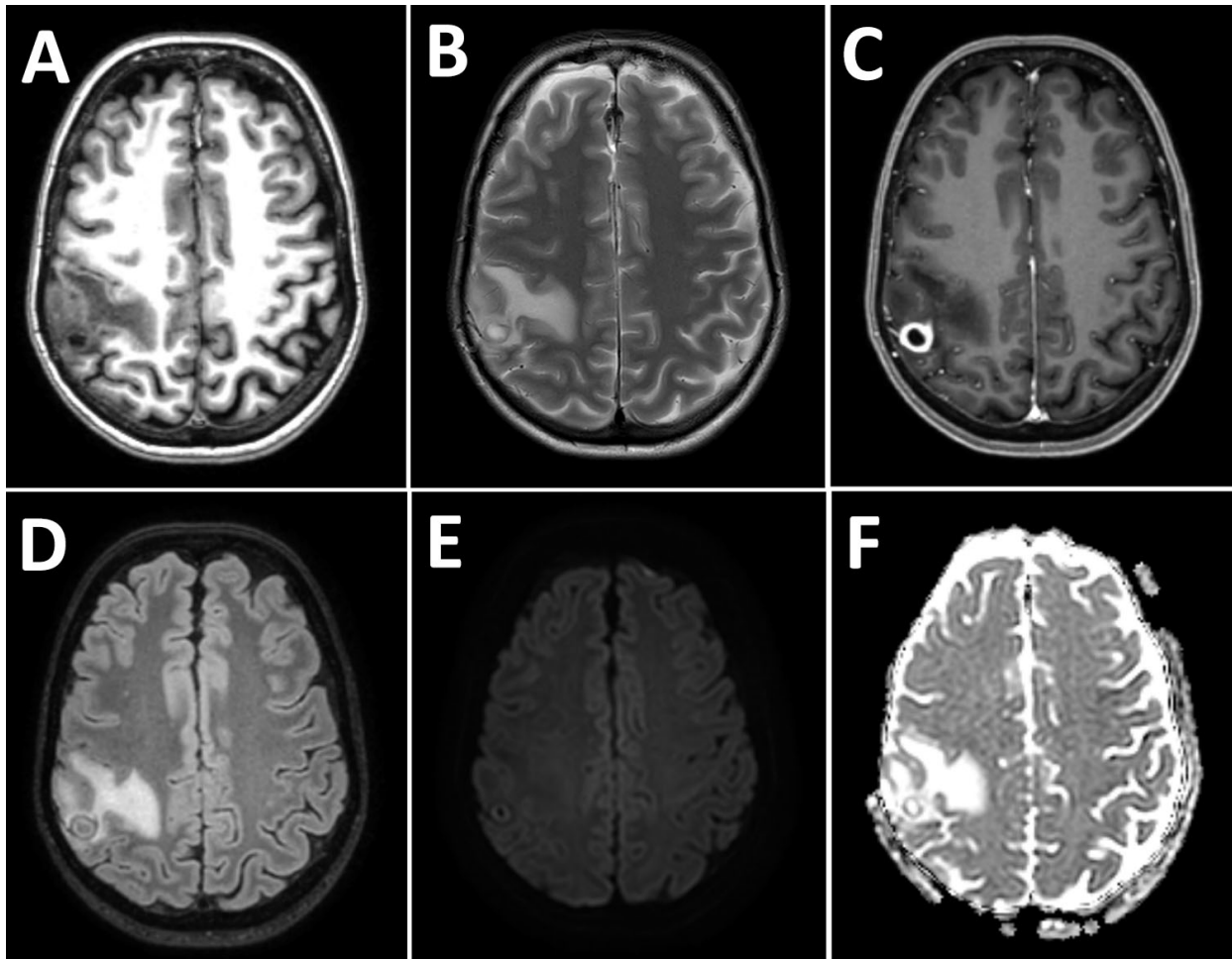
Appendix

Appendix Table. Zoonotic *Taenia* spp. to be considered as rare causes of human neurocysticercosis (1,2)

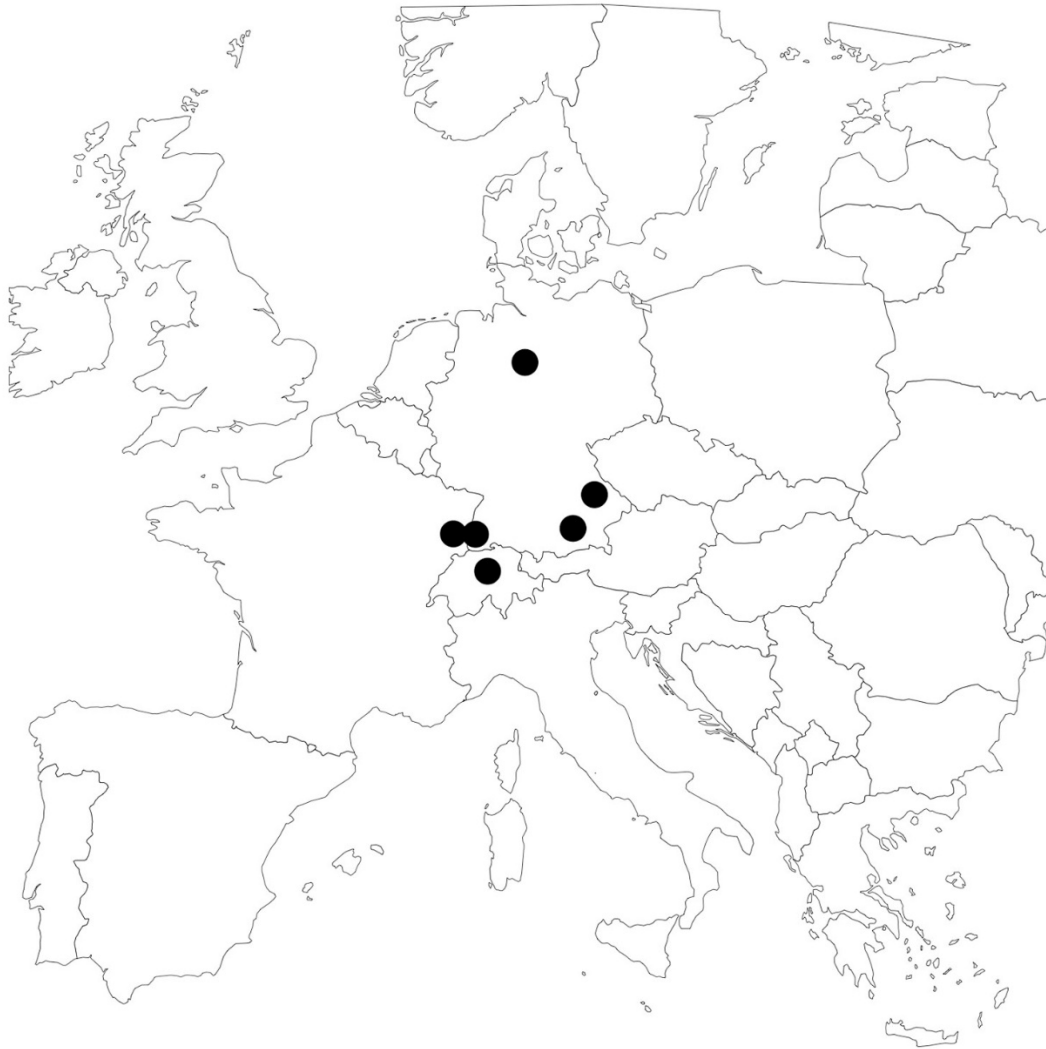<i>Taenia</i> species	Natural definite host	Natural intermediate host	Known geographic range of the parasite
<i>T. multiceps</i>	Dog and other canids	Sheep	Worldwide
<i>T. serialis</i>	Dog and other canids	Rabbit, hare	North America, Europe, Africa
<i>T. brauni</i>	Dog and other canids	Rabbit, hare	Africa
<i>T. glomerata</i>	Dog and other canids	Rabbit, hare	Africa
<i>T. crassiceps</i>	Dog, fox, cat	Rodents	North America, Europe, Russia
<i>T. martis</i>	Marten and other mustelids (also rarely canids, wild cat)	Rodents	North America, Europe, Russia



Appendix Figure 1. Axial CT of the head showing a ring-enhancing lesion in the right postcentral gyrus. A) Noncontrast. B) Contrast enhanced.



Appendix Figure 2. Axial magnetic resonance imaging of the larval cyst in the right postcentral gyrus. A) T1. B) T2. C) T1 enhanced. D) Fluid attenuated inversion recovery (FLAIR). E) Diffusion-weighted imaging (DWI B1000) (B1,000). F) Apparent diffusion coefficient (ADC).



Appendix Figure 3. Geographic localization of all published human *Taenia martis* infections (3–7).

References

1. Neumayr A. Antiparasitic treatment recommendations: a practical guide to clinical parasitology. 2018 [cited 2022 Dec 18]. <https://edoc.unibas.ch/69153>
2. Mueller A, Förch G, Zustin J, Muntau B, Schuldt G, Tappe D. Case report: molecular identification of larval *Taenia martis* infection in the pouch of Douglas. *Am J Trop Med Hyg.* 2020;103:2315–7. [PubMed https://doi.org/10.4269/ajtmh.20-0782](https://doi.org/10.4269/ajtmh.20-0782)
3. Deplazes P, Eichenberger RM, Grimm F. Wildlife-transmitted *Taenia* and *Versteria* cysticercosis and coenurosis in humans and other primates. *Int J Parasitol Parasites Wildl.* 2019;9:342–58. [PubMed https://doi.org/10.1016/j.ijppaw.2019.03.013](https://doi.org/10.1016/j.ijppaw.2019.03.013)

4. Eberwein P, Haeupler A, Kuepper F, Wagner D, Kern WV, Muntau B, et al. Human infection with marten tapeworm. *Emerg Infect Dis*. 2013;19:1152–4. [PubMed](#)
<https://doi.org/10.3201/eid1907.121114>
5. Brunet J, Benoild A, Kremer S, Dalvit C, Lefebvre N, Hansmann Y, et al. First case of human cerebral *Taenia martis* cysticercosis. *J Clin Microbiol*. 2015;53:2756–9. [PubMed](#)
<https://doi.org/10.1128/JCM.01033-15>
6. Koch T, Schoen C, Muntau B, Addo M, Ostertag H, Wiechens B, et al. Molecular diagnosis of human *Taenia martis* eye infection. *Am J Trop Med Hyg*. 2016;94:1055–7. [PubMed](#)
<https://doi.org/10.4269/ajtmh.15-0881>
7. Rudelius M, Brehm K, Poelcher M, Spinner C, Rosenwald A, da Costa CP. First case of human peritoneal cysticercosis mimicking peritoneal carcinosis: necessity of laparoscopy and histologic assessment for the correct diagnosis. *JMM Case Rep*. 2017;4:e005097. [PubMed](#)
<https://doi.org/10.1099/jmmcr.0.005097>