

$\geq 0.8 \times 10^9$ cells/L, which identified all cases in this series with a specificity of 71% (Figure). We assessed the potential effect on resource use of this threshold by examining the region's whole-population distribution of absolute eosinophil counts. Among 8,562 persons who submitted a specimen for complete blood count for any reason from January 2019 through April 2022, a total of 287 had eosinophil counts that exceeded our threshold (86 [1.2%] specimens/year).

Automated flags and reflex testing in Nunavik now incorporate the threshold identified in our analysis. In the absence of a defined alternative diagnosis, eosinophil counts of $\geq 0.80 \times 10^9$ cells/L should prompt clinical consideration of trichinellosis and further investigation. Early identification of outbreaks is critical in this region—where hunted meat is shared widely within and among communities—to limit exposures and enable delivery of postexposure prophylactic anthelmintic therapy, which has evidence of effectiveness in this serious illness (1,4,10). The cost-benefit ratio of this threshold will require ongoing assessment.

Acknowledgments

We appreciate the collaboration of Nunavik Public Health, the National Reference Centre for Parasitology, and the staff of Inuulitsivik Health Centre, including members of medical records department.

This work was supported by a FRQ-S Clinician-Researcher Career Junior 2 award to C.P.Y.

About the Author

Dr. Harrison is chief resident in Infectious Diseases and Medical Microbiology at the McGill University Health Centre. His research interests include evolutionary biology.

References

- Schellenberg RS, Tan BJK, Irvine JD, Stockdale DR, Gajadhar AA, Serhir B, et al. An outbreak of trichinellosis due to consumption of bear meat infected with *Trichinella nativa*, in 2 northern Saskatchewan communities. *J Infect Dis*. 2003;188:835–43. <https://doi.org/10.1086/378094>
- Dalcin D, Zarlega DS, Larter NC, Hoberg E, Boucher DA, Merrifield S, et al. *Trichinella nativa* outbreak with rare thrombotic complications associated with meat from a black bear hunted in northern Ontario. *Clin Infect Dis*. 2017;64:1367–73. <https://doi.org/10.1093/cid/cix165>
- MacLean JD, Viallet J, Law C, Staudt M. Trichinosis in the Canadian Arctic: report of five outbreaks and a new clinical syndrome. *J Infect Dis*. 1989;160:513–20. <https://doi.org/10.1093/infdis/160.3.513>
- Proulx JF, MacLean JD, Gyorkos TW, Leclair D, Richter AK, Serhir B, et al. Novel prevention program for trichinellosis in Inuit communities. *Clin Infect Dis*. 2002;34:1508–14. <https://doi.org/10.1086/340342>
- Larrat S, Simard M, Lair S, Bélanger D, Proulx J-F. From science to action and from action to science: the Nunavik Trichinellosis Prevention Program. *Int J Circumpolar Health*. 2012;71:18595. <https://doi.org/10.3402/ijch.v71i0.18595>
- R Core Team. R: a language and environment for statistical computing. Version 4.1.3 [cited 2022 Apr 1]. <https://www.R-project.org>
- Robin X, Turck N, Hainard A, Tiberti N, Lisacek F, Sanchez J-C, et al. pROC: an open-source package for R and S+ to analyze and compare ROC curves. *BMC Bioinformatics*. 2011;12:77. <https://doi.org/10.1186/1471-2105-12-77>
- Ducrocq J, Proulx J-F, Simard M, Lévesque B, Iqaluk M, Elijassiapik L, et al. The unique contribution of a local response group in the field investigation and management of a trichinellosis outbreak in Nunavik (Québec, Canada). *Can J Public Heal*. 2020;111:31–9. <https://doi.org/10.17269/s41997-019-00255-8>
- Gottstein B, Pozio E, Nöckler K. Epidemiology, diagnosis, treatment, and control of trichinellosis. *Clin Microbiol Rev*. 2009;22:127–45. <https://doi.org/10.1128/CMR.00026-08>
- Faber M, Schink S, Mayer-Scholl S, Ziesch S, Schönfelder R, Wichmann-Schauer H, et al. Outbreak of trichinellosis due to wild boar meat and evaluation of the effectiveness of post exposure prophylaxis, Germany, 2013. *Clin Infect Dis*. 2015;60:e98-104.

Address for correspondence: Luke B. Harrison, McGill University Health Centre, Rm E5.1815, 1001 Blvd Decarie, Montreal, QC H4A 3J1, Canada; email: luke.harrison@mail.mcgill.ca

***Dirofilaria repens* Testicular Infection in Child, Italy**

Sara Ugolini, Mario Lima, Michela Maffi, Francesco Pierangeli, Marzia Vastano, Tommaso Gargano, Stefania Varani, Andrea Gustinelli, Monica Caffara, Maria L. Fioravanti

Author affiliations: Wythenshawe Hospital, Manchester, UK (S. Ugolini); University of Manchester NHS Foundation Trust, Manchester (S. Ugolini); IRCCS Azienda Ospedaliero–Universitaria di Bologna, Bologna, Italy (M. Lima, M. Maffi, M. Vastano, T. Gargano, S. Varani); Ospedali Riuniti di Ancona, Ancona, Italy (F. Pierangeli); Alma Mater Studiorum–University of Bologna, Bologna (M. Lima, T. Gargano, S. Varani, A. Gustinelli, M. Caffara, M.L. Fioravanti)

DOI: <https://doi.org/10.3201/eid2812.220424>

Testicular *Dirofilaria repens* infection was identified and confirmed by sequence analysis in a child in northeastern Italy. Because human dirofilariasis is emerging in southern and eastern Europe, this parasitic infection should be considered in the differential diagnosis of scrotal swelling in disease-endemic countries to avoid unnecessary interventions, such as orchiectomy.

Dirofilariasis is a zoonotic nematode infection that typically affects canines and other carnivores and can be transmitted to humans by Culicidae mosquitos. Dirofilariasis incidence has increased worldwide; new cases have been reported in previously nonendemic regions (1,2). This changing trend is likely related to global warming and subsequent increases in vector density and activity during the year. Canine dirofilariasis is endemic in Mediterranean countries of Europe and has 2 main etiologic agents: *Dirofilaria repens*, the main agent of subcutaneous infections, and *D. immitis*, the agent largely responsible for cardiopulmonary infections (1–3). Humans are usually dead-end hosts, and infection is mainly caused by a single immature worm (2). A clinical manifestation of human dirofilariasis is pulmonary dirofilariasis, which has been predominantly detected within the Americas, although recent cases have been reported in Europe. In addition, *D. repens* nematodes cause human subcutaneous dirofilariasis (HSD), which is typical of the

Old World (1–3); subcutaneous or ocular infection and infections in male genitalia, female mammary glands, lungs, liver, and mesentery have been described.

We report a case of dirofilariasis that occurred in September 2017 in a boy 13 years of age living in Bologna (northeastern Italy) who was born in Taormina (Sicily, Italy). The patient had a 5-month history of swelling in the left testicle. During initial assessment, the left testicle had a tender nodule upon palpation without associated scrotal hyperemia or inguinal lymphadenopathy. Ultrasonography showed a 1-cm, well-defined cyst containing a coiled structure with parallel echogenic walls and movement within the cyst (Figure, panel A). Subsequent magnetic resonance imaging showed the cyst was located on the testis without signs of infiltration and contained fluid mixed with tubular structures and moving artifacts (Figure, panel B). The patient was scheduled for surgical excision and histologic diagnosis. Routine preoperative laboratory tests showed normal blood cell counts: erythrocytes, 5.07×10^{12} cells/L; leukocytes, 5.30×10^9 cells/L; and eosinophils, 0.10×10^9 cells/L. Intraoperative exploration revealed a well-circumscribed, encapsulated tense nodule in the left side of the scrotum (Figure, panel C). To collect samples for histology and microbiology, we opened the cyst and found a coiled, thread-like roundworm (Figure, panel D). Further macroscopic examination indicated the worm was potentially a dirofilarial nematode. Because

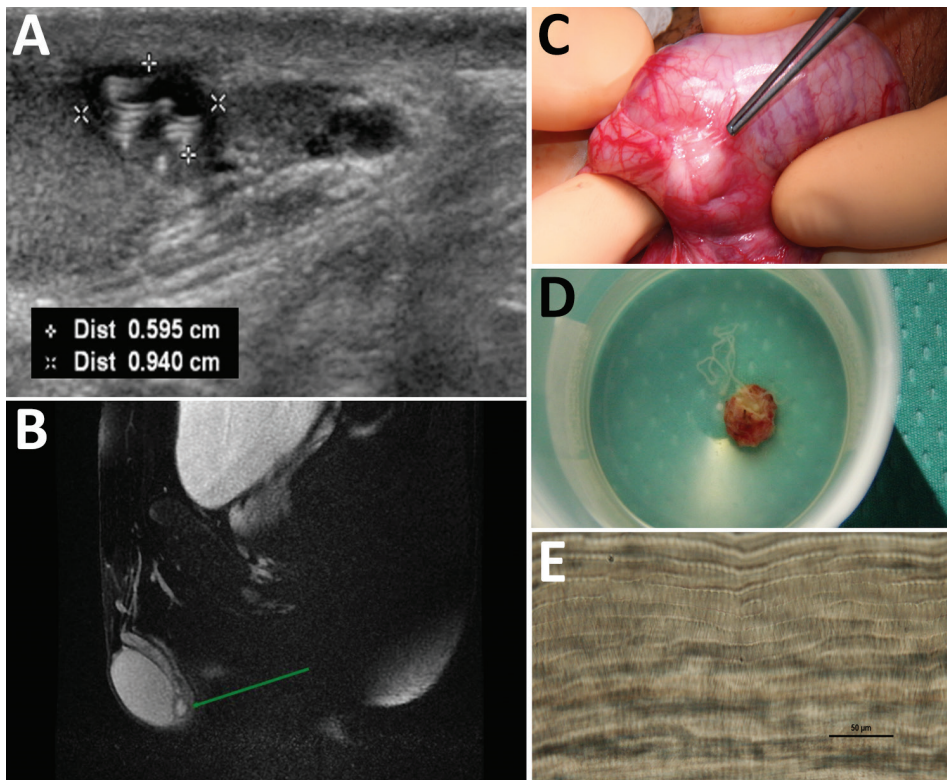


Figure. Diagnostic evaluation of *Dirofilaria repens* testicular infection in a child from Italy, a boy 13 years of age who had a 5-month history of swelling in the left testicle. A) Ultrasound scan showed a 0.5×0.9 cm hypoechoic cyst with moving artifacts and thread-like hyperechoic structures. B) Magnetic resonance imaging showed the cyst was located on the testis without signs of infiltration and contained fluid mixed with tubular structures and moving artifacts. C) Exploration of the scrotum before cyst excision showed a well-circumscribed, encapsulated tense nodule on the left side. D) The cyst was excised and a coiled roundworm was found in the opened capsule. E) We identified the nematode as a female *D. repens* nematode by microscopically observing typical longitudinal ridges on the body surface. Scale bar indicates 50 μ m. Dist, distance.

both ends of the worm were not visible, we identified the worm by microscopic observations and molecular sequence analysis of the remaining portions after fixing in 70% ethanol. The parasite was 423–588 μm wide with a cuticular layer 13–15 μm thick; the external surface was characterized by longitudinal ridges spaced 6–9 μm apart (Figure, panel E). We identified the nematode as a female *D. repens* by the longitudinal ridges, which we confirmed by molecular identification (4). We performed phylogenetic analysis of the 12S rRNA and cytochrome c oxidase subunit 1 mitochondrial genes; our specimen clustered with and was identical to *D. repens* sequences obtained from humans and dogs in Italy (Appendix Figure, <https://wwwnc.cdc.gov/EID/article/28/12/22-0424-App1.pdf>). The patient had an uneventful postoperative course, and no further therapy was administered. At 20-month follow-up, the patient had no residual symptoms, and ultrasonography showed no testicular abnormalities.

HSD localization in male genitalia (testis, scrotum, verga, spermatic cord, and epididymis) has been previously described (5–9) and might be related to a *D. repens* tropism in response to sex hormones (1). Our case highlights that testicular dirofilariasis might mimic a testicular tumor and lead to unnecessary orchiectomy because of misdiagnosis. A helminthic infection should be considered in this differential diagnosis for gradual-onset testicular swelling with or without signs of inflammation, especially in endemic areas. Serologic tests for helminthic infections are performed only in specialized laboratories and are not routinely available. In addition, the accuracy and usefulness of those tests have been debated (10). Ultrasonography and magnetic resonance imaging can help identify features of dirofilariasis, such as dirofilarial nodules with suspicious inner hypoechoic/T1-hypointense findings, or might demonstrate moving worms (10). Imaging results should be consistent with a thick-walled lesion, semiliquid content with a central signal caused by the worm, and a macroscopic thread-like structure. The definitive diagnosis of HSD can only be achieved by postoperative identification of the worm by using morphologic, histologic, or molecular analysis. When malignancy cannot be excluded, an excisional biopsy is indicated for histologic diagnosis. The complete extraction of the worm is usually curative, and no specific antihelminth therapy is indicated in the absence of secondary lesions (8,9).

In conclusion, diagnoses of human dirofilariasis have increased in countries in Europe, and clinical awareness of this parasitic infection should be strengthened through education and interdisciplinary collaboration among clinicians, surgeons, and parasitologists.

Clinicians should consider HSD in the differential diagnosis of subcutaneous or superficial tissue nodules of the testicles. Excisional biopsies should be performed for parasitologic, molecular, and histologic analyses to avoid invasive surgical procedures that might cause permanent reduction in quality of life, such as orchiectomy.

Acknowledgments

We thank Karl Christian Walsh for proofreading the article and Gian Carla Sartori Segadelli for retrieving full-text articles included in the literature review.

The opinions expressed by authors contributing to this journal do not necessarily reflect the opinions of the institutions with which the authors are affiliated.

About the Author

Dr. Ugolini is a senior clinical fellow in cardiothoracic surgery at Manchester University NHS Foundation Trust, UK. She qualified as a pediatric surgeon in 2021 in Italy, and this case occurred while she was in training.

References

1. Pampiglione S, Rivasi F. Human dirofilariasis due to *Dirofilaria* (Nochtiella) *repens*: an update of world literature from 1995 to 2000. *Parassitologia*. 2000;42:231–54.
2. Simón F, Diosdado A, Siles-Lucas M, Kartashev V, González-Miguel J. Human dirofilariasis in the 21st century: a scoping review of clinical cases reported in the literature. *Transbound Emerg Dis*. 2021 Jul 1 [Epub ahead of print]. <https://doi.org/10.1111/tbed.14210>
3. Miterpáková M, Antolová D, Rampalová J, Undesser M, Krajčovič T, Víchová B. *Dirofilaria immitis* pulmonary dirofilariasis, Slovakia. *Emerg Infect Dis*. 2022;28:482–5. <https://doi.org/10.3201/eid2802.211963>
4. Suzuki J, Kobayashi S, Okata U, Matsuzaki H, Mori M, Chen KR, et al. Molecular analysis of *Dirofilaria repens* removed from a subcutaneous nodule in a Japanese woman after a tour to Europe. *Parasite*. 2015;22:2. <https://doi.org/10.1051/parasite/2015002>
5. Fleck R, Kurz W, Quade B, Geginat G, Hof H. Human dirofilariasis due to *Dirofilaria repens* mimicking a scrotal tumor. *Urology*. 2009;73:209.e1–3. <https://doi.org/10.1016/j.urology.2008.02.015>
6. Tripi F, Scarlata F, Verde V, Voti G, Chiaramonte C. Human dirofilariasis presenting as scrotal mass. *J Urol Nephrol Open Access*. 2016;3:1–4. <https://doi.org/10.15226/2473-6430/3/1/00120>
7. Leccia N, Patouraux S, Carpentier X, Boissy C, Del Giudice P, Parks S, et al. Pseudo-tumor of the scrotum, a rare clinical presentation of dirofilariasis: a report of two autochthonous cases due to *Dirofilaria repens*. *Pathog Glob Health*. 2012;106:370–2. <https://doi.org/10.1179/2047773212Y.00000000029>
8. D'Amuri A, Senatore SA, Carlà TG, Floccari F, Villani E, Leocata P, et al. Cutaneous dirofilariasis resulting in orchiectomy. *J Cutan Pathol*. 2012;39:304–5. <https://doi.org/10.1111/j.1600-0560.2011.01828.x>
9. Kallampallil J, Wood SJ, O'Dempsey T, Craigie RJ. Nematode infection mimicking paratesticular malignancy. *BMJ Case*

- Rep. 2013;2013:bcr2013200775. <https://doi.org/10.1136/bcr-2013-200775>
10. European Society of Dirofilariosis and Angiostrongylosis. Guidelines for clinical management of human Dirofilaria infections. 2017 [cited 2022 Aug 8]. <https://www.esda.vet/media/attachments/2021/08/19/human-dirofilaria-infections.pdf>

Address for correspondence: Sara Ugolini, Department of Cardiothoracic Surgery, Wythenshawe Hospital, University of Manchester NHS Foundation Trust, Southmoor Rd, Wythenshawe, Manchester M23 9LT, UK; email: sara.ugolini@mft.nhs.uk

Severe Fever with Thrombocytopenia Syndrome Virus Infection, Thailand, 2019–2020

Patthaya Rattanakomol, Sarawut Khongwichit, Piyada Linsuwanon, Keun Hwa Lee, Sompong Vongpunsawad, Yong Poovorawan

Author affiliations: Chulalongkorn University, Bangkok, Thailand (P. Rattanakomol, S. Khongwichit, S. Vongpunsawad, Y. Poovorawan); US Army Medical Directorate–Armed Forces Research Institute of Medical Sciences, Bangkok, Thailand (P. Linsuwanon); Hanyang University, Seoul, South Korea (K.H. Lee)

Infection with severe fever with thrombocytopenia syndrome (SFTS) virus, which can cause hemorrhagic febrile illness, is often transmitted by ticks. We identified 3 patients with SFTS in or near Bangkok, Thailand. Our results underscore a need for heightened awareness by clinicians of possible SFTS virus, even in urban centers.

DOI: <https://doi.org/10.3201/eid2812.221183>

Severe fever with thrombocytopenia syndrome (SFTS) is a tickborne viral disease associated with acute fever, possibly accompanied by vomiting, diarrhea, fatigue, myalgia, and leukocytopenia (1). Most reports of infection have come from studies in South Korea, Japan, and China, although Taiwan, Vietnam, and Myanmar have had confirmed cases in recent years (2). Severe infections can cause hemorrhagic

fever and multiple organ failure leading to death. SFTS results from infection by the SFTS virus (SFTSV, newly renamed *Dabie bandavirus*), an RNA virus in the family Phenuiviridae, genus *Bandavirus* (3). More frequent arbovirus infections in Thailand, primarily dengue and chikungunya, often confound diagnosis of febrile illness caused by other viruses such as SFTSV because most clinicians lack awareness.

Testing during an upsurge in chikungunya virus infection in Thailand at the end of 2018 found that >70% of acute febrile illnesses were laboratory-confirmed chikungunya (4). As the proportion of chikungunya virus-positive samples eventually decreased, we began to screen for other common viral etiologies of acute fever, including dengue and Zika viruses (Appendix Figure, <https://wwwnc.cdc.gov/EID/article/28/12/22-1183-App1.pdf>). Because SFTSV had been reported in 2 patients in Vietnam (5) at the time, when the samples from Thailand tested negative for all 3 more common viruses, we began examining for possible SFTSV infection. The Institutional Review Board of Chulalongkorn University Faculty of Medicine approved this study (IRB number 0453/65).

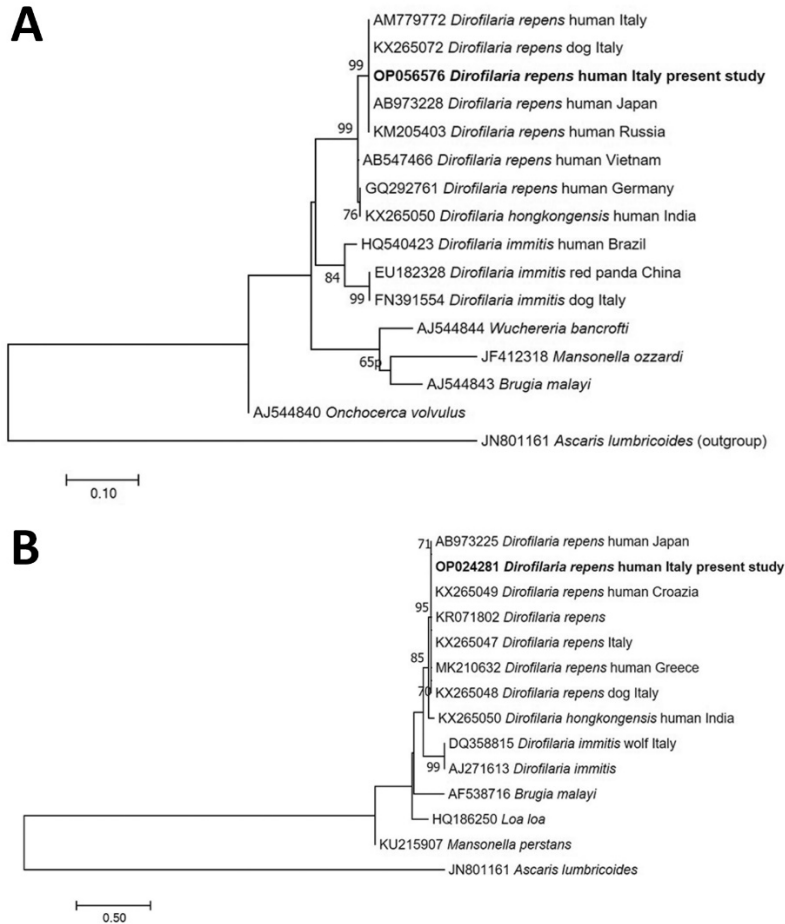
We subjected de-identified archived RNA samples from 712 patients from Bangkok and surrounding areas, hospitalized during October 2018–March 2021, to reverse transcription PCR to detect the nucleoprotein gene region of the small (S) segment of SFTSV (6). Three samples tested positive, so we used 3 primer sets described elsewhere (7) to determine full-length S-segment nucleotide sequences. We deposited sequences in the GenBank database (accession numbers ON840548–50) and constructed the SFTSV S-segment phylogenetic tree using MEGA11 (<https://www.megasoftware.net>).

Phylogenetic analysis suggested that the 3 SFTSV strains from Thailand shared ≈99.7% nucleotide sequence identities and were genetically closest to the SFTSV strains from China identified in 2012–2017 (99.3%–99.6% nucleotide identity) (Figure; Appendix Table). On the basis of available clinical records, all 3 patients reported myalgia with lower than normal leukocyte (<3,000 cells/μL) and platelet (<110,000 cells/μL) counts (Table). Two patients experienced elevated alanine and aspartate aminotransferase levels (>60 U/L). Although patient 1 did not demonstrate substantially altered leukocyte count or blood chemistry, he experienced gastrointestinal symptoms (abdominal pain, nausea, vomiting, and diarrhea).

Patients reported no history of travel within 3 weeks before symptom onset. Patients 1 and 3 lived in Bangkok, whereas patient 2 lived in Chachoengsao Province, ≈40 km east of Bangkok. Because international travel

Dirofilaria repens Testicular Infection in Child, Italy

Appendix



Appendix Figure. Phylogenetic analysis of the nematode *Dirofilaria repens* causing a testicular infection in a child in Italy. Phylogenetic trees were constructed by using the maximum-likelihood method. A) The sequence of the 12S rRNA mitochondrial gene from *D. repens* found in this case was compared with *D. repens* sequences from GenBank. Evolutionary history was inferred according to the Hasegawa, Kishino, Yano (HKY) model. B) The sequence of the cytochrome c oxidase subunit 1 mitochondrial gene from *D. repens* found in this case was compared with *D. repens* sequences from GenBank. Evolutionary history was inferred according to the Tamura-Nei model. Our specimen clustered with and was identical to *D. repens* sequences obtained from humans and dogs in Italy. Bootstrap values are shown at different nodes. The trees are drawn to scale; scale bars indicate nucleotide substitutions per site.