

2. Pralong F, Dereure J, Ravel C, Lami P, Balard Y, Serres G, et al. Geographical distribution and epidemiological features of Old World cutaneous leishmaniasis foci, based on the isoenzyme analysis of 1048 strains. *Trop Med Int Health*. 2009;14:1071–85. <http://dx.doi.org/10.1111/j.1365-3156.2009.02336.x>
3. Harrat Z, Boubidi SC, Pralong F, Benikhlef R, Selt B, Dedet JP, et al. Description of a dermatropic *Leishmania* close to *L. killicki* (Rioux, Lanotte & Pralong 1986) in Algeria. *Trans R Soc Trop Med Hyg*. 2009;103:716–20. <http://dx.doi.org/10.1016/j.trstmh.2009.04.013>
4. Mihoubi I, Picot S, Hafirassou N, de Monbrison F. Cutaneous leishmaniasis caused by *Leishmania tropica* in Algeria. *Trans R Soc Trop Med Hyg*. 2008;102:1157–9. <http://dx.doi.org/10.1016/j.trstmh.2008.06.013>
5. Mansouri R, Pralong F, Bachi F, Hamrioui B, Dedet JP. The first isoenzymatic characterizations of the *Leishmania* strains responsible for cutaneous leishmaniasis in the area of Annaba (Eastern Algeria) [cited 2014 Jan 16]. *The Open Conference Proceedings Journal*. 2012;3 (Suppl.2–M2):6–11. <http://www.benthamscience-publisher.com/open/toprocj/articles/V003/SS0001TOPROCJ/6TOPROCJ.pdf>
6. Klaus S, Frankenburg S. Cutaneous leishmaniasis in the Middle East. *Clin Dermatol*. 1999;17:137–41. [http://dx.doi.org/10.1016/S0738-081X\(99\)00006-1](http://dx.doi.org/10.1016/S0738-081X(99)00006-1)
7. Haouas N, Garrab S, Gorcii M, Khorchani H, Chargui N, Ravel C, et al. Development of a polymerase chain reaction-restriction fragment length polymorphism assay for *Leishmania major/Leishmania killicki/Leishmania infantum* discrimination from clinical samples, application in a Tunisian focus. *Diagn Microbiol Infect Dis*. 2010;68:152–8. <http://dx.doi.org/10.1016/j.diagmicrobio.2010.06.011>
8. Morizot G, Kendjo E, Mouri O, Thellier M, Pérignon A, Foulet F, et al. Travelers with cutaneous leishmaniasis cured without systemic therapy. *Clin Infect Dis*. 2013;57:370–80. <http://dx.doi.org/10.1093/cid/cit269>
9. Magill AJ, Grogl M, Gasser RA, Sun W, Oster CN. Visceral infection caused by *Leishmania tropica* in veterans of Operation Desert Storm. *N Engl J Med*. 1993;328:1383–7. <http://dx.doi.org/10.1056/NEJM199305133281904>
10. Maubon D, Thurot-Guillou C, Ravel C, Leccia MT, Pelloux H. *Leishmania killicki* imported from Tunisian desert. *Emerg Infect Dis*. 2009;15:1864–5. <http://dx.doi.org/10.3201/eid1511.090148>

Address for correspondence: Rémy Durand, Service de Parasitologie-Mycologie, Hôpital Avicenne, 125 rue de Stalingrad 93009 Bobigny Cedex, France; email: [remy.durand@avc.aphp.fr](mailto:remy.durand@avc.aphp.fr)

## Rift Valley Fever in Kedougou, Southeastern Senegal, 2012

**To the Editor:** Rift Valley fever (RVF) is an acute, febrile, viral disease caused by Rift Valley fever virus (RVFV), a phlebovirus of the family *Bunyaviridae* that is endemic to sub-Saharan Africa. RVF mortality and abortion rates among young domesticated ruminants and pregnant females are high.

In humans, clinical manifestations range from mild to severe syndromes, which can include neurologic, hemorrhagic, and hepatic features and retinitis, and which sometimes result in death (1). Diagnosis of RVF is challenging for clinicians because clinical manifestations are not specific (2). Heavy rainfall and flooding create conditions for emergence of RVF vectors (*Aedes* and *Culex* spp. mosquitoes), and dispersion of this disease into new areas is linked to migration of infected livestock, wildlife, or mosquitoes.

Since 1987, when the Diama dam was built, RVF outbreaks in Mauritania have been reported regularly (3). In Kedougou, southeastern Senegal, RVFV was isolated 4 times from *Ae. dalzieli* mosquitoes and once from a person with a mild case of RVF (4). We report results of a field investigation and laboratory findings for a human case of RVF detected by surveillance of acute febrile illnesses in Kedougou.

On October 16, 2012, a 27-year-old man (school teacher) who lived and worked in Baya village in the Kedougou region of Senegal (12°27'50"N, 12°28'6"W) visited the Kedougou military health post because of high fever, chills, headache, back pain, myalgia, and arthralgia that started on October 14. He reported regular contact with domesticated animals (cows, sheep, and goats) during farming.

A thick blood smear for the patient showed a positive result for

malaria, and specific treatment was given. As part of surveillance for acute febrile illnesses, blood samples from the patient were tested for IgM against RVF, chikungunya, dengue, West Nile, yellow fever, Zika, and Crimean-Congo hemorrhagic fever viruses; and for viral RNA and virus (5,6). All test results for IgM against the 7 viruses were negative.

RVFV was isolated from newborn mice that were intracerebrally inoculated with a blood sample from the patient. Viral RNA was detected by reverse transcription PCR in serum from the patient. Phylogenetic analysis of the partial nonstructural protein gene on the small RNA segment showed that the RVFV isolate was closely related to a strain that had circulated in Mauritania in 2012 (Figure).

An epidemiologic field investigation was conducted to assess the extent of RVFV circulation. During this investigation, the case-patient provided an additional blood sample. In addition, 115 contacts of the case-patient, including primary school students, friends, family members and neighbors (median age 12 years, range 6–75 years; female:male sex ratio 1.6) were also sampled and questioned to identify asymptomatic and benign cases. A total of 218 samples from patients attending the nearest health posts in Ibel and Thiokoye villages during October 2012 were also tested during surveillance of acute febrile illnesses.

All 334 samples were negative for RVFV RNA and IgM and IgG against RVFV except for samples from 3 patients, including the case-patient, which were positive for RVFV-specific IgG and malaria parasites. The 2 other patients were a 32-year-old tradesman and a 20-year-old housewife sampled during surveillance of acute febrile illnesses in Kedougou and Bandafassi, which is 30 km from Baya (online Technical Appendix Figure, [wwwnc.cdc.gov/EID/article/20/3/13-1174-Techapp1.pdf](http://wwwnc.cdc.gov/EID/article/20/3/13-1174-Techapp1.pdf)). No RVFV RNA was detected

from 519 mosquito pools sampled in the Kedougou region during October 2012, although these pools included 7 species previously found associated with RVFV and which represented 26.6 % of the pools.

The patient reported no travel outside Kedougou in the 2-year period before his illness. Because no evidence of recent RVFV circulation among humans and mosquitoes was found, we believe that the patient was

infected by contact with an animal imported from Mauritania. This hypothesis is based on reports by farmers from neighboring villages (Baya, Ibel, Thiokoye, and Dondol) of the presence of ruminants imported from Mauritania in the market in Thiokoye village and of deaths and abortions among sheep and goats in their villages during October–November 2012. However, no animals were sampled during the investigation.

There is an abundance of competent vectors for RVFV in Kedougou (4). In addition, there are massive human migrations resulting from gold mining and regular importation of animals from RVFV-endemic regions of western Africa. Thus, an integrated human and animal surveillance system should be implemented or reinforced to avoid large-scale RVF outbreaks in Kedougou.

### Acknowledgments

We thank Moctar Mansaly for providing assistance during field investigations and the medical authorities of Kedougou for facilitating the field investigation.

This study was supported by grants from the Institut Pasteur de Dakar, Senegal, and the National Institutes of Health (grant 5R01A 1069145).

**Abdourahmane Sow,  
Oumar Faye, Ousmane Faye,  
Diawo Diallo, Bakary D. Sadio,  
Scott C. Weaver,  
Mawlouth Diallo,  
and Amadou A. Sall**

Author affiliations: Institut Pasteur, Dakar, Senegal (A. Sow, Ou. Faye, Om. Faye, D. Diallo, B.D. Sadio, M. Diallo, A.A. Sall); and University of Texas Medical Branch, Galveston, Texas, USA (S.C. Weaver)

DOI: <http://dx.doi.org/10.3201/eid2003.131174>

### References

- Aradaib IE, Erickson BR, Elageb RM, Khristova ML, Carroll SA, Elkhidir IM, et al. Rift Valley fever, Sudan, 2007 and 2010. *Emerg Infect Dis*. 2013;19:246–53. <http://dx.doi.org/10.3201/eid1902.120834>
- Kahlon SS, Peters CJ, LeDuc J, Muchiri EM, Muiruri S, Njenga MK, et al. Severe Rift Valley fever may present with a characteristic clinical syndrome. *Am J Trop Med Hyg*. 2010;82:371–5. <http://dx.doi.org/10.4269/ajtmh.2010.09-0669>
- Digoutte JP, Peters CJ. General aspects of the 1987 Rift Valley fever epidemic in Mauritania. *Res Virol*. 1989;140:27–30. [http://dx.doi.org/10.1016/S0923-2516\(89\)80081-0](http://dx.doi.org/10.1016/S0923-2516(89)80081-0)
- Monlun E, Zeller H, Le Guenno B, Traore-Lamizana M, Hervy JP, Adam F, et al. Surveillance of the circulation of arbovirus of

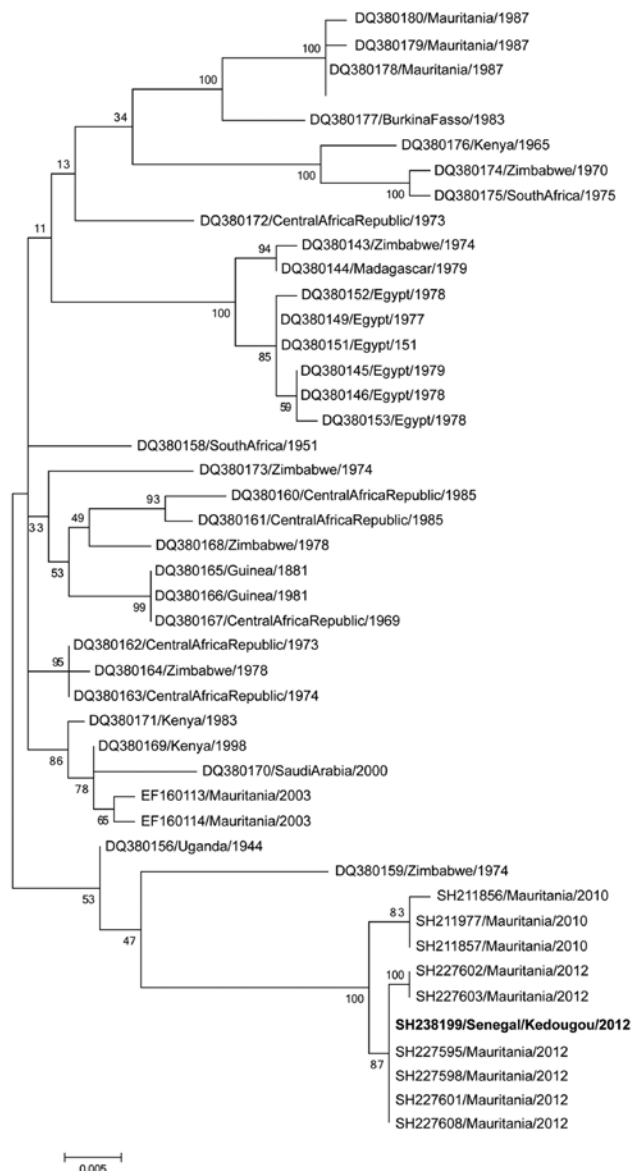


Figure. Phylogenetic tree of a 581-bp sequence of the nonstructural protein gene on the small RNA segment of Rift Valley fever viruses. **Boldface** indicates strain isolated in this study. Bootstrap values are indicated along branches. Scale bar indicates nucleotide substitutions per site.

- medical interest in the region of eastern Senegal [in French]. *Bull Soc Pathol Exot.* 1993;86:21–8.
- Niklasson B, Peters CJ, Grandien M, Wood O. Detection of human immunoglobulins G and M antibodies to Rift Valley fever virus by enzyme-linked immunosorbent assay. *J Clin Microbiol.* 1984;19:225–9.
  - Cornet M, Robin Y, Chateau R, Hème G, Adam C. Isolation of arboviruses in east Senegal from mosquitoes (1972–1977) and notes on the epidemiology of viruses transmitted by *Aedes*, especially of yellow fever virus. *Cah ORSTOM Sér Ent Méd. et Parasitol.* 1979;17:149–63.

Address for correspondence: Amadou A. Sall, Unité des Arbovirus et Virus de Fièvres Hémorragiques, Institut Pasteur de Dakar, BP 220 Dakar, Senegal; email: asall@pasteur.sn

## Concomitant Multidrug-Resistant Pulmonary Tuberculosis and Susceptible Tuberculous Meningitis

**To the Editor:** In 2012, a 34-year-old HIV-seronegative man was hospitalized after several months of cough, fever, night sweats, 10-kg weight loss, and, in the past month, severe headache. The patient was born in Romania and had lived in France for 2 years. He had a history of pulmonary tuberculosis (TB) for which treatment was started in Romania in 2006 and 2008, but he did not

complete treatment. The treatment he received in Romania was unknown.

At hospital admission, the patient had a fever of 39°C, stiff neck, and swollen cervical and axillary lymph nodes. A chest radiograph showed multiple cavities and nodular opacities in both superior lobes. Sputum auramine staining indicated that acid-fast bacilli was positive, which supported the diagnosis of pulmonary TB. Examination of cerebrospinal fluid (CSF) revealed hypoglycorrhachia (0.95 mmol/L, concentration ratio CSF/blood: 0.2 [reference range 0.5–0.75]), hyperproteinorrhachia (1.3 g/L [reference range 0.2–0.4 g/L]), erythrocyte count 2,000  $\mu$ L (reference value <10  $\mu$ L), and leukocyte count 150  $\mu$ L (reference value <10  $\mu$ L). Auramine staining showed no acid-fast bacilli in CSF. Standard antituberculous therapy with rifampin (RIF), isoniazid (INH), pyrazinamide, and ethambutol was started.

Genomic amplification-based assay (Xpert MTB/RIF; Cepheid, Maurens-Scopont, France), performed on sputum, confirmed the presence of the *Mycobacterium tuberculosis* genome and detected resistance to RIF (Table). The line probe assay Genotype MTBDR<sub>plus</sub> (Hain Lifescience, Bandol, France) performed on sputum showed a positive signal for all wild-type sequences and for *rpoB* (S531L associated with RIF resistance) and *katG* (S315T associated with INH resistance) mutations, suggesting the presence of mixed susceptible and resistant *M. tuberculosis*. Second-line treatment was started: moxifloxacin, amikacin, ethionamide, para-aminosalicylic acid, cycloserine and

linezolid. The presence of mixed *M. tuberculosis* organisms in lungs was confirmed with culture methods and by phenotypic drug susceptibility testing (DST) that showed 1% resistant mutant to RIF and INH (proportion method) (1). The isolate was considered resistant to RIF and INH and was thus categorized as multidrug resistant (MDR). DST also showed that the sputum isolate had an elevated proportion of ofloxacin-resistant mutants (2 mg/L, 0.02% resistant mutants). Although no mutation in *gyrA* or *gyrB* was detected on colonies grown in the absence of fluoroquinolone, a *gyrB* N538D mutation was identified on colonies grown on ofloxacin medium. On the basis of the DST results, the treatment was changed to ethambutol, pyrazinamide, amikacin, moxifloxacin, para-aminosalicylic acid, and linezolid. CSF culture was eventually positive for *M. tuberculosis* on Lowenstein-Jensen medium after 30 days. DST performed on the CSF isolate showed a drug-sensitive phenotype; thus, RIF was reintroduced in addition to the other antimicrobial drugs. After 3 months, although the patient had improved, he left the hospital against medical advice without providing follow-up contact information.

Mycobacterial interspersed repetitive unit-variable number tandem repeat (MIRU-VNTR) analysis was conducted on culture of the sputum and CSF sample and on colonies grown on INH, RIF, and ofloxacin-containing medium, as described (2) (Table). This analysis showed different genotypes for the lung MDR and the CSF-susceptible isolates. None of the MIRU-VNTR patterns

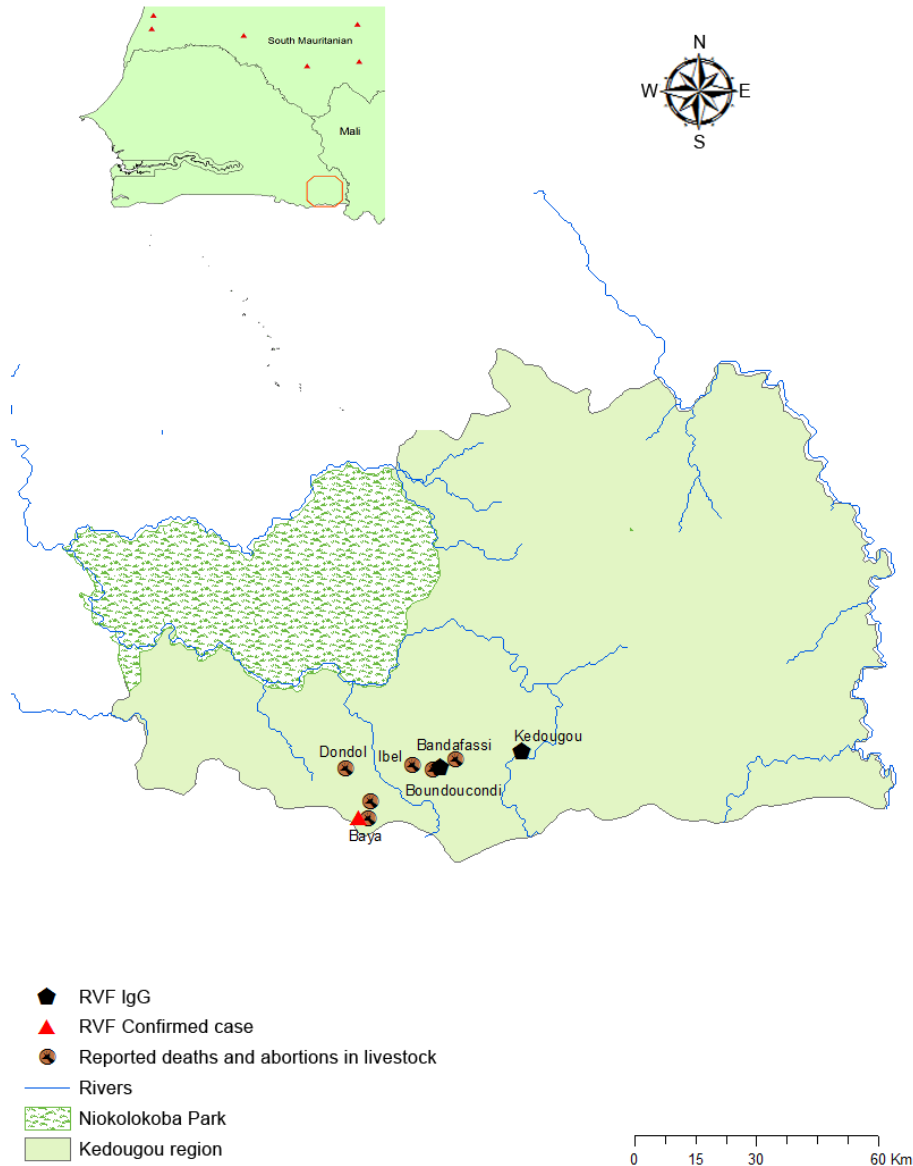
Table. Localization, drug-susceptibility results, and MIRU-VNTR genotypes of *Mycobacterium tuberculosis* strains recovered from a man with both pulmonary tuberculosis and tuberculous meningitis, France, 2012\*

Tissue	MIRU-VNTR genotype 1 222213222234225153333622	MIRU-VNTR genotype 2 224243122234225143335622
Lung	Isoniazid and rifampin resistant, fluoroquinolone susceptible, <i>rpoB</i> S531L, <i>katG</i> S315T, no mutations in <i>gyrA</i> and <i>gyrB</i>	Pan-susceptible except to fluoroquinolones, no mutations in <i>rpoB</i> , <i>katG</i> , and <i>gyrA</i> ; <i>gyrB</i> N538D
Cerebrospinal fluid		Pan-susceptible, no mutations in <i>rpoB</i> , <i>katG</i> , <i>gyrA</i> , and <i>gyrB</i>

\*MIRU-VNTR, mycobacterial interspersed repetitive unit-variable number tandem repeat.

# Rift Valley Fever in Kedougou, Southeastern Senegal, 2012

## Technical Appendix



Technical Appendix Figure. Geographic distribution of Rift Valley fever cases, southeastern Senegal, 2012.