

bronchitis, wheezing bronchitis, and pneumonia.

In the context of the previous reports of WUPyV detection in Australia and North America (3), our data suggest a worldwide distribution of WUPyV. Most of the WUPyV-positive children were <4 years of age, and WUPyV DNA was rarely found in children >6 years of age. This age distribution is compatible with WUPyV infection occurring in day nurseries and kindergartens. In keeping with the findings of Gaynor et al. (3), we observed a high number of co-infections. The true number of co-infections in our study is probably higher than the reported 53.2% because we did not test for several respiratory pathogens, such as coronaviruses, rhinoviruses, enteroviruses, and the human metapneumovirus. Hypotheses to account for the detection of WUPyV in respiratory samples include the following: WUPyV is a persisting asymptomatic virus that is detected by chance, WUPyV is a persisting virus that is reactivated by an inflammatory process, or WUPyV is a predisposing or aggravating factor of respiratory diseases. Further studies are necessary to determine whether WUPyV is a human pathogen.

Acknowledgments

We thank the team of the viral diagnostic laboratory for skillful and dedicated assistance.

Florian Neske,* Kerstin Blessing,† Franziska Ullrich,† Anika Pröttel,*† Hans Wolfgang Kreth,† and Benedikt Weissbrich*

*University of Würzburg, Würzburg, Germany; and †University Hospital of Würzburg, Würzburg, Germany

References

1. Ahsan N, Shah KV. Polyomaviruses and human diseases. *Adv Exp Med Biol*. 2006;577:1–18.

2. Allander T, Andreasson K, Gupta S, Bjerkner A, Bogdanovic G, Persson MA, et al. Identification of a third human polyomavirus. *J Virol*. 2007;81:4130–6.
3. Gaynor AM, Nissen MD, Whiley DM, Mackay IM, Lambert SB, Wu G, et al. Identification of a novel polyomavirus from patients with acute respiratory tract infections. *PLoS Pathog*. 2007;3:e64.
4. Weissbrich B, Neske F, Schubert J, Tollmann F, Blath K, Blessing K, et al. Frequent detection of bocavirus DNA in German children with respiratory tract infections. *BMC Infect Dis*. 2006;6:109.

Address for correspondence: Benedikt Weissbrich, Institute of Virology and Immunobiology, University of Würzburg, Versbacher Str 7, 97078 Würzburg, Germany; email: weissbrich@vim.uni-wuerzburg.de

Hepatitis E, Central African Republic

To the Editor: Outbreaks of hepatitis E virus (HEV) have been documented in many geographic regions and nonindustrialized countries (1–3); they have been primarily associated with fecal contamination of drinking water (4). In the Central African Republic (CAR), economic indicators (CAR ranks 172/177 countries on the 2006 United Nations Development Program Human Development Index), political instability, geographic situation, a deteriorating health network, and a very poor epidemiologic surveillance system all contribute to the country's epidemic susceptibility.

In July 2002, Ministry of Health (MoH) and Médecins sans Frontières (MSF) teams working in the Begoua Commune Health Center, north of CAR's capital Bangui, reported an increased number of patients from the Yembi I neighborhood who were showing signs of jaundice and extreme fatigue.

Patients suspected of having hepatitis E were defined as those with clinical jaundice (yellow discoloration of the sclera) and symptoms of malaise, anorexia, abdominal pain, arthralgia, and fever. Confirmed cases were those in which patients' serum samples were positive for HEV immunoglobulin (Ig) M or IgG.

Initially, 16 pairs of serum and stool samples were collected from jaundiced patients. Fecal samples were stored at –20°C and sent to the National Reference Center of Enterically Transmitted Hepatitis, Hospital Val de Grâce (Paris, France) for HEV marker testing; serum samples were tested at the Bangui Pasteur Institute for yellow fever (YF) IgM by MAC-ELISA.

The HEV epidemic was confirmed by the detection of HEV markers: HEV IgG (Enzyme Immuno Assay, HEV, Abbott Laboratories, Abbott Park, IL, USA), HEV IgM (Abbott Laboratories), amplification of RNA (5), and the absence of YF IgM. The HEV genome was detected in 4 of the fecal samples. Genotyping and sequencing showed that one of these was genotype 1, prevalent in Africa; the others were related to genotype 2 (Mexico-like) (GenBank accession nos. DQ151640, DQ151640) (5,6).

Data suggest that the epidemic began in the Yembi I neighborhood, then spread to the rest of the Begoua commune and finally to Bangui or surrounding areas (Figure). Of 715 suspected HEV case-patients recorded in the MSF hospital between July 22 and October 25, 2002, 552 (77%) lived in the Begoua commune (271 in the Yembi I neighborhood). The attack rate for the Begoua commune (20,080 inhabitants) was 2.7%. Of 351 suspected case-patients serologically tested for IgG and IgM anti-HEV antibodies, 222 (63%) had IgM antibodies, including 5/16 pregnant women (2.3% of all confirmed cases). Most patients reported jaundice (97.5%) and choluria (95.1%); other reported symptoms

were nausea and vomiting (37.9%), dyspepsia (28.3%), and hepatomegaly and/or splenomegaly (26.4%). Four of the confirmed case-patients died, a case-fatality ratio (CFR) of 1.8%; one was a pregnant woman (CFR 20% for pregnant women group).

No significant differences were found among confirmed case-patients by sex or age-group. Seventy-seven (34.6%) had relatives with suspected HEV, and 163 (73.5%) had drunk untreated water from their own wells.

These epidemiologic findings suggest the water-borne nature of this outbreak. Environmental testing of water from 2 wells (before chlorination was implemented) showed the water to be unsafe to drink (i.e., heat-resistant coliforms and aerobic bacteria were present) (7).

The outbreak was not surprising because a 1995 survey in Bangui showed anti-HEV antibodies in 24% of patients tested (8), indicating endemic HEV. Our results for IgG-positive patients were similar (23.2% in men and 20.1% in women). As demonstrated during other outbreaks (3), we found no significant difference between the distribution of HEV-positive patients by age or sex, although most patients were males (58%) and young adults (71% of ages 14–45 years).

The observed CFR was similar to that in other reported HEV outbreaks, in which CFR varied from 1% to 4% (9,10), but it was as high as $\geq 30\%$ in

pregnant women (9). Deliveries during pregnancy months 6–8 in this outbreak highlight the need for close surveillance of pregnant women affected by this disease.

We recommended application of preventive measures, including water disinfection, safe disposal of excreta, community health education, and the strengthening of case management and disease surveillance. For the CAR, free access to a safe water supply and drugs was the only way to achieve these goals.

The number of HEV cases in the Yembi I neighborhood declined after the crisis team implemented hygienic and chlorination measures in the district, although the number of cases remained constant in other neighborhoods of the commune (Figure). Definite conclusions cannot be drawn from this finding. First, the MSF hospital was within the Begoua commune. Thus, patients from the rest of Bangui (outside the commune) only started arriving at the center for treatment after hearing about the hospital through broadcast messages. Second, a military coup d'état during epidemiologic week 43 prevented us from conducting further surveillance.

Our results agree with international data on HEV outbreaks in other nonindustrialized countries. However, studies to improve our understanding of this epidemic and to identify the main risk factors involved would be beneficial.

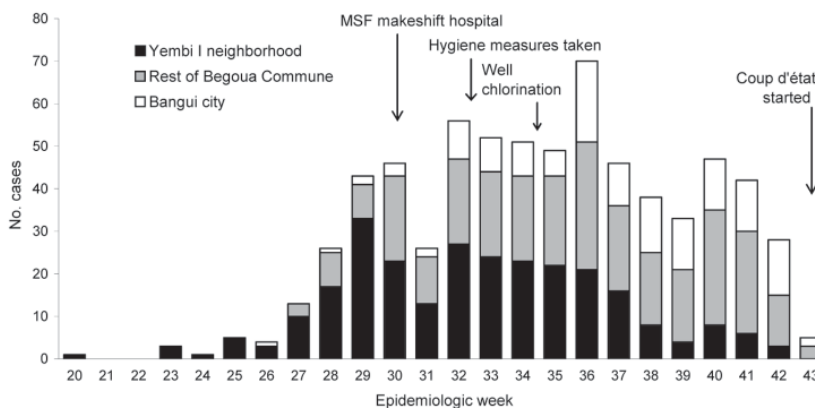


Figure. Suspected cases of hepatitis E virus in Begoua, Central African Republic, by neighborhood, weeks 20–43, 2002. MSF, Médecins sans Frontières.

Josep M. Escribà,^{*1}
Emmanuel Nakoune,†
Carlos Recio,*
Péguy-Martial Massamba,*
Marcelle Diane Matsika-Claquin,†
Charles Goumba,‡
Angela M.C. Rose,§
Elisabeth Nicand,¶ **Elsa García,***
Cornelia Leklegban,*
and Boniface Koffi‡

^{*}Médecins sans Frontières, Barcelona, Spain; [†]Institute Pasteur of Bangui, Bangui, Central African Republic; [‡]Ministry of Health, Bangui, Central African Republic; [§]University of the West Indies, Bridgetown, Barbados; and [¶]National Reference Centre for Enterically Transmitted Hepatitis, Val de Grâce, Paris, France

References

- Bryan JP, Iqbal M, Tsarev S, Malik IA, Duncan JF, Ahmed A, et al. Epidemic of hepatitis E in a military unit in Abbottabad, Pakistan. *Am J Trop Med Hyg.* 2002;67:662–8.
- Sedyaningsih-Mamahit ER, Larasati RP, Laras K, Sidemen A, Sukri N, Sabarudin N, et al. First documented outbreak of hepatitis E virus transmission in Java, Indonesia. *Trans R Soc Trop Med Hyg.* 2002;96:398–404.
- Benjelloun S, Bahbouhi B, Bouchrit N, Cherkaoui L, Hda N, Mahjour J, et al. Seroprevalence study of an acute hepatitis E outbreak in Morocco. *Res Virol.* 1997;148:279–87.
- Hyams KC. New perspectives on Hepatitis E. *Curr Gastroenterol Rep.* 2002;4:302–7.
- Tam AW, Smith MM, Guerra ME, Huang CC, Bradley DW, Fry KE, et al. Hepatitis E virus (HEV): molecular cloning and sequencing of the full-length viral genome. *Virology.* 1991;185:120–31.
- Van Cuyck-Gandré H, Zhang HY, Clements NJ, Cohen SG, Caudill JD, Coursaget P, et al. Partial sequence of HEV isolates from North Africa and Pakistan: comparison with known HEV sequences. In: Buisson Y, Coursaget P, Kane M, editors. *Enterically-transmitted hepatitis viruses. Joue-les-Tours (France): La Simarre; 1996. p. 301–10.*
- World Health Organization. Guidelines for drinking-water quality incorporating first addendum, 3rd edition. Vol. 1—recommendations. Geneva: The Organization; 2006 [cited 2006 Mar 10]. Available from http://www.who.int/water_sanitation_health/dwq/gdwq3rev

¹Current affiliation: Catalan Institute of Health, Barcelona, Spain.

8. Pawlotsky JM, Belec L, Gresenguet G, Deforges L, Bouvier M, Duval J, et al. High prevalence of hepatitis B, C and E markers in young sexually active adults from the Central African Republic. *J Med Virol.* 1995;46:269–72.
9. Guthmann JP, Klovstad H, Boccia D, Hamid N, Pinoges L, Nizou J, et al. A large outbreak of hepatitis E among displaced population in Darfur, Sudan, 2004: The role of water treatment methods. *Clin Infect Dis.* 2006;42:1685–91.
10. Bile K, Isse A, Mohamud O, Allebeck P, Nilsson L, Norder H, et al. Contrasting roles of rivers and wells as sources of drinking water on attack and fatality rates in hepatitis E epidemic in Somalia. *Am J Trop Med Hyg.* 1994;51:466–74.

Address for correspondence: Josep M. Escribà, Medical Department, Médecins sans Frontières, C/ Nou de la Rambla 23, E-08001 Barcelona, Spain; email: jescriba.bcn.ics@gencat.net

Rickettsia sibirica subsp. *mongolitimonae* Infection and Retinal Vasculitis

To the Editor: *Rickettsia sibirica* subsp. *mongolitimonae* is an intracellular bacterium that belongs to the species *R. sibirica* (1). To date, only 11 cases of infection with this bacterium have been reported (2–6). We report a case in a pregnant woman with ocular vasculitis.

A 20-year-old woman in the 10th week of her pregnancy was admitted in June 2005 to St. Eloi Hospital in Montpellier, France, with an 8-day history of fever, eschar, hemifacial edema, and headache. On examination the day of admission, she had a fever of 38.5°C, headache, and frontal eschar surrounded by an inflammatory halo. Painful retroauricular and cervical lymphadenopathies were noted. Results of a clinical examination

were otherwise within normal limits. No tick bite was reported by the patient, although she had been walking a few days before in Camargue (southern France). Serologic results for *R. conorii*, *R. typhi*, *Brucella* spp., *Borrelia* spp., and *Coxiella burnetii* were negative.

One day after admission, she reported loss of vision (scotoma) in her right eye. She underwent a complete ophthalmic evaluation. Measurement of visual acuity and results of a slit-lamp examination were within normal limits, but a fundoscopic examination showed a white retinal macular lesion that corresponded in a fluorescein angiograph to an area of retinal ischemia induced by vascular inflammation and subsequent occlusion (Figure). The following day, a rash with a few maculopapular elements developed, which involved only the palms of the hands and soles of the feet. Mediterranean spotted fever was suspected. Cyclines and fluoroquinolones were contraindicated because of her pregnancy, and the patient had a history of maculopapular rash after taking josamycin. She was treated with azithromycin, 500 mg/day

for 10 days, under close surveillance. After 2 days of treatment, she was afebrile and the rash completely resolved. No obstetric complications occurred and she gave birth to a healthy boy at term. Two years later, the right scotoma remained unchanged.

Serologic tests for rickettsiosis were performed with an acute-phase serum sample and a convalescent-phase serum sample (1 month after onset of symptoms). Samples were sent to the World Health Organization Collaborative Center in Marseille for rickettsial reference and research. Immunoglobulin (Ig) G and IgM titers were estimated by using a microimmunofluorescence assay; results were negative. Culture of a skin biopsy specimen from the eschar showed negative results.

DNA was extracted from eschar biopsy specimen and used as template in a PCR with primers complementary to portions of the coding sequences of the rickettsial outer membrane protein A and citrate synthase genes as described (5). Nucleotide sequences of the PCR products were determined. All sequences shared 100% similar-

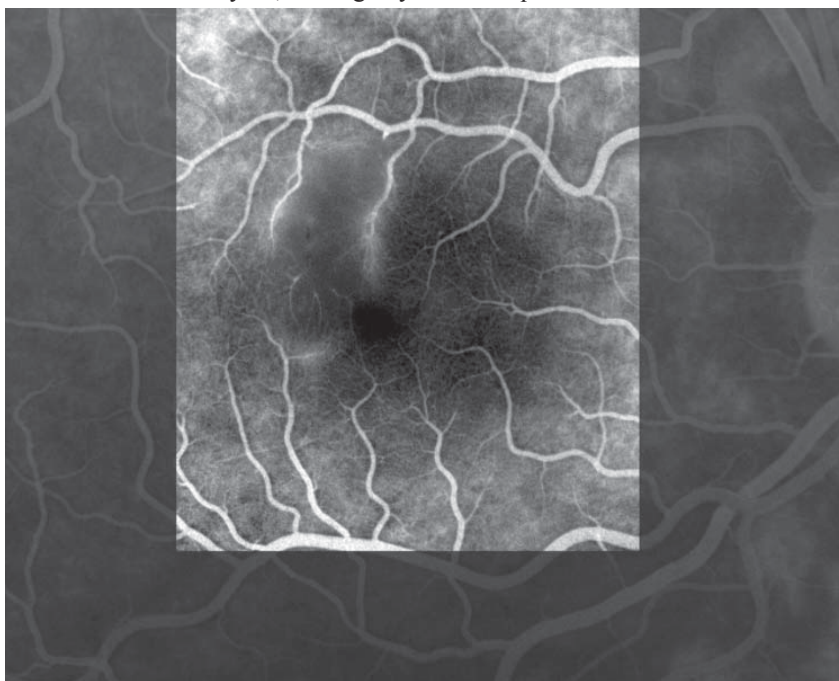


Figure. Fluorescein angiograph of the right eye of the patient showing retinal occlusive vasculitis with arteriolar leakage at late phase.