

Hepatitis, Rash and Eosinophilia Following Trichloroethylene Exposure: A Case Report and Speculation on Mechanistic Similarity to Halothane Induced Hepatitis

G. Randall Bond, MD

*Department of Emergency Medicine,
University of Virginia, Charlottesville, Virginia*

ABSTRACT

***Case Report:** A previously healthy 30-year-old male began work as a degreaser. The solvent used in the degreasing operation was trichloroethylene. Over the next month he experienced symptoms of weakness, dizziness, decreased appetite, nausea, abdominal pain, diarrhea, fever, chills, dry skin, red rash with bumps, peeling face, and itching. At that time he had marked liver enzyme elevation without evidence of cholestasis. CBC was remarkable for a significant number of atypical lymphocytes. Two weeks later his liver enzymes showed a marked reduction in ALT from a peak of 1250 IU to 717 IU. Tests for Hepatitis A, B, and C, CMV, HIV1 were all negative. The night following his first day back at work he had a recurrence of a red, diffuse rash without any consumption of alcohol. The rash caused tremendous itching. Over the next few days off work the rash continued and peeled. Physical examination one week after re-exposure was remarkable for diffuse, erythematous rash; some peeling skin and pitting edema to the knees. ALT was 517 IU/L. White blood cell count was 10,100/mm³ with 27% eosinophilia. **Conclusion:** This patient had possibly experienced sensitization to trichloroethylene, or more likely, to one of its metabolites. Similar symptoms attributed to trichloroethylene have been reported in only a few other patients. Patch testing with trichloroethylene and its metabolites may better clarify a causal relationship in future patients. If an immune mechanism is involved it may be similar to one postulated for halothane induced hepatitis.*

Correspondence: Dr. G. Randall Bond, Box 523-21, University of Virginia Hospital, Charlottesville, VA 22908. Tel: 804/924-9152; Fax: 804/924-5656.

Case Report

A previously healthy 30-year-old male began working as a degreaser. The solvent used in the degreasing operation was trichloroethylene (TCE). When performing his job he stood outside of the degreasing machine, reaching in through an opening to clean metal parts. He did not wear any respiratory protection since the TCE was cooled and the process was performed under a hood with ventilation. His employer had conducted air quality studies in the area around his ventilatory space and documented that levels of TCE were not in excess of Occupational Safety and Health Administration standards (STEL 200 ppm). However, the patient noted that he could smell the TCE (odor threshold 100 ppm) and that he occasionally experienced a mild lightheaded feeling (unlike drunkenness) with TCE exposure. He also had enough exposure to TCE to develop degreasers' flush when he consumed alcohol after work. On only one occasion had he put his head inside the machine. At that time he began to feel drunk but took his head out before collapsing. He recovered almost immediately.

Over the first few weeks of his employment he began to experience symptoms of weakness, dizziness, decreased appetite, nausea, abdominal pain, diarrhea, fever, chills, dry skin, red rash with bumps, peeling face, and itching. The patient was taking no medications. He reported ethanol use of 1-2 beers per day during the week and 4-5 beers per day on the weekend. He is exclusively heterosexual and denied all past or present recreational drug abuse except for marijuana. He had no hobby, past work or other environmental exposures to hepatotoxins.

Evaluation by his physician one month later revealed marked hepatic enzyme elevation (AST 551 IU/L, ALT 1250 IU/L) without evidence of cholestasis (AP 87 IU/L, total bilirubin 0.9 mg/dL). CBC was remarkable for a white count which was not elevated and for a significant number of atypical lymphocytes. A viral etiology was considered but tests for Hepatitis A, B, and C were negative as were tests for HIV1 and CMV.

He was off work for two weeks. He had not consumed alcohol since the diagnosis of hepatitis. He also had not been smoking for several weeks, since observing that cigarettes had a sweet taste even though he washed his hands and took off his gloves

prior to igniting the cigarettes. He associated this with the smell of the TCE. On the day prior to returning to work he was feeling better, although not totally normal. His ALT was 717 IU/L.

He returned to work two weeks later. He did not feel particularly ill at work that day although he noted some of the usual lightheadedness. That night he had a recurrence of a red, diffuse rash without the consumption of alcohol. He described this rash as being similar to the degreasers' flush but with tremendous itching. Over the next few days off work the rash continued and he developed swelling in his legs. At this same time he again noted drying of the skin over his hands and face with some peeling (as at the time of his original presentation with hepatitis). This time the rash was somewhat different in that it did not have any red bumps, just the diffuse redness.

Examination one week later revealed an awake, alert, and healthy looking man, appearing his stated age. Vital signs were BP 140/70 mm Hg; HR 80 bpm; RR 14/min; T 36.6°C. The remainder of the physical examination was remarkable only for the dermal and abdominal examination. He had a diffuse, mildly erythematous color to his skin which blanched with pressure. There was dryness over his face and hands with some peeling. There were a few papules scattered on his forehead. His abdominal examination was remarkable only for mild discomfort in the right upper quadrant. Liver span was 10 cm by percussion.

Laboratory evaluation at that time showed: ESR 3 mm/h; Hgb 13.9 g/dL, hematocrit 42%, Wbc 10,100 (45% N, 19% L, 6% M and 27% E); PT 12.5 seconds; total protein 6.0; albumin 3.7; AST 133 IU/L; ALT 517 IU/L; LDH 645 IU/L; AP 92 IU/L; total bilirubin 0.8 mg/dL.

On follow-up 10 weeks after beginning employment, he was much improved. He returned to work with the restriction that he not be exposed to TCE. Since then he has had no complaints of rash or illness. Follow up hepatic enzyme testing was entirely normal.

DISCUSSION

Several cases of purported TCE sensitization are described in the literature (Table 1). An Israeli woman with similar exposure was also noted to have

Table 1
Dermatitis with Systemic Symptoms Attributed to TCE

	Reference	Rash	Hepatitis	Fever	Recurrence or Eosinophilia Reexposure
Present report	yes	yes	yes	yes	yes, symptomatic
Schattner and Malnick					
Case 1	yes	yes	yes	yes	yes, symptomatic
Bauer and Rabens					
Case 2	yes			yes	unknown
Case 3	yes	yes		yes	unknown
Case 4	yes		yes		unknown
Phoon <i>et al.</i>					
Case 1	yes	yes	yes		no
Case 2	yes	yes	yes		no
Case 3	yes	yes			patch skin test negative
Case 4	yes	yes			yes, fatal hepatitis
Case 5	yes	yes			no
Nakayama <i>et al.</i>					
Case 1	yes	yes	yes		patch skin test positive

fever, marked eosinophilia and hepatic enzyme elevation without hyperbilirubinemia.¹ She also experienced a recurrence of symptomatology on re-exposure to TCE. In a series from Los Angeles, three patients exposed to TCE are described to have had various combinations of low grade fever, liver enzyme elevation and exfoliative dermatitis or macular papular rash.² In a case series from Singapore, five patients are described with Stevens-Johnson Syndrome and hepatitis.³ One patient died. All presented within 2 to 5 weeks of the onset of exposure to TCE. In Japan, a 21-year-old printer experienced exfoliative dermatitis with mucous membrane involvement, fever and hepatic enzyme elevation following a two week occupational exposure.⁴ A positive patch test to TCE and trichloroethanol was noted.

Establishing a cause and effect association between TCE and the rash and hepatitis observed is quite difficult. The reports in the literature are presumptive. All cases reported a work history of TCE exposure. Biological testing to confirm exposure was performed only in some of the patients.

Causal association was based on recurrence of symptoms upon re-exposure in three cases (including skin testing in one patient), and similarity of presentation in seven others.

Similarly, the case for an association between TCE and the symptoms in the patient in this report is entirely circumstantial. Although no biological monitoring studies were performed, workplace exposure is consistent with information provided by his employer and the workplace habits he described. Additional studies such as follow up viral hepatitis titers and, possibly, skin testing would be desirable but were not performed. In the context of the other reports, this patient's features of fever, eosinophilia, hepatocellular injury and rash (re-manifested on re-exposure to TCE), suggest that he may have become sensitized to TCE or one of its metabolites.

The role of skin testing for TCE sensitivity should be clarified. Patch skin testing was performed in two patients but it was only positive in one. One of the Singapore cases was patch tested only with TCE (5% in olive oil) six months after his acute illness. He had no reaction. In the Japanese case, patch

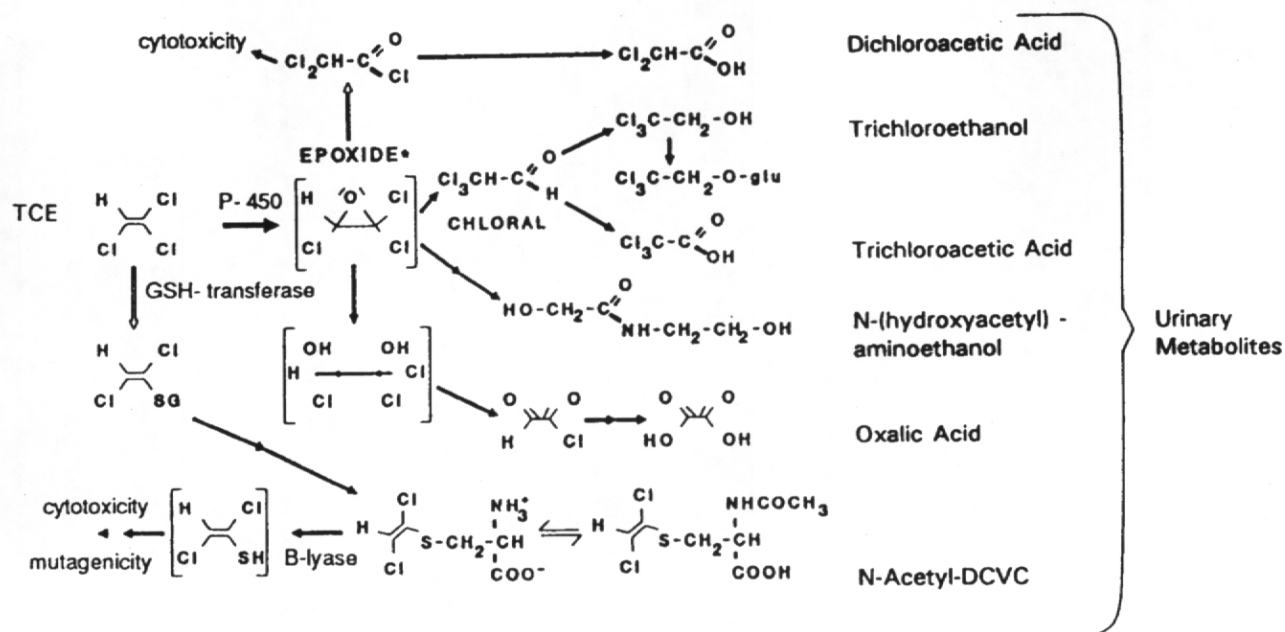


Figure 1. Intermediates and final metabolites of TCE metabolism. Adapted with permission from Reference 5.

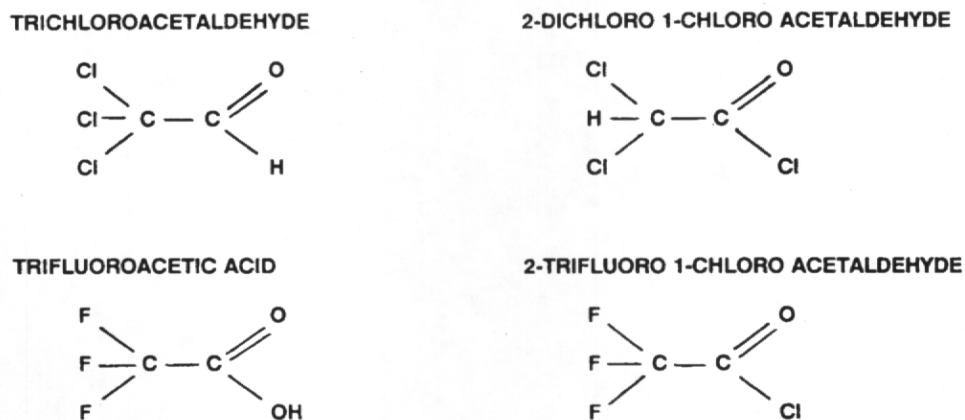


Figure 2. Structural similarity of human TCE metabolites (upper) and halothane metabolites (lower).

testing was conducted using TCE in olive oil, trichloroethanol in water and trichloroacetic acid. The patient's response was weakly positive to 10% and 25% concentrations of TCE but not to a 5% concentration. It was moderately positive to three very dilute concentrations of trichloroethanol (5%, .05%, .005%) but negative to a 5% concentration of trichloroacetic acid. This patient's illness was postulated to be a delayed hypersensitivity to the

TCE metabolite trichloroethanol.

The possibility of sensitivity to a metabolite of TCE rather than the native molecule changes the interpretation of skin testing. If the chemical is metabolized to a compound which alone or as a protein-hapten complex induces sensitivity, patch testing will only be positive if the metabolite is used or if there is sufficient cross reactivity between the antigen and the tested chemical. Reactivity may

further vary if the metabolite readily forms a protein hapten conjugate but the tested chemical does not. Reactive metabolites may be particularly relevant when considering sensitization to TCE. TCE has many metabolites (Figure 1).⁵ In addition to trichloroethanol, its precursor trichloroacetaldehyde and two other metabolites of the P-450 pathway, dichloroethylene glycol and the cytotoxic 2-dichloro 1-chloro acetaldehyde should be considered potential sensitizers. If skin testing is performed in symptomatic patients following TCE exposure it should include these or compounds close to these if possible.

Inhalational testing is unlikely to be diagnostic and should be avoided. The delay in recurrence of symptoms following re-exposure in the case in this report and those in the literature suggests IgG or IgM associated cell mediated immune response rather than an IgE mediated hypersensitivity. Further, fatal hepatic injury in one individual was attributed to workplace re-challenge.³

A model for TCE associated hepatitis may be halothane hepatitis. Like halothane, TCE is a two carbon poly-halogenated hydrocarbon. Halothane associated hepatitis has been described for many years. Halothane associated hepatitis is rare, occurring in from 1 in 3,000 to 1 in 30,000 episodes of halothane anesthesia.⁶ However, halothane induced hepatitis occurs more frequently in patients previously exposed to halothane. Sometimes it is associated with eosinophilia.⁶ Rarely a rash has been described.⁶ Because of these features, an autoimmune mechanism has been postulated.⁶ Recent evidence from Europe suggests that this injury may be mediated by an antibody formed to trifluoroacetylated proteins which cross react with hepatic cellular components.⁷⁻¹⁰ Trifluoro metabolites of halothane include a 2-trifluoro 1-chloro acetaldehyde intermediate and trifluoroacetic acid, structurally similar to metabolites of TCE (Figure 2).¹¹

Since most patients exposed to halothane develop trifluoroacetylated proteins, speculation as to the rarity of halothane induced hepatitis centers on the possibility that the immune surveillance system in most individuals does not recognize trifluoroacetylated proteins as foreign, i.e. that some component of native tissue resembles these compounds closely enough to inhibit formation of

antibodies.^{8,10} However, in some individuals, either due to a failure of the immune surveillance system or due to subtle differences in native proteins, formation of antibodies to trifluoroacetylated proteins is not prevented. These antibodies initiate the process of halothane associated hepatitis. This speculation is further supported by demonstration of antibodies in patients with halothane induced hepatitis which react with hepatic microsomal components (carboxylesterase and, particularly, the dihydrolipoamide acetyltransferase of pyruvate dehydrogenase).⁷⁻⁹

The uniqueness of individuals with TCE associated hepatitis, rash and eosinophilia may be either in their metabolism of TCE or in their failure to prevent the formation of an antibody which cross reacts with native hepatic elements. The products of TCE metabolism in these individuals may include more reactive intermediates. Alternately, these individuals may make an antibody which cross reacts with native hepatic antigens.

REFERENCES

- Schattner A, Malnick SD. Anicteric hepatitis and uveitis in a worker exposed to trichloroethylene. *Postgrad Med J* 1990;66:730-731.
- Bauer M, Rabens SF. Cutaneous manifestations of trichloroethylene toxicity. *Arch Dermatol* 1974;110:886-890.
- Phoon WH, Chan MO, Rajan VS, Tan KJ, Thirumoorthy T, Goh CL. Stevens-Johnson syndrome associated with occupational exposure to trichloroethylene. *Contact Dermatitis* 1984;10:270-276.
- Nakayama H, Kobayashi M, Takahashi M, Ageishi Y, Takano T. Generalized eruption with severe liver dysfunction associated with occupational exposure to trichloroethylene. *Contact Dermatitis* 1988;19:48-51.
- Davidson IW, Beliles RP. Consideration of the target organ toxicity of trichloroethylene in terms of metabolite toxicity and pharmacokinetics. *Drug Metab Rev* 1991;23:493-599.
- Ray DC, Drummond GB. Halothane hepatitis. *Br J Anaesth* 1991;67:84-99.
- Christen U, Quinn J, Yeaman SJ, et al. Identification of the dihydrolipoamide acetyltransferase subunit of the human pyruvate dehydrogenase complex as an autoantigen in halothane hepatitis. Molecular mimicry of trifluoroacetyl-lysine by lipoic acid. *Eur J Biochem* 1994;223:1035-1047.
- Gut J, Christen U, Huwylar J, Burgin M, Kenna JG.

- Molecular mimicry of trifluoroacetylated human liver protein adducts by constitutive proteins and immunochemical evidence for its impairment in halothane hepatitis. *Eur J Biochem* 1992;210:569-576.
9. Smith GC, Kenna JG, Harrison DJ, Tew D, Wolf CR. Autoantibodies to hepatic microsomal carboxylesterase in halothane hepatitis. *Lancet* 1993;342:963-964.
 10. Gut J, Christen U, Huwyler J. Mechanisms of halothane toxicity: novel insights. *Pharmacol Ther* 1993;58:133-155.
 11. Cousins MJ, Sharp JH, Gourlay GK, Adams JF, Haynes WD, Whitehead R. Hepatotoxicity and halothane metabolism in an animal model with application for human toxicity. *Anaesth Intensive Care* 1979;7:9-24.