

## ***Chlamydia pneumoniae* Infection in a Breeding Colony of African Clawed Frogs (*Xenopus tropicalis*)**

Kurt D. Reed,\* George R. Ruth,† Jeanine A. Meyer,\*  
and Sanjay K. Shukla\*

\*Marshfield Medical Research Foundation, Marshfield, Wisconsin, USA;  
and †Marshfield Laboratories, Marshfield, Wisconsin, USA

More than 90% of a breeding colony of clawed frogs (*Xenopus tropicalis*) imported to the United States from western Africa died in an epizootic of chlamydiosis. Chlamydial inclusions were observed by light and electron microscopy in the liver of an infected frog. *Chlamydia pneumoniae* was isolated in cell cultures from four frogs. A cutaneous infection by a chytridiomycete fungus observed in two frogs could have been a cofactor in the die-off.

*Chlamydia* infections cause disease in humans, birds, and mammals. Of the four currently recognized *Chlamydia* species, *C. psittaci* is the most important animal pathogen. Psittacosis, which can manifest as severe enteric and respiratory illness in many avian species, is highly contagious and can be transmitted to humans and many other mammals (1). *C. pecorum*, the newest species to be recognized, appears to have a highly restricted host range. Infections due to *C. pecorum* have been associated with sporadic encephalitis, polyarthritides, pneumonia, and conjunctivitis in pigs, sheep, cattle, and koalas (2,3). *C. trachomatis*, an agent responsible for millions of cases of ocular and urogenital infections worldwide, causes most chlamydial infections in humans. *C. pneumoniae*, an acute respiratory tract pathogen of cosmopolitan distribution, may be linked with chronic diseases such as coronary atherosclerosis and multiple sclerosis (1,4,5).

Initial reports of infections due to *C. pneumoniae* suggested that the organism's host range was limited to humans. Subsequently, infections due to *C. pneumoniae* have been documented in koalas, a horse, and most recently, a giant barred frog (*Mixophyes iteratus*) from Australia (6-8). We report an epizootic of

chlamydiosis due to *C. pneumoniae* in a commercial colony of African clawed frogs (*Xenopus tropicalis*).

In July 1998, a biologic supply company located in the midwestern United States imported 241 *X. tropicalis* from western Africa to start a breeding colony. Upon arrival, the frogs were placed in quarantine. Within 4 months, 220 (91%) of the frogs had died. Before death, most of the frogs had sloughing of the skin and lethargy and appeared bloated. Two frogs were submitted to our veterinary diagnostic laboratory for necropsy. On external examination, the frogs were 5.5 cm and 5.2 cm from snout to vent and weighed 6.5 gm and 29.5 gm, respectively. Both frogs had roughening and early sloughing of the posterior skin. The smaller frog had scattered subserosal intestinal and hepatic nodules containing tetrathyridian cestodes. The larger frog was extremely edematous, with clear gelatinous fluid in the subcutaneous tissues and body cavities. In hematoxylin- and eosin-stained 4- $\mu$ m sections of liver from the larger frog, there was moderate to severe lymphohistiocytic hepatitis with individual hepatocyte necrosis, fibrosis, and numerous granular basophilic bodies resembling bacteria within hepatocytes and histiocytes. Transmission electron microscopy of liver tissue from the larger frog confirmed the presence of bacteria replicating within vacuoles of infected cells. The organisms had a biphasic structure consistent with a *Chlamydia* spp. (Figure). Other

Address for correspondence: Kurt D. Reed, Clinical Research Department, Marshfield Medical Research Foundation, 1000 N. Oak Avenue, Marshfield, WI 54449, USA; fax:715-389-4145; e-mail: reedk@mfldclin.edu.

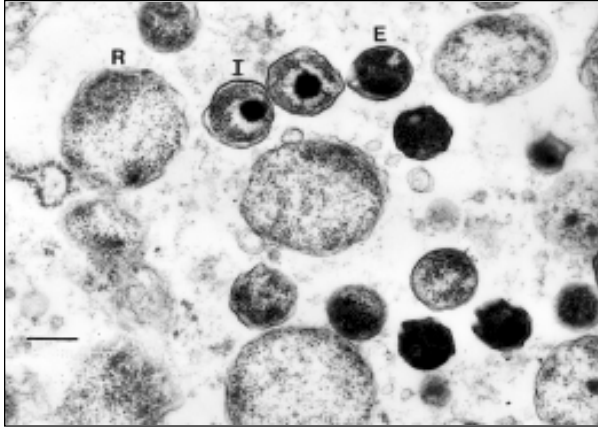


Figure. Transmission electron micrograph of chlamydial particles in liver from a captive African clawed frog (*Xenopus tropicalis*). Note the reticulate bodies (R), intermediate bodies (I), and highly condensed elementary bodies (E). Bar, 270 nm.

lesions present in both frogs included mild to moderate lymphohistiocytic interstitial pneumonia and mild lymphocytic interstitial nephritis. No chlamydial inclusions were observed in other organs by light microscopy. Both frogs had multifocal epidermal hyperplasia with numerous intracorneal fungal organisms characterized by thick-walled sporangia containing multiple 2- $\mu$ m to 3- $\mu$ m round spores. Many of the sporangia had single tubular extensions (discharge papillae) directed toward the skin surface, and transmission electron microscopy showed the spores had flagella. These features were considered diagnostic of a chytridiomycete fungus (9).

To further characterize the *Chlamydia* species, liver samples were submitted for culture from the larger frog and three additional frogs obtained subsequently from the same breeding colony. Tissue homogenates were injected into shell-vials having monolayers of either buffalo green monkey kidney (BGMK), Hep-2, McCoy, or HeLa - 229 cells. Cultures were incubated at 35°C for 72 hours and then the cell monolayers were stained with a fluorescein-conjugated monoclonal antibody specific for the genus *Chlamydia* (Pathfinder, Kallestad, California). *Chlamydia* grew from all four liver specimens and in all the cell lines used. The organism grew better, with more and larger inclusions, in the McCoy and BGMK cell lines.

*Chlamydia* was identified by sequence analysis of the 16S rDNA and major outer membrane protein A (*ompA*) genes. Bacterial

DNA was extracted by lysis (Generations, Gentra, Maryland) of liver and cell culture specimens from each of the four frogs. The broad-range eubacterial primers FD1(5'-AGAGTTTG ATCCTGGCTCAG-3') and RD1(5'-AAGGAGGTG ATCCAGCC-3') were used in a polymerase chain reaction (PCR) to amplify a 1,520-bp segment of the 16S rDNA gene (10); primers 20CHOMP (5'-TTAGAGGTRAGWATGAARAA-3') and CHOMP371 (5'-TAGAAICKGAATTGIGCRTTI AYGTTGIGCIGC-3') were used to amplify a 1,200-bp segment of the *ompA* gene (11). Agarose gel electrophoresis of the PCR products yielded single bands for each specimen. Amplified products were column purified to remove unincorporated primers and nucleotides, and sense and antisense strands were sequenced by using nested primers in an automated laser fluorescent sequencer (ALF Express, Amersham Pharmacia Biotech, New Jersey). Sequence fragments were aligned with the assembly software program DNAsis 2.5 (Hitachi, California), and ambiguities resolved. A contiguous sequence was established from the overlapping regions, which were used as a query sequence in the GenBank database.

The 1,520-bp 16S rDNA sequences from the *Chlamydia* infecting the four *X. tropicalis* (GenBank-AF139200) were identical to one another and had 99.1%, 99.3%, and 99.4% homology with published sequences for *C. pneumoniae* strains N16 (U68426.2), CWL026 (AE001668), and TW-183 (L06108), respectively. In addition, there was 100% homology with the 235-bp segment of 16S rDNA reported for the *C. pneumoniae* isolated recently from the giant barred frog from Australia (AF102832). In contrast, there was 96.0% sequence homology with *C. psittaci* strain 6BC (U68447.2), 95.7% homology with *C. pecorum* strain E58 (D88317.1), and 93.8% homology with *C. trachomatis* strain D/UW-3/CX (AE001345).

The sequence of a 279-bp segment of the variable domain IV region of the *ompA* gene was determined for one of the frog *Chlamydia* isolates (AF184214). There were six nucleotide differences (97.8% homology) from the giant barred frog biovar of *C. pneumoniae* (AF102830) and three differences (98.9% homology) from *C. pneumoniae* strain CWL029 (AE001652). Less than 75% homology was observed with the *ompA* variable domain IV sequences reported for the three other *Chlamydia* species (results not shown).

Previous reports of confirmed *Chlamydia* infections among captive amphibians in North America involved *X. laevis*, another member of the African clawed frog family (12-14). These reports occurred before the discovery and molecular characterization of *C. pneumoniae*, and the *Chlamydia* species involved were either not known or presumed to be *C. psittaci*. Our study is the second documented report of *C. pneumoniae* involving an amphibian and the first describing an epizootic in a captive population of *X. tropicalis*.

The spectrum of clinical disease and histopathologic lesions associated with chlamydial infections in amphibians is unknown. In our study, only two animals were evaluated histologically. The more severely affected animal had active hepatitis with hepatocyte necrosis, lymphohistiocytic infiltrates, and inclusion bodies within hepatocytes and sinusoidal histiocytes. These lesions are similar to those observed in a 1984 outbreak of chlamydiosis among laboratory-bred *X. laevis*; in that outbreak, hepatosplenomegaly and histologic evidence of active hepatitis were the major pathologic findings in affected animals (12). In the recent case of *C. pneumoniae* involving a free-ranging giant barred frog, the predominant necropsy findings were chronic mononuclear pneumonia, nonregenerative anemia, and pancytopenia (8). Additional studies will be necessary to determine the epidemiology and virulence of *C. pneumoniae* in captive and free-ranging populations of amphibians and reptiles, as well as the pathogenicity and transmissibility of this agent to humans and other mammals.

This breeding colony had >90% deaths during the 4-month epizootic, and the few surviving frogs appeared ill and were subsequently euthanized. We were unable to determine the prevalence of *C. pneumoniae* infection in the colony but believe that it was very high, since all four frogs submitted for culture were positive. The crowding and stress associated with the captive environment may have contributed to spread of infection within the colony. The potential for zoonotic transmission of *C. pneumoniae* from amphibians to humans has important public health implications, especially in situations involving frequent and prolonged human contact with amphibians in crowded conditions, such as commercial breeding colonies or zoos. Until more is known about the host range of this pathogen,

chlamydiosis should at least be considered in the differential diagnosis of an unexplained respiratory or febrile illness in persons exposed to amphibians.

Whether *Chlamydia* was the primary pathogen responsible for the die-off or served as a cofactor with the chytrid fungus or other parasites was difficult to determine. Although the *Chlamydia* infection is the primary focus of this report, the presence of cutaneous chytridiomycosis in two of the frogs is also important. This highly pathogenic zoosporic fungus has only been found in the American and Australian continents, where it has been implicated as a major factor in amphibian deaths and population declines in the rain forests (9). The origin of the chytrid fungus found in our cases was not determined. However, the rapid onset of illness affecting the frogs after their arrival in the United States suggests that at least some of the frogs may have been infected before capture.

The pipid frog *X. tropicalis* has a diploid genome and short generation time, which make it an ideal model organism for multigenerational genetic analysis. Current demand for this species is higher than most biologic supply companies can meet. Continued importation of *X. tropicalis* and other amphibians from regions of the world experiencing poorly understood population declines raises concern about the inadvertent spread of virulent pathogens to naive populations of amphibians and reptiles, as well as transmission of these agents to mammals. Until more is known about the epidemiology and prevention of these infections, caution must be exercised in transportation, husbandry, and human contact with these animals.

### Acknowledgments

The authors thank Lynn Ivacic for expert technical assistance with the chlamydial cultures, Donald Stoiber for preparing the electron micrographs, and the veterinary pathology section of the Armed Forces Institute of Pathology for identifying the cestodes and reviewing the histopathology.

This work was supported in part by grants from the Marshfield Medical Research Foundation. Jeanine Meyer was an undergraduate research fellow of Marshfield Clinic.

Dr. Reed is a clinical pathologist and director of Clinical Research at the Marshfield Medical Research Foundation. His research focuses on the diagnosis and molecular epidemiology of tickborne and other zoonotic pathogens.

## References

1. Schacter J. Infection and disease epidemiology. In: *Chlamydia: intracellular biology, pathogenesis, and immunity*. Stephens RS, editor. Washington: American Society for Microbiology Press; 1999. p. 139-69.
2. Fukushi H, Hirai K. Proposal of *Chlamydia pecorum* sp. nov. for *Chlamydia* strains derived from ruminants. *Int J Syst Bacteriol* 1992;42:306-9.
3. Glassick TV, Giffard P, Timms P. Outer membrane protein 2 gene sequence indicates that *Chlamydia pecorum* and *Chlamydia pneumoniae*, cause infection in koalas. *Syst Appl Microbiol* 1996;19:457-64.
4. Kuo C, Jackson LA, Campbell LA, Grayston JT. *Chlamydia pneumoniae* (TWAR). *Clin Microbiol Rev* 1995;8:451-61.
5. Campbell LA, Kuo C, Grayston JT. *Chlamydia pneumoniae* and cardiovascular disease. *Emerg Infect Dis* 1998;4:571-9.
6. Jackson M, White N, Gifford P, Timms P. Epizootic of *Chlamydia* infection in two free-ranging Koala populations. *Vet Microbiol* 1999;65:255-64.
7. Storey C, Lusher M, Yates P, Richmond S. Evidence for *Chlamydia pneumoniae* of non-human origin. *Journal of General Microbiology* 1993;139:2621-6.
8. Berger L, Volp K, Mathews S, Speare R, Timms P. *Chlamydia pneumoniae* in a free-ranging giant barred frog (*Mixophyes iteratus*) from Australia. *J Clin Microbiol* 1999;37:2378-80.
9. Berger L, Speare R, Daszak P, Green DE, Cunningham AA, Goggin CL, et al. Chytridiomycosis causes amphibian mortality associated with population declines in the rain forests of Australia and Central America. *Proc Nat Acad Sci U S A* 1998;95:9031-6.
10. Weisburg WG, Barns SM, Pelletier DA, Lane DJ. 16S ribosomal DNA amplification for phylogenetic study. *J Bacteriol* 1991;173:697-703.
11. Kaltenboeck B, Kousoulas KG, Storz J. Structures of and allelic diversity and relationships among the major outer membrane protein (*ompA*) genes of four chlamydial species. *J Bacteriol* 1993;175:487-502.
12. Howerth EW. Pathology of naturally occurring chlamydiosis in African clawed frogs (*Xenopus laevis*). *Vet Pathol* 1984;21:28-32.
13. Newcomer CE, Anver MR, Simmons JL, Wilcke BW, Nace GW. Spontaneous and experimental infections of *Xenopus laevis* with *Chlamydia psittaci*. *Lab Anim Sci* 1982;32:680-6.
14. Wilcke BW, Newcomer CE, Anver MR, Simmons JL, Nace GW. Isolation of *Chlamydia psittaci* from naturally infected African clawed frogs (*Xenopus laevis*). *Infect Immun* 1983;41:789-94.