

## Sporotrichosis Cluster in Domestic Cats and Veterinary Technician, Kansas, USA, 2022

Ian Hennessee, Erin Barber, Erin Petro, Stephanie Lindemann, Bryan Buss, Amanda Santos, Lalitha Gade, Shawn R. Lockhart, D. Joseph Sexton, Tom Chiller, Mitsuru Toda

Author affiliations: Centers for Disease Control and Prevention, Atlanta, Georgia, USA (I. Hennessee, B. Buss, A. Santos, L. Gade, S.R. Lockhart, J. Sexton, T. Chiller, M. Toda); Republican Valley Veterinary Clinic, Saint Francis, Kansas, USA (E. Barber); Kansas Department of Health and Environment, Topeka, Kansas, USA (E. Petro, S. Lindemann); Nebraska Department of Health and Human Services, Lincoln, Nebraska, USA (B. Buss)

DOI: <http://doi.org/10.3201/eid3005.231563>

We describe a feline sporotrichosis cluster and zoonotic transmission between one of the affected cats and a technician at a veterinary clinic in Kansas, USA. Increased awareness of sporotrichosis and the potential for zoonotic transmission could help veterinary professionals manage feline cases and take precautions to prevent human acquisition.

**S**porotrichosis, an implantation mycosis caused by fungi in the genus *Sporothrix*, affects humans and other mammals. Although cat-transmitted sporotrichosis caused by the highly transmissible *Sporothrix brasiliensis* species is an increasing concern in Latin America (1), *S. brasiliensis* has not been detected in the United States, and cat-transmitted *Sporothrix schenckii* is rarely reported (2,3). We describe a cluster of sporotrichosis cases involving 2 domestic cats and zoonotic transmission between one of the affected cats and a veterinary technician in Kansas, USA.

In August 2022, a pregnant, 2-year-old, indoor-outdoor cat was brought to a veterinary clinic in northwest Kansas with an ulcerated lesion on her distal paw thought to be from a cat fight. She was initially treated with amoxicillin-clavulanic acid, but the wound worsened over the next month and additional ulcerated lesions developed along the rest of the forelimb (Figure, panel A).

The veterinarian performed an impression smear, which revealed cytology consistent with *Sporothrix* (Figure, panel B). The cat was treated with 10 mg/kg itraconazole and meloxicam in addition to amoxicillin-clavulanic acid. The cat improved on antifungal medication and gave birth to 2 healthy kittens in

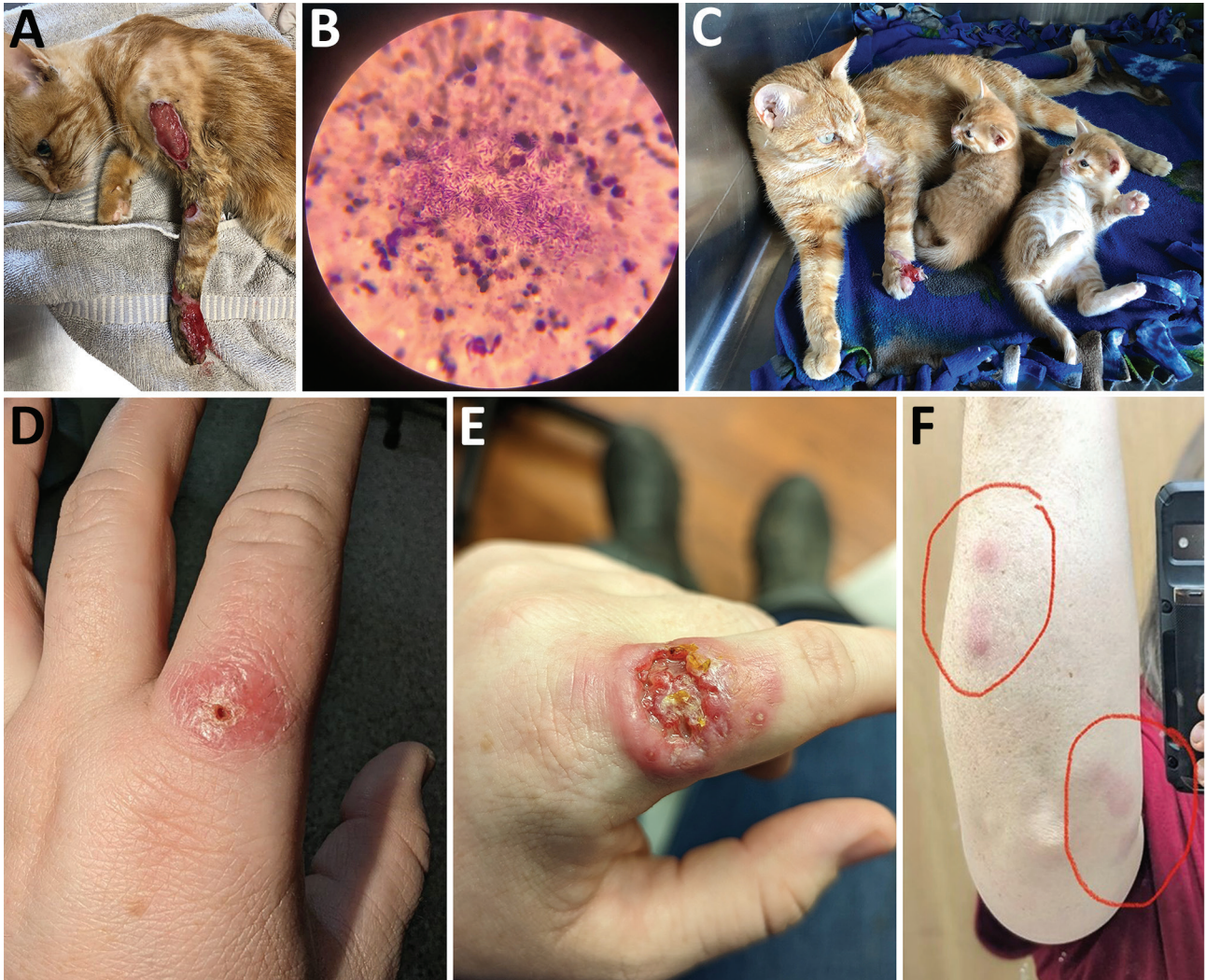
September 2022 (Figure, panel C). However, lesions reappeared after 1 month and began to extend up the limb. Treatment was adjusted to include terbinafine at 30 mg/kg, but the lesions continued to worsen and spread to the other 3 limbs. The cat was humanely euthanized, and the remains were cremated.

In November 2022, a veterinary technician caring for cat 1 at the clinic received a puncture wound through the glove from the cat's infected paw. A small blister developed at the puncture site approximately 2 weeks after the scratch (Figure, panel D). The blister quickly ulcerated, and the technician developed sporotrichoid lymphadenopathy up her arm (Figure, panels E, F). The technician began a treatment of cephalexin and then switched to 200 mg oral itraconazole twice daily and doxycycline. Cultures completed at Nebraska Medical Center were positive for *Sporothrix* spp., and an isolate was sent to the US Centers for Disease Control and Prevention (CDC) for identification. The isolate was identified as *S. schenckii* based on Sanger sequencing of the calmodulin gene (Appendix, <https://wwwnc.cdc.gov/EID/article/30/5/23-1563-App1.pdf>). Whole-genome sequencing showed the isolate clustered with historical *S. schenckii* isolates from the United States (bootstrap value of 100%) (Appendix Figure). The technician completed 8 months of oral itraconazole and recovered.

In February 2023, cat 1's owners brought another indoor-outdoor cat from the same property to the veterinary clinic with similar lesions. Cytology revealed *Sporothrix*. Cat 2 underwent a 4-month regimen of itraconazole 10 mg/kg, and the lesions healed.

This report describes a cluster of feline sporotrichosis cases in 2 indoor-outdoor cats and zoonotic transmission between 1 of the cats and a veterinary technician. The disease course of cat 1 highlights the potential severity of feline sporotrichosis. Early diagnosis of sporotrichosis and early treatment initiation with appropriate antifungal drugs can improve outcomes and help prevent transmission to other cats or humans (4). Cytology and culture should be considered for wounds or lesions that fail to respond to antibiotics. Itraconazole should be given to cats with food to improve absorption, and potassium iodide in combination with itraconazole can improve treatment efficacy in cats with multiple or extensive lesions or in treatment refractory cases (5,6).

This sporotrichosis cluster raised concerns that *S. brasiliensis* could be the etiologic agent. *S. brasiliensis* has increasingly been reported in Latin America (1), and 3 cases were recently reported in the United Kingdom, highlighting the potential for international spread (7). However, the etiologic agent in our report



**Figure.** Clinical manifestations seen in pregnant 2-year-old cat and human from a sporotrichosis cluster in domestic cats and veterinary technician, Kansas, USA, 2022. A) Severe lesion on cat 1 in August 2022; B) cytological examination from cat 1's lesions showing numerous cigar-shaped yeasts consistent with *Sporothrix*; C) image of cat 1 with kittens and improved lesion in September 2022; D) lesion on the finger of a veterinary technician who had contact with cat 1; E) ulcerated and more severe lesion on technician's finger after X days; F) lymphadenopathy on technician's arm. Cat 1 initially was treated with antibiotics in August 2022 and lesions improved on antifungal therapy. However, the cat's lesions returned and worsened in October 2022, after discharge from the facility. In November 2022, a veterinary technician developed a small lesion 1 week after being poked through the glove by a claw on cat 1's infected paw. Lymphadenopathy progressed up the technician's arm (red circles, panel F) in a sporotrichoid pattern along dermal and lymphatic vessels.

was *S. schenckii*, which is typically acquired through traumatic contact with plant matter. Although rare, cat-transmitted *S. schenckii* cases have been reported in the United States and Southeast Asia (2,3,8).

To reduce zoonotic transmission risk, veterinary professionals should wear examination gloves when handling cats with suspected sporotrichosis and take precautions to avoid scratches or bites (9). Wounds from scratches or bites should be washed promptly with soap and water (<https://www.cdc.gov/healthy-pets/pets/cats.html>). Persons who have close contact with a cat with sporotrichosis should seek healthcare

promptly if they develop lesions or sporotrichoid lymphadenopathy (1,3).

This report was limited by a lack of detailed exposure information for how the cats acquired sporotrichosis. Nevertheless, keeping cats indoors is recommended to prevent environmental acquisition of sporotrichosis (1,2). Risk factors for feline acquisition of sporotrichosis likely resemble those for humans, including traumatic inoculation or wound contamination with hay, roses, or sphagnum moss, or bites or scratches from other cats (9,10). Intact male, free-roaming cats might be at increased risk for



sporotrichosis (10). Cats with sporotrichosis should be kept indoors and apart from other cats in the home to reduce the potential for further transmission. In conclusion, increased awareness of sporotrichosis in cats and the potential for zoonotic transmission could help veterinary professionals more quickly recognize and treat feline cases and take precautions to prevent human acquisition in the veterinary setting.

### Acknowledgments

We gratefully acknowledge the cat owners as well as the veterinary technician who shared her experience for this report. We also acknowledge Dr. Karen Wu for facilitating the initial connection between the Kansas veterinary office and CDC.

This activity was reviewed by CDC and was conducted consistent with applicable federal law and CDC policy (e.g., 45 C.F.R. part 46, 21 C.F.R. part 56; 42 U.S.C. §241(d); 5 U.S.C. §552a; 44 U.S.C. §3501 et seq).

### About the Author

Dr. Hennessee is an Epidemic Intelligence Service Officer with the Mycotic Diseases Branch, Division of Foodborne, Waterborne, and Environmental Diseases, National Center for Emerging and Zoonotic Infectious Diseases, Centers for Disease Control and Prevention, Atlanta, Georgia, USA. His research focuses on the epidemiology, prevention, and control of emerging infectious diseases.

### References

- Rossow JA, Queiroz-Telles F, Caceres DH, Beer KD, Jackson BR, Pereira JG, et al. A One Health approach to combatting *Sporothrix brasiliensis*: narrative review of an emerging zoonotic fungal pathogen in South America. *J Fungi (Basel)*. 2020;6:247. <https://doi.org/10.3390/jof6040247>
- Rees RK, Swartzberg JE. Feline-transmitted sporotrichosis: a case study from California. *Dermatol Online J*. 2011;17:2. <https://doi.org/10.5070/D30459K1JB>
- Reed KD, Moore FM, Geiger GE, Stemper ME. Zoonotic transmission of sporotrichosis: case report and review. *Clin Infect Dis*. 1993;16:384-7. <https://doi.org/10.1093/clind/16.3.384>
- de Miranda LHM, Silva JN, Gremião IDF, Menezes RC, Almeida-Paes R, Dos Reis ÉG, et al. Monitoring fungal burden and viability of *Sporothrix* spp. in skin lesions of cats for predicting antifungal treatment response. *J Fungi (Basel)*. 2018;4:92. <https://doi.org/10.3390/jof4030092>
- Reis ÉG, Schubach TMP, Pereira SA, Silva JN, Carvalho BW, Quintana MSB, et al. Association of itraconazole and potassium iodide in the treatment of feline sporotrichosis: a prospective study. *Med Mycol*. 2016;54:684-90. <https://doi.org/10.1093/mmy/myw027>
- Gremião IDF, Martins da Silva da Rocha E, Montenegro H, Carneiro AJB, Xavier MO, de Farias MR, et al. Guideline for the management of feline sporotrichosis caused by *Sporothrix brasiliensis* and literature revision. *Braz J Microbiol*. 2021;52:107-24. <https://doi.org/10.1007/s42770-020-00365-3>
- Barnacle JR, Chow YJ, Borman AM, Wyllie S, Dominguez V, Russell K, et al. The first three reported cases of *Sporothrix brasiliensis* cat-transmitted sporotrichosis outside South America. *Med Mycol Case Rep*. 2023;39:14-7. <https://doi.org/10.1016/j.mmcr.2022.12.004>
- Yingchanakiat K, Limsivilai O, Sunpongsri S, Niyomtham W, Lugsomya K, Yurayart C. Phenotypic and genotypic characterization and antifungal susceptibility of *Sporothrix schenckii sensu stricto* isolated from a feline sporotrichosis outbreak in Bangkok, Thailand. *J Fungi (Basel)*. 2023;9:590. <https://doi.org/10.3390/jof9050590>
- Welsh RD. Sporotrichosis. *J Am Vet Med Assoc*. 2003;223:1123-6. <https://doi.org/10.2460/javma.2003.223.1123>
- Crothers SL, White SD, Ihrke PJ, Affolter VK. Sporotrichosis: a retrospective evaluation of 23 cases seen in northern California (1987-2007). *Vet Dermatol*. 2009;20:249-59. <https://doi.org/10.1111/j.1365-3164.2009.00763.x>

Address for correspondence: Ian Hennessee, Centers for Disease Control and Prevention, 1600 Clifton Road NE, Mailstop H24-10, Atlanta, GA 30329, USA; email: xye0@cdc.gov

## ***Burkholderia thailandensis* Isolated from Infected Wound, Southwest China, 2022**

Jin Li, Jishan Tan, Xingyun Xiong, Qiu Zhong, Weiping Lu

Author affiliations: Chongqing Medical University Affiliated Dazu Hospital, Chongqing, China (J. Li); Daping Hospital of Army Medical University, Chongqing (J. Li, Q. Zhong, W. Lu); General Hospital of Western Theater Command, Chengdu, China (J. Tan); Dazu County People's Hospital, Dazhou, Sichuan, China (X. Xiong)

DOI: <http://doi.org/10.3201/eid3005.230743>

We report a clinical isolate of *Burkholderia thailandensis* 2022DZh obtained from a patient with an infected wound in southwest China. Genomic analysis indicates that this isolate clusters with *B. thailandensis* BPM, a human isolate from Chongqing, China. We recommend enhancing monitoring and surveillance for *B. thailandensis* infection in both humans and livestock.

# Sporotrichosis Cluster in Domestic Cats and Veterinary Technician, Kansas, USA, 2022

## Appendix

### Species Identification

Species identification was conducted at the Mycotic Diseases Branch Laboratory at CDC, Atlanta, USA. DNA was extracted using the DNeasy Blood and Tissue kit (Qiagen, Gaithersburg, MD, USA) according to the manufacturer's instructions. Quantity of the DNA was measured by a Nanodrop 2000c at a wavelength of 260A (Thermo Fisher Scientific, Pittsburgh, PA). PCR sequencing, purification of PCR products and Sanger sequencing were performed as previously described in Gade et al. (1), including the PCR conditions and purification of the PCR products by ExoSAP (Affymetrix, Santa Clara, CA) according to the manufacturer's instructions. The calmodulin (CAL) locus region was amplified directly from the genomic DNA using primers CL1-GARTWCAAGGAGGCCTTCTC and CL2A-TTTTTGCATCATGAGTTGGAC, as described in O'Donnell et al. (2) and Rodrigues et al. (3) for species confirmation.

### Genomic Sequencing

Next, genomic libraries were constructed using NEBNext Ultra DNA Library Prep kit (New England Biolabs, Ipswich, MA, U.S.) for Illumina and sequenced on Illumina NovaSeq 6000SP reagent kit (500 cycles). Read data has been deposited into the SRA database (BioProject PRJNA1021525). An additional ten *S. schenckii* isolates from the United States and NCBI SRA (Appendix Table) were included in the genomic analysis for comparison to the isolate. SNPs were identified using MycoSNP v1.4 (<https://github.com/CDCgov/mycosnp-nf/>) as described by Bagal et al. (4). Analyses were conducted using *S. schenckii* strain 1099–18

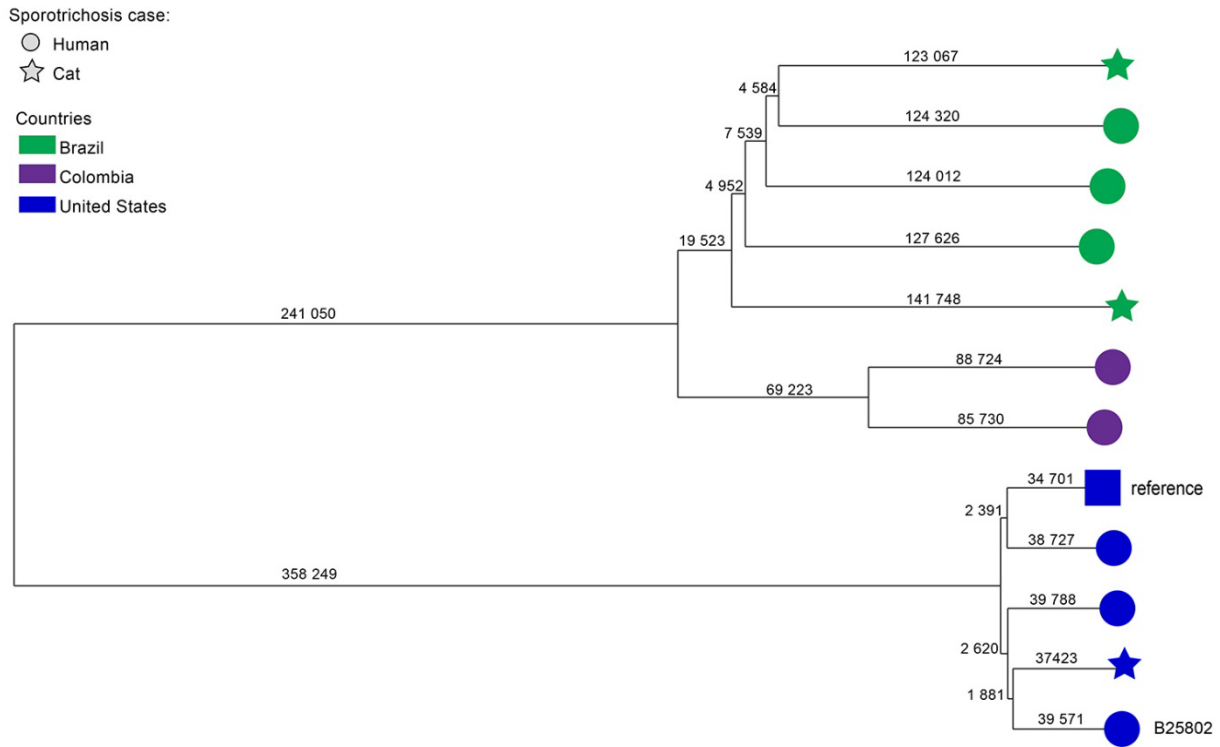
reference genome (NCBI: txid 1397361) (5). A maximum likelihood (ML) tree from the filtered SNPs calling file was built using FastTree v2.1.11. Genetic distance calculations and neighbor-joining tree construction were performed using MEGA 11. The consensus topology, branch support, and maps were visualized using Microreact (<http://microreact.org>).

## References

1. Gade L, Scheel CM, Pham CD, Lindsley MD, Iqbal N, Cleveland AA, et al. Detection of fungal DNA in human body fluids and tissues during a multistate outbreak of fungal meningitis and other infections. *Eukaryot Cell*. 2013;12:677–83. [PubMed https://doi.org/10.1128/EC.00046-13](https://doi.org/10.1128/EC.00046-13)
2. O’Donnell K, Nirenberg HI, Aoki T, Cigelnik E. A Multigene phylogeny of the *Gibberella fujikuroi* species complex: detection of additional phylogenetically distinct species. *Mycoscience*. 2000;41:61–78. <https://doi.org/10.1007/BF02464387>
3. Rodrigues AM, de Hoog S, de Camargo ZP. Emergence of pathogenicity in the *Sporothrix schenckii* complex. *Med Mycol*. 2013;51:405–12. [PubMed https://doi.org/10.3109/13693786.2012.719648](https://doi.org/10.3109/13693786.2012.719648)
4. Bagal UR, Phan J, Welsh RM, Misas E, Wagner D, Gade L, et al. MycoSNP: a portable workflow for performing whole-genome sequencing analysis of *Candida auris*. In: Lorenz A, editor. *Candida auris*. *Methods in Molecular Biology*, volume 2517. New York, NY: Springer US; 2022. p. 215–28 [cited 2023 Sep 26]. [https://link.springer.com/10.1007/978-1-0716-2417-3\\_17](https://link.springer.com/10.1007/978-1-0716-2417-3_17)
5. Teixeira MM, de Almeida LG, Kubitschek-Barreira P, Alves FL, Kioshima ÉS, Abadio AK, et al. Comparative genomics of the major fungal agents of human and animal Sporotrichosis: *Sporothrix schenckii* and *Sporothrix brasiliensis*. *BMC Genomics*. 2014;15:943. [PubMed https://doi.org/10.1186/1471-2164-15-943](https://doi.org/10.1186/1471-2164-15-943)

**Appendix Table.** Characteristics of whole-genome sequences downloaded from NCBI (<https://www.ncbi.nlm.nih.gov/sra/?term=Sporothrix>).

Sample accession no.	Strain	Year of isolation	Geographic origin	Host
SRR12483721	<i>Sporothrix schenckii</i> SsEM7	2012	Colombia	<i>Homo sapiens</i>
SRR12483722	<i>Sporothrix schenckii</i> SsMS1	2012	Colombia	<i>Homo sapiens</i>
SRR12483724	<i>Sporothrix schenckii</i> A0003	2015	Brazil	<i>Felis catus</i>
SRR24215198	B22064	2021	Brazil	<i>Homo sapiens</i>
SRR24215187	B22065	Unknown	Brazil	<i>Homo sapiens</i>
SRR2421519	B22147	2022	Brazil	<i>Homo sapiens</i>
SRR24215210	B22103	2016	Brazil	<i>Felis catus</i>
SRR24215243	B10282	2013	United States	<i>Homo sapiens</i>
SRR24215242	B11252	2015	United States	<i>Homo sapiens</i>
SRR26324850	B24667	2022	United States	<i>Felis catus</i>



**Appendix Figure.** Neighbor-joining phylogenetic tree of *Sporothrix schenckii* isolates from Brazil, Colombia, and the United States. Shapes represent the *S. schenckii* host (human or cat); the square represents the *S. schenckii* strain 1099–18 reference genome (NCBI: 1397361). Branch lengths represent SNPs. Isolate from human case in Kansas is identified (B25802).