

8. Kuschner RA, Russell KL, Abuja M, Bauer KM, Faix DJ, Hait H, et al; Adenovirus Vaccine Efficacy Trial Consortium. A phase 3, randomized, double-blind, placebo-controlled study of the safety and efficacy of the live, oral adenovirus type 4 and type 7 vaccine, in U.S. military recruits. *Vaccine*. 2013;31:2963–71. <https://doi.org/10.1016/j.vaccine.2013.04.035>
9. US Food and Drug Administration. CFR—Code of Federal Regulations Title 21, 21CFR312.32. Investigational new drug application [cited 2023 Apr 3]. <https://www.accessdata.fda.gov/scripts/cdrh/cfdocs/cfCFR/CFRSearch.cfm?fr=312.32>
10. Burke RM, Killerby ME, Newton S, Ashworth CE, Berns AL, Brennan S, et al.; Case Investigation Form Working Group. Symptom profiles of a convenience sample of patients with COVID-19—United States, January–April 2020. *MMWR Morb Mortal Wkly Rep*. 2020;69:904–8. <https://doi.org/10.15585/mmwr.mm6928a2>

Address for correspondence: John Iskander, United States Coast Guard Headquarters, 2703 Martin Luther King Jr Ave SE, Washington, DC 20593-7907, USA; email: John.K.Iskander@uscg.mil

Isolated Ocular Mpox without Skin Lesions, United States

Minh T. Nguyen, Akshay Mentreddy, Julie Schallhorn, Matilda Chan, Su Aung, Sarah B. Doernberg, Jennifer Babik, Kevin Miles, Katherine Yang, Emily Lydon, Daniel J. Minter, John Gonzales, Jessica Shantha, Thuy Doan, Gerami D. Seitzman

Author affiliations: University of California, San Francisco, California, USA (M.T. Nguyen, A. Mentreddy, J. Schallhorn, M. Chan, S. Aung, S.B. Doernberg, J. Babik, K. Miles, K. Yang, E. Lydon, D.J. Minter, J. Gonzales, J. Shantha, T. Doan, G.D. Seitzman); Francis I. Proctor Foundation, San Francisco (M.T. Nguyen, A. Mentreddy, M. Chan, J. Gonzales, J. Shantha, T. Doan, G.D. Seitzman)

DOI: <https://doi.org/10.3201/eid2906.230032>

We report a case of a 53-year-old HIV-negative patient in San Francisco, California, USA, with no classic mpox prodromal symptoms or skin lesions who experienced fulminant, vision-threatening scleritis, keratitis, and uveitis. Deep sequence analysis identified monkeypox virus RNA in the aqueous humor. We confirmed the virus on the cornea and sclera by PCR.

We report a case of ocular-only mpox infection in a 53-year-old man in San Francisco, California, USA. His medical history included chronic lymphocytic leukemia (CLL), inactive 2 years after treatment with obinutuzumab and venetoclax but with persistent lymphopenia. He reported male sexual partners but was HIV negative. Symptoms in his right eye began August 2022 as itching and nasal scleral redness (Figure, panel A). There was no fever, rash, or lymphadenopathy. Eye redness worsened; the patient sought care at an urgent care facility and was given erythromycin ointment. Continued vision loss led to an emergency department visit, resulting in a diagnosis of preseptal cellulitis, treated with trimethoprim/sulfamethoxazole plus amoxicillin/clavulanic acid.

In early September 2022, the patient sought care at a county eye clinic for purulent conjunctivitis and corneal epithelial defects. Clinicians suspected gonococcal conjunctivitis and administered intramuscular ceftriaxone and topical moxifloxacin 0.5%. Bacterial and fungal ocular cultures and herpetic viral PCR returned negative results. Topical prednisolone acetate 1% and oral valacyclovir failed to control the eye inflammation. Three weeks after initial symptoms appeared, the patient's ocular inflammation increased; keratic precipitates and a moderate corneal opacity developed. Uveitis and scleritis workups did not yield a specific diagnosis (Table).

In late September 2022, at a second opinion examination at a University of California clinic, the patient's right eye acuity was 20/640. Examination showed a nasal patch of avascular scleral necrosis (Figure, panel B), and corneal epithelial sloughing (Figure, panel C) with microcystic edema. Repeat ocular surface cultures and PCR were negative. Given the negative results of extensive infectious etiology testing, we prescribed oral prednisone (40 mg/d) for presumed undifferentiated necrotizing anterior scleritis and keratitis.

One week later, corneal inflammation worsened (Figure, panel D). Clinical deterioration on systemic steroids continued to raise suspicion for ocular infection; we stopped steroid treatments. Again, cultures and PCR remained negative. Without prednisone, the patient's limbal infiltrates worsened, with progressive corneal haze. White corneal endothelial plaques appeared. We performed anterior chamber paracentesis for cultures, viral PCR, and an RNA deep-sequencing (RNA-seq) protocol previously described (1). The patient's scleritis, keratitis, and anterior uveitis worsened (Figure, panels E, F). Right eye vision decreased to hand motion only. We performed a diagnostic scleral and corneal biopsy and initiated

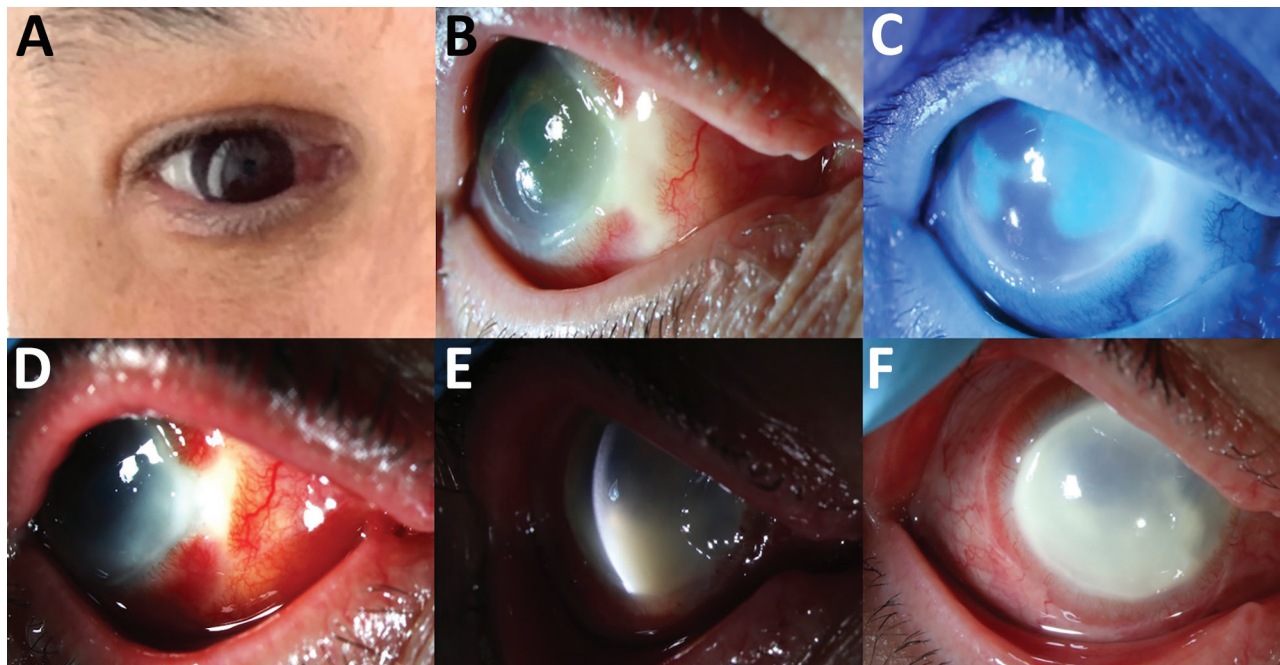


Figure. Clinical progression of ocular mpox in patient in California, USA. A) Initial manifestation of nasal scleral inflammation. B) Nasal scleral necrosis with surrounding scleritis. C) Corneal epithelial sloughing. D) Worsening scleritis and nasal keratitis. E) Corneal endothelial inflammatory plaque. Nasal area of corneal irregularity represents the area of biopsy. F) Progression of diffuse keratitis and corneal limbitis.

voriconazole for presumed fungal infection. The biopsy results returned negative for infection, and voriconazole was stopped.

Given the progressive clinical disease and negative infectious workup, we processed residual aqueous fluid for RNA-seq, which revealed a high number of reads aligning to monkeypox virus (MPXV) (Appendix Figure 1, <https://wwwnc.cdc.gov/EID/article/29/6/23-0032-App1.pdf>). Orthogonal testing from corneal and scleral swab specimens also returned positive results for MPXV by PCR. A nasal swab specimen obtained on the same day tested negative for MPXV by PCR.

When presented with those findings, the patient offered additional information regarding high-risk sexual activities, previously withheld because his definition of sexual activity included only penetrative intercourse. He described an encounter with a male partner with semen deposition into his right eye 2 weeks before the onset of his symptoms. He received the first dose of mpox vaccine for higher risk groups the week after this encounter. Several months later, during casual text messaging, the partner from this activity revealed a subsequent penile mpox diagnosis. (Appendix Figure 2).

Following treatment guidance from the Centers for Disease Control and Prevention, we initiated

oral tecovirimat (600 mg 2×/d), topical trifluridine (6×/d), and weekly topical ophthalmic betadine washes (2). Four months into this course, worsening vision to light perception and repeat positive conjunctival mpox PCR led to inpatient admission for intravenous tecovirimat and cidofovir. Used in a compassionate-use capacity, tecovirimat and cidofovir have shown good activity against other orthopoxviruses, and in vitro and animal models have shown the antivirals to be effective against mpox (3). Unfortunately, after 3 weeks of inpatient treatment, the ocular disease did not improve. The patient's eye remained PCR positive for MPXV with an opacified and vascularized cornea.

Ocular manifestations of mpox during the 2010–2013 outbreak were associated with a more severe systemic presentation (4). However, during the recent 2022 outbreak, ocular findings do not appear to have correlated with systemic disease severity (5–7). Isolated ocular mpox in the absence of systemic or skin findings is exceedingly rare.

In conclusion, we describe a case of isolated ocular mpox with no skin lesions or systemic prodromal symptoms in a relatively immunocompromised patient. Because pertinent history and clinical suspicion were lacking, metagenomic RNA sequencing was highly valuable in helping identify the pathogen.

Table. Summary of laboratory and microbiology testing of patient with ocular mpox, California, USA

| Test | Result |
|--|----------------------------------|
| Laboratory and microbiology testing from serum or ocular surface scraping or swab specimen | |
| Human leukocyte antigen B27 | Negative |
| Angiotensin-converting enzyme | Within reference range |
| Complement | Within reference range |
| Antineutrophilic cytoplasmic antibody | Within reference range |
| Antinuclear antibodies | Within reference range |
| Rheumatoid factor | Within reference range |
| Anti-cyclic citrullinated peptide | Within reference range |
| HIV antibody/antigen | Negative ×2 |
| QuantIFERON-TB Gold* | Negative |
| Fluorescent treponemal antibody absorption | Negative ×2 |
| Herpes simplex virus 1 DNA from ocular surface swab specimen | Negative ×2 |
| Cytomegalovirus DNA from ocular surface swab specimen | Negative ×2 |
| Varicella zoster virus DNA from ocular surface swab specimen | Negative ×2 |
| Bacterial culture on blood, chocolate, Middlebrook agar | Negative ×2 |
| Fungal culture on potato flake agar | Negative ×2 |
| Monkeypox virus RNA from aqueous sample | Positive for MPXV |
| Monkeypox virus DNA from conjunctival swab specimen | Positive ×5 |
| Testing from scleral and corneal biopsy | |
| Periodic acid Schiff for fungus | Negative for fungal organisms |
| Grocott's methamine silver | Negative for fungal organisms |
| Steiner | Negative for spirochetes |
| Acid-fast bacteria (Fite)† | Negative for acid-fast organisms |
| <i>Trepona pallidum</i> antibody | Negative |
| Herpes simplex virus 1 & 2 | Negative |
| Varicella zoster virus | Negative |
| Complete blood count with differential obtained at the time of hospitalization | |
| Red blood cell count (reference 4.4–5.9 × 10 ¹² cells/L) | 4.45 × 10 ¹² cells/L |
| Hemoglobin (reference 13.6–17.5 g/dL)‡ | 13.7 g/dL |
| Platelets (reference 140–450 × 10 ⁹ /L)‡ | 174 × 10 ⁹ /L |
| Leukocyte count (reference 3.4–10 × 10 ⁹ cells/L) | 4.3 × 10 ⁹ cells/L |
| Absolute neutrophils (reference 1.8 × 6.8 × 10 ⁹ cells/L) | 3.93 × 10 ⁹ cells/L |
| Absolute monocytes (reference 0.2–0.8 × 10 ⁹ cells/L)‡§ | 0.06 × 10 ⁹ cells/L |
| Absolute eosinophils (reference 0–0.4 × 10 ⁹ cells/L) | 0 |
| Absolute basophils (reference 0–0.1 × 10 ⁹ cells/L) | 0.01 × 10 ⁹ cells/L |
| Absolute lymphocytes (reference 1–3.4 × 10 ⁹ cells/L)‡§ | 0.33 × 10 ⁹ cells/L |

*QIAGEN, <https://www.qiagen.com>.

†Newcomer Supply, <https://www.newcomersupply.com/product/afb-fite-stain-kit>.

‡Hemoglobin (>10 g/dL) and platelet count (>100 × 10⁹/L) do not meet criteria for active chronic lymphocytic leukemia and treatment.

§Indicates chronic lymphocytopenia.

Semen was the likely vehicle for direct transmission (8), although hand-to-eye contact with unobserved lesions or exposure through nondisclosed encounters cannot be excluded. Intraocular mpox involving the sclera, cornea, and anterior chamber, along with persistently PCR-positive ocular surface mpox, has a poor visual prognosis. There is no established treatment for ocular mpox (9). Continued mpox disease progression over several months is unusual and could raise suspicion of immunosuppression or treatment resistance.

Research reported in this manuscript was supported by the National Eye Institute of the National Institutes of Health under award no. R01EY03861 (TD), a Research to Prevent Blindness unrestricted grant, and the Pacific Huang Foundation. The content is solely the responsibility of the authors and does not necessarily represent the official views of the National Institutes of Health.

About the Author

Dr. Nguyen is a fellow in cornea and external disease at the University of California San Francisco and F.I. Proctor Foundation in San Francisco, California. His research interests include regenerative ophthalmology and ocular infectious diseases.

References

- Doan T, Hinterwirth A, Worden L, Arzika AM, Maliki R, Abdou A, et al. Gut microbiome alteration in MORDOR I: a community-randomized trial of mass azithromycin distribution. *Nat Med*. 2019;25:1370–6. <https://doi.org/10.1038/s41591-019-0533-0>
- Centers for Disease Control and Prevention. Interim clinical considerations for management of ocular mpox virus infection. 2022 [cited 2023 Feb 20]. <https://www.cdc.gov/poxvirus/monkeypox/clinicians/ocular-infection.html>
- Frenois-Veyrat G, Gallardo F, Gorgé O, Marcheteau E, Ferraris O, Baidaliuk A, et al. Tecovirimat is effective against human monkeypox virus in vitro at nanomolar

- concentrations. *Nat Microbiol.* 2022;7:1951–5. <https://doi.org/10.1038/s41564-022-01269-8>
4. Hughes C, McCollum A, Pukuta E, Karhemere S, Nguete B, Lushima RS, et al. Ocular complications associated with acute monkeypox virus infection, DRC. *Int J Infect Dis.* 2014;21:276–7. <https://doi.org/10.1016/j.ijid.2014.03.994>
 5. Iñigo Martínez J, Gil Montalbán E, Jiménez Bueno S, Martín Martínez F, Nieto Juliá A, Sánchez Díaz J, et al. Monkeypox outbreak predominantly affecting men who have sex with men, Madrid, Spain, 26 April to 16 June 2022. *Euro Surveill.* 2022;27:2200471. <https://doi.org/10.2807/1560-7917.ES.2022.27.27.2200471>
 6. Vusirikala A, Charles H, Balasegaram S, Macdonald N, Kumar D, Barker-Burnside C, et al. Epidemiology of early monkeypox virus transmission in sexual networks of gay and bisexual men, England, 2022. *Emerg Infect Dis.* 2022;28:2082–6. <https://doi.org/10.3201/eid2810.220960>
 7. Thornhill JP, Barkati S, Walmsley S, Rockstroh J, Antinori A, Harrison LB, et al.; SHARE-net Clinical Group. Monkeypox virus infection in humans across 16 countries – April–June 2022. *N Engl J Med.* 2022;387:679–91. <https://doi.org/10.1056/NEJMoa2207323>
 8. Lapa D, Carletti F, Mazzotta V, Matusali G, Pinnetti C, Meschi S, et al.; INMI Monkeypox Study Group. Monkeypox virus isolation from a semen sample collected in the early phase of infection in a patient with prolonged seminal viral shedding. *Lancet Infect Dis.* 2022;22:1267–9. [https://doi.org/10.1016/S1473-3099\(22\)00513-8](https://doi.org/10.1016/S1473-3099(22)00513-8)
 9. Centers for Disease Control and Prevention. Ocular monkeypox – United States, July–September 2022. 2022 [cited 2022 Dec 15]. <https://www.cdc.gov/mmwr/volumes/71/wr/mm7142e1.htm>

Address for correspondence: Gerami D. Seitzman, University of California San Francisco—Ophthalmology, 490 Illinois St, San Francisco, CA 94158, USA; email: gerami.seitzman@ucsf.edu

National Surveillance of Pediatric Acute Hepatitis of Unknown Etiology, Japan, October 2021–December 2022

Shogo Otake, Chiaki Ikenoue, Natsu Sudani, Miho Kobayashi, Kensuke Takahashi, Tomoe Shimada, Itsuro Yoshimi, Tomoya Saito, Tomimasa Sunagawa

Author affiliations: Kobe University Graduate School of Medicine, Kobe, Japan (S. Otake); National Institute of Infectious Diseases, Tokyo, Japan (S. Otake, C. Ikenoue, N. Sudani, M. Kobayashi, K. Takahashi, T. Shimada, I. Yoshimi, T. Saito, T. Sunagawa)

DOI: <https://doi.org/10.3201/eid2906.221579>

Pediatric acute hepatitis of unknown etiology has been reported globally since April 2022. In Japan, 139 possible cases with onset dates after October 2021 were reported as of December 2022. Three patients required liver transplants, but none died. Rates of adenovirus positivity (11/125, 9%) were lower than those for other countries.

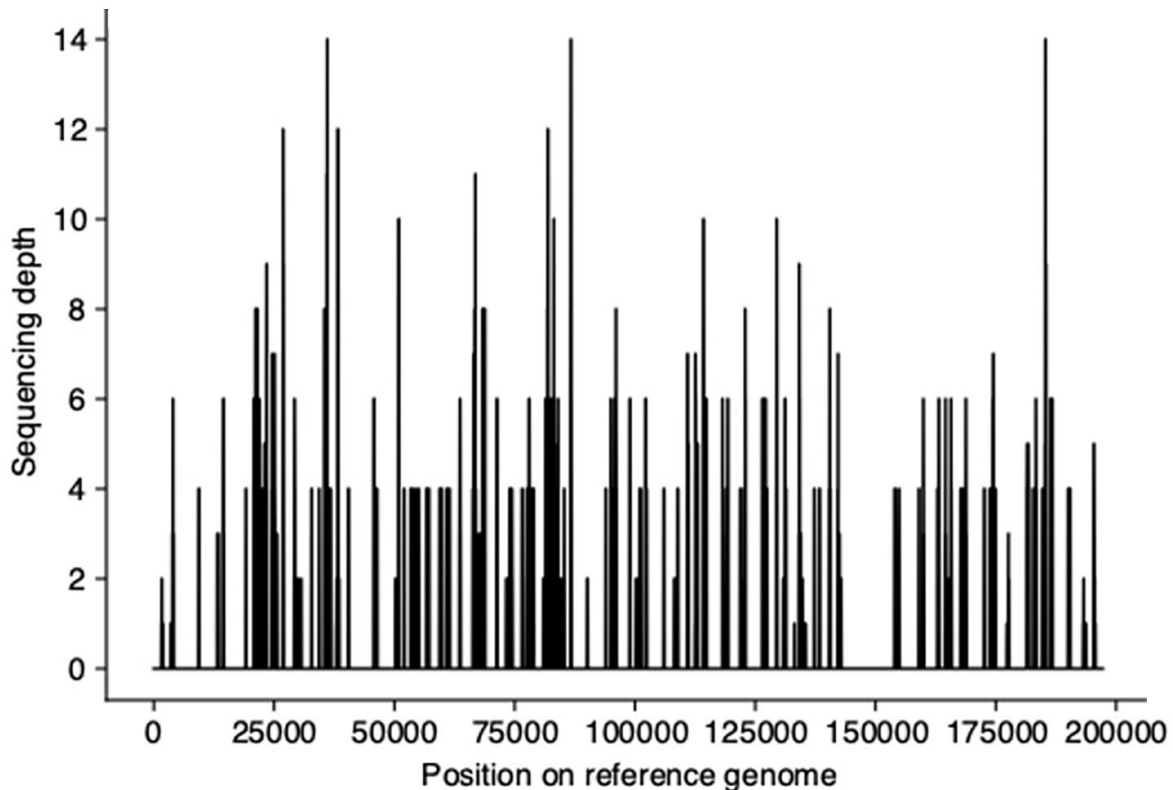
Severe acute hepatitis of unknown etiology (AHUE) in children has been reported globally since April 2022. By July 8, 2022, a total of 1,010 cases had been reported to the World Health Organization from 35 countries on the basis of the working case definitions (1). A definition for a confirmed case is not available, but probable cases are defined as acute hepatitis (non-A–E hepatitis) in persons ≤ 16 years of age with serum transaminase >500 IU/L (aspartate transaminase or aspartate aminotransferase) since October 1, 2021; epidemiologically linked cases are acute hepatitis (non-A–E hepatitis) in persons of any age who were close contacts with a probable case–patient since October 1, 2021. Of the 1,010 cases identified, 46 (5%) children required liver transplants, and 22 (2%) children died (1). We report pediatric AHUE cases in Japan and compare them with cases in other countries. Because the data for this study were taken from an epidemiologic investigation conducted by the government, the National Institute of Infectious Diseases did not require informed consent and ethical review (receipt no. 1442).

The Ministry of Health, Labor and Welfare (MHLW) of Japan issued the working case definitions of AHUE on April 27, 2022 (2), adopting the case definition published by the World Health Organization but limiting cases to hospitalized patients (Appendix Table 1, <https://wwwnc.cdc.gov/EID/article/29/6/22-1579-App1.pdf>). Physicians were instructed to exclude viral hepatitis A, B, C, and E through laboratory tests and report cases to public health centers. Laboratories at hospitals and local public health institutions performed microbiological testing recommended by MHLW (Appendix Table 2). Acute liver failure was considered a coagulopathy characterized by a prothrombin time and international normalized ratio of ≥ 2 or ≥ 1.5 with clinical encephalopathy (3).

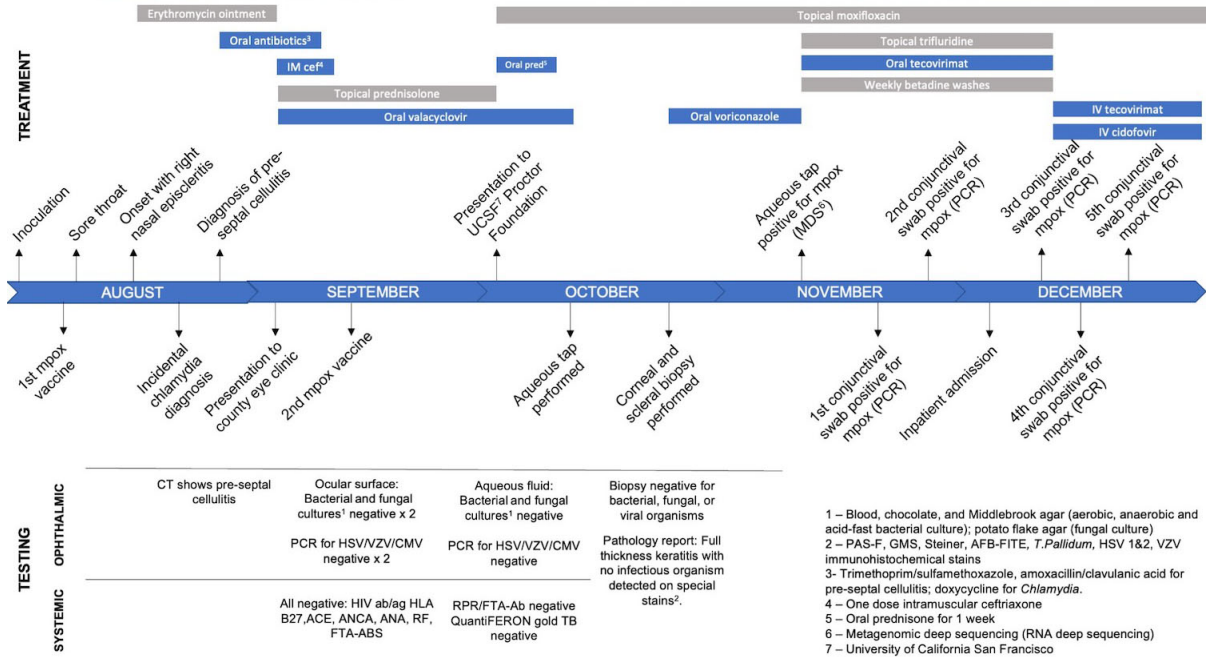
As of December 31, 2022, a total of 139 probable AHUE cases with onset dates after October 1, 2021, had been reported throughout Japan without geographic clustering (Table). Six cases with unknown onset dates were excluded, and none were epidemiologically linked. Among the 139 patients, 3 (2%) underwent liver transplantation. Eleven (13%) of 85 patients met the definition of acute liver failure, 17 (18%) of 95 received intensive care, and none died (Table 1).

Isolated Ocular Mpox without Skin Lesions, United States

Appendix



Appendix Figure 1. Identification of monkeypox virus in the patient's aqueous fluid by metagenomic RNA deep sequencing (accession no. PRJNA9554436). Alignment of detected MPXV reads to the MPXV genome (NCBI reference sequence ON563414.3). MPXV, monkeypox virus.



Appendix Figure 2. Clinical timeline of symptom onset, disease progression, important laboratory investigation and treatment.