

## About the Author

Dr. Alarcón is an Epidemic Intelligence Service Officer with the CDC, assigned to the Los Angeles County Department of Public Health. She is a family medicine physician working to protect and improve the health of vulnerable populations.

## References

1. California Department of Public Health. Healthcare provider advisory: guidance for safe specimen collection from monkeypox (MPX) lesions: reminder to not de-roof lesions and not use sharps [cited 2022 Oct 17]. <https://www.cdph.ca.gov/Programs/OPA/Pages/CAHAN/Healthcare-Provider-Advisory-Guidance-for-Safe-Specimen-Collection-From-MPX-Lesions.aspx>
2. Marshall KE, Barton M, Nichols J, de Perio MA, Kuhar DT, Spence-Davison E, et al.; Colorado Healthcare Personnel Monitoring Team. Health care personnel exposures to subsequently laboratory-confirmed monkeypox patients – Colorado, 2022. *MMWR Morb Mortal Wkly Rep.* 2022;71:1216–9. <https://doi.org/10.15585/mmwr.mm7138e2>
3. Salvato RS, Rodrigues Ikeda ML, Barcellos RB, Godinho FM, Sesterheim P, Bitencourt LCB, et al. Possible occupational infection of healthcare workers with monkeypox virus, Brazil. *Emerg Infect Dis.* 2022;28:2520–3. <https://doi.org/10.3201/eid2812.221343>
4. Centers for Disease Control and Prevention. Guidelines for collecting and handling specimens for monkeypox testing [cited 2022 Oct 18]. <https://www.cdc.gov/poxvirus/monkeypox/clinicians/prep-collection-specimens.html>
5. Centers for Disease Control and Prevention. Infection prevention and control of monkeypox in healthcare settings [cited 2022 Oct 17]. <https://www.cdc.gov/poxvirus/monkeypox/clinicians/infection-control-healthcare.html>

Address for correspondence: Gemma Alarcon, County of Los Angeles, Department of Public Health, Acute Communicable Disease Control, 313 No. Figueroa St, #202, Los Angeles, CA 90012, USA; email: [vqh4@cdc.gov](mailto:vqh4@cdc.gov), [jalarcon2@ph.lacounty.gov](mailto:jalarcon2@ph.lacounty.gov)

## Familial Monkeypox Virus Infection Involving 2 Young Children

Pascal Del Giudice, Agnes Fribourg, Laurent Roudiere, Juliette Gillon, Anne Decoppet, Mathieu Reverte

Author affiliations: Centre Hospitalier Intercommunal de Fréjus-Saint-Raphaël, Fréjus, France (P. Del Giudice, A. Fribourg, L. Roudiere, J. Gillon, M. Reverte); Agence Régionale de Santé, Toulon, France (A. Decoppet)

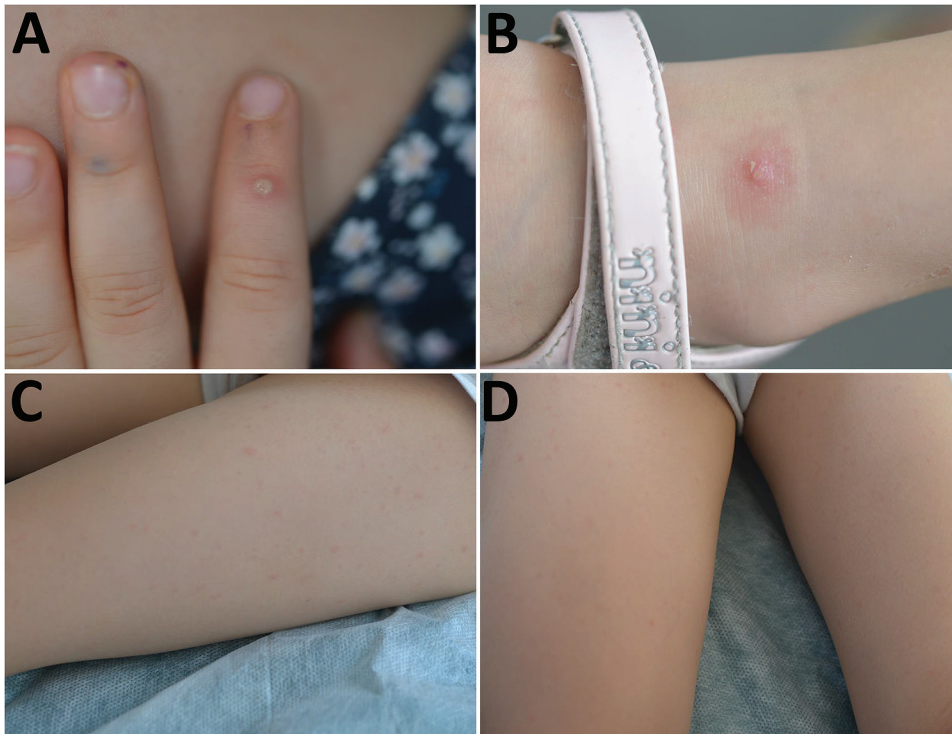
DOI: <https://doi.org/10.3201/eid2902.221674>

We report intrafamilial transmission of monkeypox virus to all members of a family (father, mother, and 2 children). Case reports in young children have been extremely rare during the 2022 mpox outbreak. Their clinical signs were mild, and clinical diagnosis would be difficult without knowledge of the father's monkeypox virus infection.

Monkeypox virus (MPXV) is a zoonotic orthopox virus. An outbreak of MPXV infections emerged in the spring of 2022 outside Africa, mainly in Europe and the United States, such that on July 23, 2022, the World Health Organization declared the outbreak to be a public health emergency of international concern. During this outbreak, MPXV spread has disproportionately affected gay or bisexual men or other men who have sex with men, which suggests transmission through sexual or intimate contact. However, in August 2022, we observed intrafamilial transmission of the virus to all members of a family (father, mother, and 2 children) in France.

The father, a 30-year-old man, showed a few papular pustules on his body, including his penis. The pustules began appearing on July 17, 2022. A pustule sample was tested for MPXV and showed a positive PCR result. The wife of the man showed a few pustules on August 2 that were later confirmed to be positive for MPXV by PCR. She had no mucous signs. Both persons were HIV negative.

The couple and their 2 young daughters went on vacation to a campsite in southern France on August 6. Their 4-year-old daughter had a fever (temperature 38°C) and a skin eruption that began on August 5, which consisted of 3 types of lesions: an umbilical pustule (Figure, panel A), papular pustules on an erythematous basis (Figure, panel B), and a disseminated faint erythematous macula (Figure, panels C, D). She also had a bilateral conjunctivitis but no lymphadenopathy or mucosal lesions.



**Figure.** Monkeypox virus lesions for the 4-year old daughter in a family (father, mother, 2 children) infected with the virus, August 6, 2022. A) Umbilical pustule on pulp of the finger; B) papulopustule on the ankle; C, D) faint erythematous rash on the thighs.

On August 9, her 7-year-old sister showed  $\approx 10$  asymptomatic micropapular pustules on a discrete erythematous basis (Appendix Figure 1, <https://wwwnc.cdc.gov/EID/article/29/2/22-1674-App1.pdf>). She had no fever, mucosal lesion, or lymphadenopathy.

The family was residing at a campsite in southern France, where there is a high burden of *Aedes albopictus* mosquitoes. They were suspected of having either MPXV infection or *Aedes* sp. mosquito bites. A skin scraping from the skin of a micropapular pustule was positive for MPXV by PCR. For all family members, only 1 lesion/person was sampled. Onset symptoms and positive PCR results are shown in the timeline (Appendix Figure 2). The family received isolation instructions and returned home on August 11. The outcome was favorable for all 4 persons. There were no secondary cases at the campsite.

During the ongoing outbreak, cases of MPXV infection in young children have been extremely rare. US data from the Centers for Disease Control and Prevention as of October 7, 2022, reported 26,577 cases in 28 patients (0.1%) <12 years of age (1,2). Those data were confirmed in Europe. As of August 3, 2022, among 4,663 laboratory-confirmed cases of MPXV infection reported in Spain, only 4 (0.1%) were in children <4 years of age (7, 10, and 13 months, and 3 years) and 12 were in adolescents 13–17 years of age (3). As of August 23, 2022, a total of 41 countries in the World Health Organization European Region

have reported 21,098 cases, of which 15 (0.07%) were in persons <15 years of age (4).

Intrafamilial transmission to all family members including both children, also appears extremely rare in the 2022 outbreak. We assume that the transmission route was through household direct skin-to-skin contact with their parents.

The clinical signs shown by the children were mild, and clinical diagnosis would be extremely difficult in the absence of knowledge of the MPXV infection of the father. Case reports in young children have been extremely rare in this outbreak (5–7). Thus, a dermatologic description is lacking in this population. The 2 children in this report had mild general signs. Skin lesions consisted of a few umbilical pustules or papulopustules similar to those reported (8–10). However, the children also had discrete micropapular pustules on an erythematous basis similar to mosquito bites and a faint erythematous rash. Such skin lesions have rarely been reported in children or adults (8–10).

#### Acknowledgment

We thank Moussa Hajer for editing the figures, proofreading, and submitting this manuscript.

#### About the Author

Dr. Del Giudice is a physician in the Infectious Diseases and Dermatology Unit at Bonnet Hospital, Fréjus, France. His primary research interest is skin infections.

## References

- Centers for Disease Control and Prevention. Monkeypox cases by age and gender, race/ethnicity, and symptoms [cited 2022 Dec 1]. <https://www.cdc.gov/poxvirus/monkeypox/response/2022/demographics.html>
- Hennessee I, Shelus V, McArdle CE, Wolf M, Schatzman S, Carpenter A, et al.; California Department of Public Health Monkeypox Pediatric Working Group; CDC Monkeypox Pediatric Working Group. Epidemiologic and clinical features of children and adolescents aged <18 years with monkeypox—United States, May 17–September 24, 2022. *MMWR Morb Mortal Wkly Rep.* 2022;71:1407–11. <https://doi.org/10.15585/mmwr.mm7144a4>
- Aguilera-Alonso D, Alonso-Cadenas JA, Roguera-Sopena M, Lorusso N, Miguel LG, Calvo C. Monkeypox virus infections in children in Spain during the first months of the 2022 outbreak. *Lancet Child Adolesc Health.* 2022;6:e22–3. [https://doi.org/10.1016/S2352-4642\(22\)00250-4](https://doi.org/10.1016/S2352-4642(22)00250-4)
- Vaughan AM, Cenciarelli O, Colombe S, Alves de Sousa L, Fischer N, Gossner CM, et al. A large multi-country outbreak of monkeypox across 41 countries in the WHO European Region, 7 March to 23 August 2022. *Euro Surveill.* 2022;27:2200620. <https://doi.org/10.2807/1560-7917.ES.2022.27.36.2200620>
- Tutu van Furth AM, van der Kuip M, van Els AL, Fievez LC, van Rijckevorsel GG, van den Ouden A, et al. Paediatric monkeypox patient with unknown source of infection, the Netherlands, June 2022. *Euro Surveill.* 2022;27:2200552. <https://doi.org/10.2807/1560-7917.ES.2022.27.29.2200552>
- Ramnarayan P, Mitting R, Whittaker E, Marcolin M, O'Regan C, Sinha R, et al.; NHS England High Consequence Infectious Diseases (Airborne) Network. Neonatal monkeypox virus infection. *N Engl J Med.* 2022;387:1618–20. <https://doi.org/10.1056/NEJMc2210828>
- Fuente SM, Nava FB, Valerio M, Veintimilla C, Aguilera-Alonso D. A call for attention: pediatric monkeypox case in a context of changing epidemiology. *Pediatr Infect Dis J.* 2022;41:e548–9. <https://doi.org/10.1097/INF.0000000000003695>
- Thornhill JP, Barkati S, Walmsley S, Rockstroh J, Antinori A, Harrison LB, et al.; SHARE-net Clinical Group. Monkeypox virus infection in humans across 16 countries, April–June 2022. *N Engl J Med.* 2022;387:679–91. <https://doi.org/10.1056/NEJMoa2207323>
- Girometti N, Byrne R, Bracchi M, Heskin J, McOwan A, Tittle V, et al. Demographic and clinical characteristics of confirmed human monkeypox virus cases in individuals attending a sexual health centre in London, UK: an observational analysis. *Lancet Infect Dis.* 2022;22:1321–8. [https://doi.org/10.1016/S1473-3099\(22\)00411-X](https://doi.org/10.1016/S1473-3099(22)00411-X)
- Tarín-Vicente EJ, Alemany A, Agud-Dios M, Ubals M, Suñer C, Antón A, et al. Clinical presentation and virological assessment of confirmed human monkeypox virus cases in Spain: a prospective observational cohort study. *Lancet.* 2022;400:661–9. [https://doi.org/10.1016/S0140-6736\(22\)01436-2](https://doi.org/10.1016/S0140-6736(22)01436-2)

Address for correspondence: Pascal Del Giudice, Infectiology and Dermatology Unit, Centre Hospitalier Intercommunal de Fréjus-Saint-Raphaël, Fréjus, France; email: pascal.delgiudice@chi-fsr.fr

## *Dirofilaria immitis* in Dog Imported from Venezuela to Chile

Cristian A. Alvarez Rojas,<sup>1</sup> Beatriz Cancino-Faure,<sup>1</sup> Pablo Lillo, María Luisa Fernández, Alejandro Piñeiro González, Alonso Flores Ramírez

Author affiliations: Escuela de Medicina Veterinaria, Facultad de Agronomía e Ingeniería Forestal, Facultad de Ciencias Biológicas y Facultad de Medicina, Pontificia Universidad Católica de Chile, Santiago, Chile (C.A. Alvarez Rojas, P. Lillo); Laboratorio de Microbiología y Parasitología, Departamento de Ciencias Preclínicas, Facultad de Medicina, Universidad Católica del Maule, Talca, Chile (B. Cancino-Faure, A. Piñeiro González); Hospital Veterinario Mi Mascota, Santiago (M.L. Fernández); Sociedad Chilena de Cardiología Veterinaria, Santiago (A. Flores Ramírez)

DOI: <https://doi.org/10.3201/eid2902.221427>

We report a case of *Dirofilaria immitis* nematode infection in a dog imported from Venezuela that had been living for 2 years in Santiago, Chile, where this parasite had not been reported before. Our findings warrant surveillance for all dogs imported to Chile, given that suitable conditions exist for establishing this parasite.

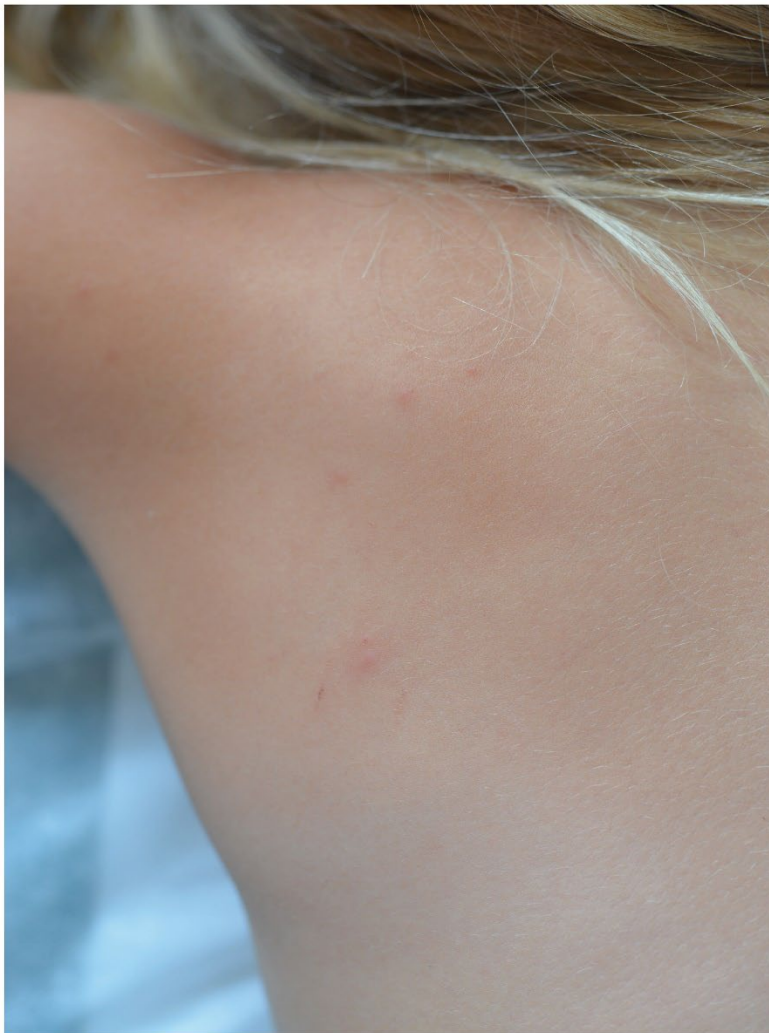*Dirofilaria immitis*, a species of zoonotic parasitic nematode transmitted by mosquitoes, causes canine dirofilariosis. These nematodes are usually found in countries with temperate and tropical climates and are endemic throughout Europe and in the southeastern regions of Asia and Africa (1). In the Americas, *D. immitis* nematodes are present in all countries and territories except Chile and Uruguay (2). We report a case of a female dog born in Venezuela and imported to Santiago, Chile, where she lived for 2 years before having *D. immitis* infection diagnosed in January 2022.

The dog was a 5.5-year-old Shar-pei who was brought to 2 veterinary clinics in Santiago during December 2021–January 2022. The initial cause of the consultation was vulvar discharge evolving to vomiting, melena, and general discomfort. Initially, the dog's health improved after treatment with enrofloxacin (5 mg/kg). However, the animal's condition deteriorated after 1 week (in January 2022). Ultrasound examination showed the presence of a fetus for which no heartbeat was detected. Blood work showed severe anemia, kidney failure, and the presence of microfilariae at the blood smear examination. An echocardiogram examination showed signs compatible

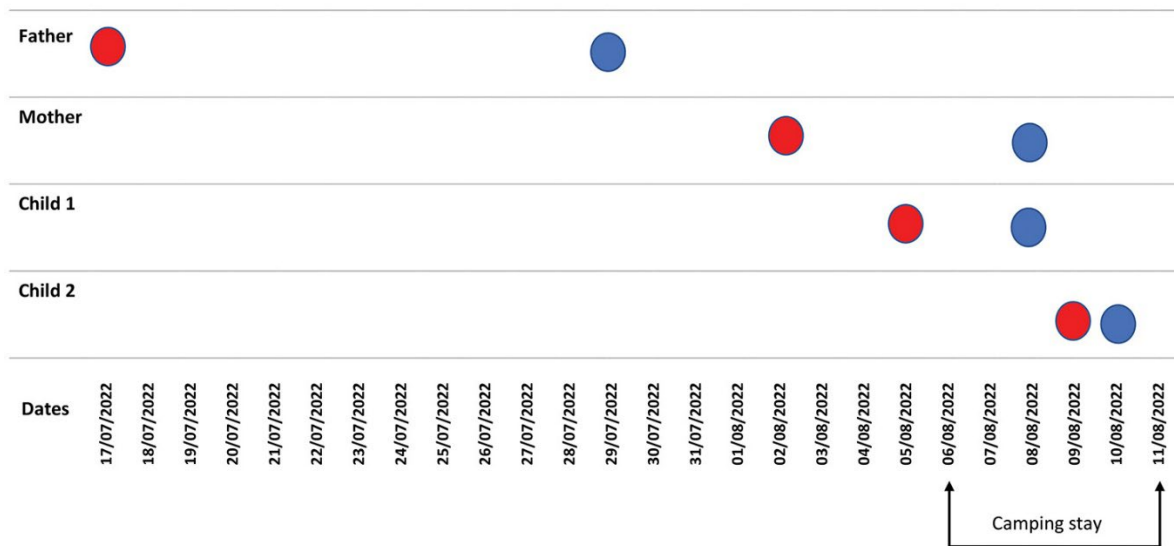
<sup>1</sup>These first authors contributed equally to this article.

# Familial Mpox Virus Infection Involving 2 Young Children

## Appendix



**Appendix Figure 1.** Micropapular pustule over a discreet erythematous basis similar to a mosquito bite, August 9, 2022.



**Appendix Figure 2.** Timeline of mpox virus infection in each family member. Red dots indicate onset of symptoms, and blue dots indicate sample date and positive PCR result.