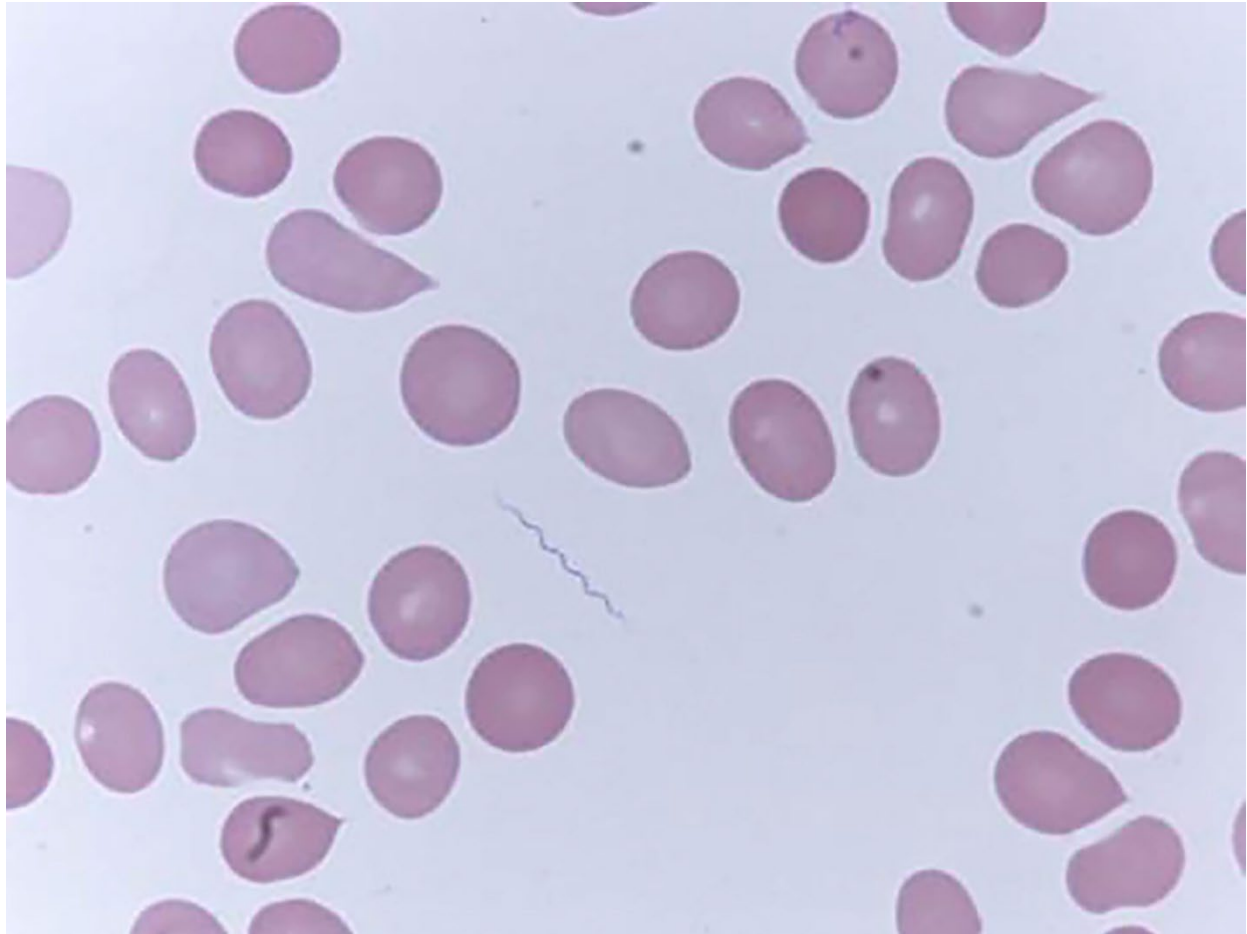


Relapsing Fever Caused by *Borrelia lonestari* after Tick Bite in Alabama, USA

Appendix



Appendix Figure. Microscopic image of spirochete bacteria found in patient's peripheral blood in study of relapsing fever caused by *Borrelia lonestari* after tick bite in Alabama, USA. Peripheral blood was collected before treatment with the antimicrobial drug doxycycline and smears were prepared for microscopic examination, original magnification $\times 1,000$.