

## Multisystem Inflammatory Syndrome in Adult after First Dose of mRNA Vaccine

Yusuke Miyazato, Kei Yamamoto, Gen Yamada, Shuji Kubota, Masahiro Ishikane, Masaya Sugiyama, Mikako Ueno, Akihiro Matsunaga, Tohru Miyoshi-Akiyama, Yukihito Ishizaka, Norio Ohmagari

Author affiliations: National Center for Global Health and Medicine, Tokyo, Japan (Y. Miyazato, K. Yamamoto, G. Yamada, S. Kubota, M. Ishikane, M. Ueno, A. Matsunaga, T. Miyoshi-Akiyama, Y. Ishizaka, N. Ohmagari); National Center for Global Health and Medicine, Chiba, Japan (M. Sugiyama)

DOI: <https://doi.org/10.3201/eid2804.212585>

A 32-year-old man in Japan experienced respiratory failure after receiving the first dose of coronavirus disease (COVID-19) vaccine. He was treated with noninvasive ventilation and corticosteroids. Serologic test results suggested previous COVID-19; therefore, he received a diagnosis of multisystem inflammatory syndrome. COVID-19 vaccination could be a trigger for this condition.

A 32-year-old man from France living in Tokyo was admitted to the National Center for Global Health and Medicine after experiencing shortness of breath and fever. He had received the first dose of the BNT162b2 (Pfizer-BioNTech, <https://www.pfizer.com>) vaccine 5 days before admission. After vaccination, he experienced a fever, systemic joint pain, nausea, and vomiting. The patient sought care because of these persistent symptoms.

At admission, the patient was experiencing dyspnea as well as chest and back pain that worsened during inhalation. The patient was obese (body mass index 42.1 kg/m<sup>2</sup>). He had no history of smoking, illegal drug use, or international travel. When he received the vaccine, Japan was experiencing its largest coronavirus disease (COVID-19) surge, but he had no known exposure to patients with COVID-19. At admission, he had a body temperature of 38.1°C and peripheral oxygen saturation (SpO<sub>2</sub>) of 95% on room air (Table). He had no notable jugular venous dilation, chest crackles, peripheral edema, or rashes.

Laboratory test results showed an elevated inflammatory response and cardiac enzymes (Table). Chest computed tomography (CT) showed smooth interlobular septal thickening, mixed lesions with ground-glass opacities, and infiltrates in the bilateral lower lobes (Figure, panel A). Electrocardiography

showed slight ST segment elevations in leads I, aVL, V1, and V2. Echocardiography showed no pericardial effusion, myocardial edema, or decreased wall motion. Real-time PCR results were negative for severe acute respiratory syndrome coronavirus 2 (SARS-CoV-2). Loop-mediated isothermal amplification did not detect *Legionella pneumophila*. We used FilmArray version 1.3 (bioMérieux, <https://www.biomerieux.com>) to conduct a respiratory panel on respiratory specimens and a meningitis/encephalitis panel on serum specimens to detect herpesvirus, enterovirus, and cytomegalovirus; results of both panels were negative.

One day after admission, the patient's dyspnea and hypoxemia worsened, and he experienced profuse cold sweats. His SpO<sub>2</sub> dropped to 90% despite 10 L/min of oxygen supply. We suspected severe respiratory failure resulting from COVID-19 vaccine-related systemic inflammation and congestive heart failure. Therefore, we treated the patient with intravenous methylprednisolone at a dose of 1 mg/kg/day (125 mg/d) and with diuretics and noninvasive ventilation (NIV). The next day, his symptoms and hypoxemia greatly improved. He tapered off both treatments; he no longer needed ventilation 2 days after treatment and completed the course of steroids by the day of discharge, 7 days after admission. One month after discharge, CT was performed to confirm the improvement in the lung lesions (Figure, panel B).

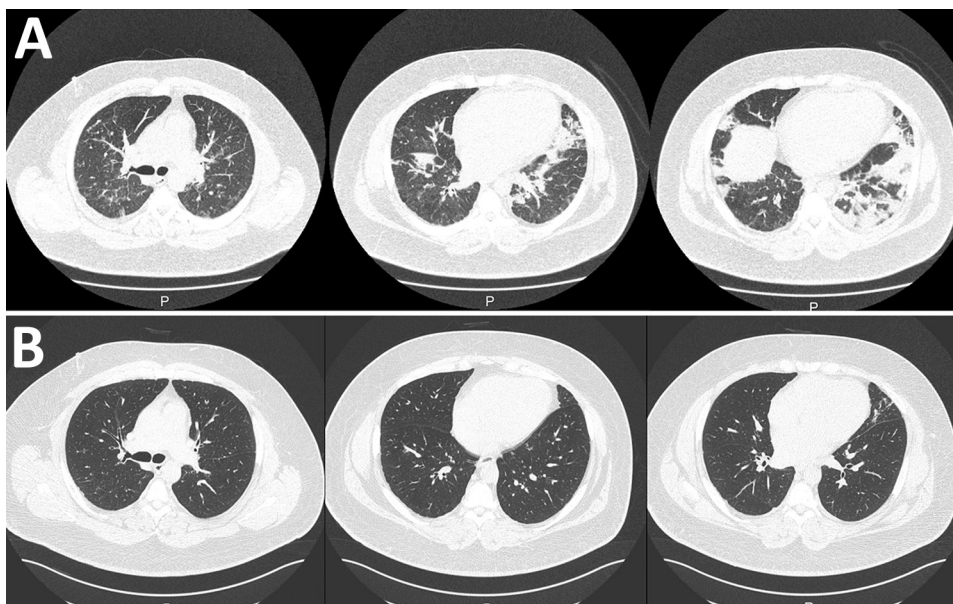
Testing showed that SARS-CoV-2 spike IgG and neutralizing activities were significantly elevated 5 days and 23 days after the first COVID-19 vaccination dose had been administered (Appendix Figure 1, <https://wwwnc.cdc.gov/EID/article/28/4/21-2585-App1.pdf>). Moreover, SARS-CoV-2 nucleocapsid IgG in the serum was positive 5 days after COVID-19 vaccination. On the basis of these findings, we hypothesize that the patient had an asymptomatic or mild SARS-CoV-2 infection before vaccination. After his discharge, we measured a panel of 67 cytokines and chemokines from the patient and 3 healthy controls for comparison (Appendix Table, Figure 2).

This case emphasized 2 clinical issues. First, severe respiratory failure can occur after COVID-19 vaccination, and steroids effectively alleviated this complication. Second, multisystem inflammatory syndrome in adults (MIS-A) can occur after COVID-19 vaccination in a previously infected patient and can manifest as respiratory distress. In cases of respiratory failure after the vaccination, a previous SARS-CoV-2 infection should be considered.

**Table.** Clinical features and laboratory results of a patient who experienced multisystem inflammatory syndrome in an adult after a coronavirus vaccination, Japan, 2021

Characteristic	Hospital day 1	Hospital day 2	Hospital day 3	Hospital day 5	Day of discharge (day 8)	1 month after discharge	Reference range
<b>Clinical features</b>							
Maximum body temperature, °C	38.1	39.1	36.8	36.8	36.8	36.0	NA
Maximum respiratory rate, breaths/min	20	35	26	22	18	NA	NA
Maximum heart rate, bpm	126	128	120	111	100	NA	NA
Minimum blood pressure, mm Hg	102/81	105/85	113/88	141/85	135/85	NA	NA
<b>Laboratory results</b>							
SARS-CoV-2 real-time PCR	Negative	NA	NA	NA	NA	NA	Negative
SARS-CoV-2 spike IgG	Positive	NA	NA	NA	NA	Positive (day 19)	Negative
SARS-CoV-2 nucleocapsid IgG	Positive	NA	NA	NA	NA	NA	Negative
Leukocytes, cells/ $\mu$ L	12,790	16,330	14,280	13,380	17,680	4,780	3,300–8,600
Platelets, $\times 10^3/\mu$ L	166	217	240	294	341	208	158–348
Creatinine, mg/dL	1.02	1.14	1.26	1.09	0.95	1.07	0.65–1.07
LDH, U/L	210	228	225	227	214	213	124–222
Troponin I, ng/mL	0.371	1.102	1.306	0.295	0.094	NA	0–0.026
BNP, pg/mL	129.3	409.5	NA	NA	68.0	NA	0–18.4
CRP, mg/dL	30.73	35.82	33.34	10.35	1.98	0.08	0–0.14
Ferritin, ng/mL	880.0	NA	NA	NA	NA	NA	21–282
ESR, mm/h	NA	NA	NA	NA	49	NA	2–10
IL-6, pg/mL	NA	NA	NA	99.29	0 (day 9)	0 (day 44)	0
<b>Treatment</b>							
Oxygen delivery devices	Nasal cannula	NIV	NIV	Nasal cannula	None	None	NA
Corticosteroids	None	mPSL 125 mg/d (1 mg/kg/d) IV	mPSL 125 mg/d (1 mg/kg/d) IV	PSL 60 mg orally	None	None	NA
Diuretics	Furosemide 20 mg orally	Furosemide 40 mg IV	Furosemide 40 mg IV	Furosemide 20 mg orally	None	None	NA
Antimicrobial drugs	LVFX 500 mg orally	LVFX 500 mg orally	None	None	None	None	NA

\*BNP, brain natriuretic peptide; CRP, C-reactive protein; ESR, erythrocyte sedimentation rate; IL-6, interleukin-6; IV, intravenous; IgG, immunoglobulin G; LDH, lactate dehydrogenase; LVFX, levofloxacin; mPSL, methylprednisolone; NA, not applicable; NIV, noninvasive ventilation; PSL, prednisolone; SARS-CoV-2, severe acute respiratory syndrome coronavirus 2.



**Figure.** Chest computed tomography (CT) images of a male patient in Japan who was hospitalized with multisystem inflammatory syndrome. A) CT performed at hospital admission revealed infiltration in bilateral lower lobes. B) Chest CT performed a month after discharge revealed that most of these lesions had resolved.

Postvaccination myocarditis has been reported as more common in male than in female patients (1). Bozkurt et al. described mild cases (1); however, severe cases have also been reported (2). Although our patient's myocardial damage was not severe, we suspected myocarditis based on his elevated troponin I level after COVID-19 vaccination. Vaccine-related myocarditis typically develops after the second vaccination, but it has been reported after the first vaccination of patients who had COVID-19 previously (1). Therefore, we considered the possibility of myocarditis after the first vaccination in this patient, because his serology results suggested a history of COVID-19. Moreover, his respiratory failure, severe inflammation, and serologic test results strongly suggesting a history of COVID-19 led us to suspect MIS-A, as reported by Morris et al. (3). Although the association between the COVID-19 vaccine and MIS-A development is unclear (4), the patient in our case fulfilled the clinical criteria of severe cardiac illness, hypotension, vomiting, and fever. In addition, his laboratory results showed elevated C-reactive protein levels, ferritin levels, interleukin-6 levels, and erythrocyte sedimentation rate. He also exhibited serologic positivity for SARS-CoV-2. These findings were consistent with the definition of MIS-A (5). This case showed that vaccination was a possible trigger of MIS-A in a patient who had a history of COVID-19.

The treatment for postvaccination myocarditis and MIS-A has not been standardized. As demonstrated in our case, immunosuppressive therapy, particularly corticosteroids, improved the prognosis. Intravenous immunoglobulin, anakinra, and infliximab have been used to treat multisystem inflammatory syndrome in children (6,7); a previous case report documented their role in treating MIS-A (8).

### Acknowledgments

We thank Hitomi Igarashi for providing technical assistance.

This research was supported by the National Center for Global Health and Medicine Intramural Research Fund (grant no. 21A006) and Japan Agency for Medical Research and Development Research Program on Emerging and Re-emerging Infectious Diseases (no. JP20fk0108416).

### About the Author

Dr. Miyazato is a clinical fellow in the Disease Control and Prevention Center at the National Center for Global Health and Medicine. His primary research interests are sexually transmitted diseases and clinical infectious diseases.

### References

1. Bozkurt B, Kamat I, Hotez PJ. Myocarditis with COVID-19 mRNA vaccines. *Circulation*. 2021;144:471–84. <https://doi.org/10.1161/CIRCULATIONAHA.121.056135>
2. Abbate A, Gavin J, Madanchi N, Kim C, Shah PR, Klein K, et al. Fulminant myocarditis and systemic hyperinflammation temporally associated with BNT162b2 mRNA COVID-19 vaccination in two patients. *Int J Cardiol*. 2021;340:119–21. <https://doi.org/10.1016/j.ijcard.2021.08.018>
3. Morris SB, Schwartz NG, Patel P, Abbo L, Beauchamps L, Balan S, et al. Case series of multisystem inflammatory syndrome in adults associated with SARS-CoV-2 infection—United Kingdom and United States, March–August 2020. *MMWR Morb Mortal Wkly Rep*. 2020;69:1450–6. <https://doi.org/10.15585/mmwr.mm6940e1>
4. Centers for Disease Control and Prevention. Interim clinical considerations for use of COVID-19 vaccines currently approved or authorized in the United States. 2021 [cited 2021 Dec 10]. <https://www.cdc.gov/vaccines/covid-19/clinical-considerations/covid-19-vaccines-us.html>
5. Centers for Disease Control and Prevention. Multisystem inflammatory syndrome in adults (MIS-A) case definition information for healthcare providers. 2021 [cited 2022 Jan 16]. <https://www.cdc.gov/mis/mis-a/hcp.html>
6. Henderson LA, Canna SW, Friedman KG, Gorelik M, Lapidus SK, Bassiri H, et al. American College of Rheumatology clinical guidance for multisystem inflammatory syndrome in children associated with SARS-CoV-2 and hyperinflammation in pediatric COVID-19: version 2. *Arthritis Rheumatol*. 2021;73:e13–29. <https://doi.org/10.1002/art.41616>
7. Cole LD, Osborne CM, Silveira LJ, Rao S, Lockwood JM, Kunkel MJ, et al. IVIG compared with IVIG plus infliximab in multisystem inflammatory syndrome in children. *Pediatrics*. 2021;148:e2021052702. <https://doi.org/10.1542/peds.2021-052702>
8. Ahmad F, Ahmed A, Rajendraprasad SS, Loranger A, Gupta S, Velagapudi M, et al. Multisystem inflammatory syndrome in adults: a rare sequela of SARS-CoV-2 infection. *Int J Infect Dis*. 2021;108:209–11. <https://doi.org/10.1016/j.ijid.2021.05.050>

Address for correspondence: Kei Yamamoto, Disease Control and Prevention Center, National Center for Global Health and Medicine, 1-21-1 Toyama, Shinjuku-ku, Tokyo 162-8655, Japan; email: [kyamamoto@hosp.ncgm.go.jp](mailto:kyamamoto@hosp.ncgm.go.jp)

# Multisystem Inflammatory Syndrome in Adult after First Dose of mRNA Vaccine

## Appendix

### Additional Methods

After discharge, we measured a panel of 67 cytokines and chemokines from the patient and 3 healthy controls using Bio-plex Pro Human Chemokine assays (Bio-Rad, <https://www.bio-rad.com>) (Appendix Table, Appendix Figure 2) to investigate abnormal responses induced by coronavirus disease. The patient's BCA-1/CXCL13, HGF, IL-5, IL-6, IL-8/CXCL8, IL-13, IL-15, IL-16, IP-10/CXCL10, MIF, MPIF-1/CCL23, PDGF-BB, and VEGF levels were elevated before steroid administration compared to healthy controls and became almost normal during the recovery period.

Among the cytokines known to be elevated in the cytokine storm, IL-1, IL-2, IL-6, IL-7, IL-12, IL-17, IL-18 TNF- $\alpha$ , MCSF, G-CSF, CXCL-10/IP-10, CCL-3, CCL-5, IFN- $\gamma$ , and MCP-1, only IL-6 and CXCL-10/IP-10 were elevated in the acute phase (1). We believe that the elevation of IL-5, IL-16, MIF, and VEGF are also characteristic of this case. IL-5, IL-16, and MIF have been reported to be elevated in myocardial injury (2–4), and MIF and VEGF have been suggested to be associated with vasculitis (5,6), which may be related to the pathogenesis of this case.

## References

1. Mariappan V, Manoharan PS, R P, Shanmugam L, Rao SR, Pillai AB. Potential biomarkers for the early prediction of SARS-COV-2 disease outcome. *Microb Pathog.* 2021;158:105057. [PubMed](#)  
<https://doi.org/10.1016/j.micpath.2021.105057>
2. Song T, Jones DM, Homsy Y. Therapeutic effect of anti-IL-5 on eosinophilic myocarditis with large pericardial effusion. *BMJ Case Rep.* 2017;2017:bcr-2016-218992. [PubMed](#)  
<https://doi.org/10.1136/bcr-2016-218992>
3. Zhang J, Yang Z, Liang Z, Wang M, Hu C, Chang C, et al. Anti-interleukin-16-neutralizing antibody attenuates cardiac inflammation and protects against cardiac injury in doxorubicin-treated mice. *Mediators Inflamm.* 2021;2021:6611085. [PubMed](#) <https://doi.org/10.1155/2021/6611085>
4. Fan F, Fang L, Moore XL, Xie X, Du XJ, White DA, et al. Plasma macrophage migration inhibitor factor is elevated in response to myocardial ischemia. *J Am Heart Assoc.* 2016;5:e003128.  
[PubMed](#) <https://doi.org/10.1161/JAHA.115.003128>
5. Wakabayashi K, Otsuka K, Sato M, Takahashi R, Odai T, Isozaki T, et al. Elevated serum levels of macrophage migration inhibitory factor and their significant correlation with rheumatoid vasculitis disease activity. *Mod Rheumatol.* 2012;22:59–65. [PubMed](#)  
<https://doi.org/10.3109/s10165-011-0466-z>
6. Yücel Ç, Sertoğlu E, Fırat Oğuz E, Hayran Y, Omma A, Özgürtaş T. Serum VEGF-A and VEGFR-1 levels in patients with adult immunoglobulin A vasculitis. *Int J Rheum Dis.* 2021;24:789–94.  
[PubMed](#) <https://doi.org/10.1111/1756-185X.14115>

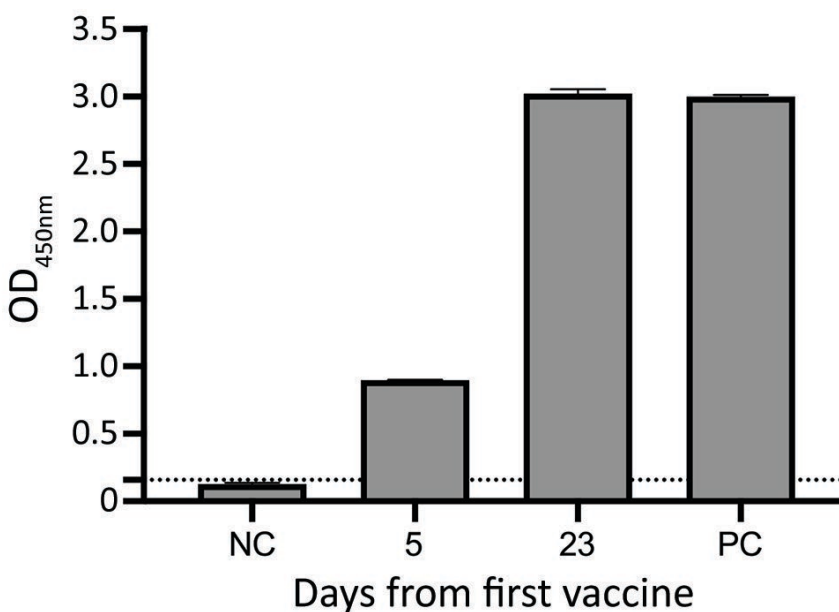
**Appendix Table.** Profile of 67 cytokines and chemokines from a patient with multisystem inflammatory syndrome in an adult and 3 healthy persons who had received 2 doses of mRNA vaccine for coronavirus disease

Cytokines and chemokines	Patient					Controls		
	Day 5	Day 6	Day 9	Day 23	Day 44	N1	N2	N3
BCA-1/CXCL13	91.93	93.02	33.63	27.79	33.04	26.81	27.16	24.96
HGF	860.57	916.26	513.33	420.42	462.91	328.58	242.75	187.56
IL-5	45.35	48.35	0.00	0.00	0.00	0.00	0.00	0.00
IL-6	99.29	79.43	0.00	0.00	0.00	0.00	0.00	0.00
IL-8/CXCL8	23.01	21.97	10.25	12.13	14.56	9.03	10.68	7.85
IL-13	1.73	1.93	0.00	0.00	0.00	0.00	0.00	0.00
IL-15	573.25	551.10	0.00	0.00	0.00	0.00	0.00	0.00
IL-16	251.27	192.02	86.50	108.90	121.02	91.20	81.37	73.20
IP-10/CXCL10	923.37	836.39	103.41	92.82	152.13	197.93	97.95	150.18
MIF	21,666.34	45,596.47	17,066.50	24,660.14	2,433.82	1,568.66	1,421.55	2,559.85
MPIF-1/CCL23	917.16	1,077.75	317.36	249.18	185.88	168.91	67.99	291.75
PDGF-BB	7,437.96	5,179.37	3,261.03	2,455.29	2,895.53	4,077.71	1,628.17	2,180.10
VEGF	227.94	271.61	0.00	0.00	0.00	0.00	0.00	0.00
b-NGF	30.04	30.13	6.32	7.72	3.19	0.00	0.00	0.00
GCP-2/CXCL6	160.60	127.54	234.13	194.95	373.96	29.53	27.86	37.87
G-CSF	808.20	572.19	1,101.25	1,189.84	3,463.18	116.85	166.68	122.80
Gro-b/CXCL2	613.63	558.26	874.69	747.56	1,276.49	199.66	315.38	296.14
IFN- $\alpha$ 2	9.54	7.06	4.75	5.93	8.34	0.00	0.00	0.00
IL-1 $\alpha$	38.68	31.24	22.65	25.09	21.90	2.01	2.01	0.19
IL-1 $\alpha$	869.98	878.00	130.95	172.08	309.16	44.71	0.00	0.00
IL-2 $\alpha$	118.62	116.42	79.87	80.98	108.86	50.41	40.80	46.40
IL-12(p40)	180.16	128.66	124.88	113.61	181.62	65.73	35.30	35.30
IL-17	12.88	8.42	2.49	4.62	9.87	0.00	0.00	0.00
IL-18	113.03	93.66	53.68	56.97	60.35	20.16	35.33	19.20
I-TAC/CXCL11	128.64	130.71	258.81	158.94	79.01	22.94	17.68	30.81
M-CSF	39.22	29.75	26.71	27.35	22.10	7.17	11.19	10.18
MIP-1 $\alpha$ /CCL3	267.53	194.33	378.72	435.93	1554.19	4.76	7.27	4.76
MIP-1 $\delta$ /CCL15	5,363.92	5,592.40	3,610.77	3,456.25	4,886.33	2,536.68	2,686.14	1,751.91
6Ckine/CCL21	26,044.85	39,882.28	17,327.50	19,974.72	59,927.96	23,972.90	25,506.51	21,218.49
ENA-78/CXCL5	1,212.70	977.62	942.50	695.23	3,312.40	825.19	776.21	764.77

Cytokines and chemokines	Patient					Controls		
	Day 5	Day 6	Day 9	Day 23	Day 44	N1	N2	N3
Eotaxin-2/CCL24	610.70	733.43	1160.59	968.08	976.64	428.15	526.03	332.06
Gro-a/CXCL1	365.64	347.95	376.18	393.44	921.62	218.10	174.88	182.84
LIF	77.01	70.30	61.98	66.18	112.24	50.08	30.82	52.39
MCP-3/CCL7	0.00	0.00	0.00	0.00	42.59	0.00	0.00	0.00
MCP-4/CCL13	66.89	60.32	59.43	57.52	134.17	60.58	66.21	53.50
BasicFGF	51.09	40.12	33.58	37.90	64.48	43.51	38.95	47.77
CTACK/CCL27	1103.94	746.55	438.94	502.99	873.03	878.66	759.24	1123.30
Eotaxin/CCL11	47.07	53.18	34.86	37.49	59.50	47.78	67.31	63.64
Eotaxin-3/CCL26	83.57	81.38	79.49	70.25	113.99	94.96	100.01	104.82
Fractalkine/CX3CL1	126.98	112.19	154.47	149.99	222.58	133.50	119.69	181.95
GM-CSF	25.22	24.23	25.16	22.18	33.92	21.10	24.61	24.70
I-309/CCL1	32.89	30.92	29.11	31.80	61.86	43.29	44.17	54.29
IFN-g	27.31	26.81	30.19	26.10	37.50	30.88	24.68	25.84
IL-1b	6.29	6.76	5.89	6.09	8.62	6.68	7.35	7.51
IL-2	0.00	0.00	0.00	0.00	14.05	7.31	5.32	8.90
IL-3	0.01	0.00	0.00	0.00	0.00	0.00	0.00	0.00
IL-4	81.83	75.30	83.59	80.30	107.60	68.40	70.87	80.52
IL-7	9.74	12.49	0.00	0.00	7.35	7.35	10.87	0.07
IL-9	208.11	228.20	226.58	216.36	327.58	297.72	281.09	311.00
IL-10	8.16	8.79	6.89	6.72	10.54	8.03	6.42	8.40
IL-12(p70)	0.00	0.00	0.00	0.00	0.00	0.00	0.00	0.00
MCP-1/CCL2	53.91	64.66	46.43	52.05	79.06	60.63	69.33	62.39
MCP-2/CCL8	53.48	50.60	26.42	31.40	71.61	101.63	54.37	55.22
MDC/CCL22	792.45	701.66	474.66	665.63	928.56	541.04	662.62	620.09
MIG/CXCL9	56.05	47.46	16.67	16.96	41.42	30.58	34.09	34.39
MIP-1b	224.02	225.72	217.14	221.23	244.88	221.81	196.70	209.23
MIP-3a/CCL20	0.00	0.00	0.00	0.00	0.00	0.00	0.00	0.00
MIP-3b/CCL19	138.39	135.39	0.00	15.78	204.26	127.83	107.47	147.32
RANTES	9,363.29	8,820.77	6,618.98	6,886.85	8,146.81	7,986.42	6,914.73	7,588.66
SCF	75.83	64.30	46.75	59.98	95.11	75.33	68.48	99.40
SCGF-b	141,179.79	108,130.23	151,784.32	166,409.90	174,281.40	113,842.98	149,646.34	157,163.45

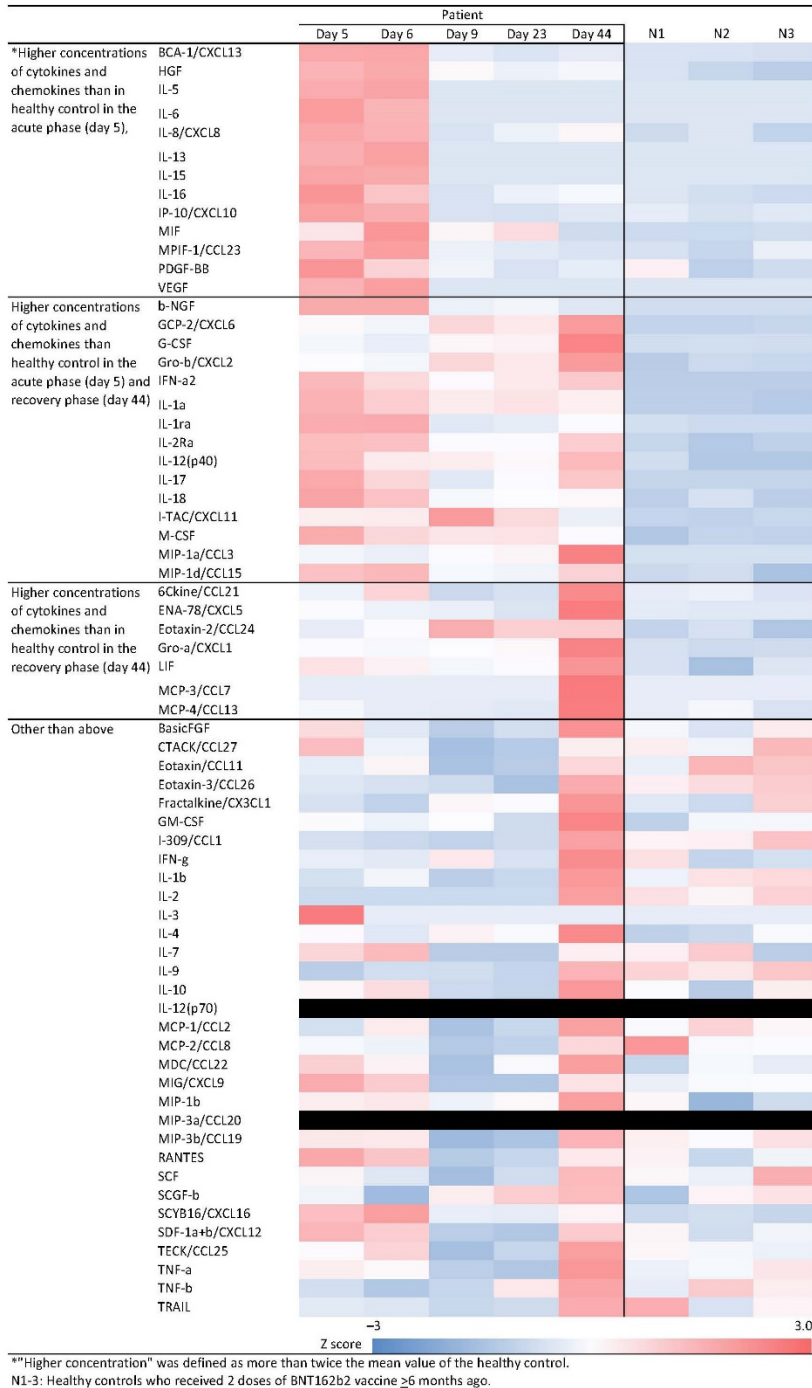
Cytokines and chemokines	Patient					Controls		
	Day 5	Day 6	Day 9	Day 23	Day 44	N1	N2	N3
SCYB16/CXCL16	863.50	958.28	630.81	624.50	709.56	553.42	573.47	542.07
SDF-1a+b/CXCL12	2,704.63	2514.82	1,580.83	1,512.64	2,530.59	2,178.87	1,762.36	2,021.26
TECK/CCL25	1,045.18	1,147.02	824.00	902.54	1,289.05	1,052.93	1,019.89	997.06
TNF-a	130.18	126.50	99.40	95.10	167.69	117.97	122.05	134.08
TNF-b	279.37	265.23	274.34	306.91	339.22	287.75	320.74	304.75
TRAIL	13.45	13.23	12.33	12.61	18.53	18.43	13.00	15.06

\*Values are expressed in pg/mL. Values below the detection sensitivity are indicated as 0.00.



**Appendix Figure 1.** Severe acute respiratory syndrome coronavirus 2 anti-spike (full-length) antibody titers from a patient with multisystem inflammatory syndrome in an adult. Antibody induction was observed within 5 days after vaccination. High antibody titers were obtained 23 days after vaccination. Dotted line indicates the positivity criterion, which was based on the negative control mean + 3 SD. NC, negative control; PC, positive control.





**Appendix Figure 2.** Profile of 67 cytokines and chemokines from a patient with multisystem inflammatory syndrome, compared with those of 3 healthy persons as controls. The controls were infection-free men 34–41 years of age who had received 2 doses of the BNT162b2 vaccine (Pfizer-BioNTech, <https://www.pfizer.com>).

