

of death were higher for patients with multiple and more severe underlying conditions. Further studies are necessary to better clarify the mechanisms that lead to severe outcomes among these patients.

For case-patients infected with MERS-CoV, the presence and compounding of underlying conditions, including DM, hypertension, and, ultimately, COD, corresponded with an increasingly complicated clinical course and death. These findings indicate that increased clinical vigilance is warranted for patients with multiple and severe underlying conditions who are suspected of being infected with MERS-CoV.

About the Author

Dr. Alanazi is director general of infection prevention and control at the Ministry of Health, Riyadh, Saudi Arabia. His research interests include prevention and control of infectious diseases in the healthcare setting.

References

1. World Health Organization. Regional office for the Eastern Mediterranean. MERS situation update; October 2018 [cited 2019 Oct 30]. <http://www.emro.who.int/pandemic-epidemic-diseases/mers-cov/mers-situation-update-october-2018.html>
2. Assiri A, Al-Tawfiq JA, Al-Rabeeh AA, Al-Rabiah FA, Al-Hajjar S, Al-Barrak A, et al. Epidemiological, demographic, and clinical characteristics of 47 cases of Middle East respiratory syndrome coronavirus disease from Saudi Arabia: a descriptive study. *Lancet Infect Dis*. 2013;13:752–61. [https://doi.org/10.1016/S1473-3099\(13\)70204-4](https://doi.org/10.1016/S1473-3099(13)70204-4)
3. Alqahtani FY, Aleanizy FS, Ali El Hadi Mohamed R, Alanazi MS, Mohamed N, Alrasheed MM, et al. Prevalence of comorbidities in cases of Middle East respiratory syndrome coronavirus: a retrospective study. *Epidemiol Infect*. 2018;Nov 5:1–5.
4. Al-Abdely HM, Midgley CM, Alkhamis AM, Abedi GR, Lu X, Binder AM, et al. Middle East respiratory syndrome coronavirus infection dynamics and antibody responses among clinically diverse patients, Saudi Arabia. *Emerg Infect Dis*. 2019;25:753–66. <https://doi.org/10.3201/eid2504.181595>
5. Alraddadi BM, Watson JT, Almarashi A, Abedi GR, Turkistani A, Sadran M, et al. Risk factors for primary Middle East respiratory syndrome coronavirus illness in humans, Saudi Arabia, 2014. *Emerg Infect Dis*. 2016;22:49–55. <https://doi.org/10.3201/eid2201.151340>

Address for correspondence: Glen R. Abedi, Centers for Disease Control and Prevention, 1600 Clifton RD NE, Mailstop A34, Atlanta, GA 30329-4027, USA; email: gabedi@cdc.gov

Influenza D Virus of New Phylogenetic Lineage, Japan

Shin Murakami, Ryota Sato, Hiroho Ishida, Misa Katayama, Akiko Takenaka-Uema, Taisuke Horimoto

Author affiliations: University of Tokyo, Tokyo, Japan (S. Murakami, H. Ishida, M. Katayama, A. Takenaka-Uema, T. Horimoto); Yamagata Livestock Hygiene Service Center, Yamagata, Japan (R. Sato)

DOI: <https://doi.org/10.3201/eid2601.191092>

Influenza D virus (IDV) can potentially cause respiratory diseases in livestock. We isolated a new IDV strain from diseased cattle in Japan; this strain is phylogenetically and antigenically distinguished from the previously described IDVs.

Influenza D virus (IDV; family *Orthomyxoviridae*) is one of the possible bovine respiratory disease complex (BRDC) causative agents. IDVs are detected in and isolated from cattle in many countries in North America, Asia, Europe, and Africa (1–4). In addition, both IDV RNAs and specific antibodies have been detected in many animal species (1,5,6). To date, IDVs have been phylogenetically classified into 3 lineages: D/OK, D/660, and Japanese lineages. We isolated a new IDV strain from cattle in Japan with respiratory disease, whose hemagglutinin-esterase-fusion (HEF) gene did not belong to the known phylogenetical lineages.

At a herd in Yamagata Prefecture in northern Japan, 15 Holsteins (37.5% of bred cattle in the herd) had respiratory signs develop during January 6–10, 2019 (Appendix Table 1, <http://wwwnc.cdc.gov/EID/article/26/1/19-1092-App1.pdf>). We collected nasal swab samples from 9 of 15 cows on January 7 and 10. All samples subjected to IDV-specific real-time reverse transcription PCR (RT-PCR) (7) were found positive. We also subjected these samples to RT-PCR analyses specific for bovine viral diarrhoea virus 1 and 2, infectious bovine rhinotracheitis virus, bovine parainfluenza virus 3, bovine respiratory syncytial virus, bovine coronavirus, bovine rhinitis A virus, *Mycobacterium bovis*, *Mycoplasma bovis*, *Mycoplasma dispar*, *Ureaplasma diversum*, and *Mycoplasma bovirhinis*. All samples were found negative for these pathogens except for the sample from cow no. 5, which was positive for *M. dispar*. Despite these cows receiving antimicrobial drug treatment, we isolated *Mannheimia haemolytica* from 7 of them (nos. 1–5, 7, 8); cow no. 5 died on January 7. Taken together, these

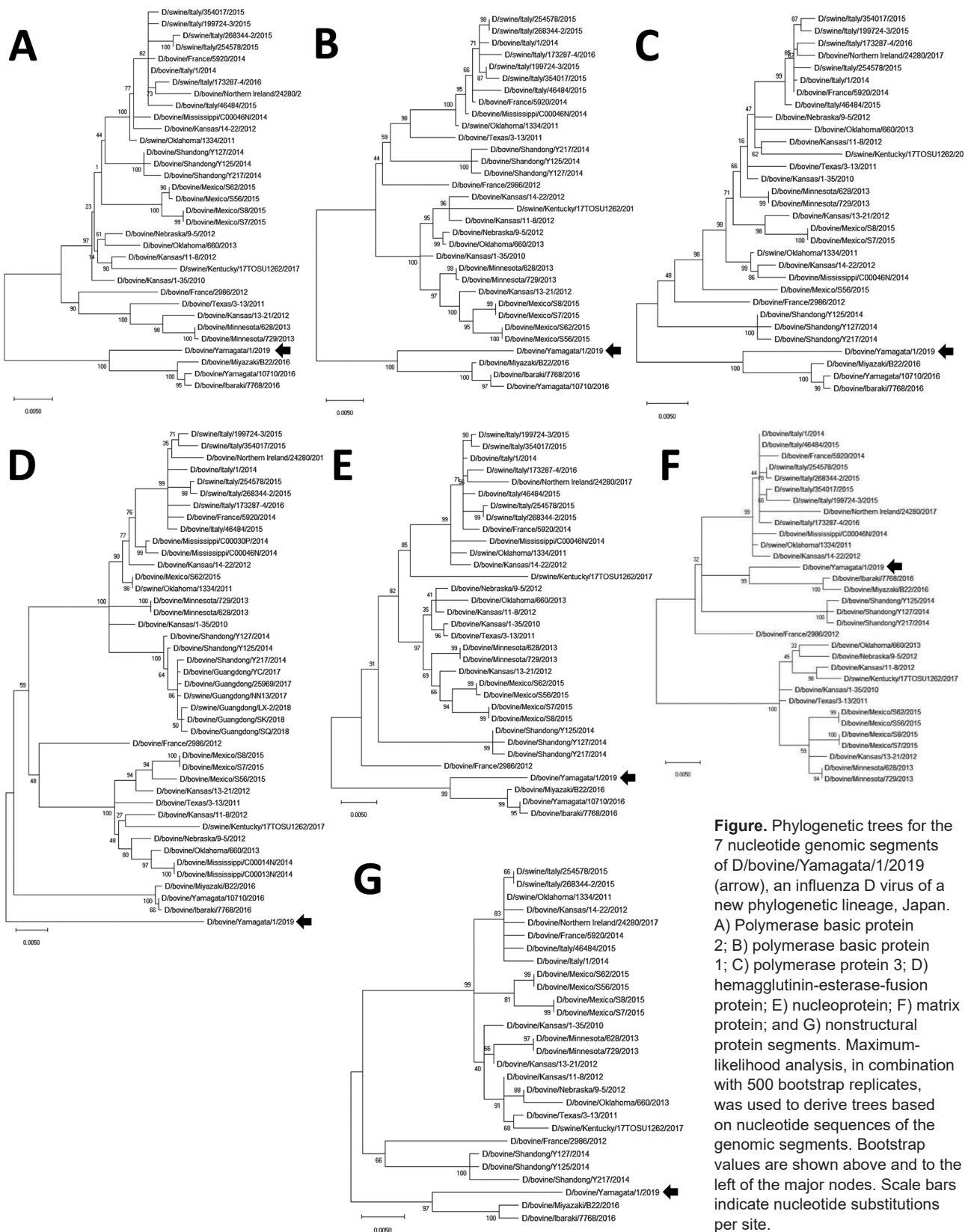


Figure. Phylogenetic trees for the 7 nucleotide genomic segments of D/bovine/Yamagata/1/2019 (arrow), an influenza D virus of a new phylogenetic lineage, Japan. A) Polymerase basic protein 2; B) polymerase basic protein 1; C) polymerase protein 3; D) hemagglutinin-esterase-fusion protein; E) nucleoprotein; F) matrix protein; and G) nonstructural protein segments. Maximum-likelihood analysis, in combination with 500 bootstrap replicates, was used to derive trees based on nucleotide sequences of the genomic segments. Bootstrap values are shown above and to the left of the major nodes. Scale bars indicate nucleotide substitutions per site.

factors suggested that IDV infection was involved in the onset of BRDC in this herd.

To isolate IDV, we inoculated the collected samples into human rectal tumor HRT-18G cells (American Type Culture Collection [ATCC] no. CRL-11663), incubated the cells for 4 days at 37°C, and blindly passaged the supernatants in swine testis ST cells (ATCC no. CRL-1746) in the presence of tosyl phenylalanyl chloromethyl ketone-treated trypsin. We observed a cytopathic effect at the second passage. For further analysis, we used supernatants that tested positive for hemagglutination (HA) and for presence of IDV RNA detected by real-time RT-PCR, indicating successful isolation of IDV (designated as D/bovine/Yamagata/1/2019 [D/Yama2019]). We determined the entire genomic sequence of D/Yama2019 by performing RT-PCR amplification of each viral segment with specific primers, revealing an identical sequence with that detected in swab sample no. 1. We deposited our sequence data in GenBank (accession nos. LC494105–11).

We phylogenetically analyzed the sequences of D/Yama2019 by performing maximum-likelihood analysis using MEGA version X (8). The HEF sequence of D/Yama2019 acquired an independent position different from that exhibited in any other lineage, whereas those of the other segments were positioned relatively close to the preexisting Japanese strains, in which polymerase basic protein 1 and 2, polymerase protein 3, nucleoprotein, and nonstructural protein sequences were of the Japanese lineage, whereas the matrix sequence was of the D/OK lineage (Figure).

We also collected serum samples from 8 cows on January 10 (acute phase of the disease) and February 4 (recovery phase) and examined them for antibodies against D/Yama2019 by using the HA inhibition (HI) test (Appendix Table 1). We treated serum samples with receptor-destroying enzyme (RDEII; Denka Seiken, Tokyo, Japan, <https://www.denka.co.jp>) before the HI test, which was done with the D/Yama2019 antigen and 0.6% turkey erythrocyte suspension. We considered samples with HI titer >1:40 to be positive (4). All serum samples collected on January 7 were HI-negative except for the sample from cow no. 1 (a titer of 1:40), whereas all samples collected on February 4 were HI-positive (a titer range of 1:40–1:160), confirming seroconversion to IDV antibodies in diseased cows. Taken together, these results indicate that cattle were infected with IDV, leading to BRDC in this herd.

We next compared HEF antigenicities among D/Yama2019 and 3 reference IDVs, D/swine/

Oklahoma/1334/2011 (D/OK) in the D/OK-lineage (1), D/bovine/Nebraska/9–5/2012 (D/NE) in the D/660-lineage (9), and D/bovine/Yamagata/10710/2016 (D/Yama2016) in the Japanese lineage (10), by performing HI tests using anti-IDV mouse serum and a panel of anti-HEF monoclonal antibodies (Appendix Table 2). We observed 1-way cross-reactivity between D/Yama2019 and D/OK or D/Yama2016 with antiserum. Monoclonal antibody clones B4 and R36 cross-reacted to D/Yama2019 and other tested viruses with different titers, whereas the clones G22, G27, and G74, which reacted strongly to D/Yama2016, did not react to D/Yama2019. These data indicated HEF antigenic heterogeneity between D/Yama2019 and viruses of the 3 known lineages. Monoclonal antibodies revealed the presence of common epitopes among IDVs, as suggested by previous reports (9,10). Amino acid differences were located on the head region of HEF among the IDVs, possibly causing antigenic heterogeneity.

In summary, we isolated a newly identified IDV from diseased cattle that was phylogenetically and antigenically distinguished from known IDVs. Further epidemiologic studies are needed to clarify invasion and epidemic status of these heterologous IDVs, but our results indicated that heterologous IDVs are circulating in close vicinity within the prefecture.

Acknowledgments

We thank Ben M. Hause for the viruses used in the study.

S.M. is supported by a Grant-in-Aid for the Encouragement of Young Scientists (A) (grant no. 17H05042). T.H. is supported by Livestock Promotion Funds from the Japan Racing Association.

About the Author

Dr. Murakami is an associate professor at the Graduate School of Agricultural and Life Sciences, University of Tokyo, Tokyo, Japan. His research interests include epidemiologic and molecular biological studies of animal viruses, including influenza viruses.

References

- Hause BM, Ducatez M, Collin EA, Ran Z, Liu R, Sheng Z, et al. Isolation of a novel swine influenza virus from Oklahoma in 2011 which is distantly related to human influenza C viruses. *PLoS Pathog.* 2013;9:e1003176. <https://doi.org/10.1371/journal.ppat.1003176>
- Jiang WM, Wang SC, Peng C, Yu JM, Zhuang QY, Hou GY, et al. Identification of a potential novel type of influenza virus in bovine in China. *Virus Genes.* 2014;49:493–6. <https://doi.org/10.1007/s11262-014-1107-3>

3. Dane H, Duffy C, Guelbenzu M, Hause B, Fee S, Forster F, et al. Detection of influenza D virus in bovine respiratory disease samples, UK. *Transbound Emerg Dis*. 2019;66:2184–7. <https://doi.org/10.1111/tbed.13273>
4. Murakami S, Endoh M, Kobayashi T, Takenaka-Uema A, Chambers JK, Uchida K, et al. Influenza D virus infection in herd of cattle, Japan. *Emerg Infect Dis*. 2016;22:1517–9. <https://doi.org/10.3201/eid2208.160362>
5. Salem E, Cook EAJ, Lbacha HA, Oliva J, Awoume F, Aplogon GL, et al. Serologic evidence for influenza C and D virus among ruminants and camelids, Africa, 1991–2015. *Emerg Infect Dis*. 2017;23:1556–9. <https://doi.org/10.3201/eid2309.170342>
6. Murakami S, Odagiri T, Melaku SK, Bazartseren B, Ishida H, Takenaka-Uema A, et al. Influenza D virus infection in dromedary camels, Ethiopia. *Emerg Infect Dis*. 2019;25:1224–6. <https://doi.org/10.3201/eid2506.181158>
7. Faccini S, De Mattia A, Chiapponi C, Barbieri I, Boniotti MB, Rosignoli C, et al. Development and evaluation of a new real-time RT-PCR assay for detection of proposed influenza D virus. *J Virol Methods*. 2017;243:31–4. <https://doi.org/10.1016/j.jviromet.2017.01.019>
8. Kumar S, Stecher G, Li M, Knyaz C, Tamura K. MEGA X: Molecular evolutionary genetics analysis across computing platforms. *Mol Biol Evol*. 2018;35:1547–9. <https://doi.org/10.1093/molbev/msy096>
9. Collin EA, Sheng Z, Lang Y, Ma W, Hause BM, Li F. Cocirculation of two distinct genetic and antigenic lineages of proposed influenza D virus in cattle. *J Virol*. 2015;89:1036–42. <https://doi.org/10.1128/JVI.02718-14>
10. Odagiri T, Ishida H, Li JY, Endo M, Kobayashi T, Kamiki H, et al. Antigenic heterogeneity among phylogenetic clusters of influenza D viruses. *J Vet Med Sci*. 2018;80:1241–4. <https://doi.org/10.1292/jvms.18-0157>

Address for correspondence: Taisuke Horimoto, University of Tokyo, Graduate School of Agricultural and Life Sciences, Department of Veterinary Microbiology, 1-1-1 Yayoi, Bunkyo-ku, Tokyo 113-8657, Japan; email: ahorimo@mail.ecc.u-tokyo.ac.jp

Diagnosis of Syphilitic Bilateral Papillitis Mimicking Papilloedema

Alicia Gonzalez-Martinez, Sonia Quintas, Diego Celdrán Vivancos, José Cebrián, José Vivancos

Author affiliation: Hospital Universitario de la Princesa, Madrid, Spain

DOI: <https://doi.org/10.3201/eid2601.191122>

Syphilis produces myriad nonspecific signs and symptoms. For example, optic disk swelling might be seen in patients with syphilis as a result of cranial hypertension (papilloedema), inflammatory optic neuritis with papillitis, or optic perineuritis. We report a case involving differential diagnosis of syphilitic bilateral papillitis mimicking papilloedema.

Syphilis, caused by infection with the bacterium *Treponema pallidum*, is a sexually transmitted infection for which incidence has been increasing since 2002, especially among adult men >55 years of age who engage in risky sex (1). Syphilis has earned its nickname, the “great masquerader,” because it produces myriad nonspecific signs and symptoms that make it difficult to distinguish from certain other diseases. Eye impairment occurs in ≥3% of cases (2,3) and can be the first manifestation (4). Optic nerve involvement, either unilateral or bilateral, in the form of papilloedema, perineuritis, or optic neuritis, is the second most common type of syphilitic ocular impairment (5). Each of these conditions shares findings from funduscopy testing with unilateral or bilateral optic disk swelling (Table), but the etiology and, therefore, the diagnostic algorithm are different. Semiology and ophthalmological findings are the key to achieving a correct syndromic diagnosis.

We describe the case of a 62-year-old man who was admitted to the neurology department at Hospital Universitario de la Princesa in Madrid, Spain, with a 4-day history of bilateral decreased visual acuity. He was obese, an active smoker, and dyslipidemic. He reported neither ocular pain nor dyschromatopsia suggestive of optic neuritis, nor headache or diplopia usually associated with intracranial hypertension. He had no known history of syphilis. Visual acuity was 20/32 in the right eye and 20/63 in the left. Pupils were equal and reactive to light, with no relative afferent pupillary defect, which is typical of unilateral optic neuritis. Slit lamp examination results were normal, showing no inflamed cells in the anterior chambers or vitreous. Neurologic examination was normal. Opening pressure of the cerebrospinal fluid (CSF) on lumbar puncture was 27 cm H₂O, above the reference range of 5–20 cm H₂O. The CSF white cell count was 0, with normal glucose and protein levels. A fundus examination revealed bilateral optic disk swelling and peripapillary retinitis; visual field testing revealed bilateral central scotoma and an enlarged blind spot (Appendix, <https://wwwnc.cdc.gov/EID/article/26/1/19-1122-App1.pdf>).

Doctors initiated acetazolamide for suspected idiopathic intracranial hypertension (IIH), but

Influenza D Virus of New Phylogenetic Lineage, Japan

Appendix

Appendix Table 1. Cattle tested in the study of influenza D virus, Japan*

Cow		Clinical onset of respiratory illness	IDV qRT-PCR	HI titer	
no.	Age, mo			2019 Jan 10	2019 Feb 4
1	78	2019 Jan 6	Positive (2019 Jan 7)†	40	160
2	80	2019 Jan 6	Positive (2019 Jan 7)	<40	160
3	48	2019 Jan 6	Positive (2019 Jan 7)	<40	80
4	116	2019 Jan 7	Positive (2019 Jan 7)	<40	160
5	40	2019 Jan 6	Positive (2019 Jan 10)	ND	ND
6	43	2019 Jan 8	Positive (2019 Jan 10)	<40	160
7	53	2019 Jan 10	Positive (2019 Jan 10)	<40	160
8	29	2019 Jan 9	Positive (2019 Jan 10)	<40	160
9	69	2019 Jan 9	Positive (2019 Jan 10)	<40	40

*HI (hemagglutinin-inhibition) titers against D/bovine/Yamagata/1/2019; IDV, influenza D virus; ND, not determined; qRT-PCR, quantitative reverse transcription PCR

†Dates indicate dates on which nasal swabs were collected.

Appendix Table 2. HI titers of polyclonal and monoclonal antibodies to IDV, Japan, 2019*

Antibody	Virus			
	D/Yama2019	D/Yama2016	D/OK	D/NE
anti-D/OK serum	80	640	320	40
anti-D/Yama2016 serum	80	320	640	40
anti-D/Yama2019 serum	640	320	320	80
B4 mAb	1,280	2,560	40	2,560
B13 mAb	<40	<40	<40	<40
R36 mAb	5,120	40,960	40,960	320
G22 mAb	<40	5,120	320	40
G27 mAb	<40	>81,960	<40	<40
G74 mAb	<40	320	<40	80

*D/Yama2019, D/bovine/Yamagata/1/2019; D/Yama2016, D/bovine/Yamagata/10710/2016; D/OK, D/swine/Oklahoma/1334/2011; D/NE,

D/bovine/Nebraska/9-5/2012; HI, hemagglutination-inhibition; IDV, influenza D virus; mAb, monoclonal antibody raised against

D/bovine/Yamagata/10710/2016 in BALB/c mice.