

## References

1. Shayan S, Bokaeian M, Shahrivar MR, Chinikar S. Crimean-Congo hemorrhagic fever. *Lab Med*. 2015;46:180–9. <http://dx.doi.org/10.1309/LMN1P2FRZ7BKZSCO>
2. Mertens M, Schmidt K, Ozkul A, Groschup MH. The impact of Crimean-Congo hemorrhagic fever virus on public health. *Antiviral Res*. 2013;98:248–60. <http://dx.doi.org/10.1016/j.antiviral.2013.02.007>
3. Mustafa ML, Ayazi E, Mohareb E, Yingst S, Zayed A, Rossi CA, et al. Crimean-Congo hemorrhagic fever, Afghanistan, 2009. *Emerg Infect Dis*. 2011;17:1940–1. <http://dx.doi.org/10.3201/eid1710.110061>
4. Niazi A-u-R. Clinical epidemiology of Crimean-Congo hemorrhagic fever in west region of Afghanistan. Herat (Afghanistan): Herat University Press; 2017.
5. World Health Organization. Communicable disease profile. Afghanistan and neighboring countries. January 2002 [cited 2012 Apr 17]. [https://www.who.int/diseasecontrol\\_emergencies/toolkits/Afghanistan\\_profile.pdf](https://www.who.int/diseasecontrol_emergencies/toolkits/Afghanistan_profile.pdf)
6. Hui P, Cook DJ, Lim W, Fraser GA, Arnold DM. The frequency and clinical significance of thrombocytopenia complicating critical illness: a systematic review. *Chest*. 2011;139:271–8. <http://dx.doi.org/10.1378/chest.10-2243>
7. Swanepoel R, Gill DE, Shepherd AJ, Leman PA, Mynhardt JH, Harvey S. The clinical pathology of Crimean-Congo hemorrhagic fever. *Rev Infect Dis*. 1989;11(Suppl 4):S794–800. [http://dx.doi.org/10.1093/clinids/11.Supplement\\_4.S794](http://dx.doi.org/10.1093/clinids/11.Supplement_4.S794)
8. Tezer H, Polat M. Diagnosis of Crimean-Congo hemorrhagic fever. *Expert Rev Anti Infect Ther*. 2015;13:555–66. <http://dx.doi.org/10.1586/14787210.2015.1021782>
9. Bastug A, Kayaaslan B, Kazancioglu S, Aslaner H, But A, Akinici E, et al. Crimean-Congo hemorrhagic fever: prognostic factors and the association of leukocyte counts with mortality. *Jpn J Infect Dis*. 2016;69:51–5. <http://dx.doi.org/10.7883/yoken.JJID.2014.566>
10. Chamberlain J, Atkinson B, Logue CH, Latham J, Newman ENC, Hewson R. Genome sequence of ex-Afghanistan Crimean-Congo hemorrhagic fever virus SCT strain, from an imported United Kingdom case in October 2012. *Genome Announc*. 2013;1:e00161–13. <http://dx.doi.org/10.1128/genomeA.00161-13>

Address for correspondence: David T. Williams, CSIRO, Australian Animal Health Laboratory, 5 Portarlington Rd, Geelong, VIC 3220, Australia; email: d.williams@csiro.au

## Prolonged Zika Virus RNA Detection in Semen of Immunosuppressed Patient

Christina Petridou, David Bonsall, Aleem Ahmed, Mark Roberts, Carolyn Bell, Mariateresa de Cesare, Rory Bowden, Victoria Graham, Daniel Bailey, Andrew Simpson, Emma Aarons

Author affiliations: Rare and Imported Pathogens Laboratory, Public Health England Porton, Salisbury, UK (C. Petridou, V. Graham, D. Bailey, A. Simpson, E. Aarons); University of Oxford, Oxford, UK (D. Bonsall, M. de Cesare, R. Bowden); Leicester Royal Infirmary, Leicester, UK (A. Ahmed); Worcestershire Royal Hospital, Worcester, UK (M. Roberts); South Warwickshire National Health System Foundation Trust, Warwick, UK (C. Bell)

DOI: <https://doi.org/10.3201/eid2508.181543>

Zika virus RNA has been detected in semen samples collected  $\leq 370$  days after symptom onset. We report unusual persistence of Zika virus RNA in semen, confirmed by sequencing at 515 days after symptom onset and detectable for  $>900$  days, in a patient with immunosuppression.

Detection of Zika virus RNA in semen was described previously in an immunocompetent man 370 days after symptom onset; envelope and precursor of M protein gene sequencing indicated high genetic stability in semen 3–4 months after symptom onset (*1*). We report detection of Zika virus RNA in semen over a longer period in a 43-year-old immunosuppressed man in the United Kingdom.

The patient has multicentric reticulohistiocytosis (MRH), a rare rheumatologic condition, which was diagnosed in 2015. When MRH was diagnosed, the patient had multiple pruritic, firm papules and nodules on his face and neck. He also had lesions with a characteristic coral bead appearance at periungual sites. In addition, he had severe joint pain and stiffness affecting his hands and knees and drenching sweats. His MRH diagnosis was confirmed by testing of a punch biopsy of a lesion. He was HIV negative, and his immunoglobulin levels and immunoglobulin electrophoresis results were normal. He was initially treated with topical steroids and antihistamines, but he only had limited relief. He was prescribed oral steroids and required high doses to control his symptoms. Clinicians added methotrexate and hydroxychloroquine to his medications as steroid-sparing agents and to reduce the chance his MRH would progress to erosive disease.

Sign up for **Twitter** and find the latest information about **emerging infectious diseases** from the EID journal.

 @CDC\_EIDjournal

**Table.** Serial Zika virus genome sequence and culture results from semen of a patient with immunosuppression, United Kingdom\*

Sample no.	Days after symptom onset	RT-PCR C <sub>t</sub> value†	Sequence coverage, %‡	Average read depth	Sequencing platform§	Mutations detected	Culture result
1	13	19	99.9 (min depth 2), 88.4 (min depth 40)	386.9	MinION	Reference	Frozen sample: unsuccessful
2	46	26	ND		NA	NA	Fresh sample: unsuccessful
3	167	Subthreshold	ND		NA	NA	ND
4	194	No RNA detected¶	ND		NA	NA	ND
5	241	31	Unsuccessful		NA	NA	ND
6	257	34	44 (min depth 2), 0 (min depth 40)	3.3	MinION	None	Frozen sample: unsuccessful
7	278	No RNA detected¶	ND		NA	NA	ND
8	326	26	76 (min depth 2), 6 (min depth 40)	13.2	MinION	None	Fresh sample: unsuccessful
9	396	29	ND		NA	NA	ND
10	515	24	98.1 (min depth 5)	33.3	MiSeq	K3272E, Syn2921	Fresh sample: unsuccessful
11	687	39	ND		NA	NA	ND
12	941	32	ND		NA	NA	ND

\*C<sub>t</sub>, cycle threshold; min, minimum; NA, not applicable; ND, not done; RT-PCR, reverse transcription PCR.

†Before PCR, nucleic acid was extracted from samples 1–7 using the EZ1 Virus Mini Kit (QIAGEN, <https://www.qiagen.com>). Samples 8–12 were extracted using the MagNA Pure 96 DNA and Viral NA Small Volume Kit (LifeScience-Roche Diagnostics Corporation, <https://lifescience.roche.com>). C<sub>t</sub> values <40 with acceptable amplification curves are interpreted as positive, but results for samples with C<sub>t</sub> values >35 are confirmed by reextraction and repeat PCR in triplicate, where possible.

‡Conservative read-depth thresholds were selected for comparative analyses of the day 13 (sample 1) and day 515 (sample 10) consensus genomes.

§MinION (Oxford Nanopore Technologies, <https://nanoporetech.com>); MiSeq (Illumina, <https://www.illumina.com>).

¶Confirmed on reextraction and repeat PCR testing.

In April 2016, seven months after starting his disease-modifying antirheumatic drugs, the patient experienced fever and a new widespread maculopapular rash. He had returned to the United Kingdom from Brazil 7 days before. We detected Zika virus RNA in plasma taken 1 day after symptom onset by using real-time reverse transcription PCR methods described by Pyke et al. (2), with modifications (Appendix, <http://wwwnc.cdc.gov/EID/article/25/8/18-1543-App1.pdf>). We did not detect Zika virus nonstructural protein 1-specific antibodies by ELISA (EUROIMMUN, <https://www.euroimmun.com>) in initial samples, but we noted seroconversion on day 13 (Appendix Figure). After diagnosing Zika virus infection, clinicians stopped the patient's methotrexate and hydroxychloroquine, but he remained on prednisolone to prevent a flare-up of his MRH (Appendix Figure). The patient's clinical course of Zika virus infection was unremarkable.

A previous study reported that Zika virus RNA was detected in several semen samples taken within 6 months of symptom onset (3). We tested subsequent semen samples from this patient and found Zika virus RNA persisted at a viral load sufficient for sequencing 515 days after symptom onset (Table; Appendix Figure). To date, Zika virus RNA remains detectable in further semen samples, although at higher cycle threshold values (Table). The patient remains asymptomatic for Zika virus infection despite persistent detection of Zika virus RNA in his semen.

We attempted viral culture on multiple semen samples, as previously described (3), but were unsuccessful (Table). We constructed sequencing libraries from total seminal plasma-extracted RNA enriched by using a panel of oligonucleotide probes, 120 nt in length, designed to capture all known Asian Zika virus strains, according to previously described methods (4). We prepared libraries for previously collected semen samples from before day 326 and sequenced these using MinION (Oxford Nanopore Technologies, <https://nanoporetech.com>). We did the same for the day 515 sample and sequenced it using MiSeq (Illumina, <https://www.illumina.com>). We used double indexing to prevent cross-contamination and index misassignment errors.

We also prepared 90 plasma samples from patients infected with hepatitis C, collected for a separate study, in parallel with the day 515 sample. We did this to exclude the possibility of cross-contamination from our patient's previous samples, particularly the day 13 sample, which were shipped, prepared, and sequenced 6 months earlier. We did not detect Zika virus in any of the hepatitis C samples. We found no evidence of cross-contamination with Zika virus sequences during processing that could explain the near-whole genomes detected in the day 515 sample. Consensus sequences were consistent with all samples having come from the same patient with only 2 mutations, 1 synonymous change at codon 2921 and a K3272E substitution, acquired during the 502 days between the first and last samples sequenced (Table). We deposited sequence data in GenBank (accession nos. MH763832–3).

Counotte et al. systematically reviewed all available evidence on the risk for sexual transmission of Zika virus (5). Data from case reports, case series, cohort studies, in vitro work, and animal studies indicate that the infectious period for sexual transmission of Zika virus is considerably shorter than the period during which viral RNA can be detected in semen. As a result, the World Health Organization now recommends male travelers with potential Zika virus exposure delay conception for  $\geq 3$  months rather than  $\geq 6$  months (6).

In our case, Zika virus RNA might have persisted in semen because of failed immune clearance secondary to the patient's MRH or his immunosuppressive drug treatment. However, when advising returning male travelers in couples planning pregnancy, clinicians should be aware that Zika virus RNA shedding in semen might be intermittent and persist for longer in patients with immunosuppression.

### Acknowledgments

We thank Tim Brooks, Steve Pullen, Azim Ansari, Megan MacDiarmid, and Paul Klenerman for their valuable contributions.

### About the Author

Dr. Petridou is an infectious diseases registrar working at the Rare and Imported Pathogens Laboratory at Porton Down, Salisbury, United Kingdom. Her research interest is in Zika virus infection and she previously worked as the Zika virus registrar at Porton Down.

### References

1. Barzon L, Percivalle E, Pacenti M, Rovida F, Zavattoni M, Del Bravo P, et al. Virus and antibody dynamics in travelers with acute Zika virus infection. *Clin Infect Dis*. 2018;66:1173–80. <http://dx.doi.org/10.1093/cid/cix967>
2. Pyke AT, Daly MT, Cameron JN, Moore PR, Taylor CT, Hewitson GR, et al. Imported Zika virus infection from the Cook Islands into Australia, 2014. *PLoS Curr*. 2014;6:1–7. <http://dx.doi.org/10.1371/currents.outbreaks.4635a54dbfba2156fb2fd76dc49f65e>
3. Atkinson B, Thorburn F, Petridou C, Bailey D, Hewson R, Simpson AJ, et al. Presence and persistence of Zika virus RNA in semen, United Kingdom, 2016. *Emerg Infect Dis*. 2017;23:611–5. <http://dx.doi.org/10.3201/eid2304.161692>
4. Theze J, Li T, du Plessis L, Bouquet J, Kraemer MUG, Somasekar S et al. Genomic epidemiology reconstructs the introduction and spread of Zika virus in Central America and Mexico. *Cell Host Microbe*. 2018; 23:855–64. 1. 2. 3. 4. <http://dx.doi.org/10.1016/j.chom.2018.04.017>
5. Counotte MJ, Kim CR, Wang J, Bernstein K, Deal CD, Broutet NJN, et al. Sexual transmission of Zika virus and other flaviviruses: a living systematic review. *PLoS Med*. 2018; 15:e1002611. <http://dx.doi.org/10.1371/journal.pmed.1002611>
6. World Health Organization. WHO guidelines for the prevention of sexual transmission of Zika virus: executive summary. Geneva: The Organization; 2019. <https://www.who.int/reproductivehealth/zika/en>

Address for correspondence: Christina Petridou or Emma Aarons, Rare and Imported Pathogens Laboratory, Public Health England Porton, Salisbury, UK; email: christina.petridou@nhs.net or emma.aarons@phe.gov.uk

## No Evidence for Role of Cutavirus in Malignant Melanoma

Ulrike Wieland, Steffi Silling, Martin Hufbauer, Cornelia Mauch, Paola Zigrino, Frank Oellig, Alexander Kreuter, Baki Akgül

Author affiliations: University of Cologne, Cologne, Germany (U. Wieland, S. Silling, M. Hufbauer, C. Mauch, P. Zigrino, B. Akgül); Institute of Pathology, Mülheim an der Ruhr, Germany (F. Oellig); Helios St. Elisabeth Hospital Oberhausen, University Witten/Herdecke, Witten, Germany (A. Kreuter)

DOI: <https://doi.org/10.3201/eid2508.190096>

Cutavirus was previously found in cutaneous melanoma. We detected cutavirus DNA in only 2/185 melanoma biopsies and in 0/52 melanoma metastases from patients in Germany. Viral DNA was localized in the upper epidermal layers. Swab specimens from healthy skin were cutavirus positive for 3.8% (9/237) of immunocompetent and 17.1% (35/205) of HIV-positive men.

Cutavirus, a novel human protoparvovirus with linear single-stranded DNA, has been detected in fecal samples from children with diarrhea and in cutaneous T-cell lymphomas (CTCL) (1,2). Recently, Møllerup et al. reported the identification of cutavirus in 1 of 10 cutaneous malignant melanomas using viral enrichment methods with high-throughput sequencing and real-time PCR (3). This discovery raised questions concerning tropism and pathogenicity of cutavirus in human skin. We performed a retrospective study to determine cutavirus DNA prevalence and viral load in a large collection of formalin-fixed paraffin-embedded tissue biopsy specimens of malignant melanomas and in forehead swabs of healthy skin of immunocompetent and HIV-positive persons in Germany.

We used 185 cutaneous malignant melanoma biopsy specimens from 179 patients and 52 melanoma metastases from 42 patients from Germany for analyses with cutavirus real-time PCR (Appendix, <http://wwwnc.cdc.gov/EID/article/25/8/19-0096-Appl.pdf>). We detected cutavirus DNA only in 2 nodular malignant melanomas, located on the abdomen of a 64-year-old man (MM-A) and on the cheek of an 85-year-old woman (MM-B). Viral DNA loads in these biopsies were 0.3 (MM-A) and 2.8 (MM-B) cutavirus DNA copies per  $\beta$ -globin gene copy. None of the 52 analyzed metastases carried cutavirus DNA (Table). The cutavirus PCR results of the 2 melanomas could be confirmed by sequencing and by in situ hybridization. In both melanomas, the cutavirus DNA-specific signals could be

# Prolonged Zika Virus RNA Detection in Semen of Immunosuppressed Patient

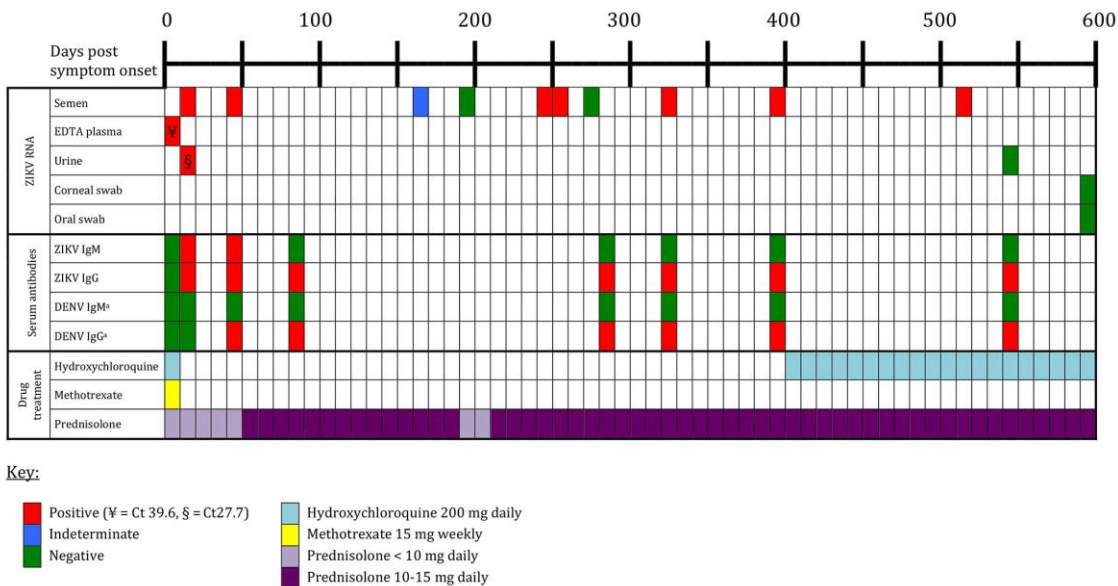
## Appendix

### Modifications to real-time reverse transcription PCR methods for detecting Zika virus RNA

We used real-time reverse transcription PCR methods described by Pyke et al. (1) with the following modifications: we incorporated MS2 as an internal control; made slight changes to the forward primer and added a second probe to better cover African strains; and we replaced of the 3' TAMRA dye on the probes with BHQ1.

### Reference

1. Pyke AT, Daly MT, Cameron JN, Moore PR, Taylor CT, Hewitson GR, et al. Imported Zika virus infection from the Cook Islands into Australia, 2014. PLoS Curr. 2014;6:1–7.



**Appendix Figure.** Clinical case timeline of PCR and serology investigations, and drug treatment for patient with immunosuppression and prolonged presence of Zika virus RNA in his semen.