

8. Wang F, Lin J, Chang J, Cao Y, Qin S, Wu J, et al. Isolation, complete genome sequencing, and phylogenetic analysis of the first Chuzan virus in China. *Virus Genes*. 2016;52:138–41. <http://dx.doi.org/10.1007/s11262-015-1282-x>
9. Yang H, Xiao L, Meng J, Xiong H, Gao L, Liao D, et al. Complete genome sequence of a Chuzan virus strain isolated for the first time in mainland China. *Arch Virol*. 2016;161:1073–7. <http://dx.doi.org/10.1007/s00705-015-2734-2>
10. Ma J-G, Zhang X-X, Zheng W-B, Xu Y-T, Zhu X-Q, Hu G-X, et al. Seroprevalence and risk factors of bluetongue virus infection in Tibetan sheep and yaks in Tibetan Plateau, China. *Biomed Res Int*. 2017;2017:5139703.

Address for correspondence: Qiaoying Zeng, Gansu Agricultural University, The College of Veterinary Medicine, Lanzhou, China; email: zengqy@gsau.edu.cn

Conservation of White Rhinoceroses Threatened by Bovine Tuberculosis, South Africa, 2016–2017

Michele A. Miller,¹ Peter Buss,¹ Sven D.C. Parsons, Eduard Roos, Josephine Chileshe, Wynand J. Goosen, Louis van Schalkwyk, Lin-Mari de Klerk-Lorist, Markus Hofmeyr,² Guy Hausler, Leana Rossouw, Tebogo Manamela, Emily P. Mitchell,³ Rob Warren, Paul van Helden

Author affiliations: Stellenbosch University, Department of Science and Technology–National Research Foundation Centre of Excellence for Biomedical Tuberculosis Research, South African Medical Research Council Centre for Tuberculosis Research, Cape Town, South Africa (M.A. Miller, S.D.C. Parsons, E. Roos, J. Chileshe, W.J. Goosen, G. Hausler, R. Warren, P. van Helden); South African National Parks, Skukuza, South Africa (P. Buss, M. Hofmeyr, L. Rossouw, T. Manamela); Office of the State Veterinarian, Skukuza (L. van Schalkwyk, L.-M. de Klerk-Lorist); National Zoological Gardens of South Africa, Pretoria, South Africa (E.P. Mitchell)

DOI: <https://doi.org/10.3201/eid2412.180293>

¹These first authors contributed equally to this article.

²Current affiliation: Great Plains Conservation, Maun, Botswana.

³Current affiliation: University of Pretoria, Pretoria, South Africa.

During 2016–2017, when Kruger National Park, South Africa, was under quarantine to limit bovine tuberculosis spread, we examined 35 white and 5 black rhinoceroses for infection. We found 6 infected white rhinoceroses during times of nutritional stress. Further research on *Mycobacterium bovis* pathogenesis in white rhinoceroses is needed.

Tuberculosis (TB) caused by *Mycobacterium tuberculosis* or *M. bovis* has been reported in captive rhinoceroses since the early 1800s (1–3). Bovine TB is endemic in many wildlife populations worldwide, including among those in Kruger National Park (KNP), South Africa (4). KNP contains the largest free-living population of white rhinoceroses in the world (estimated at 6,649–7,830). However, prolonged drought in South Africa (2015–2017) raised concerns that starvation and disease could increase the mortality rate and affect conservation efforts for this species (5).

In June 2016, a black rhinoceros (*Diceros bicornis minor*) with an *M. bovis* infection was discovered (6). Thereafter, a surveillance program was initiated to screen rhinoceros carcasses in KNP, leading to 35 white and 5 black rhinoceros carcasses being examined during June 2016–October 2017. To determine which animals were infected, we conducted macroscopic examinations and collected samples for histopathologic studies and mycobacterial culture, as previously described (7). Research protocols were approved by the South African National Park Animal Use and Care Committee and ethics committee of Stellenbosch University.

No additional cases of *M. bovis* infection were found in black rhinoceroses. However, we confirmed *M. bovis* infection in 6 white rhinoceroses (Table). Grossly visible lesions, mostly found in the retropharyngeal or tracheobronchial lymph nodes or lung, were typically small and localized and could easily be missed or mistaken for granulomas caused by other pathogens if careful dissections of tissues were not performed (online Technical Appendix, <https://wwwnc.cdc.gov/EID/article/24/12/18-0293-Techapp1.pdf>). On histologic examination, we found granulomatous inflammation in lung or lymph node sections and rare acid-fast organisms in some granulomas (Table). We typed these *M. bovis* isolates as strain SB0121, the most common strain found in KNP (8).

Four of the infected animals were found during September–November 2016, near the end of the drought, and the remaining 2 animals were found in September and October 2017, at the end of the next winter. The timing of infections suggests that animals under nutritional stress might be more susceptible to infection, similar to observations in other species (9). The low number of positive cases and localized paucibacillary lesions support the hypothesis that white rhinoceroses, although susceptible to infection,

Table. Findings from 6 *Mycobacterium bovis*-infected white rhinoceroses, Kruger National Park, South Africa, 2016–2017*

Case no.	Age category	Sex	Date	Body condition	Features of lesions consistent with bovine TB†			<i>M. bovis</i> culture-positive tissue pools†	AFB on cytology of lesions†
					Macroscopic, multifocal mineralized granulomas	Multifocal granulomas on histology	AFB on histology		
1	Subadult	M	Sep 2016	Thin	+ Lung and retropharyngeal LN	+ Lung and retropharyngeal LN	–	Head, thoracic, and peripheral LNs and lung	+ LNs
2	Adult	F	Sep 2016	Thin	– Lung and all LNs	ND‡	ND‡	Thoracic LN and lung	ND‡
3	Adult	M	Oct 2016	Thin	+ Lung; – all LNs	+ Lung; – LNs	–	Thoracic and abdominal LNs and lung	+ Lung
4	Subadult	F	Nov 2016	Thin	– Lung; + submandibular, retropharyngeal, tracheobronchial, and mesenteric LNs	– Lung; + submandibular, retropharyngeal, tracheobronchial, and mesenteric LNs	Rare	Head and thoracic LNs	+ LNs
5	Subadult	F	Sep 2017	Normal	+ Lung and prescapular and axillary LNs	ND	ND	Thoracic LN	+ Lung
6	Adult	M	Oct 2017	Thin	+ Lung and prescapular, retropharyngeal, and tracheobronchial LNs	ND	ND	Tracheobronchial, prescapular, and retropharyngeal LNs and lung	+ Lung and LNs

*AFB, acid-fast bacilli; LN, lymph node; ND, not done; TB, tuberculosis; + feature present; – feature absent.

†LNs were pooled into 4 sets: head (retropharyngeal, submandibular, and cervical); thoracic (tracheobronchial and mediastinal); abdominal (mesenteric and hepatic); and peripheral (axillary, prescapular, and inguinal) LNs.

‡No clinically significant lesions other than inflammation (poaching case).

are able to limit disease progression (10). However, whether infected animals would develop disease if compromised is unknown. Location of lesions yielding positive cultures suggests an aerosol route of exposure, although *M. bovis* was also isolated from mesenteric and peripheral lymph nodes (Table). Although no data were available to evaluate transmission, a previous study has shown white rhinoceroses with localized *M. bovis* infection did not regularly shed bacilli (10). Further research is required to understand the pathogenesis and epidemiology of *M. bovis* infection in these animals.

Fresh samples from animals that die naturally are difficult to locate in a large ecosystem, especially before predators arrive at the carcass or decomposition occurs due to elevated temperatures. In our study, collection of samples with minimal degradation was facilitated by our examining only rhinoceroses dead for <12 hours and animals euthanized because of their severe state of debilitation, most often from poaching wounds. Bovine TB was not considered the cause of the poor condition or death in any of these animals. We found small, nonspecific culture-positive lesions histologically similar to those caused by helminths, foreign material, and fungi, and the paucibacillary nature of the infection could result in false-negative histopathologic results. Therefore, we needed to confirm infection by mycobacterial culture and species determination with every tissue set collected. However, low numbers of viable bacteria, sample handling, and the likelihood of overgrowth by contaminants could also lead to false-negative culture results. Positive culture results from >1 tissue sample in the same rhinoceros suggests infection rather than

contamination. However, no cases of disseminated bovine TB have been observed in this species, supporting the authors' hypothesis that the disease in white rhinoceroses is self-limiting. Factors such as drought might play a role in altering susceptibility to infection, considering no positive culture results were obtained in >20 rhinoceros carcasses examined before June 2016.

Although disease and death associated with bovine TB have not been observed in white rhinoceroses, *M. bovis* infection nonetheless presents a threat to conservation of this species. Genetic management and translocation of rhinoceroses are essential components of in situ conservation; animals need to be moved from high-risk poaching areas to more secure locations (5). In addition, calves orphaned by poaching require intensive specialized care, which is only available outside KNP (5). Because *M. bovis* is a controlled disease, premises with infected populations are placed under quarantine to prevent translocation of potentially infected animals. With a paucity of data to assess risks, movement restrictions are a substantial impediment to conservation and can threaten the survival of this population. Therefore, research into antemortem detection, pathogenesis, and epidemiology of *M. bovis* infection is essential for programs to conserve rhinoceroses of Africa.

Acknowledgments

We thank the staffs of the South African National Parks, State Veterinary Services of KNP, National Zoological Gardens of South Africa, and Faculty of Veterinary Science, University of Pretoria, for providing assistance with these cases.

This study was supported by South African National Parks, National Research Foundation South African Research Chair Initiative in Animal Tuberculosis (grant no. 86949), the Department of Science and Technology–National Research Foundation Centre of Excellence for Biomedical Tuberculosis Research, and the South African Medical Research Council.

About the Author

Prof. Miller is the South African Research Chair in Animal TB at the Department of Science and Technology–National Research Foundation Centre of Excellence for Biomedical TB Research, and a member of the South African Medical Research Council, Centre for Tuberculosis Research, at Stellenbosch University, Cape Town, South Africa. Her research interests include infectious diseases that threaten animal conservation.

References

1. Miller M, Michel A, van Helden P, Buss P. Tuberculosis in rhinoceros: an underrecognized threat? *Transbound Emerg Dis*. 2017;64:1071–8. <http://dx.doi.org/10.1111/tbed.12489>
2. Stetter MD, Mikota SK, Gutter AF, Monterroso ER, Dalovisio JR, Degraw C, et al. Epizootic of *Mycobacterium bovis* in a zoologic park. *J Am Vet Med Assoc*. 1995;207:1618–21.
3. Espie IW, Hlokwé TM, Gey van Pittius NC, Lane E, Tordiffe ASW, Michel AL, et al. Pulmonary infection due to *Mycobacterium bovis* in a black rhinoceros (*Diceros bicornis minor*) in South Africa. *J Wildl Dis*. 2009;45:1187–93. <http://dx.doi.org/10.7589/0090-3558-45.4.1187>
4. Hlokwé TM, van Helden P, Michel AL. Evidence of increasing intra and inter-species transmission of *Mycobacterium bovis* in South Africa: are we losing the battle? *Prev Vet Med*. 2014;115:10–7. <http://dx.doi.org/10.1016/j.prevetmed.2014.03.011>
5. Department of Environmental Affairs, Republic of South Africa. Minister Molewa highlights process on integrated strategic management of rhinoceros. 2017 Feb 27 [cited 2018 Aug 14]. https://www.environment.gov.za/mediarelease/molewa_progressionintegrated_strategicmanagement_ofrhinoceros
6. Miller M, Buss P, van Helden P, Parsons S. *Mycobacterium bovis* in a free-ranging black rhinoceros, Kruger National Park, South Africa, 2016. *Emerg Infect Dis*. 2017;23:557–8. <http://dx.doi.org/10.3201/eid2303.161622>
7. Goosen WJ, Miller MA, Chegou NN, Cooper D, Warren RM, van Helden PD, et al. Agreement between assays of cell-mediated immunity utilizing *Mycobacterium bovis*-specific antigens for the diagnosis of tuberculosis in African buffaloes (*Syncerus caffer*). *Vet Immunol Immunopathol*. 2014;160:133–8. <http://dx.doi.org/10.1016/j.vetimm.2014.03.015>
8. Dippenaar A, Parsons SDC, Miller MA, Hlokwé T, Gey van Pittius NC, Adroub SA, et al. Progenitor strain introduction of *Mycobacterium bovis* at the wildlife-livestock interface can lead to clonal expansion of the disease in a single ecosystem. *Infect Genet Evol*. 2017;51:235–8. <http://dx.doi.org/10.1016/j.meegid.2017.04.012>
9. Cegielski JP, McMurray DN. The relationship between malnutrition and tuberculosis: evidence from studies in humans and experimental animals. *Int J Tuberc Lung Dis*. 2004;8:286–98.
10. Michel AL, Lane EP, de Klerk-Lorist L-M, Hofmeyr M, van der Heijden EMDL, Botha L, et al. Experimental *Mycobacterium bovis* infection in three white rhinoceroses (*Ceratotherium simum*): susceptibility, clinical and anatomical pathology. *PLoS One*. 2017;12:e0179943. <http://dx.doi.org/10.1371/journal.pone.0179943>

Address for correspondence: Michele A. Miller, DST-NRF Centre of Excellence for Biomedical TB Research, MRC Centre for Tuberculosis Research, Division of Molecular Biology and Human Genetics, Faculty of Medicine and Health Sciences, Stellenbosch University, PO Box 241, Cape Town 8000, South Africa; email: miller@sun.ac.za

Lung Involvement in Chronic Schistosomiasis with Bladder Squamous Cell Carcinoma

Anastasia Saade, Edith Carton, Audrey Mansuet-Lupo, Romain Jouffroy, Diane Damotte, Hélène Yera, Marie-Pierre Revel, François Goldwasser

Author affiliations: Hôpital Cochin, Paris, France (A. Saade, E. Carton, A. Mansuet-Lupo, D. Damotte, H. Yera, M.-P. Revel, F. Goldwasser); Université Paris Descartes, Paris (A. Saade, R. Jouffroy, M.-P. Revel, F. Goldwasser)

DOI: <https://doi.org/10.3201/eid2412.180355>

We report a case of chronic *Schistosoma haematobium* infection with pseudometastatic pulmonary nodules and high-grade squamous cell carcinoma in a 30-year-old man in Mali. Lung biopsies revealed chronic pulmonary involvement of *S. haematobium* and ruled out lung metastases.

A 30-year-old man from Mali, who had immigrated to France a year before, was hospitalized for acute urinary retention. The patient reported isolated hematuria over the preceding month with recent dysuria. He was afebrile and had normal vital signs. Physical examination revealed pelvic tenderness and guarding. The only biologic abnormality was a hypereosinophilia (1,640 cells/mm³). Unenhanced computed tomography (CT) revealed linear calcifications on the bladder wall, with a large intraluminal mass infiltrating the left ureter (Figure, panel A). Cystoscopy was typical of schistosomiasis. Anatomic pathology revealed urinary schistosomiasis complicated by a high-grade, well-differentiated, keratinized squamous cell carcinoma (SCC) (Figure, panel B). Within the wall, ovoid structures, sometimes calcified,

Conservation of White Rhinoceroses Threatened by Bovine Tuberculosis, South Africa, 2016–2017

Technical Appendix

Heparinized whole blood collected before death was used to assess interferon γ (IFN- γ) release in response to mycobacteria-specific antigenic peptides by using a modified QuantiFERON TB Gold (In-Tube) (QIAGEN, Venlo, Limburg, the Netherlands) assay as previously described (1,2). The commercial Bovine IFN- γ ELISA development kit (Mabtech AB, Nacka Strand, Sweden), which is cross-reactive with IFN- γ of sheep and horses, was used in combination with a bovine recombinant IFN- γ standard curve to measure rhinoceros IFN- γ . Rhinoceros IFN- γ has been previously detected in white rhinoceroses experimentally infected with *Mycobacterium bovis* (2), and a cutoff value of 36 pg/mL was determined by using QuantiFERON-TB–stimulated whole blood from uninfected white rhinoceroses (M.A. Miller, unpub. data). Five rhinoceroses had detectable antigen-specific IFN- γ responses of 5, 20, 24, 75, and 125 pg/mL, which suggests immune sensitization to *M. tuberculosis* complex in at least 2 animals (those with the higher IFN- γ values). The low level of immune sensitization supports the hypothesis that white rhinoceroses have limited infections with *M. bovis* (1).

Detailed macroscopic examinations were conducted with lung and numerous lymph nodes: head (submandibular, retropharyngeal, and cervical); thoracic (tracheobronchial and mediastinal); abdominal (mesenteric and hepatic); and peripheral (prescapular, axillary, and inguinal). Representative samples were frozen for mycobacterial culture and preserved in 10% buffered formalin for histopathology. Tissues were processed and inoculated for culture by using the BACTEC MGIT Mycobacterial Growth Indicator Tube system (Becton Dickinson, Franklin Lakes, NJ, USA), as previously described (2). For all positive cultures, the species was determined by PCR of regions of difference (3) and spoligotyping (4).

Gross lesions were typically localized and varied from consolidated tissue and single pinpoint lesions to multifocal, small, mineralized granulomas (Technical Appendix Figures 1, 2). The location of lesions and the tissues that were culture positive for *M. bovis* in each

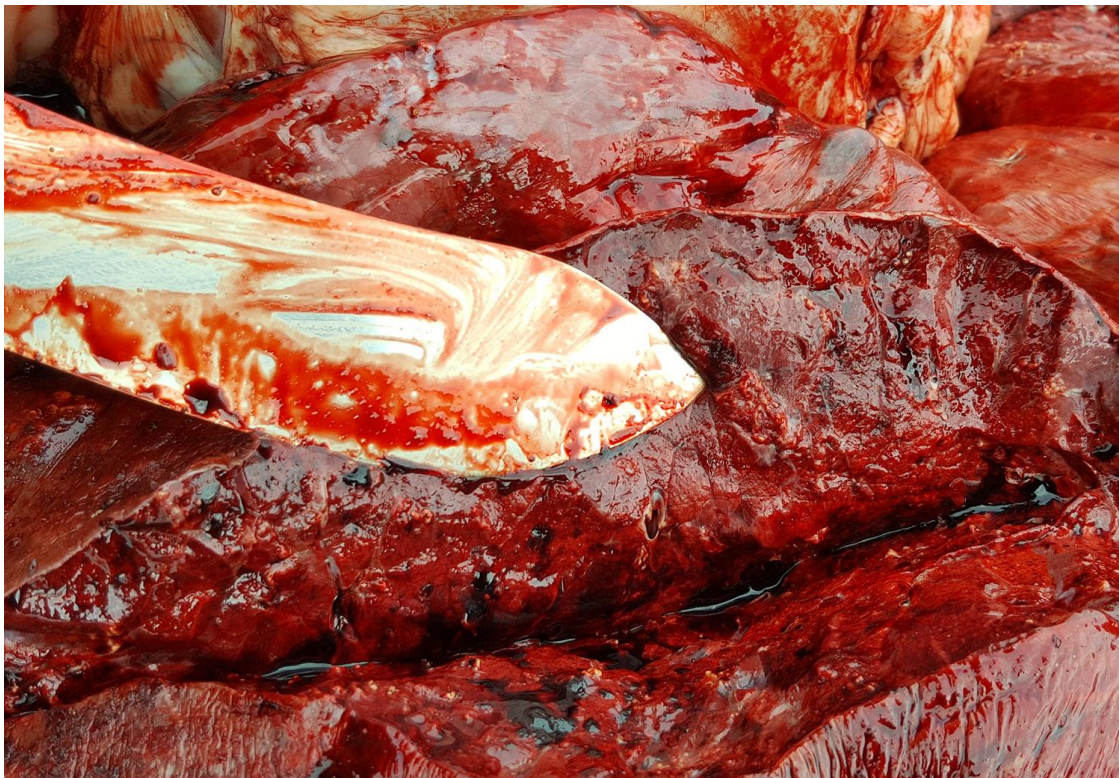
animal are shown in main text Table. All 6 white rhinoceroses had *M. bovis* isolated from thoracic (tracheobronchial, mediastinal, or both) lymph node tissue cultures, and 4 animals had positive cultures from lung tissue, suggesting inhalation as the route of exposure (main text Table). Culture results were concordant with the histologic presence of acid-fast organisms in only 1 animal (out of 3 with histologic granulomas), although cytologic evaluation revealed acid-fast organisms in all 5 rhinoceroses in which direct lesion smears were performed.

Histopathologic findings in 3 of 4 cases examined included the following. In case 1, moderate multifocal chronic granulomatous lymphadenitis was present in the retropharyngeal lymph nodes, characterized by large discrete foci of mineralized necrotic tissue surrounded by a thin layer of macrophages, epithelioid cells, and rare multinucleate giant cells, which were encapsulated by a thick layer of fibrous connective tissue containing small-to-moderate numbers of lymphocytes and plasma cells. This rhinoceros also had mild, multifocal chronic granulomatous pneumonia with an appearance similar to lymph nodes, as well as some fibrous foci and foci with nonmineralized necrotic debris. In case 3, the lungs contained multiple small granulomas ranging from encapsulated lymphoplasmacytic and histiocytic inflammation surrounding necrotic foci to discrete fibrous foci of mineralized necrotic tissue, minimal inflammation, and discrete fibrous foci with no associated inflammation or mineralization. Case 4 had the most substantial microscopic changes of the 3 cases. We found severe multifocal chronic necrogranulomatous lymphadenitis characterized by multiple pale-tan, discrete, and coalescing foci in several lymph nodes (<7 x 5 mm) consisting of foci of variably mineralized lytic necrotic tissue debris, surrounded by thin layers of macrophages, multinucleate giant cells, and epithelioid cells and a variability thick capsule of immature fibrous connective tissue.

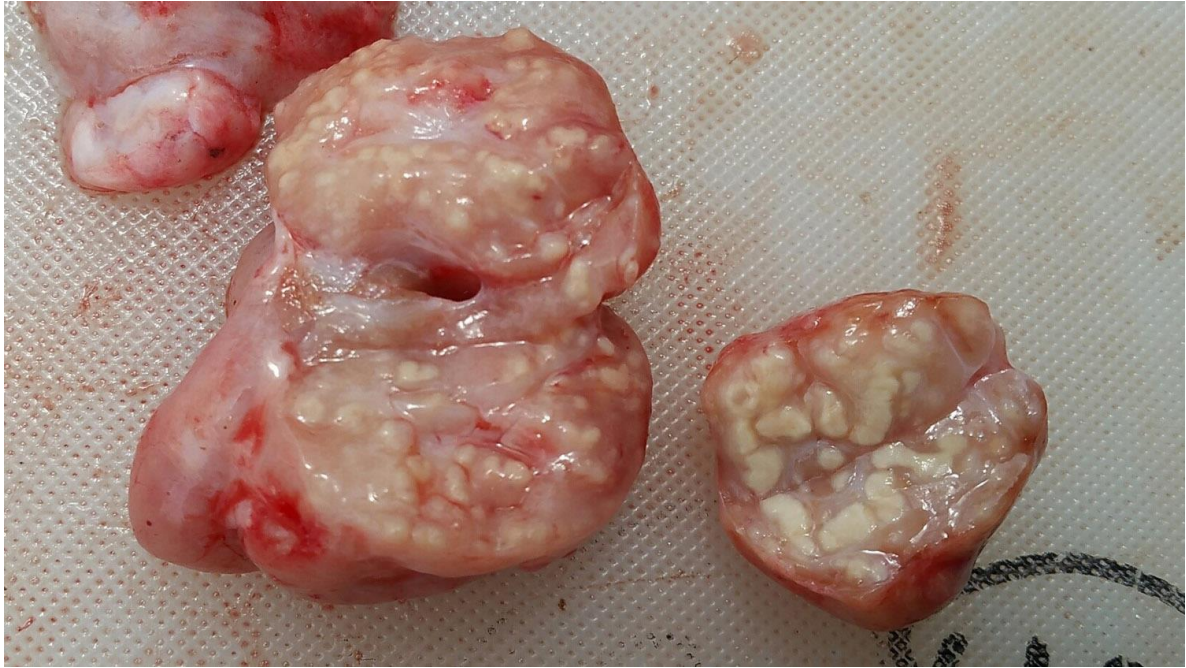References

1. Michel AL, Lane EP, de Klerk-Lorist L-M, Hofmeyr M, van der Heijden EMDL, Botha L, et al. Experimental *Mycobacterium bovis* infection in three white rhinoceroses (*Ceratotherium simum*): Susceptibility, clinical and anatomical pathology. PLoS One. 2017;12:e0179943. [PubMed http://dx.doi.org/10.1371/journal.pone.0179943](http://dx.doi.org/10.1371/journal.pone.0179943)
2. Parsons SDC, Morar-Leather D, Buss P, Hofmeyr J, McFadyen R, Rutten VPMG, et al. The kinetics of the humoral and interferon-gamma immune responses to experimental *Mycobacterium bovis* infection in the white rhinoceros (*Ceratotherium simum*). Front Immunol. 2017;8:1831. [PubMed http://dx.doi.org/10.3389/fimmu.2017.01831](http://dx.doi.org/10.3389/fimmu.2017.01831)

3. Goosen WJ, Miller MA, Chegou NN, Cooper D, Warren RM, van Helden PD, et al. Agreement between assays of cell-mediated immunity utilizing *Mycobacterium bovis*-specific antigens for the diagnosis of tuberculosis in African buffaloes (*Syncerus caffer*). *Vet Immunol Immunopathol.* 2014;160:133–8. [PubMed http://dx.doi.org/10.1016/j.vetimm.2014.03.015](http://dx.doi.org/10.1016/j.vetimm.2014.03.015)
4. Warren RM, Gey van Pittius NC, Barnard M, Hesseling A, Engelke E, de Kock M, et al. Differentiation of *Mycobacterium tuberculosis* complex by PCR amplification of genomic regions of difference. *Int J Tuberc Lung Dis.* 2006;10:818–22. [PubMed](#)
5. Kamerbeek J, Schouls L, Kolk A, van Agterveld M, van Soolingen D, Kuijper S, et al. Simultaneous detection and strain differentiation of *Mycobacterium tuberculosis* for diagnosis and epidemiology. *J Clin Microbiol.* 1997;35:907–14. [PubMed](#)



Technical Appendix Figure 1. Area of consolidation in white rhinoceros lung tissue showing a nonspecific lesion from which *Mycobacterium bovis* was isolated.



Technical Appendix Figure 2. Multifocal granulomas in the retropharyngeal lymph node of a white rhinoceros with confirmed *Mycobacterium bovis* infection.