

Borrelia miyamotoi–Associated Neuroborreliosis in Immunocompromised Person

Katharina Boden, Sabine Lobenstein,
Beate Hermann, Gabriele Margos, Volker Fingerle

Borrelia miyamotoi is a newly recognized human pathogen in the relapsing fever group of spirochetes. We investigated a case of *B. miyamotoi* infection of the central nervous system resembling *B. burgdorferi*–induced Lyme neuroborreliosis and determined that this emergent agent of central nervous system infection can be diagnosed with existing methods.

The tickborne relapsing fever spirochete *Borrelia miyamotoi* was described in 1994 but only recently was recognized as a human pathogen (1). This spirochete is present in *Ixodes* ticks across the Northern Hemisphere, comparable to the distribution of *B. burgdorferi* sensu lato, but reported cases are still rare (2,3). Thus far, only 2 cases of central nervous system infection have been reported, both with a chronic course and both in immunocompromised persons (4,5). We investigated a case of *B. miyamotoi* infection that was initially diagnosed as seronegative early Lyme neuroborreliosis (LNB) that could be attributed to *B. miyamotoi* only by molecular–biological methods.

The Case

On July 31, 2015, a 74-year-old woman with a history of non-Hodgkin lymphoma (follicular type, stage IV) came to the Burgenlandkreis Hospital (Naumburg, Germany). She reported dizziness, vomiting, and a headache of 5 days' duration. She had been treated for her lymphoma with cyclophosphamide, doxorubicin, vincristine, and prednisone with rituximab during May–August 2012. Thereafter, she received rituximab maintenance therapy (375 mg/m² every 8 weeks) until November 2014. The monoclonal antibody rituximab that targets the CD20 antigen expressed by B cells leads to anti-CD20–mediated B-cell depletion. This treatment, together with the underlying hematologic disease, resulted in an immunocompromised condition. The patient reported 2 tick bites while in

Elsteraue municipality (Saxony-Anhalt, Germany) during June and July 2015 but had no recent travel history. On examination, she had slight neck stiffness but no other notable findings.

A lumbar puncture was performed to assess the patient for viral or lymphomatous meningitis. Cerebrospinal fluid (CSF) showed a pleocytosis of 70 leukocytes/mL (reference 0–5 leukocytes/mL) and elevated protein at 1,718 mg/L (reference 150–400 mg/L); albumin quotient (Qalb) 34.8% (reference <9%), lactate 5.58 mmol/L (1.2–2.1 mmol/L), and glucose quotient 0.45 (>0.5); and an intrathecal IgM synthesis of 18%. The greatly elevated lactate and highly increased Qalb and protein made a viral cause unlikely. Pappenheim staining of a cytopspin preparation of CSF revealed a mixed cell population (32% polymorphonuclear leukocytes, 61% lymphocytes, and 7% monocytes) with heterogeneous morphology of lymphocytes that did not suggest lymphomatous meningitis. Serum and CSF were negative for *B. burgdorferi*–specific antibodies by the chemiluminescent immunoassay LIASON (DiaSorin, Vercelli, Italy). However, because the CSF constellation was typical for LNB, including the slight intrathecal IgM synthesis (6), the patient was treated with 2 intravenous ceftriaxone (2,000 mg 1×/d for 3 wks).

To exclude early tuberculous meningitis, we examined the CSF for mycobacteria by PCR, culture, and staining. To further substantiate the LNB diagnosis, we determined the B-cell attractant chemokine CXCL13 from CSF. The measured value of 1,155 pg/mL was clearly higher than the minimum concentration of 250 pg/mL, indicating neuroborreliosis and thus supporting our working diagnosis of LNB (7). After 5 days of treatment, the patient recovered fully. A second lumbar puncture after 7 days of treatment revealed a stable count of 76 monomorphic lymphocytes/μL. In addition, protein, Qalb, and CXCL13 had decreased (Table). However, we remained unable to detect *B. burgdorferi*–specific antibodies in serum or CSF, and *B. burgdorferi*–specific PCR of the first CSF specimen showed no amplification product.

To conclusively identify the pathogen, we tested the first CSF and serum samples by PCR for panbacterial 16S rRNA, with a positive result from CSF only. Using the BLAST algorithm (<http://blast.ncbi.nlm.nih.gov/Blast.cgi>) in GenBank, we found, to our surprise, that the sequence was identical to that for *B. miyamotoi*. Moreover,

Author affiliations: University Hospital Jena, Jena, Germany (K. Boden, B. Hermann); Burgenlandkreis Hospital Naumburg, Naumburg, Germany (S. Lobenstein); Bavarian Health and Food Safety Authority, Oberschleissheim, Germany (G. Margos, V. Fingerle)

DOI: <http://dx.doi.org/10.3201/eid2208.152034>

Table. CSF findings of *Borrelia miyamotoi* meningitis cases and patients with Lyme neuroborrelioses*

Finding (reference)	Case (reference)			Lyme neuroborreliosis(6)†
	New Jersey, USA (4)	Netherlands (5)	Germany (this study)	
Leukocytes/ μL (0–5 cells/ μL)	65	388	70	170.5 [57.0–369]
Differential count	23% PMNC, 70% lymphocytes, 6% monocytes, 1% diverse	60% mononuclear cells	32% PMNC, 61% lymphocytes, 7% monocytes	
Protein level, mg/dL (150–400 mg/dL)	>300		1718	1,232 [697–1,926]
Qalb, $\times 10^3$ (<9)			34.8	17.2 [9.7–28.4]
Quantitative IgM, $\times 10^3$			18.1	Elevated in 70%
Glucose, mmol/L (2.2–4.2 mmol/L)	1.8	1.6	2.41	
Glucose ratio (>0.5)			0.45	
Lactate, mmol/L (1.2–2.1 mmol/L)			5.58	≥ 3.5 in 4%‡
Routine microscopy		Cellular CSF with high nos. of granulocytes and plasma cells	Cellular CSF with heterogeneous morphology	
CXCL13, pg/mL (100 to <250 pg/mL, borderline)			1,150; 8 d after start of therapy: 186	>415 (7)
Spirochetes visible in CSF by	Gram staining, Giemsa staining	Darkfield microscopy	Acridinorange staining, Pappenheim cytopsin	Typically negative

*Blank cells indicate value not determined or was within reference range. CSF, cerebrospinal fluid; PMNC, polymorphonuclear leukocytes; Qalb, albumin quotient.

†n = 118 patients. Values are median [interquartile range].

‡Associated with headache.

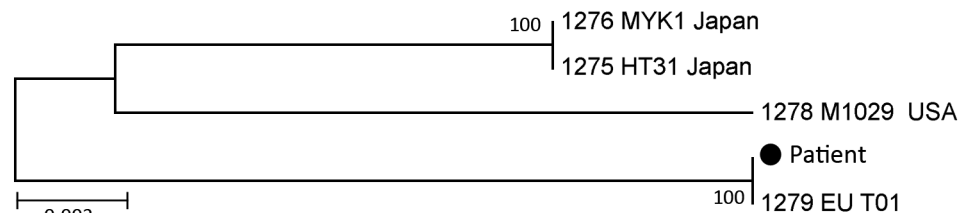
sequences of 16S rRNA, *flaB*, and 6 housekeeping genes revealed the European type of *B. miyamotoi* (Figure 1; details of molecular phylogenetic analysis and GenBank accession numbers in online Technical Appendix, <http://www.wnc.cdc.gov/EID/article/22/9/15-2034-Techapp1.pdf>).

B. miyamotoi is one of the *Borrelia* species that causes relapsing fever. The spirochetes of the relapsing fever *Borrelia* group are more easily detectable than *B. burgdorferi* spirochetes from blood and CSF by microscopy and PCR. We therefore reexamined the first Pappenheim-stained cytopsin preparation from CSF, but no spirochetes were recognizable. To increase the sensitivity, we restained the preparation with acridine orange. A few spirochetes were then microscopically visible in the preparation using an Axioskop (Zeiss, Germany) (Figure 2).

Conclusions

The genus *Borrelia* is divided into 2 groups: *B. burgdorferi* sensu lato, which causes Lyme disease, and a group of species that cause relapsing fever. *B. miyamotoi* belongs to the second group and was first described in 2011 as a human pathogen in several patients from Russia who had an unspecific febrile illness where few patients experienced febrile relapses, which is the typical sign for relapsing fever (1). *B. miyamotoi* was also reported to have caused meningoencephalitis in a patient from New Jersey, USA (4), and a patient from the Netherlands (5). As with the patient we report, these patients had a history of non-Hodgkin lymphoma with recent rituximab treatment. Because of the increasing indications for rituximab treatment (10) and a prevalence of *B. miyamotoi* in *Ixodes ricinus* ticks in

Figure 1. Molecular phylogenetic analysis of *Borrelia* strain from cerebrospinal fluid of a 74-year-old immunocompromised woman in Germany (black dot) conducted by using 6 multilocus sequence typing genes (*clpA*, *clpX*, *pepX*, *pyrG*, *recG*, *rplB*) of *Borrelia miyamotoi*. The



sequences obtained from the patient sample clustered with *B. miyamotoi* strain EU_T01 from Europe, retrieved from the PubMLST *Borrelia* database (<http://pubmlst.org/borrelia/>). The phylogenetic relationship of the sample analyzed was inferred by using DNA sequences of chromosomal housekeeping genes. The maximum-likelihood method based on the general time reversible model (8) was applied. The tree with the highest log likelihood (–5531.9051) is shown. The percentage of trees in which the associated taxa clustered is shown next to the branches. Initial tree(s) for the heuristic search were obtained automatically by applying neighbor-joining and BioNJ algorithms (<http://bionj.org/about-bionj/>) to a matrix of pairwise distances estimated by using the maximum composite likelihood approach and then selecting the topology with superior log likelihood value. The tree is drawn to scale; branch lengths are measured in the number of substitutions per site. The analysis involved 5-nt sequences. Codon positions included were 1st+2nd+3rd+Noncoding. All positions containing gaps and missing data were eliminated. The final dataset contained 3,642 positions. Evolutionary analyses were conducted in MEGA5 (9).

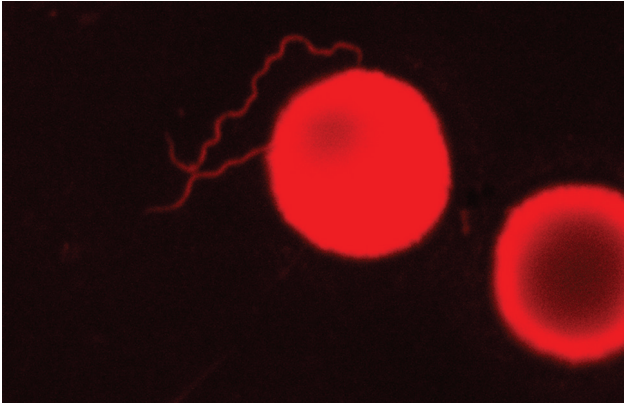


Figure 2. *Borrelia miyamotoi* in cerebrospinal fluid stained by acridine orange (LSM Exciter 5, Zeiss, Germany). The cerebrospinal fluid was from a 74-year-old woman with non-Hodgkin lymphoma. Original magnification $\times 1,000$.

Europe of up to 3.2% (2), clinicians should be aware that cases of *B. miyamotoi* neuroborreliosis may increase (4).

Detection of specific antibodies is a useful complementary diagnostic method. Only recently it was shown that assays based on the GlpQ protein, which is present in relapsing fever *Borrelia* but absent in *B. burgdorferi* sensu lato, might be useful in diagnosing *B. miyamotoi* infection (2,3). Moreover, up to 90% of PCR-confirmed *B. miyamotoi* infections were positive in a *B. burgdorferi* enzyme immunoassay, although only a few by 2-tiered testing (reviewed in 3). For the case we report, we had no access to a GlpQ assay, and the standard serologic tests for Lyme borreliosis were negative, as it was for the 2 published reports (4,5). However, a clinician relies on combining history, clinical examination, and routine CSF analyses. Clinicians should therefore be aware of possible *B. miyamotoi* neuroborreliosis, especially in patients who have a history of non-Hodgkin lymphoma and recent rituximab treatment. The clinical picture seems to be unspecific. Although the patient we report had acute symptoms (dizziness, vomiting, and headache) of short duration, the other published cases had decline in mental status (slow cognitive processing, memory deficits), and disturbed gait developing gradually over several months. All 3 *B. miyamotoi* cases had CSF pleocytosis with elevated CSF protein concordant with CSF changes found in LNB (Table). We even found slight intrathecal IgM synthesis, as is seen in 70% of patients with LNB (6). However, a viral cause must be excluded, especially when CSF protein is only slightly elevated.

In recent years, CXCL13 has been identified as a potentially sensitive and specific biomarker for diagnosing acute LNB. It was a useful indicator in our investigation and might be a suitable indicator for diseases caused by spirochetes in general, as was already shown for *B. burgdorferi* and *Treponema pallidum* (7). Furthermore, the

amounts of this chemokine might be used to assess the success of therapy because it declined rapidly in the patient we report after therapy began (Table). In contrast to the lack of sensitivity of culture and PCR for detecting *B. burgdorferi* in CSF, *B. miyamotoi*, as a member of the relapsing fever spirochete group, was detectable by microscopy and by PCR in the CSF in this patient, as well as in the 2 previously reported (4,5). Darkfield microscopy or staining with acridine orange might be required to increase sensitivity. In all 3 cases, PCR targeting the panbacterial 16S rRNA followed by sequencing showed the causative species. Our report of *B. miyamotoi* infection in a patient from Germany indicates that this emergent agent of central nervous system infection can be diagnosed by using existing methods if clinicians are aware of it.

Acknowledgments

We thank Christian Schmeer for his technical support concerning microscopy of the acridine orange slide and Clara Lettl and Cecilia Hizo-Teufel for excellent technical assistance.

S.L. managed the patient. K.B., B.H., and V.F. were involved in the diagnostic testing. G.M. performed the molecular biological investigations. All authors contributed to writing the article.

Dr. Boden is a physician at the University Hospital Jena and specializes in clinical chemistry, laboratory medicine, and medical microbiology. Her research interests include infectious diseases of the central nervous system and zoonotic pathogens.

References

- Platonov AE, Karan LS, Kolyasnikova NM, Makhneva NA, Toporkova MG, Maleev VV, et al. Humans infected with relapsing fever spirochete *Borrelia miyamotoi*, Russia. *Emerg Infect Dis*. 2011;17:1816–23. <http://dx.doi.org/10.3201/eid1710.101474>
- Krause PJ, Fish D, Narasimhan S, Barbour AG. *Borrelia miyamotoi* infection in nature and in humans. *Clin Microbiol Infect*. 2015;21:631–9. <http://dx.doi.org/10.1016/j.cmi.2015.02.006>
- Telford SR III, Goethert HK, Molloy PJ, Berardi VP, Chowdri HR, Gugliotta JL, et al. *Borrelia miyamotoi* disease: neither Lyme disease nor relapsing fever. *Clin Lab Med*. 2015;35:867–82. <http://dx.doi.org/10.1016/j.cll.2015.08.002>
- Gugliotta JL, Goethert HK, Berardi VP, Telford SR III. Meningoencephalitis from *Borrelia miyamotoi* in an immunocompromised patient. *N Engl J Med*. 2013;368:240–5. <http://dx.doi.org/10.1056/NEJMoa1209039>
- Hovius JW, de Wever B, Sohne M, Brouwer MC, Coumou J, Wagemakers A, et al. A case of meningoencephalitis by the relapsing fever spirochaete *Borrelia miyamotoi* in Europe. *Lancet*. 2013;382:658. [http://dx.doi.org/10.1016/S0140-6736\(13\)61644-X](http://dx.doi.org/10.1016/S0140-6736(13)61644-X)
- Djukic M, Schmidt-Samoa C, Lange P, Spreer A, Neubieser K, Eiffert H, et al. Cerebrospinal fluid findings in adults with acute Lyme neuroborreliosis. *J Neurol*. 2012;259:630–6. <http://dx.doi.org/10.1007/s00415-011-6221-8>
- Hytönen J, Kortela E, Waris M, Puustinen J, Salo J, Oksi J. CXCL13 and neopterin concentrations in cerebrospinal fluid of patients with Lyme neuroborreliosis and other diseases that cause neuroinflammation. *J Neuroinflammation*. 2014;11:103. <http://dx.doi.org/10.1186/1742-2094-11-103>

8. Nei M, Kumar S. Molecular evolution and phylogenetics. New York: Oxford University Press; 2000.
9. Tamura K, Peterson D, Peterson N, Stecher G, Nei M, Kumar S. MEGA5: Molecular Evolutionary Genetics Analysis using maximum likelihood, evolutionary distance, and maximum parsimony methods. *Mol Biol Evol.* 2011;28:2731–9. <http://dx.doi.org/10.1093/molbev/msr121>
10. Tsutsumi Y, Yamamoto Y, Ito S, Ohigashi H, Shiratori S, Naruse H, et al. Hepatitis B virus reactivation with a rituximab-containing regimen. *World J Hepatol.* 2015;7:2344–51. <http://dx.doi.org/10.4254/wjh.v7.i21.2344>

Address for correspondence: Katharina Boden, University Hospital Jena, Institute of Clinical Chemistry and Laboratory Medicine, Erlanger Allee 101 Jena 07747, Germany; email: katharina.boden@labor-greiz.de

May 2015: Vectorborne Infections Including:

- Transmission of Hepatitis C Virus among Prisoners, Australia, 2005–2012
- Recent US Case of Variant Creutzfeldt-Jakob Disease—Global Implications
- Novel Thogotovirus Associated with Febrile Illness and Death, United States, 2014
- Detecting Spread of Avian Influenza A(H7N9) Virus Beyond China
- Pathologic Changes in Wild Birds Infected with Highly Pathogenic Avian Influenza (H5N8) Viruses, South Korea, 2014
- Itaya Virus, a Novel Orthobunyavirus Associated with Human Febrile Illness, Peru
- Isolation of *Onchocerca lupi* in Dogs and Black Flies, California, USA
- Molecular Epidemiology of *Plasmodium falciparum* Malaria Outbreak, Tumbes, Peru, 2010–2012
- Delayed-Onset Hemolytic Anemia in Patients with Travel-Associated Severe Malaria Treated with Artesunate, France, 2011–2013
- Protective Antibodies against Placental Malaria and Poor Outcomes during Pregnancy, Benin
- The Fourth Case of Variant Creutzfeldt-Jakob Disease in the United States: Global Implications
- Canine Distemper in Endangered Ethiopian Wolves
- Comparative Sequence Analyses of La Crosse Virus Strain Isolated from Patient with Fatal Encephalitis, Tennessee, USA
- Low-level Circulation of Enterovirus D68–associated Acute Respiratory Infections, Germany, 2014
- Rapid Emergence of Highly Pathogenic Avian Influenza Subtypes from a Subtype H5N1 Hemagglutinin Variant
- Postmortem Stability of Ebola Virus
- Malaria Imported from Ghana by Returning Gold Miners, China, 2013

<http://wwwnc.cdc.gov/eid/articles/issue/21/05/table-of-contents>

**EMERGING
INFECTIOUS DISEASES®**

Borrelia miyamotoi–Associated Neuroborreliosis in Immunocompromised Persons

Technical Appendix

GenBank Accession Numbers for Nucleotide Sequence of *Borrelia miyamotoi*, Elsteraue, Germany, 2015

BankIt1864937	KT932822	16srRNA
BankIt1864947 Seq1	KT932823	flaB
BankIt1864947 Seq2	KT932824	clpA
BankIt1864947 Seq3	KT932825	clpX
BankIt1864947 Seq4	KT932826	pepX
BankIt1864947 Seq5	KT932827	pyrG
BankIt1864947 Seq6	KT932828	recG
BankIt1864947 Seq7	KT932829	rplB