

have been a cross-species infection from mice to bats in the same habitat.

Although bats rarely come in direct contact with humans, humans can come into more frequent contact with bat urine and feces and, in the case of fruit bats, bat saliva through partially eaten fruits. Bats in the Middle East are not eaten for food but are occasionally hunted. In this study, HKU9-related viruses were detected in apparently healthy fruit bat species from Egypt and Lebanon and appear to cause systemic infection. HKU9-related viruses are not known to cause human disease. MERS-CoV was not detected in bats sampled in this study. More surveillance for bat CoVs in the Middle East is needed, and the zoonotic potential for bat-CoVs requires further study.

This work was funded by the National Institute of Allergy and Infectious Diseases, National Institutes of Health, US Department of Health and Human Services, under contract no. HHSN272201400006C; and supported by the American Lebanese Syrian Associated Charities.

References

- Drexler JF, Corman VM, Drosten C. Ecology, evolution and classification of bat coronaviruses in the aftermath of SARS. *Antiviral Res.* 2014;101:45–56. <http://dx.doi.org/10.1016/j.antiviral.2013.10.013>
- Ithete NL, Stoffberg S, Corman VM, Cottontail VM, Richards LR, Schoeman MC, et al. Close relative of human Middle East respiratory syndrome coronavirus in bat, South Africa. *Emerg Infect Dis.* 2013;19:1697–9. <http://dx.doi.org/10.3201/eid1910.130946>
- Memish ZA, Mishra N, Olival KJ, Fagbo SF, Kapoor V, Epstein JH, et al. Middle East respiratory syndrome coronavirus in bats, Saudi Arabia. *Emerg Infect Dis.* 2013;19:1819–23. <http://dx.doi.org/10.3201/eid1911.131172>
- Yang L, Wu Z, Ren X, Yang F, Zhang J, He G, et al. MERS-related betacoronavirus in *Vespertilio superans* bats, China. *Emerg Infect Dis.* 2014;20:1260–2. <http://dx.doi.org/10.3201/eid2007.140318>
- Hulva P, Maresova T, Dundarova H, Bilgin R, Benda P, Bartonicka T, et al. Environmental margin and island evolution in Middle Eastern populations of the Egyptian fruit bat. *Mol Ecol.* 2012;21:6104–16. <http://dx.doi.org/10.1111/mec.12078>
- Towner JS, Amman BR, Sealy TK, Carroll SA, Comer JA, Kemp A, et al. Isolation of genetically diverse Marburg viruses from Egyptian fruit bats. *PLoS Pathog.* 2009;5:e1000536. <http://dx.doi.org/10.1371/journal.ppat.1000536>
- Kalunda M, Mukwaya LG, Mukuye A, Lule M, Sekyalo E, Wright J, et al. Kasokero virus: a new human pathogen from bats (*Rousettus aegyptiacus*) in Uganda. *Am J Trop Med Hyg.* 1986;35:387–92.
- Amman BR, Albarino CG, Bird BH, Nyakarahuka L, Sealy TK, Balinandi S, et al. A recently discovered pathogenic paramyxovirus, Sosuga virus, is present in *Rousettus aegyptiacus* fruit bats at multiple locations in Uganda. *J Wildl Dis.* 2014;51:774–9. <http://dx.doi.org/10.7589/2015-02-044>
- Woo PC, Wang M, Lau SK, Xu H, Poon RW, Guo R, et al. Comparative analysis of twelve genomes of three novel group 2c and group 2d coronaviruses reveals unique group and subgroup features. *J Virol.* 2007;81:1574–85. <http://dx.doi.org/10.1128/JVI.02182-06>

Addresses for correspondence; Malik Peiris, School of Public Health, The University of Hong Kong, 21 Sassoon Rd, Pokfulam, Hong Kong Special Administrative Region, China; email: malik@hku.hk; Ghazi Kayali, Department of Infectious Diseases, St. Jude Children's Research Hospital, 262 Danny Thomas Pl, Memphis, TN 38105 USA; email: ghazi.kayali@stjude.org

Ebola Virus Disease Complicated by Late-Onset Encephalitis and Polyarthrititis, Sierra Leone

Patrick Howlett, Colin Brown, Trina Helderma, Tim Brooks, Durodamil Lisk, Gibrilla Deen, Marylou Solbrig, Marta Lado

Author affiliations: Kings Sierra Leone Partnership, Freetown, Sierra Leone (P. Howlett, M. Lado); University College London Hospital, London, UK (C. Brown); Medair, Ecublens, Switzerland (T. Helderma); Public Health England, Porton Down, UK (T. Brooks); Connaught Hospital, Freetown (D. Lisk, G. Deen); University of Kansas, Lawrence, Kansas, USA (M. Solbrig)

DOI: <http://dx.doi.org/10.3201/eid2201.151212>

To the Editor: Ebola virus (EBOV) disease is usually an acute illness, but increasing evidence exists of persistent infections and post-Ebola syndromes. We report a case of EBOV encephalitis.

A 30-year-old woman with no known EBOV contact sought treatment at an Ebola isolation unit in Freetown, Sierra Leone, on January 1, 2015 (day 7 of illness). She was afebrile and weak, but ambulatory, with a history of fever, vomiting, diarrhea, headache, and muscle and joint pain. According to local protocol, she was given oral antimalarial, antimicrobial, and antiemetic drugs and oral rehydration therapy. On day 8 of illness, after testing EBOV PCR–positive (cycle threshold [C_t] value of 23.5) (1), she was given intravenous ceftriaxone (2 g) for 7 days, artesunate (180 mg) for 3 days, and Ringer's lactate (4–6 L) with supplemental KCl for 5 days.

During days 13–15, the patient improved, moving independently and talking. On day 16, she became confused; by day 20, she was unresponsive to voices. Intravenous ceftriaxone (2 g) and artesunate (180 mg) were administered for an additional 7 and 3 days, respectively. On days 28 and 29, she was still unconscious; serum PCR test results on both days were negative for EBOV. On day 29, she was transferred to Connaught Hospital in Freetown, where she had a Glasgow Coma Scale score of 9/15 (E3, V1, M5) but no localizing or focal signs. She was

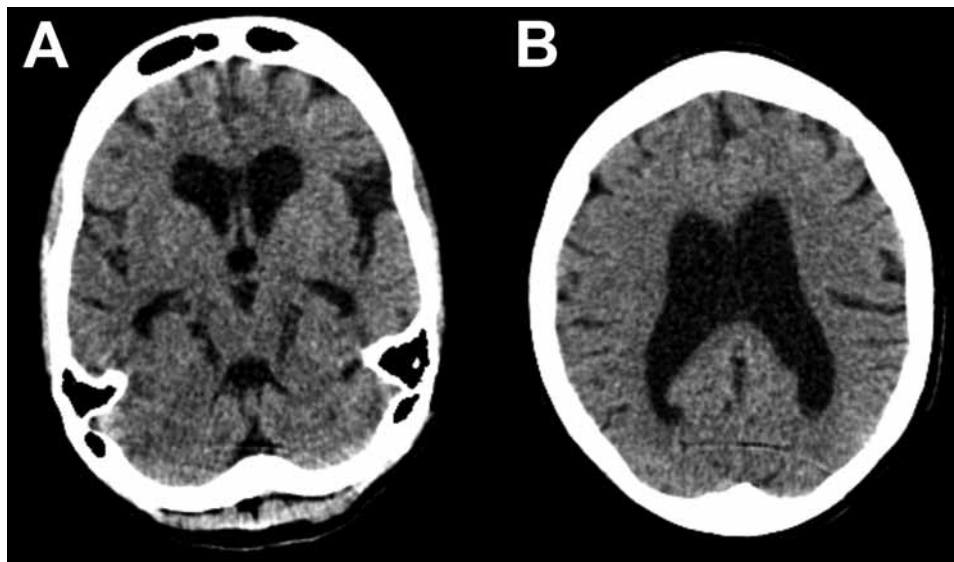


Figure. Representative axial cuts from noncontrast head computed tomography scan imaging of a 30-year-old woman with encephalitis resulting from Ebola virus infection, Sierra Leone. Images show global atrophy in keeping with nonobstructive ventriculomegaly and no periventricular low attenuation: A) subcortical atrophy; B) cortical atrophy. There was no evidence of hydrocephalus, previous stroke, or intracranial hemorrhage. A cavum septum pellucidum was noted in other images.

given intravenous fluconazole (800 mg 1×/d). Admission blood test results showed anemia, elevated alanine aminotransferase and C-reactive protein, and low creatinine (online Technical Appendix, <http://wwwnc.cdc.gov/EID/article/22/1/15-1212-Techapp1.pdf>). HIV test results were negative.

On day 34, large-joint polyarthritides of the right shoulder, left elbow, and left knee developed. Affected joints appeared normal on radiographs, and synovial fluid (15 mL) from the left knee was EBOV PCR negative. She was given diclofenac (50 mg 2×/d) and 1 intramuscular dose of methylprednisolone (80 mg). Concurrent blood PCR on day 34 was negative.

By day 41 she was more alert, although her family reported she had slowed responses. Lumbar puncture was performed; opening pressure (30 cm H₂O) was elevated, and cerebrospinal fluid (CSF) was EBOV PCR-positive (C_t value 37.6), as determined by using the Public Health England in-house, optimized version of the Trombley assay (2) with a cutoff C_t value of 40. Concurrent catheter specimens of urine and blood samples tested EBOV-negative. FilmArray (BioFire Diagnostics, Salt Lake City, UT, USA) testing showed methicillin-resistant *Staphylococcus aureus* and *Klebsiella pneumoniae* in CSF and mixed pathogens in urine. A computer tomographic scan image of the patient's head showed substantial cerebral atrophy without hydrocephalus (Figure).

On day 44, an underarm sweat swab sample was PCR-positive (C_t value 39.6) and a buccal swab sample PCR-negative for EBOV. Ongoing painful synovitis was treated with an additional 80-mg intramuscular dose of methylprednisolone. On day 51, a midstream urine sample was EBOV PCR-positive (C_t value 35.7), and an underarm

sweat swab sample was EBOV PCR-negative. The patient was discharged; her family was advised to minimize contact with her body fluids.

At follow-up on day 64, the patient's family reported she had impaired short-term memory and ongoing slowness. She had a score of 18/23 on the Mini-Mental State Examination, but general neurologic exam results were normal. A midstream urine test was still EBOV PCR-positive (C_t value 39.6); PCR of her sweat swab sample was inhibited (online Technical Appendix). She was referred to the local survivors' clinic; no contact cases were reported.

The depressed mental status and presence of EBOV in this case-patient's CSF are consistent with encephalitis, a finding in autopsies of persons with Marburg virus infection (3,4) and in EBOV nonhuman primate models (5). The general atrophy seen in computer tomographic scan images is consistent with a rapidly developing complication of a diffuse inflammatory process. Given inadequate antimicrobial drug doses for meningitis and clinical improvement, we believe methicillin-resistant *S. aureus* and *K. pneumoniae* were CSF sample contaminants.

This case shows the brain's immune privilege is incomplete for EBOV and prompts a broader discussion regarding neurovirulence in Ebola virus disease. Our finding that EBOV can be present in CSF, even after serum clearance, adds to the knowledge of neurologic symptoms in acute infection and of postinfectious sequelae in observational clinical studies (6–8). This finding raises the possibility that EBOV persistence elsewhere in the body, or in multiple organs, could be an indicator of or risk for central nervous system invasion.

Our report has limitations. We could not perform many blood chemistry tests, in-country virus cultures, or deep sequencing on samples. Likewise, diagnosis of coma was challenging because of the lack of CSF cell counts, biochemistry values, and paired EBOV IgG and IgM titers in CSF and blood.

This case raises the practical issue that Ebola treatment requires understanding of multiorgan virologic and inflammatory complications; survivor care and research programs should screen for neurocognitive impairment and consider appropriate imaging. The case confirms previously reported intermittent EBOV PCR positivity in urine (9). The development of arthritis with synovitis, treated with corticosteroids, supports the diagnosis of reactive arthritis.

References:

1. Logan JM, Edward KJ, Saunders NA. Real-time PCR: current technology and applications. Norfolk (UK): Caister Academic Press; 2009. p. 421–2.
2. Trombley AR, Wachter L, Garrison J, Buckley-Beason VA, Jahrling J, Hensley LE, et al. Comprehensive panel of real-time TaqMan polymerase chain reaction assays for detection and absolute quantification of filoviruses, arenaviruses, and New World hantaviruses. *Am J Trop Med Hyg.* 2010;82:954–60. <http://dx.doi.org/10.4269/ajtmh.2010.09-0636>
3. Bechtelsheimer H, Jacob H, Solcher H. The neuropathology of an infectious disease transmitted by African green monkeys (*Cercopithecus aethiops*). *Ger Med Mon.* 1969;14:10–2.
4. Jacob H. The neuropathology of the Marburg disease in man. In: Martini GA, Siebert R, editors. Marburg virus disease. Berlin: Springer-Verlag; 1971. p. 54–61.
5. Larsen T, Stevens EL, Davis KJ, Geibert JB, Daddario-DiCaprio KM, Jahrling PJ, et al. Pathologic findings associated with delayed death in nonhuman primates experimentally infected with Zaire Ebola virus. *J Infect Dis.* 2007;196(Suppl 2):S323–8. <http://dx.doi.org/10.1086/520589>
6. Bah EI, Lamah MC, Fletcher T, Jacob ST, Brett-Major DM, Sall AA, et al. Clinical presentation of patients with Ebola virus disease in Conakry, Guinea. *N Engl J Med.* 2015;372:40–7. <http://dx.doi.org/10.1056/NEJMoa1411249>
7. Fitzpatrick G, Vogt F, Gbabai OM, Decroo T, Keane M, De Clerck H, et al. The contribution of Ebola viral load at admission and other patient characteristics to mortality in a Médecins Sans Frontières Ebola case management centre, Kailahun, Sierra Leone, June–October, 2014. *J Infect Dis.* 2015 May 22 [Epub ahead of print]. <http://dx.doi.org/10.1093/infdis/jiv304>
8. Bwaka MA, Bonnet MJ, Calain P, Colebunders R, De Roo A, Guimard Y, et al. Ebola hemorrhagic fever in Kikwit, Democratic Republic of the Congo: clinical observations in 103 patients. *J Infect Dis.* 1999;179(Suppl 1):S1–7. <http://dx.doi.org/10.1086/514308>
9. Wolf T, Kann G, Becker S, Stephan C, Brodt HR, de Leuw P, et al. Severe Ebola virus disease with vascular leakage and multiorgan failure: treatment of a patient in intensive care. *Lancet.* 2015;385:1428–35. [http://dx.doi.org/10.1016/S0140-6736\(14\)62384-9](http://dx.doi.org/10.1016/S0140-6736(14)62384-9)

Address for correspondence: Patrick Howlett, Kings Sierra Leone Partnership, 2nd Floor Connaught Hospital, Lightfoot Boston Street, Freetown, Sierra Leone; email: patrick.howlett@gmail.com

Louseborne Relapsing Fever in Young Migrants, Sicily, Italy, July–September 2015

Alessandra Ciervo, Fabiola Mancini, Francesca di Bernardo, Anna Giammanco, Giustina Vitale, Piera Dones, Teresa Fasciana, Pasquale Quartaro, Giovanni Mazzola, Giovanni Rezza

Author affiliations: Istituto Superiore di Sanità, Rome, Italy (A. Ciervo, F. Mancini, G. Rezza); Azienda di Rilievo Nazionale ed Alta Specializzazione Civico Di Cristina e Benfratelli, Palermo, Italy (F. di Bernardo, P. Dones); University of Palermo, Palermo (A. Giammanco, T. Fasciana); Azienda Ospedaliera Universitaria Policlinico, Palermo (G. Vitale, P. Quartaro, G. Mazzola)

DOI: <http://dx.doi.org/10.3201/eid2201.151580>

To the Editor: During the early 20th century, at the end of World War I, and during World War II, louseborne relapsing fever (LBRF) caused by *Borrelia recurrentis* was a major public health problem, especially in eastern Europe and northern Africa (1,2). Currently, poor living conditions, famine, war, and refugee camps are major risk factors for epidemics of LBRF in resource-poor countries, such as those in the Horn of Africa (3,4).

Increased migration from resource-poor countries and war/violence create new routes for spread of vectorborne diseases. Recently, several cases of LBRF have been reported among asylum seekers from Eritrea in the Netherlands, Switzerland, and Germany (5–8). All of these asylum seekers had been in refugee camps in Libya or Italy. We report 3 cases of LBRF in migrants from Somalia to refugee camps in Sicily, Italy.

Patient 1 was a 13-old-boy from Somalia who arrived in Palermo, Italy, on July 11, 2015, after traveling though Libya. He was admitted to G. Di Cristina Hospital in Palermo 5 days after arrival because of high fever, headache, and general malaise, which developed 2 days after arrival. The patient had skin lesions on his fingers and legs and a conjunctival infection. He had thrombocytopenia (79,000 platelets/ μ L [reference range 150 platelets/ μ L–400 platelets/ μ L]), creatine phosphokinase level 967 mg/L [reference range 0.001 mg/L–0.10 mg/L], aspartate aminotransferase level 30 U/L (reference value 37 U/L), and alanine aminotransferase level 21 U/L (reference value 41 U/L). He was given ceftriaxone (2 g/d) and intravenous hydration. His conditions worsened \approx 10 hours after treatment: high fever (temperature 40°C), chills, and profuse sweating (Jarish-Herxheimer reaction). The patient recovered

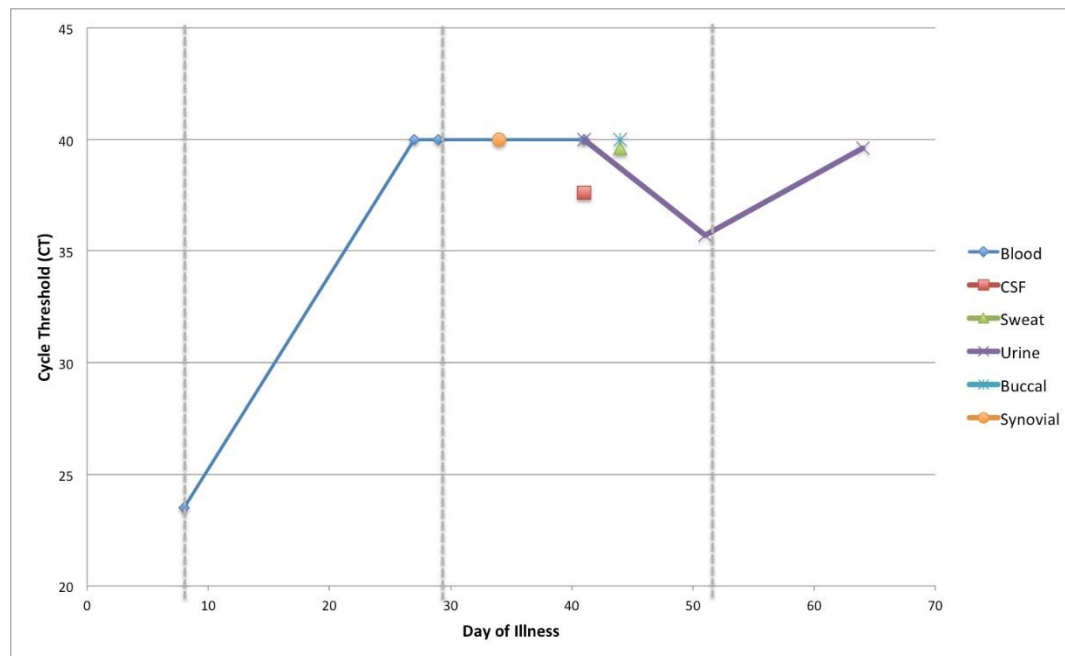
Ebola Virus Disease Complicated by Late Onset Encephalitis and Polyarthrititis

Technical Appendix

Technical Appendix Table. Blood test results at admission for a 30-year-old woman with Ebola virus disease, Sierra Leone*

Parameter	Value or result	Reference range or value
Hemoglobin, g/dL	8.4	11.5–16.0
Platelets, x 10 ⁹ /L	254	150–400
Leukocyte count, x 10 ⁹ /L	5.4	4.0–11.0
Creatinine, μmol/L	34	70–150
Alanine aminotransferase, IU/L	90	5–35
C-reactive protein, mg/L	30	<5
HIV	Negative	NA

*Blood tests were not repeated after admission. NA, not applicable.



Technical Appendix Figure. Cycle threshold results for Ebola virus in body fluids of a 30-year-old woman with Ebola virus disease, Sierra Leone. CSF, cerebrospinal fluid.