

## ***Klebsiella pneumoniae*–Induced Liver Abscesses, Germany**

**To The Editor:** Monomicrobial liver abscesses caused by *Klebsiella pneumoniae* are an emerging problem in Asia. Among 77 capsular types of *Klebsiella* spp., K1 and K2 are the most virulent (1–3). In Asia, isolated strains are mainly serotype K1, followed by K2. In Taiwan, about 63.4% of liver abscesses caused by *K. pneumoniae* are associated with K1 strains and 14.2% by K2 (4); no comparable epidemiologic data for Western countries are available (5,6). Cases of *K. pneumoniae* liver abscesses have been also reported from North America and Europe (6–9); patients outside of Asia predominantly have a history of traveling to high-prevalence countries and/or Asian ethnicity (10).

We describe 2 cases of *K. pneumoniae* liver abscesses in patients in Germany. Both cases were associated with life-threatening metastatic spread of *K. pneumoniae* in previously healthy white patients with no travel history, no Asian ethnicity, and no contact with persons in high-risk groups, including patients with *K. pneumoniae* infection.

Patient 1 was a 48-year-old white male medical doctor with no history of serious medical conditions, who suddenly experienced fever up to 40°C,

abdominal pain, mild diarrhea, and fatigue. Blood analysis revealed signs of inflammation: C-reactive protein level of 26 mg/dL. Erythrocyte and leukocyte counts were within reference ranges, but thrombocytes were decreased (43,000 cells/mL) and liver enzymes were increased (glutamate pyruvate transaminase 112 U/L, aspartate aminotransferase 75 U/L, gamma glutamyl transferase 332 U/L). An initial chest radiograph and abdominal ultrasonograms were unremarkable. *K. pneumoniae* was isolated from blood and urine and was later characterized as K1 capsular type (no further typing techniques could be performed because no sample was stored). Ceftriaxone was administered, in accordance with an antibiogram, but the patient's condition worsened and he required mechanical ventilation and treatment with a catecholamine in an intensive care unit. A computed tomographic (CT) scan showed 2 liver abscesses and infiltrates of both lungs with pleural effusion (Figure). Under CT guidance, the liver abscesses were punctured and drained percutaneously by using pigtail catheters. After this intervention, the patient recovered gradually. The drain was removed after 10 days, and ceftriaxone treatment was continued for a total of 21 days. The patient recovered and was transferred to a rehabilitation hospital.

Patient 2 was a 71-year-old white woman with type-2 diabetes, who was hospitalized for epigastric pain and fatigue. Laboratory results showed an

increased level of C-reactive protein (13 mg/dL), blood count and liver enzymes within reference range, and a urinary tract infection positive for nitrite and leukocytes (500/mL). Abdominal ultrasonography revealed a 3 × 4-cm subcapsular lesion in the left lobe of the liver, highly suspect for metastatic spread of an unknown tumor. Chest radiographs, taken in search of the primary lesion, revealed a lesion in the right upper lung; on follow-up CT images, this lesion was suspect for malignancy (Figure). For diagnostic purposes, the liver lesion was punctured and a sample was obtained. Histologic analysis revealed pus, which was in accordance with an abscess. A pigtail drain was placed, and *K. pneumoniae* was cultured from the liver punctate as well as from the urine. The isolate proved to be serotype K2. Multilocus sequencing of this strain confirmed the presence of the *wzx2* and *wzy2* genes. In accordance with susceptibility test results, therapy with ceftriaxone and ciprofloxacin was initiated. Dislocation of the pigtail catheter resulted in an abscess of the abdominal wall, which required additional surgical treatment. However, the patient recovered within 2 weeks. Follow-up CT images showed resolution of the thoracic lesion and only a residual scar on the liver lobe (online Technical Appendix <http://wwwnc.cdc.gov/EID/article/20/11/14-0149-Techapp1.pdf>).

These 2 cases of community-acquired *K. pneumoniae* serotype K1 and K2 liver abscesses with metastatic spread to the lung and urinary systems

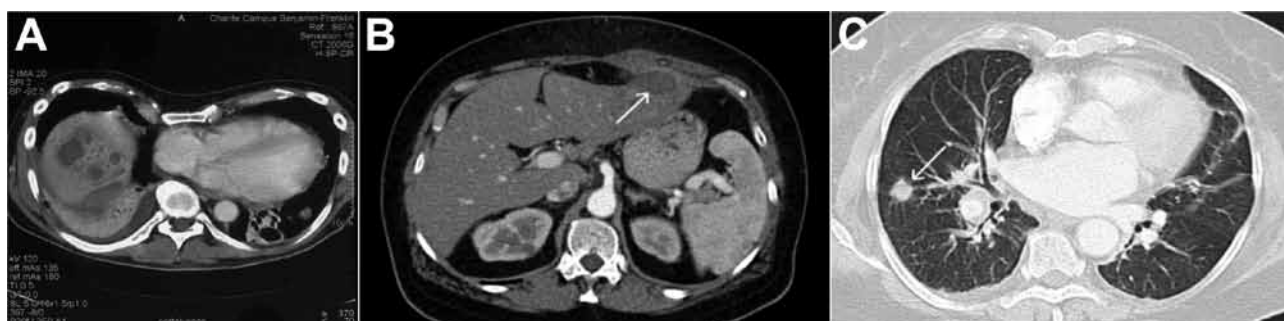

Figure. Pretreatment computed tomography images of patients with *Klebsiella pneumoniae* liver abscesses. A) Multilobular abscess in segment 8 of the liver and pleural effusion in 48-year-old white man (patient 1). B) Liver abscess (arrow) in 71-year-old white woman with type-2 diabetes (patient 2). C) Lung lesion (arrow) in patient 2.

in previously healthy white patients from Germany differ from previously published cases. These 2 patients were not of Asian ethnicity and had no travel history, no contact with persons in a high-risk group (10), and no common risk factors such as malignancy (8); however, 1 patient had type-2 diabetes. *K. pneumoniae* liver abscesses might be an emerging problem with global spread. Although initial radiographic findings might more commonly indicate metastasis than abscesses, differential diagnosis of liver lesions should include *K. pneumoniae*-induced abscesses.

**Sueleyman Bilal,<sup>1</sup>  
Magdalena Sarah Volz,<sup>1</sup>  
Tomas Fiedler,  
Rainer Podschun,  
and Thomas Schneider**

Author affiliations: Charité University Medicine Berlin, Berlin, Germany (S. Bilal, M.S. Volz, T. Schneider); Rostock University Medical Center, Rostock, Germany (T. Fiedler); and University Hospital Schleswig-Holstein, Kiel, Germany (R. Podschun)

DOI: <http://dx.doi.org/10.3201/eid2011.140149>

## References

1. Tsai FC, Huang YT, Chang LY, Wang JT. Pyogenic liver abscess as endemic disease, Taiwan. *Emerg Infect Dis*. 2008;14:1592–600. <http://dx.doi.org/10.3201/eid1410.071254>
2. Chung DR, Lee SS, Lee HR, Kim HB, Choi HJ, Eom JS, et al. Emerging invasive liver abscess caused by K1 serotype *Klebsiella pneumoniae* in Korea. *J Infect*. 2007;54:578–83. <http://dx.doi.org/10.1016/j.jinf.2006.11.008>
3. Siu LK, Yeh KM, Lin JC, Fung CP, Chang FY. *Klebsiella pneumoniae* liver abscess: a new invasive syndrome. *Lancet Infect Dis*. 2012;12:881–7. [http://dx.doi.org/10.1016/S1473-3099\(12\)70205-0](http://dx.doi.org/10.1016/S1473-3099(12)70205-0)
4. Fung CP, Chang FY, Lee SC, Hu BS, Kuo BI, Liu CY, et al. A global emerging disease of *Klebsiella pneumoniae* liver abscess: is serotype K1 an important factor for complicated endophthalmitis? *Gut*. 2002;50:420–4. <http://dx.doi.org/10.1136/gut.50.3.420>

<sup>1</sup>These authors contributed equally to this article.

5. Fang FC, Sandler N, Libby SJ. Liver abscess caused by magA+ *Klebsiella pneumoniae* in North America. *J Clin Microbiol*. 2005;43:991–2.
6. Sobirk SK, Struve C, Jacobsson SG. Primary *Klebsiella pneumoniae* liver abscess with metastatic spread to lung and eye, a North-European case report of an emerging syndrome. *Open Microbiol J*. 2010;4:5–7. <http://dx.doi.org/10.2174/1874285801004010005>
7. Nadasy KA, Domiati-Saad R, Tribble MA. Invasive *Klebsiella pneumoniae* syndrome in North America. *Clin Infect Dis*. 2007;45:e25–8. <http://dx.doi.org/10.1086/519424>
8. Ali AH, Smalligan RD, Ahmed M, Khasawneh FA. Pyogenic liver abscess and the emergence of *Klebsiella* as an etiology: a retrospective study. *Int J Gen Med*. 2013;7:37–42.
9. Moore R, O'Shea D, Geoghegan T, Mallon PW, Sheehan G. Community-acquired *Klebsiella pneumoniae* liver abscess: an emerging infection in Ireland and Europe. *Infection*. 2013;41:681–6. <http://dx.doi.org/10.1007/s15010-013-0408-0>
10. Liu Y, Wang JY, Jiang W. An increasing prominent disease of *Klebsiella pneumoniae* liver abscess: etiology, diagnosis, and treatment. *Gastroenterol Res Pract*. 2013;2013:258514.

Address for correspondence: Magdalena Sarah Volz, Charité–Universitätsmedizin Berlin, Medical Center for Gastroenterology, Infectiology and Rheumatology, Hindenburgdamm 30, 12200 Berlin, Germany; email: [magdalena.volz@charite.de](mailto:magdalena.volz@charite.de)

## Hepatitis E Virus and Implications for Blood Supply Safety, Australia

**To the Editor:** Hepatitis E virus (HEV) is an emerging public health concern for industrialized countries (1). Although HEV infection has been associated with travel to countries where the virus is endemic, cases of autochthonous HEV are increasing (2). Detection of HEV RNA in blood donations in the United Kingdom,

Germany, the Netherlands, Japan, and China and accumulating reports of HEV transmitted through blood transfusion highlight the potential risk this virus poses to blood supply safety (1–4).

In Australia, where most HEV infections are associated with travel (5), an average of 25 HEV cases occurred each year during 1999–2013 ([http://www9.health.gov.au/cda/source/rpt\\_3.cfm](http://www9.health.gov.au/cda/source/rpt_3.cfm)). HEV infection is nationally notifiable in Australia, but the presence of subclinical infections and the lack of recent seroprevalence studies have prevented the accurate estimation of HEV incidence and population exposure. Thus, we examined HEV seroprevalence in a cohort of Australian blood donors, assessed risk factors for exposure, and used the data to examine the effectiveness of current blood safety strategies for the management of HEV in Australia.

Plasma samples (n = 3,237) were collected from donors during August–September 2013. Information on age, sex, state of residence, new/repeat donor status, and overseas travel disclosure was obtained. Details of any relevant blood donation deferral (malaria, diarrhea) applied on previous donation attempts were also collected. Application of a specific malaria deferral code is routine for donors disclosing travel to a malaria-endemic country, and a diarrhea deferral applies when a donor reports having had diarrhea (of viral or unknown cause) 1 week before any attempted donation.

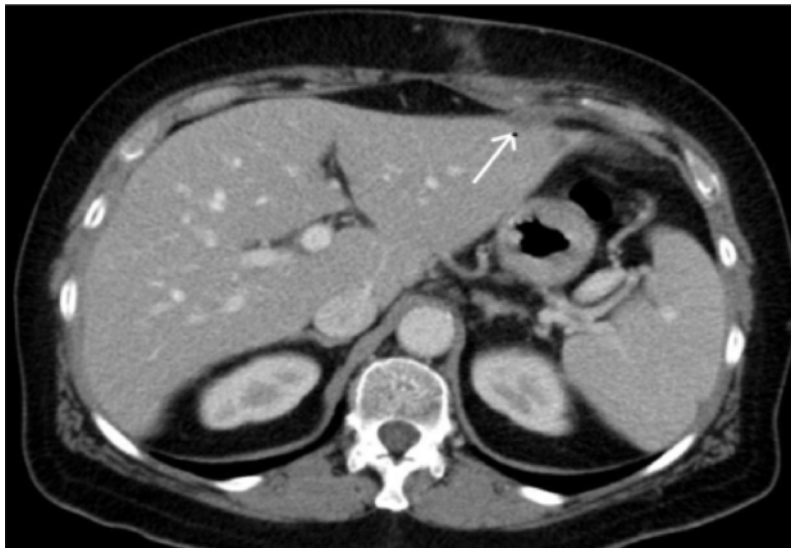All samples were tested for HEV IgG by using the Wantai HEV-IgG ELISA (Beijing Wantai Biologic Pharmacy Enterprise Co., Ltd, Beijing, China). Positive samples were tested for HEV IgM by using the Wantai HEV-IgM ELISA and for HEV RNA by using a prototype transcription-mediated amplification assay (Hologic Inc., San Diego, CA, USA).

Of 3,237 samples, 194 (5.99%) were positive for HEV IgG (95% CI 5.18–6.81). Compared with estimates

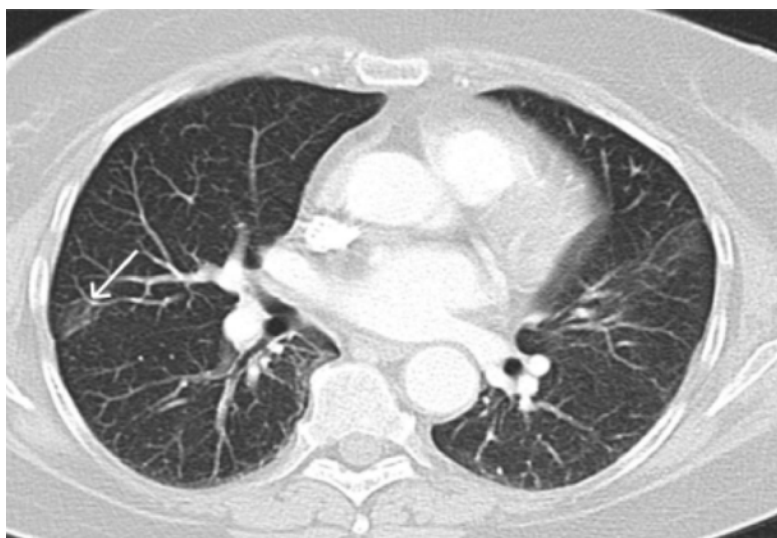
# *Klebsiella pneumoniae*–Induced Liver Abscesses, Germany

## Technical Appendix

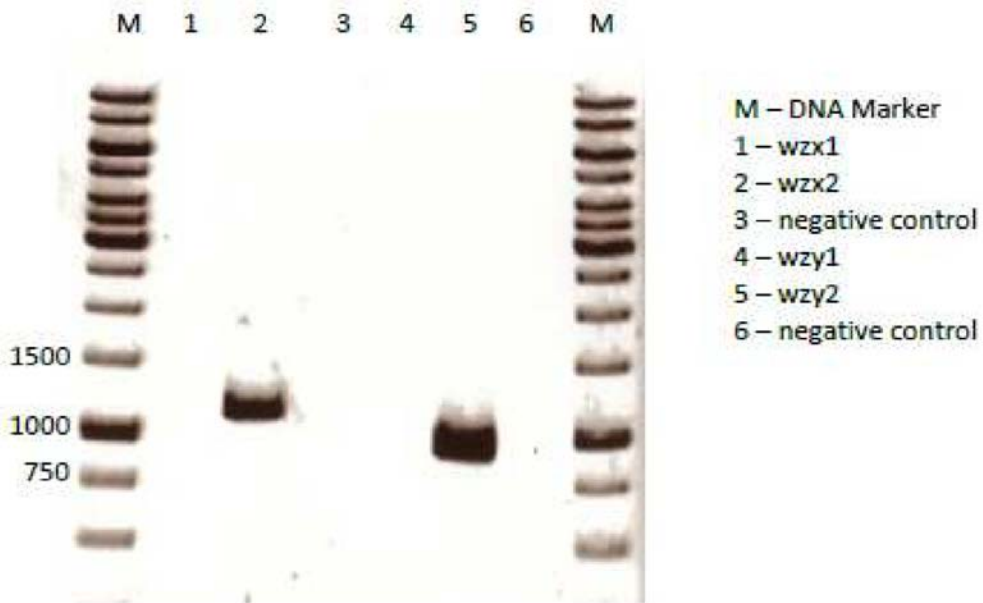
A



B



C



Technical Appendix legend. A and B) Posttreatment computed tomography images of liver abscess (arrow) (A) and lung lesion (B) in 71-year-old white woman with type-2 diabetes (patient 2). C) PCR of the *Klebsiella pneumoniae* K2 strain isolated from a patient with liver abscess (patient 2).