

feline strains from Italy and Australia grouped together, as did the P[9] strains from the United States.

Thus, both the VP7 and VP4 genes of G3P[9] strain identified in this study were most closely related to a racoon dog rotavirus strain (RAC-DG5), suggesting an animal origin of this rotavirus strain. These strains are likely an example of an animal strain causing limited disease in humans, rather than existence of a true strain, which has entered and adapted to the human environment. Recent whole-genome sequencing of 2 G3P[9] strains isolated from children in Italy showed they were composed of genes of human, bovine, and feline origin (2); whether the G3P[9] strains from Malaysia identified in this study are also human/animal reassortant strains requires further study.

Identification of G3P[9] strains in Malaysia continues to highlight the presence of these rare strains in Asian communities. The close similarity of the strains to a G3P[9] strain from a racoon dog further highlights the transmission of rotavirus strains between animal and human sources. Whether this strain can establish itself in humans and cause disease is unknown, but the identification of rare strains illustrates that movement of rotaviruses between various hosts does occur from time to time.

**Ling-Sing Ch'ng, Way S. Lee,
and Carl D. Kirkwood**

Author affiliations: Murdoch Childrens Research Institute, Parkville, Victoria, Australia (L.-S. Ch'ng, C.D. Kirkwood); University of Melbourne, Melbourne, Victoria, Australia (L.-S. Ch'ng, C.D. Kirkwood); and University of Malaya, Kuala Lumpur, Malaysia (W.S. Lee)

DOI: 10.3201/eid1705.101652

References

1. Parashar UD, Burton A, Lanata C, Bosch-Pinto C, Shibuya K, Steele D, et al. Global mortality associated with rotavirus disease among children in 2004. *J Infect Dis.* 2009;200:S9–15. doi:10.1086/605025

2. De Grazia S, Giammanco GM, Potgieter AC, Matthijnssens J, Bányai KN, Platia MA, et al. Unusual assortment of segments in 2 rare human rotavirus genomes. *Emerg Infect Dis.* 2010;16:859–62.
3. Griffin DD, Nakagomi T, Hoshino Y, Nakagomi O, Kirkwood CD, Parashar UD, et al. Characterization of nontypeable rotavirus strains from the United States: identification of a new rotavirus reassortant (P2A[6],G12) and rare P3[9] strains related to bovine rotaviruses. *Virology.* 2002;294:256–69. doi:10.1006/viro.2001.1333
4. Inoue Y, Kitahori Y. Rare group a rotavirus P[9]G3 isolated in Nara Prefecture, Japan. *Jpn J Infect Dis.* 2006;59:139–40.
5. Khamrin P, Maneekarn N, Peerakome S, Tonusin S, Phan TG, Okitsu S, et al. Molecular characterization of rare G3P[9] rotavirus strains isolated from children hospitalized with acute gastroenteritis. *J Med Virol.* 2007;79:843–51. doi:10.1002/jmv.20840
6. Wang Y-H, Kobayashi N, Zhou X, Nagashima S, Zhu Z-R, Peng J-S, et al. Phylogenetic analysis of rotaviruses with predominant G3 and emerging G9 genotypes from adults and children in Wuhan, China. *J Med Virol.* 2009;81:382–9. doi:10.1002/jmv.21387
7. Rasool NB, Larralde G, Gorziglia MI. Determination of human rotavirus VP4 using serotype-specific cDNA probes. *Arch Virol.* 1993;133:275–82. Medline doi:10.1007/BF01313768
8. Iturriza-Gómara MI, Cubitt D, Desselberger U, Gray J. Amino acid substitution within the VP7 protein of G2 rotavirus strains associated with failure to serotype. *J Clin Microbiol.* 2001;39:3796–8. doi:10.1128/JCM.39.10.3796-3798.2001
9. Simmonds MK, Armah G, Asmah R, Banerjee I, Damanka S, Esona M, et al. New nucleotide primers for p-typing of rotavirus strains: strategies for typing previously untypeable strains. *J Clin Virol.* 2008;42:368–73. doi:10.1016/j.jcv.2008.02.011
10. Tamura K, Dudley J, Nei M, Kumar S. MEGA4: Molecular Evolutionary Genetics Analysis (MEGA) software version 4.0. *Mol Biol Evol.* 2007;24:1596–9. doi:10.1093/molbev/msm092

Address for correspondence: Carl D. Kirkwood, Enteric Virus Group, Murdoch Children's Research Institute, Royal Children's Hospital, Flemington Rd, Parkville, Victoria, 3052, Australia; email: carl.kirkwood@mcri.edu.au

Avian Malaria Deaths in Parrots, Europe

To the Editor: Avian malaria is an insect-borne disease induced by a so far unknown number of protozoan blood parasites of the genera *Plasmodium* and *Haemoproteus* (hematozoa) (1,2). The unintentional introduction of *P. relictum* to the Hawaiian Islands, USA, has had fatal effects for the native bird fauna (3). In Europe, asymptomatic blood infections by hematozoa have been regularly observed, with an especially high prevalence in songbirds (4). However, numerous outbreaks of fatal protozoan infections have been reported over the past 40 years, mainly among psittacines of Australia that have been kept in aviaries (5,6). Diagnosis in all these cases was based on histopathologic detection of protozoan cyst-like structures of unexplained origin in the heart and skeletal muscles and, to a lesser extent, in other organs. In most cases, the protozoans were identified as members of the genus *Leucocytozoon* because of their morphologic features. Recent studies suggest that these cases may, in fact, have been infections of *Besnoitia* spp. (Sarcocystidae) or other unknown hematozoa (5); however, genetic evidence is lacking.

In August 2010, sudden deaths of parrots were noticed in 2 separate aviaries in northern Germany and Switzerland (online Technical Appendix Table, www.cdc.gov/EID/content/17/5/950-Techapp.pdf). Nine yellow-crowned parakeets (*Cyanoramphus auriceps*), 3 barred parakeets (*Bolborhynchus lineola*), and 2 budgerigars (*Melopsittacus undulatus*) died within 2–5 days after a history of reduced general conditions and reduced activity and food intake before death. In addition, 2 budgerigars and 1 barred parakeet in the aviary in Germany showed

lethargy and reduced food intake for 2 weeks but fully recovered. About half of the birds were juvenile. No new birds had been introduced into the aviaries during the previous 24 months.

Necropsy and histologic examination of 7 animals with fatal disease showed numerous large cyst-like protozoan structures (size up to 800 μm in diameter; online Technical Appendix Figure) in myocardial and skeletal muscles and, to a lesser extent, in the lung and the smooth muscles of the intestinal tract without obvious signs of inflammation. The cyst-like structures had a thick eosinophilic outer wall, were partly compartmented by internal septae, and were filled with many merozoites. Surrounding muscle fibers were degenerated or necrotic and, in some cases, associated with hemorrhage. Blood smears of clinically affected animals screened for $\approx 5 \times 10^5$ cells each did not show parasites.

To further characterize the parasites, we carried out a nested PCR and subsequent DNA sequencing as described (7). Notably, phylogenetic comparison of 479 bp of the mitochondrial cytochrome b gene derived from protozoan cyst-like structures with known sequences of avian hematozoa found 99%–100% homology of parasites from both outbreaks with the avian malaria parasites (*Haemoproteus* spp.) of European songbirds (Figure). Identical cytochrome b sequences were detected in a yellow-crowned parakeet from Switzerland (CYAUR1), a budgerigar from Germany (MEUND1), and a *Haemoproteus* sp. (TUPHI1) previously found in the blood of a song thrush (*Turdus philomelos*) in Bulgaria. The sequence derived from the barred parakeet (BOLIN1) of the German outbreak was identical with *H. minutus* of the common blackbird (*T. merula*). In fact, different psittacine species of the German outbreak were infected with different *Haemoproteus*

spp. Because all affected parrots had been bred in Europe and had no contact to imported birds, these results suggest that infection was the result of previously unknown cross-species transmission of *Haemoproteus* spp. between birds of only distantly related orders (8,9).

Blood samples from surviving, asymptomatic animals from the German outbreak were tested cytologically and by nested PCR for the presence of *Haemoproteus* spp. PCR identified *Haemoproteus* sequences in the blood of 3 of 26 psittacines, although parasitic structures were not identifiable in blood smears. Retrieved sequences were identical with that of MEUND1, except for a single-nucleotide polymorphism in 1 sequence (MEUND3; Figure). A latent infection of these animals therefore seems possible and may constitute a potential risk for further horizontal transmission in aviaries by blood-sucking insects such as biting midges (*Culicoides*), the vectors for

Haemoproteus spp. of passerine birds in Europe (2).

In conclusion, we identified the cause of a previously unexplained lethal disease of captive parrots in Europe, induced by numerous large cyst-like megalomeronts in several organs, including the heart. Morphologically, the parasitic structures were strikingly similar to yet undetermined parasites of numerous previous outbreaks (5,6). Genetically, the parasites had 99%–100% homology to known *Haemoproteus* spp. from wild European songbirds. The avian malaria parasites identified are highly prevalent in the native songbird population but generally do not cause overt disease or death in their natural hosts. In contrast, the cases reported here suggest that these parasites that have adapted to European songbirds may cause fatal outbreaks in native psittacines of Australia, New Zealand, and South America that are raised in captivity. These findings also show that preexisting pathogens may

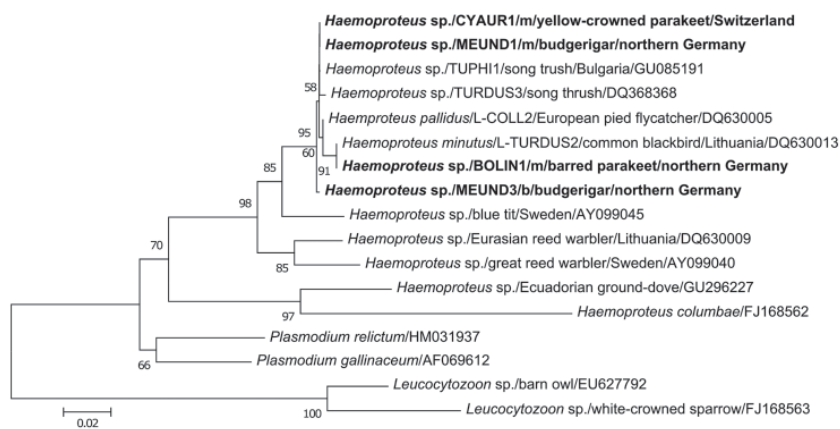


Figure. Phylogenetic relationships based on alignment of 479 bp of the cytochrome b gene of *Haemoproteus* spp. isolated from megalomeronts (m) of infected muscles and blood (b) of parrots with related hematozoan parasites in GenBank and the database MalAvi (<http://mbio-serv4.mbioekol.lu.se/avianmalaria>; 10). Nucleotide distance values of the maximum likelihood phylogenetic tree were calculated under the HKY substitution model. New sequences of *Haemoproteus* spp. from parrots of this study are shown in **boldface**. Two distinct species of the genus *Leucocytozoon* served as outgroup of the phylogenetic tree. The branch lengths are proportional to the degree of inferred evolutionary change as shown by the scale bar, and the numbers indicate bootstrap values (1,000 replicates). While the cytochrome b sequences CYAUR1, MEUND1, and BOLIN1, respectively, found matching sequences, MEUND3 showed closest sequence similarities with *Haemoproteus* spp. of the lineage COLL2, which depict a wider host breadth among songbirds (<http://mbio-serv4.mbioekol.lu.se/avianmalaria>). The isolates of *Haemoproteus* spp. from psittacine birds were deposited into GenBank under accession nos. HQ398207–HQ398212.

be a potential hazard for invading species. Avian malaria should therefore be considered a threat for exotic parrots in Europe until results of further epidemiologic and experimental studies are available. Because many European bird species have been introduced to the native range of the psittacines studied here, a concern has been expressed that these parasites already have become established in these areas and are affecting the natural populations.

**Philipp Olias, Maria Wegelin,
Wolfgang Zenker,
Sabrina Freter,
Achim D. Gruber,
and Robert Klopffleisch**

Author affiliations: Freie Universität, Berlin, Germany (P. Olias, S. Freter, A.D. Gruber, R. Klopffleisch); IDEXX Diavet Labor, Bäch, Switzerland (M. Wegelin); and Animal Clinic Neuwiesen, Uster, Switzerland (W. Zenker)

DOI: 10.3201/eid1705.101618

References

- Atkinson CT, van Riper C III. Pathogenicity and epizootiology of avian haematzoa: *Plasmodium*, *Leucocytozoon*, and *Haemoproteus*. In Loya JE, Zuk M, editors. Bird-parasite interactions. Ecology, evolution, and behavior. New York: Oxford University Press; 1991. p. 19–48.
- Martinsen ES, Perkins SL, Schall JJ. A three-genome phylogeny of malaria parasites (*Plasmodium* and closely related genera): evolution of life-history traits and host switches. *Mol Phylogenet Evol*. 2008;47:261–73. doi:10.1016/j.ympev.2007.11.012
- van Riper C III, van Riper SG, Goff ML, Laird M. The epizootiology and ecological significance of malaria in Hawaiian land birds. *Ecol Monogr*. 1986;56:327–44. doi:10.2307/1942550
- Scheuerlein A, Ricklefs RE. Prevalence of blood parasites in European passeriform birds. *Proc Biol Sci*. 2004;271:1363–70. doi:10.1098/rspb.2004.2726
- Bennett GF, Peirce MA, Ashford RW. Avian haematzoa: mortality and pathogenicity. *J Nat Hist*. 1993;27:993–1001. doi:10.1080/00222939300770621
- Stidworthy MF, Greenwood AG. Deaths in aviary birds associated with protozoal megaloschizonts. *Vet Rec*. 2006;159:606. doi:10.1136/vr.159.18.606
- Hellgren O, Waldenström J, Bensch S. A new PCR assay for simultaneous studies of *Leucocytozoon*, *Plasmodium*, and *Haemoproteus* from avian blood. *J Parasitol*. 2004;90:797–802. doi:10.1645/GE-184R1
- Križanauskienė A, Hellgren O, Kosarev V, Sokolov L, Bensch S, Valkiūnas G. Variation in host specificity between species of avian hemosporidian parasites: evidence from parasite morphology and cytochrome b gene sequences. *J Parasitol*. 2006;92:1319–24. doi:10.1645/GE-873R1
- Ricklefs RE, Fallon SM. Diversification and host switching in avian malaria parasites. *Proc Biol Sci*. 2002;269:885–92. doi:10.1098/rspb.2001.1940
- Bensch S, Hellgren O, Pérez-Tris J. MalAvi: a public database of malaria parasites and related haemosporidians in avian hosts based on mitochondrial cytochrome b lineages. *Mol Ecol Resources*. 2009;9:1353–8. doi:10.1111/j.1755-0998.2009.02692.x

Address for correspondence: Philipp Olias, Department of Veterinary Pathology, Freie Universität Berlin, Robert-von-Ostertag-Str. 15, 14163 Berlin, Germany; email: olias.philipp@vetmed.fu-berlin.de

Fatal Human Case of Western Equine Encephalitis, Uruguay

To the Editor: The genus *Alphavirus* (family *Togaviridae*) comprises 29 viral species (1), grouped in at least 7 antigenic complexes by their serologic cross-reactivity (2). They are maintained in nature through enzootic cycles involving arthropods as vectors with subsequent amplification in small mammals or birds, and epizootic cycles between mosquitoes and large mammals such as horses or humans.

Few reports have been made of the circulation of alphaviruses in Uruguay. A serologic study conducted in 1970

found antibodies to western (WEEV) and eastern equine encephalitis viruses by using complement fixation and hemagglutination inhibition tests in serum specimens from children (3). In 1972–1973, epizootics in horses caused by WEEV were reported in Argentina and Uruguay, and WEEV was isolated from a sick horse (4).

We report a fatal case of viral encephalitis in April 2009 in Montevideo, Uruguay, in a previously healthy 14-year-old boy. Four days before he sought treatment, he had fever, asthenia, and headaches. At hospital admission (April 12, 2009), he was febrile and without neurologic signs; amoxicillin treatment was initiated. Results of a computed tomography scan of the brain were normal.

On day 1, headache, vomiting, neck stiffness, and partial left seizures on the left side developed. Also exhibited were consciousness depression (Glasgow Coma Scale 12 points), hyperreflexia, and bilateral Babinski sign. A cerebrospinal fluid (CSF) sample was negative for bacteria in cultures. An electroencephalogram showed diffuse brain suffering. The patient was brought to the intensive care unit with a clinical diagnosis of viral encephalitis. Over the next 24–36 hours, intracranial hypertension developed, and medical treatment was given (sedation, hyperventilation, mannitol, and barbiturates). Consciousness depression progressed to a deeper level, and a computed tomography scan of the brain showed dilatation of the temporal ventricles and compression of the peritroncal and sylvian cisterns. During the next 48 hours, the coma level went deeper, reaching 6 on the Glasgow Scale. Another CSF specimen was taken, and PCR results were negative for herpesvirus and enterovirus. Glasgow Coma Scale level was 3 on April 15, and a decompressive craniectomy was done. Seventy-two hours after admission, the patient died.

Avian Malaria Deaths in Parrots, Europe

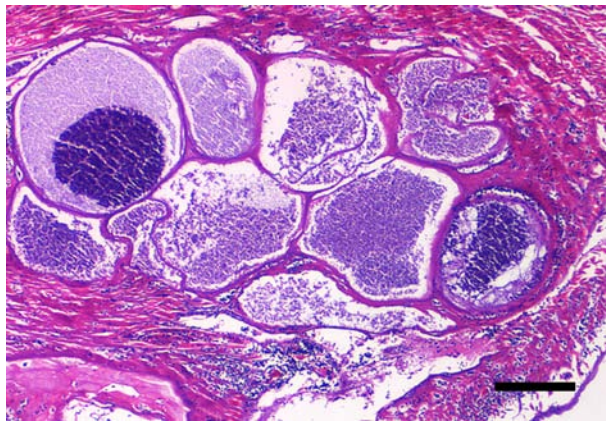
Technical Appendix

Technical Appendix Table. Complete list of animals in the affected aviaries, northern Germany and Switzerland, August 2010

Site location (species)	No. animals died/total	Histologic detection of <i>Haemoproteus</i> spp.		PCR detection of <i>Haemoproteus</i> spp. in blood
		Gametocytes in erythrocytes	Megalomeronts in heart and skeletal muscle†	
Aviary 1 (Germany), 52°16'N, 13°39'E				
Budgerigar (<i>Melopsittacus undulatus</i>)	2/20	0/18	1/1	3/18
Cockatiel (<i>Nymphicus hollandicus</i>)	0/6	0/2	ND	0/2
Barred parakeet (<i>Bolborhynchus lineola</i>)	3/6	0/5	1/1	1/5
Eastern rosella (<i>Platycercus eximius</i>)	0/2	0/2	ND	0/2
Chicken (<i>Gallus gallus domesticus</i>)	0/4	0/4	ND	0/4
Aviary 2 (Switzerland) 47°25'N, 8°50'E				
Yellow-crowned parakeet (<i>Cyanoramphus auriceps</i>)	9/18	ND	5/5	ND
Cockatiel (<i>Nymphicus hollandicus</i>)	0/6	ND	ND	ND
Domestic canary (<i>Serinus canaria</i>)	0/15	ND	ND	ND

*ND, not done.

†Confirmed by PCR.



Technical Appendix Figure. Myocardium of yellow-crowned parakeet that is severely infected with numerous large megalomeronts of *Haemoproteus* spp. Note the thick eosinophilic hyaline wall of megalomeront with internal septation and myriads of spherical basophilic merozoites. Surrounding muscle fibers are degenerated, necrotic, and hemorrhagic (hematoxylin and eosin stain). Scale bar = 150 μ m.