

ated with hypoxia, edema, or other unknown processes. However, the patient had no history of hypotensive episodes, hypoxemia, abnormal metabolic and toxic processes, and other infectious disease. In conclusion, IAAE with pandemic (H1N1) 2009 may be caused by direct viral infection of the CNS and, although its pathogenesis is not clear, physicians should remain alert to this possibility.

**Song Mi Moon, Sung-Han Kim,  
Min Hee Jeong, Eun Hye Lee,  
and Tae-Sung Ko**

Author affiliation: University of Ulsan College of Medicine, Seoul, South Korea

DOI: 10.3201/eid1611.100682

## References

1. Kitcharoen S, Pattapongsin M, Sawanyawisuth K, Angela V, Tiamkao S. Neurologic manifestations of pandemic (H1N1) 2009 virus infection. *Emerg Infect Dis.* 2010;16:569–70. DOI: 10.3201/eid1603.091699
2. Kuiken T, Taubenberger JK. Pathology of human influenza revisited. *Vaccine.* 2008;26(Suppl 4):D59–66. DOI: 10.1016/j.vaccine.2008.07.025
3. Ito Y, Ichiyama T, Kimura H, Shibata M, Ishiwada N, Kuroki H, et al. Detection of influenza virus RNA by reverse transcription PCR and proinflammatory cytokines in influenza-virus-associated encephalopathy. *J Med Virol.* 1999;58:420–5. DOI: 10.1002/(SICI)1096-9071(199908)58:4<420::AID-JMV16>3.0.CO;2-T
4. Franková V, Jirásek A, Tumorová B. Type A influenza: postmortem virus isolations from different organs in human lethal cases. *Arch Virol.* 1977;53:265–8. DOI: 10.1007/BF01314671
5. Centers for Disease Control and Prevention. Neurologic complications associated with novel influenza A (H1N1) virus infection in children, Dallas, Texas, May 2009. *MMWR Morb Mortal Wkly Rep.* 2009;58:773–8.
6. Gonzalez BE, Brust DG. Novel influenza A (H1N1) presenting as an acute febrile encephalopathy in a mother and daughter. *Clin Infect Dis.* 2009;49:1966–7. DOI: 10.1086/649014
7. Webster RI, Hazelton B, Suleiman J, Macartney K, Kesson A, Dale RC. Severe encephalopathy with swine origin influenza A H1N1 infection in childhood: case reports. *Neurology.* 2010;74:1077–8. DOI: 10.1212/WNL.0b013e3181d6b113
8. Sánchez-Torrent L, Triviño-Rodríguez M, Suero-Toledano P, Claret-Teruel G, Muñoz-Almagro C, Martínez-Sánchez L, et al. Novel influenza A (H1N1) encephalitis in a 3-month-old infant. *Infection.* 2010;38:227–9. DOI: 10.1007/s15010-010-0014-3
9. Amin R, Ford-Jones E, Richardson SE, MacGregor D, Tellier R, Heurter H, et al. Acute childhood encephalitis and encephalopathy associated with influenza: a prospective 11-year review. *Pediatr Infect Dis J.* 2008;27:390–5. DOI: 10.1097/INF.0b013e31816507b2
10. Ichiyama T, Isumi H, Ozawa H, Matsubara T, Morishima T, Furukawa S. Cerebrospinal fluid and serum levels of cytokines and soluble tumor necrosis factor receptor in influenza virus associated encephalopathy. *Scand J Infect Dis.* 2003;35:59–61. DOI: 10.1080/0036554021000026986

Address for correspondence: Sung-Han Kim, Department of Infectious Diseases, Asan Medical Center, University of Ulsan College of Medicine, 388-1 Pungnap-2 dong, Songpa-gu, Seoul 138-736, South Korea; email: kimsunghanmd@hotmail.com

## Oseltamivir-Resistant Pandemic (H1N1) 2009 Treated with Nebulized Zanamivir

**To the Editor:** In late November 2009, a 3-year-old immunocompromised boy experienced an upper respiratory tract infection caused by influenza A pandemic (H1N1) 2009 virus, as demonstrated by a positive result for real-time PCR on a nasal swab specimen. His medical history was notable for a congenital intracardiac tumor; an ABO-incompatible heart transplant at 2 months of age; and an Epstein-Barr virus-related humoral rejection 20 months later that was treated with anti-CD20 and plasmapheresis and continuous immunosuppressive ther-

apy with tacrolimus and everolimus. Thus, a 5-day regimen of oseltamivir treatment was undertaken, and the patient's clinical signs improved.

However, 3 days after drug treatment was suspended, the child had a relapse and exhibited fever, cough, and mild respiratory distress. The patient had fine crackles in the left posterior basal lung, normal oxygen saturation, and an infiltrate in the left basal lung, observed on chest radiograph. Infection with pandemic (H1N1) 2009 virus was confirmed. He was then transferred to an isolated ward of the pediatric department, and oseltamivir treatment was again initiated and dosages of immunosuppressive drugs were reduced. However, no clinical or virologic responses were observed during the 3 weeks of drug administration.

Over the next month, the oral dosage of oseltamivir was increased twice, without substantial effects on clinical course and viral clearance of the infection (Figure). Because of persistence of infection, the viral neuraminidase gene was sequenced, which showed the H275Y mutation (*I*). We immediately requested zanamivir aqueous solution from GlaxoSmithKline (Brentford, UK), and, after the approval of the hospital's ethics committee and parents' consent were obtained, nebulized treatment was carried out for 10 days. Fever and respiratory symptoms and signs resolved after 6 days of treatment and progressive real-time PCR gave negative results. Moreover, at the end of the treatment period, chest radiograph did not show abnormal findings, and results of a hemagglutination-inhibition assay were positive for influenza. No zanamivir-related adverse events were observed, except for a mild bronchospasm that responded to albuterol.

Another notable point is that the clinical course of the disease was not severe, although the child was immunocompromised and the infection persisted for almost 2 months. However,

influenza virus persistence, possibly caused by inability of the child's immune system to clear the infection, and prolonged treatment with oseltamivir, led to the appearance of the H275Y mutation. H275Y has been described as the most common mutation that confers oseltamivir resistance in pandemic (H1N1) 2009 infection and has been found in all the resistant isolates reported worldwide (1). Consistent with previous reports (2), in the patient described here, antiviral drug resistance arose early in the treatment course. Retrospective analysis demonstrated the appearance of a mixed population after  $\approx 2$  weeks of drug use with a slow progression toward a pure H275Y variant. This latter finding may be explained by other virologic characteristics of this viral isolate, which is currently undergoing deep sequencing of the full genome.

Zanamivir represents the therapeutic option for patients infected with the H275Y mutation of pandemic (H1N1) 2009 virus. Its licensed formulation as a dry powder is suitable only for patients who can actively use inhaled drugs and thus cannot be used in children <7 years of age (3). Intravenous zanamivir solution has been reported to be safe and effective in experimental influenza A virus infection

and as compassionate therapy in 2 immunocompromised adult patients who underwent mechanical ventilation for severe pneumonia (4,5). Moreover, successful use of intravenous zanamivir in a critically ill child, who was immunosuppressed after allogeneic stem cell transplantation and infected with oseltamivir-resistant pandemic (H1N1) 2009 virus, has been reported (6). In this latter case, the regimen was well tolerated and was associated with a decrease in viral load.

Despite these results showing the efficacy of zanamivir intravenous administration, the inhalatory route for influenza virus-specific drugs should be the first choice, whenever possible, because it delivers therapeutic molecules directly to the site of viral replication, resulting in low systemic exposure. For this reason and because of the mild severity of the patient's disease, we decided to use zanamivir solution nebulized by aerosol. The compliance to this treatment was easily achieved, and the therapy showed good efficacy and was well tolerated by the child. The minor side effect observed has already been reported in the literature (7).

In conclusion, our experience supports the view that in immunocompromised patients with persistent

infection, emergence of resistant viral strains should be strictly monitored. In this context, recently developed real-time PCRs for rapid screening of H275Y could be useful (8). Moreover, although a direct cause and effect has not been confirmed, this case suggests that aerosolized zanamivir solution can be considered as a therapeutic option in young children with mild respiratory symptoms who are infected with oseltamivir-resistant influenza viruses. Additional studies should be conducted in young patients with more severe disease.

Financial support was provided to G.P. from Regione Veneto (Centro Regionale Specializzato per la genotipizzazione ed epidemiologia molecolare degli agenti da infezione per la diagnostica microbiologica e virale. Dgr n. 448 del 24.02.2009).

**Liviana Da Dalt,  
Arianna Calistri,  
Chiara Chillemi,  
Riccardo Cusinato,  
Elisa Franchin, Cristiano Salata,  
Dino Sgarabotto,  
Giuseppe Toscano,  
Antonio Gambino,  
and Giorgio Palù**

Author affiliations: University of Padova, Padova, Italy (L. Da Dalt, A. Calistri, C. Chillemi, E. Franchin, C. Salata, G. Palù); and Azienda Ospedaliera di Padova, Padova (R. Cusinato, E. Franchin, D. Sgarabotto, G. Toscano, A. Gambino)

DOI: 10.3201/eid1611.100789

## References

- Centers for Disease Control and Prevention. World Health Organization. Pandemic (H1N1) 2009, update 91. 2010 Mar 12 [cited 2010 Mar 23]. [http://www.who.int/csr/don/2010\\_03\\_12/en/index.html](http://www.who.int/csr/don/2010_03_12/en/index.html).
- Centers for Disease Control and Prevention. Oseltamivir-resistant novel influenza A (H1N1) virus infection in two immunosuppressed patients. *MMWR Morb Mortal Wkly Rep.* 2009;58:893–6.

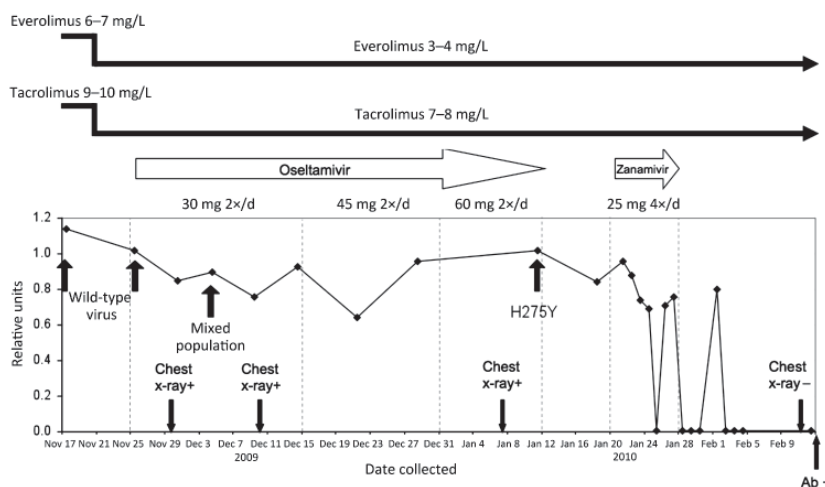


Figure. Schematic showing events surrounding oseltamivir-resistant pandemic (H1N1) 2009 virus infection in 3-year-old immunocompromised child, Italy, in relation to viremia levels, expressed as relative units of influenza A RNA, normalized with respect to the housekeeping gene RNaseP.

3. Halasa NB. Update on the 2009 pandemic influenza A H1N1 in children. *Curr Opin Pediatr*. 2010;22:83–7. DOI: 10.1097/MOP.0b013e3283350317
4. Kidd IM, Down J, Nastouli E, Shulman R, Grant PR, Howell DC, et al. H1N1 pneumonitis treated with intravenous zanamivir. *Lancet*. 2009;374:1036. DOI: 10.1016/S0140-6736(09)61528-2
5. Gaur AH, Bagga B, Barman S, Hayden R, Lamptey A, Hoffman JM, et al. Intravenous zanamivir for oseltamivir-resistant 2009 H1N1 influenza. *N Engl J Med*. 2010;362:88–9. DOI: 10.1056/NEJMc0910893
6. Dulek DE, Williams JV, Creech CB, Schulert AK, Frangoul HA, Domm J, et al. Use of intravenous zanamivir after development of oseltamivir resistance in a critically ill immunosuppressed child infected with 2009 pandemic influenza A (H1N1) virus. *Clin Infect Dis*. 2010;50:1493–6. DOI: 10.1086/652655
7. Cheer SM, Wagstaff A. Spotlight on zanamivir in influenza. *Am J Respir Med*. 2002;1:147–52.
8. Hindiyeh M, Ram D, Mandelboim M, Meninger T, Hirsh S, Robinov J, et al. Rapid detection of influenza A pandemic (H1N1) 2009 virus neuraminidase resistance mutation H275Y by real-time RT-PCR. *J Clin Microbiol*. 2010;48:1884–7. DOI: 10.1128/JCM.02540-09

Address for correspondence: Liviana Da Dalt, Department of Pediatrics, University of Padova, Via N. Giustiniani, 3 – 35121 Padova, Italy; email: liviana.dadalt@unipd.it

## Letters

Letters commenting on recent articles as well as letters reporting cases, outbreaks, or original research are welcome. Letters commenting on articles should contain no more than 300 words and 5 references; they are more likely to be published if submitted within 4 weeks of the original article's publication. Letters reporting cases, outbreaks, or original research should contain no more than 800 words and 10 references. They may have 1 Figure or Table and should not be divided into sections. All letters should contain material not previously published and include a word count.

## Enteric Viruses in Ready-to-Eat Packaged Leafy Greens

**To the Editor:** Fresh produce increasingly has been implicated in viral disease outbreaks (1). In some instances, lettuce was contaminated before wholesale distribution (1). Enteric viruses can be introduced in the field if produce is exposed to human waste. Processed and packaged produce can be contaminated if equipment or wash water is not effectively sanitized. Fewer than 10 infectious viral particles are sufficient to cause disease (2), and these organisms are resistant to disinfectants at concentrations that reduce bacterial levels (3). Contamination of fresh produce could pose a health risk to humans because fresh produce is eaten raw. High levels of viral contamination can result in large outbreaks, but intermittent contamination of fresh produce accounts for some sporadic cases of norovirus and rotavirus gastroenteritis.

During April 27–November 23, 2009, we performed viral testing on 328 samples of packaged leafy greens (representing 12–14 different lots from 3–6 companies per week; no samples were taken on weeks with a statutory holiday) for norovirus or rotavirus RNA. Packaged leafy greens were purchased from retail stores in southern Ontario, Canada. Shipments maintained an average temperature of 3.8°C during transit to the testing laboratory. Each 25-g sample was spiked with 10<sup>6</sup> PFU of feline calicivirus (FCV) as a sample process control (4). Virus was concentrated by using an adsorption-elution-ultrafiltration filtration protocol (4).

Recovery of FCV was quantified from an RNA standard curve. FCV process control recovery was <0.01% for 55 (17%) samples. Recovery of ≥0.01% of the FCV was observed for

the remaining 273 (83%) samples. Two samples from which FCV was not recovered were positive for norovirus (CE-V-09–0138) and rotavirus (CE-V-09–0129); they were considered true positive results.

Of these 275 samples, 148 (54%) were positive for norovirus by real-time reverse transcription–PCR (RT-PCR) (5), and 1 (0.4%) was positive for rotavirus group A by RT-PCR (6). To confirm detection of norovirus RNA, we amplified a second norovirus target by RT-PCR of region C (5). Only 40 samples (15% of total) produced a band of the expected size for this second norovirus amplicon. Of these 40 amplicons, only 16 (6% of total) could be sequenced to confirm norovirus RNA. The rotavirus-positive sample was confirmed by sequencing.

For some sample dates, multiple lots were positive; for others, no positive samples were identified (Figure). Multiple detections on the same date were not caused by cross-contamination; partial capsid sequencing showed different genetic types on dates when multiple samples were positive (Figure). Results were positive from 5 different brands, and no organic samples were confirmed positive for enteric virus contamination. Of the 16 norovirus strains confirmed, 13 belonged to genogroup I (GI) and 3 to genogroup II (GII) (Figure). All were strain types known to be human pathogens. The group A rotavirus was not subtyped; group A rotaviruses can be human or animal pathogens.

Most noroviruses detected belonged to GI. Previous reports indicate that GI norovirus are more frequently identified in foodborne or waterborne outbreaks; GII.4 noroviruses are more common in large outbreaks spread person to person (7). Identification of GI norovirus is consistent with occasional contamination of produce or wash water. Disinfectants and sanitation agents are used in wash water at low concentrations, at which they have limited efficacy against norovirus (3).